



## Discover Generics

Cost-Effective CT & MRI Contrast Agents



WATCH VIDEO

# AJNR

### CT diagnosis of spinal epidural hematoma.

M J Post, D S Seminer and R M Quencer

*AJNR Am J Neuroradiol* 1982, 3 (2) 190-192

<http://www.ajnr.org/content/3/2/190.citation>

This information is current as  
of June 20, 2025.

## CT Diagnosis of Spinal Epidural Hematoma

M. Judith Donovan Post,<sup>1</sup> David S. Seminer,<sup>2</sup> and Robert M. Quencer<sup>1</sup>

An acute spinal epidural hematoma is a neurosurgical emergency. If a prompt diagnosis is not made and decompression not undertaken shortly after the onset of symptoms, neurologic deficits are usually irreversible and death often ensues [1-6]. Although early recognition of this condition is possible with high-resolution computed tomography (CT) because the hematoma may be directly visualized, the use of high-resolution CT in this condition has not been emphasized in the literature. We report a case of spinal epidural hematoma and subarachnoid blood that developed after traumatic lumbar puncture and anticoagulation. We established the diagnosis with plain and metrizamide CT scans. This diagnosis was confirmed at autopsy.

### Case Report

A 76-year-old man with a history of hypertension was admitted with a complaint of visual loss. He had been well until 5 days before admission when he experienced the sudden onset of blurred vision in both eyes. His vision became progressively worse over the next few days until he could perceive only light. On the day of admission he had a sudden onset of lightheadedness with staggering gait and dysarthria. He had no diplopia, vertigo, dysphagia, weakness, numbness, or headache. The positive findings on physical examination included a blood pressure of 160/90 mm Hg, impairment of memory, visual acuity of 20/100 bilaterally with concentrically constricted visual fields, and mild left-sided weakness and hyperreflexia. The impression was right hemispheric stroke and vertebral basilar insufficiency. Pertinent admission laboratory tests included a prothrombin time and a partial thromboplastin time that were normal, 9.8 sec (with a 10.8 sec control) and 37 sec, respectively.

CT scan of the brain showed a nonhemorrhagic old infarct in the distribution of the right middle cerebral artery. Lumbar puncture was attempted several times at different levels in the upper lumbar spine but was unsuccessful. On several passes, blood was obtained. Because of the patient's symptoms of ischemia to the posterior circulation and the absence of hemorrhage on CT scan, anticoagulation therapy with heparin was initiated 3 hr after lumbar puncture.

About 12 hr after the beginning of heparin therapy, the patient developed a substernal bandlike pressure sensation in his chest. There were no electrocardiographic (ECG) changes. He developed

sudden flaccid paraplegia of the lower extremities 18 hr later, with sensory level to L1. Partial thromboplastin time was more than twice the norm, greater than 100 sec. Although the heparin infusion was stopped and Protamine and Decadron were administered, the sensory level progressed to T4 within the next few hours.

A plain high-resolution CT scan of the thoracolumbar spine with 1.0-cm-thick sections on the GE CT/T 8800 scanner revealed an acute epidural hematoma at several levels of the upper lumbar and mid and lower thoracic spine (figs. 1A and 1B); subarachnoid blood extended to the T5 level (fig. 1C). To better diagnose the exact extent of the hematoma and to show the position of the spinal cord before neurosurgical intervention, myelography was performed. A single midline lumbar puncture at L5-S1 under fluoroscopic control revealed grossly bloody subarachnoid fluid. Metrizamide (5 ml at a concentration of 170 mg/ml) was introduced through a 20 gauge spinal needle. A partial posterior extradural block was encountered at the L2-L3 level. However, the metrizamide passed into the thoracic canal in too small a volume to permit delineation of the upper level of the epidural hematoma on routine radiographs. Subsequent metrizamide CT with 1-cm-thick sections confirmed an epidural hematoma (fig. 1D) and showed that it extended continuously from L2-L3 to T5.

Despite recommendation for immediate surgery, the patient and his family refused, and 18 hr later the patient died. Autopsy revealed a diffuse extensive epidural hematoma from (at least) L1 to C7. There was recent occlusion of the basilar artery, an old infarct of the right parietal lobe, and severe atherosclerosis of the cerebral arteries.

### Discussion

Spinal epidural hematomas develop from trauma, coagulopathies, pregnancy, infection, neoplasm, and rupture of arteriovenous malformations, venous angiomas, or epidural varicose veins [1, 2, 7-9]. They can be spontaneous or can follow minor activities such as coughing, sneezing, or twisting [2, 6, 8, 9]. When iatrogenic, they can be complications of lumbar puncture, epidural spinal anesthesia, spinal surgery, or anticoagulant therapy [2, 6, 7-12]. Subarachnoid bleeding and/or subdural hematoma can also be caused by a spinal tap alone or in conjunction with anticoagulant therapy or thrombocytopenia [6, 10-14]. One-third of the

Received August 3, 1981; accepted September 30, 1981.

<sup>1</sup>Department of Radiology, R-130, Neuroradiology Section, University of Miami School of Medicine, Miami, FL 33101. Address reprint requests to M. J. D. Post, P.O. Box 016960.

<sup>2</sup>Department of Neurology, University of Miami School of Medicine, Miami, FL 33101.



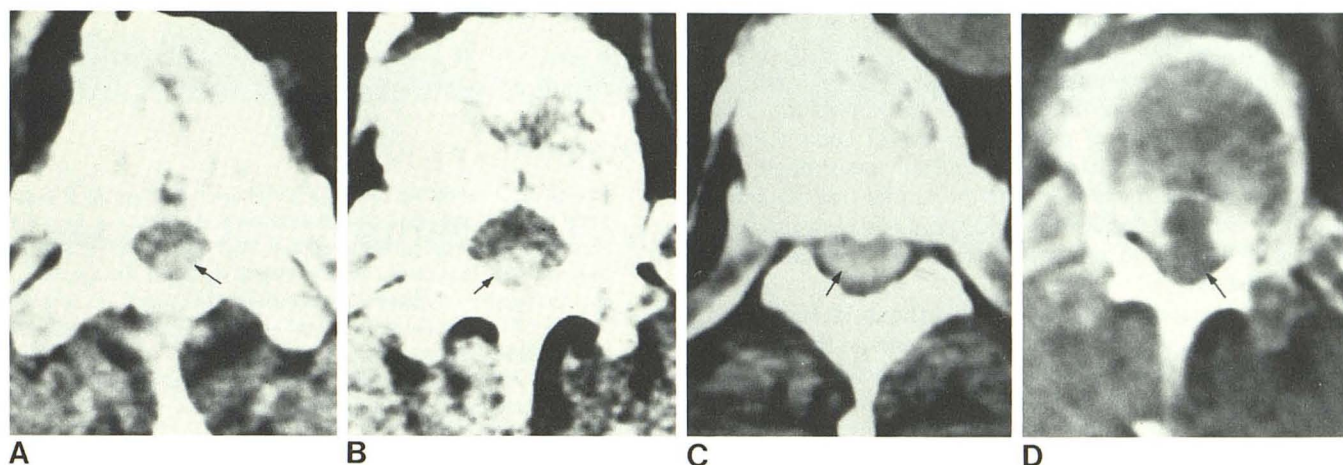


Fig. 1.—A and B, Plain high-resolution CT scans. Acute spinal epidural hematoma (arrows) in thoracic spine diagnosed by sharply demarcated focal areas of increased density of 104–110 Hounsfield units (H). Approximation of hematoma to inner margin of osseous spine. C, Plain high resolution CT scan. Subarachnoid blood (arrow) evident by diffuse area of hyperdensity in

subarachnoid sac (134 H) which surrounds more lucent thoracic spinal cord above level of well defined hematoma. D, Metrizamide high resolution CT scan. Thoracic hematoma as radiolucent posterior extradural filling defect (arrow) displaces metrizamide-filled subarachnoid sac and spinal cord anteriorly.

reported cases of spinal epidural hematoma have developed after anticoagulation with either heparin or dicumarol [6, 12]. Predisposing factors to spinal hemorrhage have included hypertension, old age, clotting studies greater than two times normal, and antecedent lumbar punctures [5, 7]. The risk of bleeding is increased if the lumbar puncture is traumatic and if anticoagulation is initiated within 1 hr after lumbar puncture [10, 14]. Because of this danger, it has been suggested recently that spinal taps might be abandoned as a method for excluding subarachnoid bleeding before anticoagulation [10]. Different investigators have proposed that CT could be used instead to detect any intracranial hemorrhage that might mitigate against the use of anticoagulants for ischemic vascular disease, even though it is known that CT may fail to detect small amounts of blood within the subarachnoid space [10].

Spinal epidural hematomas do not spare any age group and have been reported in patients aged 14 months to 79 years [2, 8]. They are commonly seen, however, in elderly people with hypertension and arteriosclerosis and are uncommon in children [1, 2]. They have no gender predilection [8]. Any spinal level can be involved, although the thoracic spine is most commonly affected [2]. They may be localized to one spinal segment, but extension to three or more spinal levels is common. The entire spinal canal can be affected too [2, 8].

The anatomy of the spinal epidural space seems to be a predisposing factor to the formation and extension of epidural hematomas. The epidural space is composed of loose areolar tissue and an extensive network of epidural veins [2, 12]. These veins are less well protected than the intracranial epidural veins because there is a larger space that separates them from the adjacent bone [12]. They are vulnerable to trauma during lumbar puncture because of their thin walls and large size [12]. Since there are no valves

within this epidural venous system, the epidural veins are not protected against changes in pressure in neighboring venous structures [2]. Therefore, rises in intraabdominal or intrathoracic pressure are readily transmitted to the epidural venous plexus and can result in rupture of these fragile structures. When bleeding occurs, it usually is more extensive posteriorly because the epidural space is the largest there [2].

A spinal epidural hematoma typically develops with dramatic suddenness: there is an abrupt onset of severe back or neck pain with radiation into the chest, legs, or arms [1, 6, 11]. Extremity weakness and urinary retention soon develop [2, 5, 8]. Within minutes, hours, or days, the paresis may progress to paraplegia or quadriplegia [2, 4, 6, 9, 11]. Occasionally, the symptoms and signs of acute spinal cord or cauda equina compression may be preceded by episodic bouts of pain and weakness [4]. This may be due to repeated small hemorrhages in preexisting vascular anomalies. In a small percentage of patients, the onset of symptoms may be insidious, resulting in discovery of a chronic spinal epidural hematoma when a diagnostic evaluation is finally undertaken [8]. Although spontaneous remissions have been reported, the prognosis usually is poor unless surgery is undertaken at the first signs of spinal cord or cauda equina compression [4, 6].

In the past, myelography has been advocated as the procedure of choice for diagnosing spinal epidural hematoma [2, 4, 8]. This study has usually revealed partial or total extradural blocks and less commonly, nonobstructing extradural defects [1–4, 7–9]. Dorsal impingement has predominated over ventral and/or lateral extradural encroachment [2].

More recently, CT has been used to detect spinal hemorrhage. Coin et al. [15, 16] described two cases of spinal epidural hematoma diagnosed by CT, but in neither case



was there pathologic confirmation. No reports have stressed the potential usefulness of CT in assessing spinal hemorrhage and its importance in the early detection of this hematoma. In addition, no reports to our knowledge have mentioned the ability of plain CT to detect subarachnoid blood. Because the incidence of spinal hemorrhage can only be expected to increase with the further use of lumbar puncture and anticoagulant therapy [2, 11, 12], we believe that the value of CT in diagnosing spinal hemorrhage should be emphasized.

We recommend when spinal hemorrhage is suspected clinically, that a plain high-resolution CT scan with 5-mm (or less)-thick sections be obtained not only through the level with well localized clinical signs but above and below that level, for as we have shown a spinal epidural hematoma may extend over many segments. To demonstrate the longitudinal extent of the lesion, sagittal reconstructions should be performed.

The diagnosis of an acute spinal epidural hematoma can be made on plain high resolution CT if a biconvex-shaped hyperdense lesion of blood equivalent density is seen within the spinal canal lying adjacent to the vertebral body and/or posterior arch. The hematoma will be sharply demarcated and smoothly outlined whether it is localized to one side of the spinal canal or is circumferential, and it will be clearly separated from the less dense spinal cord and subarachnoid space. It can be differentiated from an intramedullary hematoma because the latter, although also hyperdense, will have a more central location in the spinal canal and will not be as sharply demarcated, as regular, or as smoothly outlined. Spinal epidural hematoma can also be differentiated from subarachnoid blood because the latter will appear as a diffuse nonlocalized area of increased density, which silhouettes the more lucent-appearing spinal cord.

We believe when a plain high-resolution CT scan demonstrates the findings described above, which are typical for an acute spinal epidural hematoma, that the necessity of performing myelography is precluded. However, if any diagnostic difficulty persists, we recommend that metrizamide myelography be performed, followed by a metrizamide CT scan with 5-mm-thick sections and with sagittal reconstruction. An epidural hematoma will appear on the metrizamide CT scan as a sharply demarcated, peripheral, extradural filling defect that compresses the metrizamide-filled subarachnoid sac and displaces the spinal cord and/or cauda equina.

#### ACKNOWLEDGMENT

We thank Tamera Johnson and Paula B. Garcia for secretarial work and Chris Fletcher for photographic assistance.

#### REFERENCES

1. Ainslie JP. Paraplegia due to spontaneous extradural or subdural hemorrhage. *Br J Surg* 1958;45:565-567
2. Pear BL. Spinal epidural hematoma. *AJR* 1972;115:155-164
3. Dawson BH. Paraplegia due to spinal epidural hematoma. *J Neurol Neurosurg Psychiatry* 1963;26:171-173
4. Cooper DW. Spontaneous spinal epidural hematoma. *J Neurosurg* 1967;26:343-345
5. Senelick RC, Norwood CW, Cohen GH. 'Painless' spinal epidural hematoma during anticoagulant therapy. *Neurology (NY)* 1976;26:213-215
6. Harik SI, Raichle ME, Reis DJ. Spontaneously remitting spinal epidural hematoma in a patient on anticoagulants. *N Engl J Med* 1971;284:1355-1357
7. Alderman DB. Extradural spinal-cord hematoma. Report of a case due to dicumarol and review of the literature. *N Engl J Med* 1956;255:839-842
8. Hehman K, Norrell H. Massive chronic spinal epidural hematoma in a child. *Am J Dis Child* 1968;116:308-310
9. Boyd HR, Pear BL. Chronic spontaneous spinal epidural hematoma: report of two cases. *J Neurosurg* 1972;36:239-242
10. Ruff RL, Dougherty JH Jr. Evaluation of acute cerebral ischemia for anticoagulant therapy: computed tomography or lumbar puncture. *Neurology (NY)* 1981;31:736-740
11. Kirkpatrick D, Goodman SJ. Combined subarachnoid and subdural spinal hematoma following spinal puncture. *Surg Neurol* 1975;3:109-111
12. Edelson RN, Chernik NL, Posner JB. Spinal subdural hematomas complicating lumbar puncture. Occurrence in thrombocytopenic patients. *Arch Neurol* 1974;31:134-137
13. Masdeu JC, Breuer AC, Schoene WC. Spinal subarachnoid hematomas; clue to a source of bleeding in traumatic lumbar puncture. *Neurology (NY)* 1979;29:872-876
14. Brem SS, Hafler DA, Van Uitert RL, Ruff RL, Reichert WH. Spinal subarachnoid hematoma. A hazard of lumbar puncture resulting in reversible paraplegia. *N Engl J Med* 1981;304:1020-1021
15. Coin CG, Pennink M, Ahmad WD, Keranen VJ. Diving-type injury of the cervical spine: contribution of computed tomography to management. *J Comput Assist Tomogr* 1979;3:362-372
16. Coin CG. Computed tomography of the spine. In: Post MJD, ed. *Radiographic evaluation of the spine: current advances with emphasis on computed tomography*. New York: Masson, 1980:394-412