



## Get Clarity On Generics

Cost-Effective CT & MRI Contrast Agents



FRESENIUS  
KABI

WATCH VIDEO

# AJNR

## Unusual manifestation of vein of Galen aneurysm.

R E Fernandez, P R Kishore, M Wilson and T E Barker

*AJNR Am J Neuroradiol* 1982, 3 (4) 440-441

<http://www.ajnr.org/content/3/4/440.citation>

This information is current as  
of August 18, 2025.

# Unusual Manifestation of Vein of Galen Aneurysm

Richard E. Fernandez,<sup>1</sup> Pulla R. S. Kishore,<sup>1</sup>  
Michael Wilson,<sup>1, 2</sup> and T. E. Barker<sup>1, 2</sup>

Vein of Galen aneurysm is a rare congenital malformation that usually presents in early life. A case of such an aneurysm, with previously unreported vascular supply, and which caused symptoms in the seventh decade, is presented with a review of the literature.

## Case Report

A 62-year-old man was seen with an excruciating headache of a few hours duration. The headache was predominantly occipital but extended to the frontal and temporal regions. He also complained of nausea, vomiting, and diplopia. His medical history was unremarkable except for hypertension, which was controlled with medication.

Physical examination revealed a blood pressure of 170/80 mm Hg. There was slight nuchal rigidity. Except for diplopia, no other cranial nerve dysfunction was evident. He was stuporous but easily arousable. The admitting diagnosis was cerebrovascular accident with possible pontine hemorrhage.

Cranial computed tomography (CT) showed a midline high density in the posterior third ventricular region or pineal gland. After intravenous infusion of 75 ml of Renografin 60 (diatrizoate meglumine, 22 g iodine), CT revealed enhancement of the mass by about 20 Hounsfield numbers (H) (figs. 1A and 1B). Hydrocephalus involving the lateral and third ventricles was present. Periventricular low density was present around the anterior horns. There was no evidence of blood in the subarachnoid spaces.

Shortly after admission, the patient became comatose. Lumbar puncture was consistent with recent subarachnoid hemorrhage. Although the CT findings were those of a posterior third ventricular mass lesion, angiography was performed because of the clinical and cerebrospinal fluid findings that indicated subarachnoid hemorrhage.

The right carotid angiogram was normal. The left carotid angiogram revealed prompt opacification (less than 1 sec after injection of contrast medium) of an aneurysm measuring 1.5 cm in diameter in the region of the vein of Galen. The predominant vascular supply to the aneurysm was from hypertrophied tentorial branches of the meningohypophyseal artery (fig. 1C). Vertebral angiography revealed early visualization of the straight sinus with relatively faint opacification of the aneurysm, presumably supplied by the choroidal branches of the left posterior cerebral artery.

Over the next several hours, his neurologic status improved. He was treated with steroids. A ventriculoperitoneal shunting procedure

was performed on hospital day 11 to relieve the hydrocephalus. There was marked clinical improvement, and the patient was discharged on hospital day 21.

## Discussion

Aneurysm of the vein of Galen was first reported by Jaeger et al. [1] in 1937. Since that time, fewer than 200 cases have been reported. Litvak et al. [3] divided vein of Galen aneurysms into three types: (1) aneurysms with direct arterial supply, (2) arteriovenous malformations draining into a dilated vein of Galen, and (3) transitional types of arteriovenous shunts. These authors felt that this division was important in deciding the feasibility of surgical resection and prognosis. Others have minimized this distinction and considered the three types to represent arteriovenous malformations resulting from a single common embryologic defect [4].

Prognosis has been noted to improve with increasing age of presentation, and this has been thought to be a reflection of size because the larger aneurysms tend to present early and the smaller ones later in life [5]. Most of these aneurysms are seen in early life, either in the neonatal period with cardiomegaly and congestive heart failure secondary to massive arteriovenous shunting or in infancy because of increasing head girth or symptoms of hydrocephalus. The latter is believed to be a result of obstruction to the aqueduct of Sylvius from compression by the vein of Galen aneurysm [5]. Adults may present because of hydrocephalus with or without signs of subarachnoid hemorrhage. Headaches are felt to represent either irritation from hemorrhage or from compression and tension by the dilated vein of Galen [5]. In our case, the acuteness of the onset and the presence of blood in the cerebrospinal fluid indicate that the symptoms were from bleeding.

CT examination in our patient showed the lesion as an area of increased density with enhancement in the posterior third ventricular region. Previous reports of CT findings in vein of Galen aneurysms have emphasized increased density representing the dilated straight sinus and torcular Herophili [6, 7] as well as dilated feeding vessels [8]. Neither

Received September 29, 1981; accepted after revision January 7, 1982.

<sup>1</sup>Department of Radiology, Box 615, Medical College of Virginia, Richmond, VA 23298. Address reprint requests to P. R. S. Kishore.

<sup>2</sup>Present address: Department of Radiology, All Saints Episcopal Hospital, Fort Worth, TX 76104.



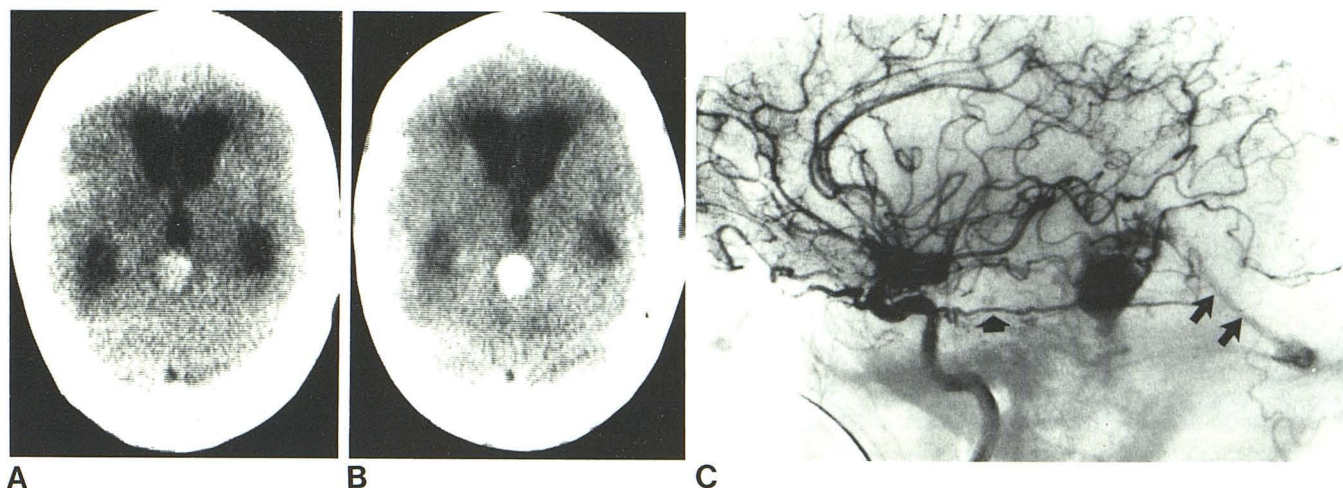


Fig. 1.—A, High density lesion in region of posterior third ventricle. B, After contrast infusion. Area shows homogenous enhancement. C, Left carotid angiogram in lateral projection. Hypertrophied tentorial branch (short

arrow) of meningohipophyseal artery giving major blood supply to aneurysm. Early filling of straight sinus (long arrows).

of these findings was present in our case. Thus, the CT findings of an enhancing posterior third ventricular lesion with obstructive hydrocephalus could easily have been mistaken for a tumor such as a pinealoma.

The oldest patient previously reported in the literature was a 52-year-old man who had become symptomatic 2 years before diagnosis [5]. Because of the rarity of these lesions in the older population, vein of Galen aneurysms are not usually considered in the differential diagnosis of enhancing posterior third ventricular lesions on CT [9, 10]. Except for the compelling clinical findings of subarachnoid hemorrhage in our case, a diagnosis of pineal-related tumor such as a germinoma could have been presumed, leading to improper therapy. Therefore, we believe that angiography is valuable to characterize posterior third ventricular mass lesions before subjecting patients to radiation therapy or surgical management on the basis of CT findings alone.

A review of the literature indicates that most of these aneurysms derive their vascular supply from the posterior cerebral artery [5, 11, 12]. Other arteries reported to be supplying these malformations include the superior cerebellar, anterior choroidal, posterior choroidal, basilar, middle cerebral, anterior cerebral, and thalamoperforate arteries [11–13]. In our case, however, the predominant blood supply was from the tentorial branches of the meningohipophyseal artery with a minimal amount from the posterior choroidal arteries.

#### ACKNOWLEDGMENTS

We thank Deborah Jaeger and Kimberly McCracken for help in manuscript preparation.

#### REFERENCES

1. Jaeger JR, Forbes RP, Dandy WE. Bilateral congenital cerebral arteriovenous communication aneurysm. *Trans Am Neurol Assoc* 1937;63:173–176
2. Copty M, Bedard F, Turcotte JF. Successful removal of an entirely calcified aneurysm of the vein of Galen. *Surg Neurol* 1980;14:396–400
3. Litvak J, Yahr MD, Ransohoff J. Aneurysms of the great vein of Galen and midline cerebral arteriovenous anomalies. *J Neurosurg* 1960;17:945–954
4. O'Brien MS, Schechter MM. Arteriovenous malformations involving the galenic system. *AJR* 1970;110:50–55
5. Gold AP, Ransohoff J, Carter S. Vein of Galen malformation. *Acta Neurol Scand* 1964;40:4–31
6. Macpherson P, Teasdale GM, Lindsay KW. Computed tomography in diagnosis and management of aneurysm of the vein of Galen. *J Neurol Neurosurg Psychiatry* 1979;42:786–789
7. Spallone A. Computed tomography in aneurysms of the vein of Galen. *J Comput Assist Tomogr* 1979;3:779–782
8. Bannister CM, Weller J. Pre- and postoperative CT scans of an infant with an aneurysm of the vein of Galen—a case report. *Neurochirurgia (Stuttg)* 1980;23:17–20
9. Zimmerman RA, Bilaniuk LT, Wood JH, Bruce DA, Schut L. Computed tomography of pineal, parapineal and histologically related tumors. *Radiology* 1980;137:669–677
10. Futrell NN, Osborn AG, Cheson BD. Pineal region tumors: computed tomographic-pathologic spectrum. *AJNR* 1981;2:415–420
11. Amacher AL, Shillito J Jr. The syndromes and surgical treatment of aneurysms of the great vein of Galen. *J Neurosurg* 1973;39:89–98
12. Russel W, Newton TH. Aneurysm of the vein of Galen. *AJR* 1964;92:756–760
13. Martelli A, Scotti G, Harwood-Nash DC, Fitz CR, Chuang SH. Aneurysms of the vein of Galen in children: CT and angiographic correlations. *Neuroradiology* 1980;20:123–133