



## Get Clarity On Generics

Cost-Effective CT & MRI Contrast Agents



FRESENIUS  
KABI

WATCH VIDEO

# AJNR

## Identification of Meckel cave during percutaneous glycerol rhizotomy for tic douloureux.

L D Lunsford

*AJNR Am J Neuroradiol* 1982, 3 (6) 680-682  
<http://www.ajnr.org/content/3/6/680.citation>

This information is current as  
of August 21, 2025.

# Identification of Meckel Cave during Percutaneous Glycerol Rhizotomy for Tic Douloureux

L. Dade Lunsford<sup>1</sup>

A new percutaneous treatment of tic douloureux has been developed. Transovale injection of glycerol into the retrogasserian trigeminal fibers in Meckel cave results in complete pain relief in 77%–89% of patients [1–3]. The major advantages of percutaneous retrogasserian glycerol rhizotomy include simplicity, radiographic confirmation of accurate needle placement, and a much reduced incidence of postoperative facial sensory loss. The technique is dependent upon proper intraoperative recognition of the trigeminal cistern for placement of the glycerol, which is identified in postoperative radiographs by tantalum dust mixed with the glycerol as a permanent marker of Meckel cave.

## Technique

Percutaneous retrogasserian rhizotomy is performed with the patient awake after light premedication that includes an anxiolytic and an anticholinergic to reduce possible vagal symptoms. The patient rests on any x-ray or operating room table that can be brought from the supine to the semi-sitting position during the procedure. A C-arm fluoroscopic image intensifier equipped with video storage capacity is positioned in the anteroposterior (AP) skull projection. The submentovertex view is not used since neck hyperextension is often difficult for elderly patients, and since the foramen ovale is usually identifiable in the frontal projection.

After local xylocaine skin infiltration, a 20 gauge (9 cm) standard spinal needle is inserted through the cheek at a point 2.5 cm from the corner of the mouth. The needle is directed to a point 2.5 cm anterior to the external auditory canal (patient's AP coordinate and superoinferior coordinate) at the medial aspect of the ipsilateral pupil (Hartel technique). Deep injection of 1 ml xylocaine just anterior to the foramen ovale reduces pain associated with needle penetration of the cistern. After fluoroscopy confirms appropriate needle position, the stylet is removed to observe for flow of cerebrospinal fluid (CSF). When properly placed in the preganglionic fibers, the needle hub frequently will rest near the skin of the cheek. CSF flow is variable from only several drops to brisk escape. Prior destructive procedures of the preganglionic fibers may reduce flow of CSF.

The patient is brought to the semi-sitting position with the neck slightly flexed. Using a 1 ml syringe, 0.1–0.5 ml of metrizamide 300 mg I/ml is injected under fluoroscopic control. The preganglionic fibers can be seen on AP and lateral projections (fig. 1). Subdural injection requires advancement of the needle or placement of a second needle. Layering of metrizamide beneath the temporal lobe indicates too medial needle placement or postsurgical deformity after prior subtemporal procedures. Poor radiographic delineation of the trigeminal cistern precludes further attempts at glycerol injection unless the needle can be redirected to obtain typical cisternal features.

The cistern size is estimated by noting the volume of metrizamide injected just before escape of the contrast material from Meckel cave into the posterior fossa. The cistern size varies from 0.15 to 0.5 ml [3]. The metrizamide is evacuated by allowing the contrast material to flow out of the needle. Placing the patient in the Trendelenburg position with the neck extended allows any residual contrast material to escape from Meckel cave into the posterior fossa. After this maneuver, the patient is returned to the semi-sitting position.

Two ml of sterile undiluted anhydrous glycerol is mixed with about 2 ml of sterile tantalum dust for radiopacity. The tantalum allows intra- and postoperative confirmation of proper placement of the glycerol. The volume injected depends on the affected trigeminal divisions and the cisternal volume. Maxillary and mandibular division pain are treated satisfactorily with 0.15–0.25 ml in most cases. Ophthalmic division fibers can be treated selectively by allowing a small residual layer of metrizamide to remain in the bottom of the cistern. The glycerol then is "floated" on top of the contrast material, which is heavier in concentration than glycerol, which is in turn heavier than CSF. After injection of the desired volume, the needle is removed. The patient is transferred sitting to the hospital bed and remains sitting up for a period of 2 hr to prevent immediate escape of the glycerol into the posterior fossa. During the first postoperative day, skull radiographs are obtained to confirm proper localization (fig. 2). The patient usually is discharged on postoperative day 2. Pain relief occurs up to 10 days postoperatively, with a median latency until pain relief of 5 days [3].

Received April 5, 1982; accepted after revision July 8, 1982.

<sup>1</sup> Department of Neurological Surgery, 9402 Presbyterian-University Hospital, University of Pittsburgh, 230 Lothrop St., Pittsburgh, PA 15213.

*AJNR* 3:680–682, November/December 1982 0195–6108/82/0306–0680 \$00.00 © American Roentgen Ray Society



Fig. 1.—Lateral (A) and AP (B) films of Meckel cave after transovale placement of 20 gauge spinal needle into trigeminal cistern and injection of 0.25 ml of metrizamide 300 mg I/ml. Filamentous filling defects of preganglionic trigeminal fibers (*short arrows*) and position of gasserian ganglion (*long arrow*).

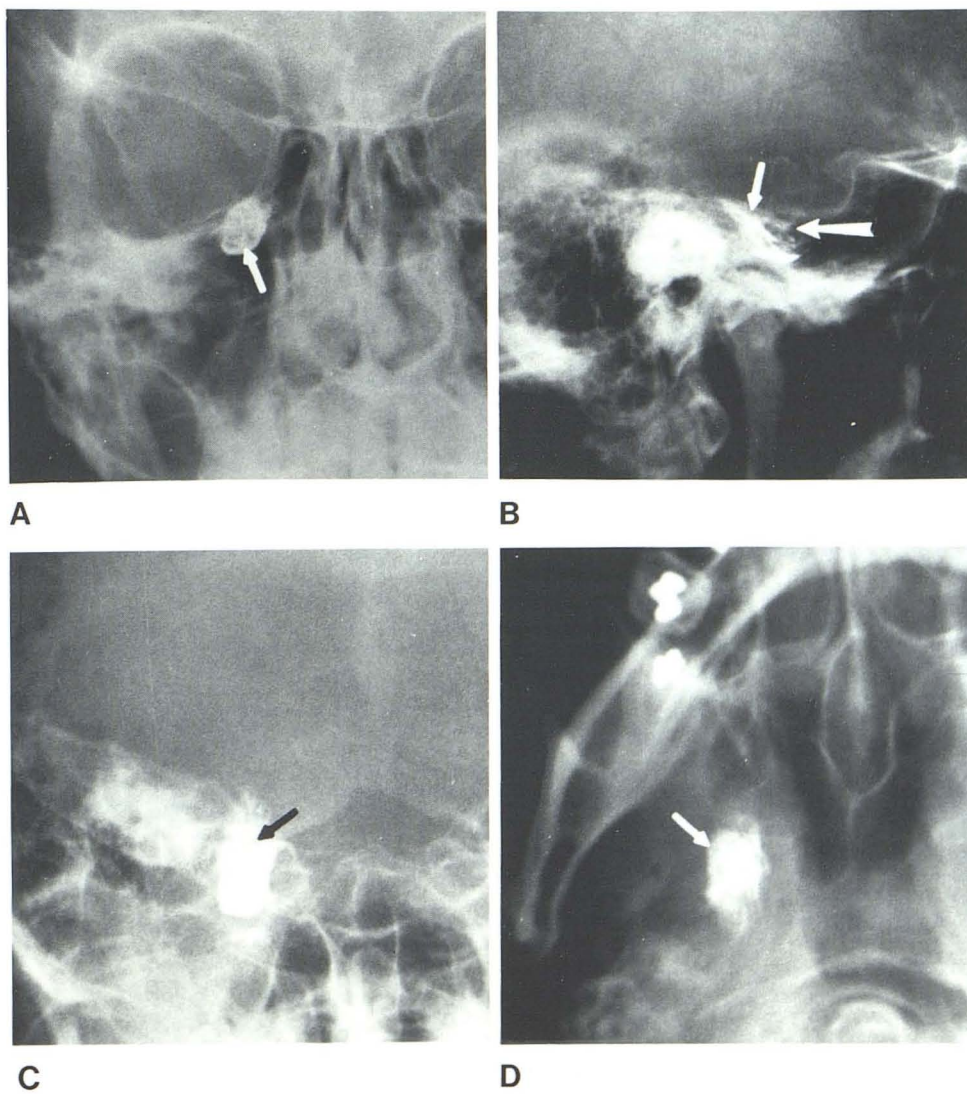
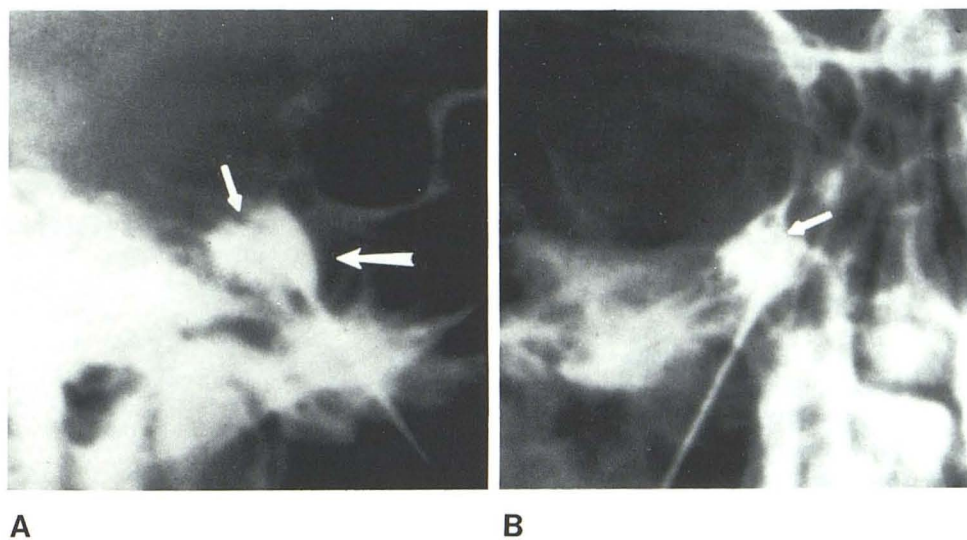


Fig. 2.—Location of Meckel cave and preganglionic trigeminal nerve in posteroanterior (A), lateral (B), Towne (C), and submentovertex (D) projections 24 hr after injection of 0.25 ml sterile anhydrous glycerol mixed with tantalum dust for treatment of right-sided trigeminal neuralgia. Preganglionic fibers identified in all projections (*short arrows*). Gasserian ganglion (*long arrow*) best seen in B.



## Discussion

Relief of trigeminal neuralgia after percutaneous retrogasserian rhizotomy requires precise localization of the trigeminal cistern in Meckel cave. Both subdural and infratemporal needle placement must be avoided [4, 5]. Trigeminal cisternography with metrizamide is mandatory to verify intracisternal placement and to demonstrate the cistern volume before glycerol injection. Transovale cisternography has been advocated to study the anatomy of the skull base and to assess tumors in Meckel cave or the cerebellopontine angle [6-9].

Meckel cave has been defined as a space between two layers of the dura mater at the tip of the petrous part of the temporal bone [10]. Within Meckel cave lie the gasserian ganglion and preganglionic trigeminal nerve. The subarachnoid space, in direct continuity with the pontine cistern, extends over the crest of the temporal bone to envelop the rootlets of the trigeminal nerve [9, 10]. The rostral gasserian ganglion is so densely covered by dura that a pia-arachnoid investment cannot be definitely demonstrated [10]. The dural coverings of Meckel cave are derived from both the posterior and middle cranial fossae, and may contain dural venous sinuses that directly communicate with the sphenoidal, petrosal, or cavernous sinuses [8]. The trigeminal preganglionic fibers are arranged in the cistern such that the ophthalmic division fibers are most superior and medial, while mandibular fibers are most inferior and lateral.

During cisternography, the trigeminal cistern is easily located on the lateral radiograph just below the floor of the sella turcica and anterior or overlapping the clivus [9]. When the needle tip is at the level of the clivus, ophthalmic division fibers will be encountered. The radiographic appearance of the trigeminal cistern is variable, although often ovoid. The gasserian ganglion and preganglionic fibers can be identified. The AP projection demonstrates the cistern at the junction of the medial and inferior orbital rims. Preganglionic fibers can be seen as small filling defects in the contrast medium.

Prior surgical procedures, including subtemporal section and percutaneous radiofrequency rhizotomy, frequently distort the cistern and may preclude successful glycerol injection. Glycerol should not be injected unless the configuration and size of the cistern can first be assessed by cisternography.

The mechanism of relief remains unknown, although both neurotoxic and osmotic effects have been proposed [2]. Between 30% and 60% of patients develop some postoperative facial sensory loss, although always of the mildest degree. In contrast to radiofrequency rhizotomy of the trigeminal nerve, pain relief after percutaneous retrogasserian

rhizotomy is not related to postoperative sensory loss, nor is relief dependent on the addition of the tantalum [1].

The addition of the tantalum dust to glycerol allows a permanent radiographic record of the procedure, permits fine assessment of the anatomy of Meckel cave, and provides a target point for future transovale needle placement should a recurrence of tic douloureux develop. No long-term complications have been associated with the use of tantalum dust in an initial series of 50 patients with tic douloureux treated with this technique. Two patients early in the series developed transient aseptic meningitis that rapidly resolved after administration of intravenous methyl prednisolone [3]. This complication has been avoided in more than 40 subsequent procedures by steam-autoclaving the tantalum rather than sterilization by ethylene oxide gas.

## ACKNOWLEDGMENT

This technique was demonstrated by Sten Håkanson, Karolinska Hospital, Stockholm, Sweden.

## REFERENCES

1. Håkanson S. Trigeminal neuralgia treated by the injection of glycerol into the trigeminal cistern. *Neurosurgery* **1981**; 9:638-646
2. Sweet WH, Poletti LE, Macon JB. Treatment of trigeminal neuralgia and other facial pains by retrogasserian injection of glycerol. *Neurosurgery* **1981**;9:647-653
3. Lunsford LD. Treatment of tic douloureux by percutaneous retrogasserian glycerol injection. *JAMA* **1982**;248:449-453
4. Håkanson S. Transovale trigeminal cisternography. *Surg Neurol* **1978**;10:137-144
5. Håkanson S. Transovale trigeminal cisternography: a method for radiological examination of the trigeminal cistern using a water soluble contrast medium. *Acta Neurochir [Suppl] (Wien)* **1979**;28:323-325
6. Grepe A. Cisternography with the non-ionic water soluble contrast medium metrizamide. *Acta Radiol [Diagn] (Stockh)* **1975**;16:146-160
7. Jimenez AP, Lyonnet J, Silva F. A new diagnostic method by transovale cisternography. *Acta Radiol [Diagn] (Stockh)* **1966**;5:662-666
8. Henderson WR. The anatomy of the gasserian ganglion and the distribution of pain in relation to injections and operations for trigeminal neuralgia. *Ann R Coll Surg Engl* **1965**;37:346-373
9. Kaufman B, Bellon EM. The trigeminal nerve cistern. *Radiology* **1973**;108:597-602
10. Burr HS, Robinson GB. An anatomical study of the gasserian ganglion with particular reference to the nature and extent of Meckel's cave. *Anat Rec* **1925**;29:269-282