



## Get Clarity On Generics

Cost-Effective CT & MRI Contrast Agents

**FRESENIUS  
KABI**

[WATCH VIDEO](#)

# AJNR

This information is current as  
of August 17, 2025.

## **Brain Structural Variability due to Aging and Gender in Cognitively Healthy Elders: Results from the São Paulo Ageing and Health Study**

P.K. Curiati, J.H. Tamashiro, P. Squarzoni, F.L.S. Duran, L.C. Santos, M. Wajngarten, C.C. Leite, H. Vallada, P.R. Menezes, M. Scazufca, G.F. Busatto and T.C.T.F. Alves

*AJNR Am J Neuroradiol* 2009, 30 (10) 1850-1856

doi: <https://doi.org/10.3174/ajnr.A1727>

<http://www.ajnr.org/content/30/10/1850>

ORIGINAL  
RESEARCH

P.K. Curiati  
J.H. Tamashiro  
P. Squarzone  
F.L.S. Duran  
L.C. Santos  
M. Wajngarten  
C.C. Leite  
H. Vallada  
P.R. Menezes  
M. Sczufca  
G.F. Busatto  
T.C.T.F. Alves



# Brain Structural Variability due to Aging and Gender in Cognitively Healthy Elders: Results from the São Paulo Ageing and Health Study

**BACKGROUND AND PURPOSE:** Several morphometric MR imaging studies have investigated age- and sex-related cerebral volume changes in healthy human brains, most often by using samples spanning several decades of life and linear correlation methods. This study aimed to map the normal pattern of regional age-related volumetric reductions specifically in the elderly population.

**MATERIALS AND METHODS:** One hundred thirty-two eligible individuals (67–75 years of age) were selected from a community-based sample recruited for the São Paulo Ageing and Health (SPAH) study, and a cross-sectional MR imaging investigation was performed concurrently with the second SPAH wave. We used voxel-based morphometry (VBM) to conduct a voxelwise search for significant linear correlations between gray matter (GM) volumes and age. In addition, region-of-interest masks were used to investigate whether the relationship between regional GM (rGM) volumes and age would be best predicted by a nonlinear model.

**RESULTS:** VBM and region-of-interest analyses revealed selective foci of accelerated rGM loss exclusively in men, involving the temporal neocortex, prefrontal cortex, and medial temporal region. The only structure in which GM volumetric changes were best predicted by a nonlinear model was the left parahippocampal gyrus.

**CONCLUSIONS:** The variable patterns of age-related GM loss across separate neocortical and temporo limbic regions highlight the complexity of degenerative processes that affect the healthy human brain across the life span. The detection of age-related limbic GM decrease in men supports the view that atrophy in such regions should be seen as compatible with normal aging.

There is enormous variability in the way different areas of the brain react to aging, and patterns of selective age-related neuroanatomic changes may be explained on the basis of brain ontogeny and phylogeny,<sup>1</sup> because late-maturing brain structures would be more susceptible to age-related decline. Accordingly, MR imaging studies that measured brain volumes by using regions of interest placed on different brain portions have shown age-related volume decrements preferentially in associative neocortical regions (mainly involving the prefrontal cortex and temporal lobe).<sup>2,3</sup> More recently, MR imaging investigations have used automated voxel-based morphometry (VBM) methods that allow unbiased assessments of regional gray matter (rGM) changes associated with healthy aging across the entire brain; these studies have reported significant negative correlations between gray matter (GM) volumes and age in neocortical regions (indicating

greater GM loss than the overall degree of GM decrement in the brain), in contrast to findings of positive correlations in limbic and paralimbic structures (which would suggest that rGM volumes did not decrease in the same proportion as the overall degree of GM loss in the brain).<sup>4–8</sup>

Besides age, sex may also influence brain morphology, and several MR imaging studies have specifically investigated sex differences in the pattern of age-related volumetric brain changes.<sup>8–13</sup> Some of them have reported that men have greater age-related brain GM decline in the frontal and temporal lobes,<sup>12</sup> whereas women have a larger degree of rGM reduction in the hippocampus, parietal lobe,<sup>11</sup> and visual cortex.<sup>12</sup> It is of critical importance to clarify further whether there are significant sex differences in brain volumetric changes related to aging, given the differential incidence of neurodegenerative diseases in men and women.<sup>14</sup>

Most of the MR imaging studies cited above have investigated sex- and age-related cerebral volume changes either in relatively small groups of healthy elderly subjects or in larger samples across the entire lifespan.<sup>5,10,15</sup> The latter aspect limits the conclusions that can be drawn from these studies, given that brain-aging processes may not follow a regular pattern across different stages of the lifespan. Moreover, the inclusion of younger subjects in the samples studied makes it difficult to distinguish age-related volumetric changes associated with brain maturation from those involved in brain aging.<sup>16</sup>

In addition, most cross-sectional morphometric MR imaging studies of healthy aging to date were restricted to the investigation of linear relationships between age and rGM indices. However, it is possible that the relationship between age and the volumes of certain brain regions would be better explained by nonlinear models.<sup>2,5,17</sup> The presence of variable

Received April 17, 2009; accepted after revision May 13.

From the LIM-21-Neuroimaging in Psychiatry Laboratory, Psychiatry Department (P.K.C., J.H.T., P.S., F.L.S.D., L.C.S., H.V., G.F.B., T.C.T.F.A.), Division of Cardiogeriatrics, Heart Institute (M.W.), Radiology Department (C.C.L.), and LIM-23-Psychiatry Department (M.S.), Clinical Hospital, São Paulo University Medical School, São Paulo Brazil; Psychiatry Department (J.H.T., T.C.T.F.A.), ABC Regional Medical School, Santo André, Brazil; Preventive Medicine Department (P.R.M.), São Paulo University Medical School, Brazil; and Epidemiology Section (P.R.M., M.S.), University Hospital, São Paulo University, Brazil.

This work was supported by the Wellcome Trust, UK (GR066133MA); “Fundação Amparo a Pesquisa Estado São Paulo” (04/15336–5, 04/12694–8, 06/04405–1), Brazil; and Conselho Nacional de Desenvolvimento Científico e Tecnológico, Brazil, to M.S., P.R.M., and G.F.B.

Please address correspondence to Tânia C.T. Ferraz Alves, MD, Nuclear Medicine Center, Clinical Hospital, São Paulo University Medical School, Dr. Ovidio Pires Campos St s/n–3rd Floor, 05403–010, São Paulo, SP, Brazil; e-mail: tania\_alves@hotmail.com



Indicates open access to non-subscribers at [www.ajnr.org](http://www.ajnr.org)

DOI 10.3174/ajnr.A1727

nonlinear patterns of correlations between age and GM volumes across separate brain portions could partially explain discrepancies in the results of previous MR imaging studies of healthy aging and differences in the significant findings between neocortical and limbic/paralimbic regions when only linear models are applied. In support of the latter proposition, Kennedy et al<sup>3</sup> have recently investigated a large sample of healthy adult volunteers ( $n = 200$ ) from 18 to 81 years of age by using both VBM and manual region-of-interest-based volumetry. They reported significant inverse relationships between age and brain volumes by both methods and found that the use of VBM-derived information across voxels contained in specific anatomically defined region-of-interest masks confirmed the nonlinearity of patterns of age-related volume changes detected by manual volumetry.<sup>3</sup>

The primary purpose of this MR imaging study was to map an accurate profile of regional age-related volumetric reductions specifically during adult elderly life and to assess whether age-related volumetric reductions in separate brain structures occur in different degrees of severity and following distinct linear or nonlinear models. We predicted that there would be age- and sex-related GM loss in neocortical frontal and temporal regions and volume preservation in temporolimbic structures. Initially, we used the conventional VBM approach to conduct a voxelwise search for significant linear correlations between GM volumes and age. Subsequently, by using regional brain-volume estimates obtained with anatomically defined region-of-interest masks, we investigated whether the relationship between rGM volumes and age would be best predicted by linear or nonlinear models. We chose to focus our analysis on a narrow age range so that our findings would better fit the profile of brain aging in such a specific period of elderly life.

## Materials and Methods

### Subjects and Assessment Schedules

The study sample was selected from a community-based data base of elderly individuals recruited for the São Paulo Ageing and Health (SPAH) study,<sup>18,19</sup> an epidemiologic investigation aimed at determining the incidence and prevalence of dementia, other mental disorders, and risk factors for these conditions. Between 2003 and 2005, 2072 participants were selected, interviewed, and examined for the first wave of the SPAH study. Two years later, they were recontacted for a new assessment with the same clinical protocol (second SPAH wave). Identification of cases of dementia and other major psychiatric disorders followed the protocol developed by the 10/66 Dementia Research Group.<sup>20</sup> This protocol included the following instruments: the Community Screening Instrument for Dementia; an adapted version of the 10-word list of the Consortium to Establish a Registry for Alzheimer Disease (CERAD); the animal-naming verbal fluency task from the CERAD; the Geriatric Mental State; a structured neurologic assessment; and a structured cardiologic evaluation.

Our cross-sectional MR imaging investigation was performed concurrently with the second SPAH wave. The pool of possible participants was created after inspection of the epidemiologic data bank from the SPAH study so that we could ascertain the following exclusion criteria: incomplete 2-year clinical follow-up; active hypo- or hyperthyroidism; epilepsy; lung or liver diseases; major psychiatric disorders; <3 months of psychoactive drug abstinence; and personal

or first-degree family history of neurodegenerative disorders (including mild cognitive impairment). The criterion for cognitive impairment was defined as a performance in the cognitive battery of 1.5 SD below the mean performance obtained from all subjects between 65 and 75 years of age from the original SPAH sample. Data concerning age, blood pressure, diabetes mellitus, smoking, and cholesterol level were extracted to generate the Framingham Coronary Heart Disease Risk (FCHDR) index, a summary index of cardiovascular risk.<sup>21</sup> On the day of MR imaging, subjects were assessed with the Hamilton Depression Rating Scale and the global function assessment scale from *Diagnostic and Statistical Manual of Mental Disorders-IV*.

Educational data of each subject were extracted from the SPAH study data base. In brief, we considered 4 years of education if subjects completed the fourth grade, 8 years if subjects completed the eighth grade, 11 years if subjects completed high school, and 15 years if subjects completed college. When one of these educational periods was not completed, the number of years until dropout was considered in the estimate of mean years of education.

Following their order of entry in the SPAH study, we consecutively contacted potentially eligible subjects by telephone, invited them to take part in the MR imaging study, and checked for the presence of the following MR imaging contraindication: carrying of a cardiac pacemaker, valvular prosthesis, or other internal electrical/magnetic devices; history of neurosurgery or cerebral aneurysm; presence of metal fragments in the eyes, brain, or spinal cord; and claustrophobia. Only individuals who were  $\leq 75$  years of age at the time of recruiting were included in this MR imaging study (age range of 8 years, from 67 to 75 years). The MR imaging study received approval from the local Committee for Ethics and Research, and written consent was obtained from all subjects.

### Imaging Data Acquisition

MR imaging data were acquired by using a 1.5T Signa LX CVi scanner (GE Healthcare, Milwaukee, Wis). The acquisition protocol included the following: 1) a dual spin-echo sequence of 120 transaxial sections across the entire brain (axial Parkinson disease/T2) with a TR/TE of 2800/25 ms and a 5-mm section thickness; 2) a T2-weighted fast spin-echo transaxial sequence with 88 images, a TR/TE of 4200/12.5 ms, an echo-train length of 16, and a 5-mm section thickness; 3) a 3D gradient-echo (spoiled gradient-recalled acquisition [SPGR]) sequence of 124 sections with a TR/TE of 121 /4.2 ms, an FA of 20°, a 220-mm FOV, a 1.5-mm section thickness, NEX of 1, and a 256 × 192 matrix.

Datasets were readily reconstructed and visually checked by an experienced radiologist.

### MR Image Processing

VBM analyses were performed on the SPGR datasets by using Statistical Parametric Mapping software (SPM2; Wellcome Department of Imaging Neuroscience, London, UK), executed in Matlab Version 5.3 (MathWorks, Natick, Mass). We used optimized VBM protocols,<sup>4</sup> taking into account the structural characteristics of elderly brains. First, a standard template set was created specifically for the study, consisting of an average T1-weighted image and a priori GM, white matter (WM), and CSF templates based on the images of all subjects. To create these study-specific templates, we spatially normalized images to the standard SPM T1 MR imaging template on the basis of 152 healthy subjects from the Montreal Neurologic Institute (MNI).<sup>23</sup> This spatial normalization step was restricted to linear 12-parameter affine transformations to minimize deformations of our original images. Spatially normalized images were then segmented into GM,

**Table 1: Demographic and clinical characteristics of the sample**

	Overall Sample	Men ( <i>n</i> = 45)	Women ( <i>n</i> = 57)	<i>P</i>
Mean age ( $\pm$ SD)	70.17 ( $\pm$ 2.28)	70.07 ( $\pm$ 2.28)	70.24 ( $\pm$ 2.30)	.696*
Mean years of education ( $\pm$ SD)	4.65 ( $\pm$ 3.33)	5.23 ( $\pm$ 3.94)	4.16 ( $\pm$ 2.67)	.120*
Hamilton Depression Rating Scale ( $\pm$ SD)	3.92 ( $\pm$ 7.84)	2.87 ( $\pm$ 7.58)	4.75 ( $\pm$ 8.01)	.229*
Subjects with high coronary heart disease risk (%)†	19 (18.6)	13 (28.9)	6 (10.5)	.002‡

\* Student *t* test.

† Framingham Coronary Heart Disease Risk &gt;20%.

‡ Pearson  $\chi^2$  test.

WM, and CSF compartments with a modified mixture-model cluster-analysis technique.<sup>4</sup> Finally, images were smoothed with an isotropic gaussian kernel (8-mm full width at half maximum) and averaged to provide the GM, WM, and CSF templates in stereotactic space.

Subsequently, the processing of the original images from all subjects was performed, beginning with image segmentation with the study-specific a priori GM, WM, and CSF templates. Extracted GM and WM images were then spatially normalized to the customized GM and WM templates with 12-parameter linear and nonlinear (7\_9\_7 basis functions) transformations. The parameters resulting from this spatial normalization step were then reapplied to the original structural images. These fully normalized images were then resliced with trilinear interpolation to a final voxel size of 2\_2\_2 mm<sup>3</sup> and segmented into GM, WM, and CSF partitions. Voxel values were modulated by the Jacobian determinants derived from the spatial normalization. Finally, all images were smoothed with a 12-mm gaussian kernel.

### Statistical Analysis

VBM-based linear correlations between age and GM volumes were performed with the general linear model based on random gaussian field theory.<sup>24</sup> Only voxels with values above an absolute GM threshold of 0.05 entered the analyses. Resulting statistics at each voxel were transformed to *z*-scores and displayed as SPMs into standard space, at a threshold of *z* = 3.09. These analyses were conducted with covariance for the amount of GM in the brain and included the FCHDR index of each subject as a confounding variable. The strategy of including the global GM covariate, given by the total number of voxels within the GM compartment of each subject, led, on the analyses for negative correlations, to the identification of localized brain areas in which age-related GM losses were greater than the overall degree of GM decrement in the brain. Conversely, the statistical maps for positive correlations, covariates for total GM, indicated the localized brain regions in which GM volumes did not decrease in the same proportion as the overall degree of GM loss in the brain.

Each SPM was initially inspected in a hypothesis-driven fashion, searching for voxel clusters in brain regions in which volumetric changes had been predicted a priori (frontal and lateral temporal cortices) and in temporolimbic regions in which volumetric preservation was expected (hippocampus, parahippocampal gyrus, and amygdala). This hypothesis-driven analysis was conducted by using the small-volume correction method, with the purpose of constraining the total number of voxels included in the analysis. Each region was circumscribed by merging the spatially normalized region-of-interest masks,<sup>3</sup> which are available within the Anatomical Automatic Labeling SPM toolbox (Wellcome Department of Imaging Neuroscience). Seven region-of-interest masks were used in each hemisphere, involving, respectively, the dorsolateral frontal, dorsomedial frontal and orbitofrontal cortices; lateral temporal neocortex; amygdala; hippocampus; and parahippocampal gyrus. Any Pearson correlation

indices within those 14 regions of interest were reported as significant if surviving family-wise error (FWE) correction for multiple comparisons was *P* < .05. Subsequently, the SPM maps were inspected for volumetric changes in unpredicted regions across the entire brain. Such unpredicted findings were reported as significant only if they survived correction for multiple comparisons at a FWE-corrected *P* = .05 threshold (voxel level) over the whole brain.<sup>24</sup> In all analyses, we converted MNI coordinates of voxels of maximal statistical significance to the Talairach and Tournoux atlas.<sup>25</sup>

To investigate sex-specific differences in the pattern of age-related rGM loss, we repeated the above voxelwise calculations of linear correlation indices between GM and age (covariate for global GM and corrected for cardiovascular risk as assessed by using FCHDR scores) after dividing our sample by sex (men [*n* = 45] and women [*n* = 57]).

For the nonlinear regression analyses, mean rGM volumes of each subject were extracted with the use of the 14 above-mentioned region-of-interest masks<sup>3</sup> and entered into the Statistical Package for the Social Sciences, Version 10.0 software (SPSS, Chicago, Ill). A multiple regression analysis was performed with rGM volumes entered as dependent variables, age as an independent variable of interest, and total brain GM volume and FCHDR group as covariates. The goodness of fit of first- and second-order polynomial expansions was assessed, and results were reported only if at least 1 of the regression models achieved the significance level set at *P* < .05. Finally, a regression statistical analysis was also performed for the total cerebrum GM volume: Age was entered as an independent variable of interest and the FCHDR group was entered as a covariate. Regression analyses were performed initially for the overall sample (entering sex as a covariate) and then separately in the male and female subgroups.

### Results

The sample investigated in the current study included 132 consecutively recruited cognitively healthy elderly subjects (mean age, 70.36  $\pm$  2.38 years). The qualitative visual inspection of brain images led to the exclusion of a total of 26 subjects (19.70%) due to the presence of at least 1 silent infarct and 4 subjects (3.0%) due to artifacts during MR imaging. Thus the final study sample comprised a total of 102 cognitively healthy subjects (mean age, 70.17  $\pm$  2.28 years). A summary of their demographic and clinical characteristics is given in Table 1.

### Voxel-Based Analysis of the Effects of Age and Sex on rGM Volumes

Table 2 summarizes the significant clusters of relative age-related GM change detected by using VBM. Local areas of negative correlations in the overall sample, indicating accelerated GM-volume decrease, were observed in the right temporal neocortex, involving the middle and superior temporal gyri. We found no significant positive correlations indicating relative GM preservation in the overall sample.

**Table 2: Correlations between age and regional gray matter volumes**

Location	Sex	Brodmann Areas	P <sub>FWE</sub> Corrected*	Size of Cluster†	Peak Z-Score‡	Coordinates X, Y, Z§
Highest gray matter decrease as a function of age						
Right middle and superior temporal gyri	Overall sample	21, 22, 42	0.040	570	3.78	67, -9, 6
Right middle and superior temporal gyri	Men	21, 22, 42	0.015	349	4.11	69, -8, -6
Right dorsomedial frontal cortex	Men	10, 11	0.048	95	3.38	6, 68, -3
Right orbitofrontal cortex	Men	10, 11	0.038	99	3.72	26, 64, -10
Left orbitofrontal cortex	Men	10, 11	0.042	103	3.62	-6, 66, -10
Left parahippocampal gyrus	Men		0.042	34	3.22	-14, -1, -15
Right amygdala	Men		0.036	17	2.83	18, 1, -15
Left amygdala	Men		0.015	40	3.12	-14, -1, -13
Lowest gray matter decrease as a function of age						
Right dorsolateral frontal cortex	Men	6	0.031	154	3.74	24, 3, 55

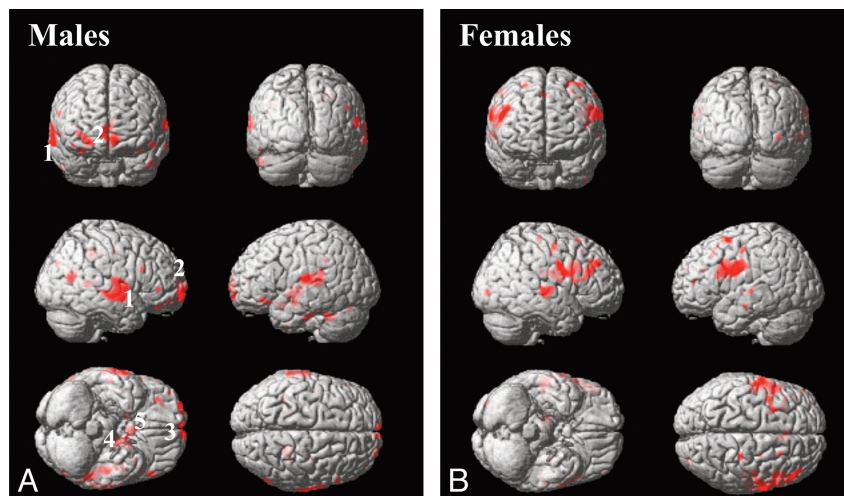
**Note:**—FWE indicates family-wise error.

\* Statistical significance after correction for multiple comparisons; inferences made at the level of individual voxels (FWE correction).

† Number of contiguous voxels that surpassed the initial threshold of  $P < 0.01$  (uncorrected) in the statistical parametric maps.

‡ Z-scores for the voxel of maximal statistical significance.

§ Talairach and Tournoux coordinates of the voxel of maximal statistical significance within each cluster.



**Fig 1.** Negative correlations between regional GM and age in male and female subgroups. Voxels that surpassed the initial threshold of  $P < .01$  in the statistical parametric maps are marked with the red scale and overlaid on reference 3D rendering images spatially normalized to the Talairach and Tournoux atlas. Numbers indicate the clusters that retain statistical significance at the  $P < .05$  threshold, corrected for multiple comparisons at the voxel level (FWE): right middle and superior temporal gyri (1), right dorsomedial frontal cortex (2), bilateral orbitofrontal cortex (3), left parahippocampal gyrus (4), and bilateral amygdala (5).

The voxelwise search for significant negative correlations between rGM volumes and age separately in men and women revealed differences in the patterns of GM reduction associated with aging in the 2 subgroups (Table 2 and Fig 1). In the female subgroup, there were no regions showing significant negative correlations between GM volumes and age. In the male subgroup, a focus of significant negative correlation between GM volume and age was detected in the right middle and superior temporal gyri, similar to the finding observed in the overall sample. The male subgroup had additional voxels displaying significant negative correlation with age in other brain areas that were not implicated in the analysis of the overall sample, namely the right dorsomedial frontal cortex, the orbitofrontal cortex bilaterally, the left parahippocampal gyrus, and the amygdala bilaterally.

Foci of significant positive correlations between GM volumes and age were not detected either in male or in female subgroups at the  $P_{FWE} \leq 0.05$  threshold. However, a trend toward relative GM preservation was found in a cluster of 160 voxels encompassing the right inferior and middle temporal gyri in women ( $P_{FWE} = 0.053$ ,  $P_{uncorrected} < 0.001$ ).

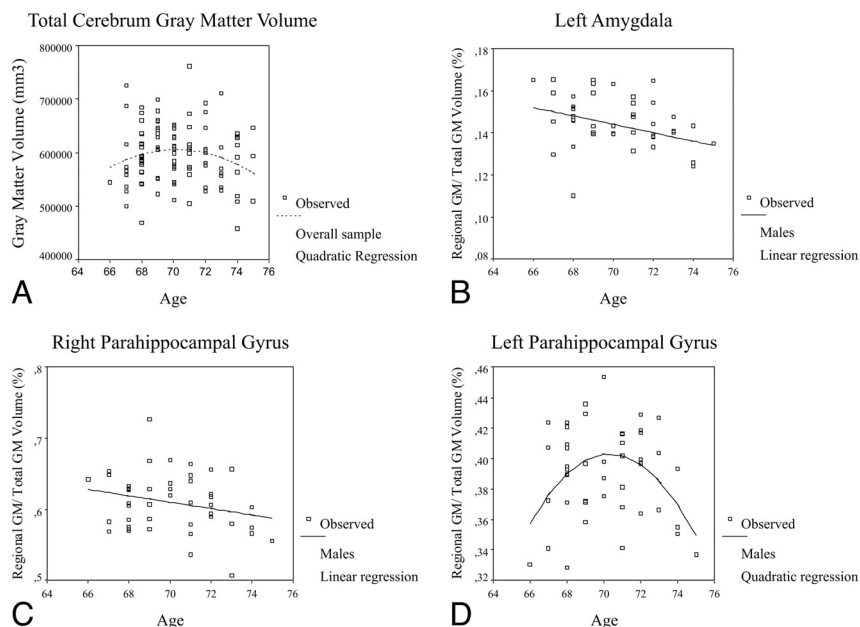
**Table 3: Best-fitting gray matter polynomial regression models by cerebral region**

Region of Interest	Sex	Best-Fitting Model	P	Adjusted R <sup>2</sup>
Left amygdala	Men	Linear	.047	0.213
Left parahippocampal gyrus	Men	Quadratic	.004	0.511
Right parahippocampal gyrus	Men	Linear	.025	0.484

### Multiple Regression Analysis

Results from the regression analyses of global GM and rGM volumes (as estimated by using region-of-interest masks) versus age are presented in Table 3 and Fig 2. In the overall sample ( $N = 102$ ), the rate of global GM decline was best fit by a quadratic model (adjusted  $R^2 = 0.243$ ,  $P = .043$ ), with relative GM preservation until the beginning of the eighth decade and accelerated volumetric loss from then onward. The rather low  $R^2$  value means that other variables are involved in the variability of these values. There were no significant findings of rGM interaction with age in the overall sample.

The results regarding best-fitting regression models for the



**Fig 2.** Plots of GM versus age (including best-fit regression lines). Male or female subgroups at the  $P < .05$  threshold are represented only in regions in which at least 1 regression model is significant for the overall sample.

separate male and female subgroups are also provided in Table 3 and Fig 2. The finding of a cubic profile of global GM volume changes did not retain statistical significance in the separate analysis. Regarding regional volumetric changes, there were significant findings for the temporolimbic regions of interest but not for neocortical regions. The left amygdala and the right parahippocampal gyrus presented a significant linear profile of brain aging in men, with accelerated GM decline. Also, a quadratic regression model, indicative of an increase in GM vulnerability to aging, was found in the left parahippocampal gyrus, with relative preservation until 70 years of age and accelerated GM loss from then onward. There were no significant findings for the female subgroup.

## Discussion

This cross-sectional morphometric MR imaging study investigated the relationship between aging and GM volumes in a relatively large sample of nondemented elderly subjects, testing both linear and nonlinear models. To the best of our knowledge, this study is the first of its kind to use a population-based design to recruit a relatively large number of individuals at this narrow age range from the same circumscribed geographic area.

### Age-Related rGM Volumes in Neocortical Regions

In agreement with our prediction, our VBM analysis showed, in the overall sample, foci of negative correlations between rGM volumes and age, located in the middle and superior temporal gyri. These findings confirm and extend previous results of significant negative correlations between age and measures of rGM volumes in neocortical regions.<sup>4,5,7</sup> The lateral temporal cortex is one of the neocortical portions most consistently found to display decreased GM in neuroimaging investigations of normal aging.<sup>2,3,6</sup> We provide herein evidence that this process continues at least until the eighth decade of life. In addition, age-related decreases in the dorsome-

dial frontal and orbitofrontal cortices were found in men. This is in agreement with the findings of several large morphometric MR imaging studies that reported age-related dorsal prefrontal and orbitofrontal volume decline in human samples spanning greater age ranges, including younger subjects.<sup>3,4,6,10</sup> The most likely explanation for the particular vulnerability of neocortical regions to age-related atrophy is their structural complexity and late maturation, as postulated by the evolutionary theory of Hughlings Jackson.<sup>1,26</sup>

Contrary to the VBM findings, the multiple regression analyses using region-of-interest masks revealed no significant findings involving the temporal neocortical and frontal regions. This is in agreement with recent data indicating that in morphometric MR imaging studies of healthy aging estimates based on peak values in VBM analyses may be more sensitive in uncovering age differences compared with region-of-interest-based measurements.<sup>3</sup>

### Age-Related GM Changes in the Medial Temporal Region

We also predicted a lack of relative age-related GM decrements in medial temporal structures on the basis of findings of significant GM preservation of temporolimbic regions with aging in previous VBM-based MR imaging studies that spanned large age ranges from childhood to elderly life.<sup>4-6</sup> However, there were no positive correlations indicating volume preservation in limbic structures during the seventh and eighth decades of life. Instead, our VBM analysis revealed increased vulnerability to age-related volumetric decline in the left parahippocampal gyrus and in the amygdala bilaterally in the subsample of cognitively healthy male elders. Moreover, the estimation of regional brain volumes from the VBM data using region-of-interest masks uncovered a pattern of age-related volumetric variability that was best fit by a quadratic model in the left parahippocampal gyrus in men, indicating an acceleration of GM decline from the beginning of the eighth decade onward in such temporolimbic regions.

The above results support the view that there is possibly an increase in the vulnerability of temporolimbic brain structures to age-related changes in advanced stages of elderly life (most evidently in male subjects), and atrophy of such regions should be seen as compatible with normal brain aging.<sup>27</sup> rGM metabolic and volumetric decline in the hippocampus/parahippocampal gyrus is considered an important biomarker for the early detection of Alzheimer disease,<sup>28,29</sup> and it has been suggested that the presence of volumetric decline in limbic structures should be considered a sign of pathologic brain aging.<sup>28,29</sup>

However, recently published structural and functional imaging studies reported findings that are consistent with the results described herein,<sup>2,27,30</sup> and the paucity of previous morphometric MR imaging studies specifically evaluating cognitively healthy subjects in the age range assessed in our study<sup>7,27</sup> may have reinforced the concept of medial temporal atrophy as necessarily denoting pathologic changes of the aging brain. Findings of rGM volume and/or metabolic preservation in the hippocampal region in healthy aging are mainly found in studies evaluating samples spanning a large age range.<sup>4-6</sup> Therefore, within the narrow age range investigated in our study, there is evidence that the beginning of the eighth decade may be a key point when brain aging undergoes a transition from a profile of degeneration predominantly in the neocortex to a pattern of involvement of phylogenetic older brain structures in the medial temporal region.

#### **Sex Differences in rGM Volume Changes with Aging**

As predicted, the subdivision of our sample by sex resulted in specific VBM-based patterns of regional volume changes in men and women. This indicates that sex-specific brain changes with aging, previously detected at earlier stages of life,<sup>9-11,30</sup> are still present during the seventh and eighth decades of life. Our observations reinforce the view that findings of age-related GM changes from previous neuroimaging studies of brain aging in samples mixing male and female subjects may be related to sex-specific patterns of age-related volumetric changes.

As to our VBM-based significant negative correlations involving neocortical areas, the separate analyses of male and female subgroups revealed that the findings of GM affecting the temporal neocortex detected in the overall sample were due to volumetric changes specifically in men. Conversely, sex-specific foci of rGM preservation were found in the temporal neocortex in females, involving the inferior and middle gyri. The latter findings are consistent with the results obtained recently by Fujimoto et al,<sup>30</sup> who reported a significant metabolic decrease in temporal lobe regions in men in contrast to age-related linear increases in women from the third until the fifth decades of adult life. Finally, accelerated GM decline in the dorsomedial frontal and orbitofrontal cortices appeared as a specific pattern of the male subgroup in the present study. The latter findings are consistent with a recently published study by Cowell et al,<sup>10</sup> which found age-related volume decrements in orbitofrontal regions selectively in men between the third and the eighth decades of life. Our results highlight the fact that sex differences in patterns of prefrontal cortical GM decline due to aging are more often recognized in

studies of samples with narrow age ranges<sup>10-12</sup> than in studies focused on the entire lifespan.

According to a variety of studies, sex hormones may play a role in the emergence and maintenance of limbic and neocortical structure and patterns of neurocognitive activation in women.<sup>31,32</sup> Our findings suggest that in elderly women, the rate of rGM atrophy does not differ significantly from the overall GM change, thus leading to a lack of significant findings of accelerated regional brain atrophy in specific regions after correction for global GM changes. Therefore, some of the results of our study might be interpreted in the context of a differential influence of these hormones on GM volumes in men and women up to the later stages of the lifespan, with progressively lesser protective effects after menopause, possibly leading to more accelerated GM loss in the very old brain. Conversely, given the lack of hormonal protective effects in men, their age-related global GM decrements would take place more continuously and in a linear fashion through the lifespan.<sup>32</sup> This would help to explain why the profile of accelerated GM loss in the temporolimbic cortex emerged exclusively in men in our study.

#### **Methodologic Considerations**

A potential factor that could have influenced the results of our study was the inclusion of subjects with conditions that may affect brain volumes through vascular changes such as hypertension and diabetes.<sup>33</sup> However, because we aimed to investigate brain volumetric changes in a representative sample of cognitively healthy elders, the exclusion of subjects with such prevalent chronic diseases would lead to results that might not reflect the reality of the overall elderly population. To control for the effects of these diseases in our findings, we accounted for their influence both in the VBM and region-of-interest analyses by covarying results to FCHDR scores. Therefore, our results are likely to truly represent normal neuroanatomic variations rather than being secondary to cerebrovascular pathology.

One limitation of our study is the use of a cross-sectional design, whereby correlations between GM and age at single time points across a sample of subjects of different ages are used to make inferences about how aging affects brain structure. The approach of limiting the age span in our study minimized the possible bias seen in other cross-sectional investigations, but it also made our statistical analysis less sensitive to brain volumetric changes in the period studied. Therefore, replication of our findings is warranted in longitudinal studies, with serial MR imaging measurements acquired with time in the same subject samples.

#### **Conclusions**

This cross-sectional population-based VBM study provided evidence that, within a narrow age range of healthy elderly life, patterns of age-related GM loss are variable across separate neocortical and temporolimbic brain regions, in a distinct manner from earlier stages of life and under considerable influence of sex differences. Although female subjects displayed a more homogeneous pattern of GM change, there were more selective foci of accelerated GM loss in men, involving the temporal neocortex, the prefrontal cortex, and the medial temporal region. Such patterns of age-related GM changes

confirm and extend findings obtained in previous MR imaging studies conducted in high-income countries. The detection of such specific profiles highlights the complexity of the degenerative processes that affect the human brain across the life span and provides a framework that may contribute to a greater understanding of the neuropathologic features associated with degenerative disorders.

## Acknowledgments

We thank Paulo Andrade Lotufo for assistance in the development of this project and Guilherme Abdo for the assistance in collecting MR images.

## References

1. York GK, Steinberg DA. **Hughlings Jackson's theory of recovery.** *Neurology* 1995;45:834–38
2. Allen JS, Bruss J, Brown CK, et al. **Normal neuroanatomical variation due to age: the major lobes and a parcellation of the temporal region.** *Neurobiol Aging* 2005;26:1245–60, discussion 79–82
3. Kennedy KM, Erickson KI, Rodrigue KM, et al. **Age-related differences in regional brain volumes: a comparison of optimized voxel-based morphometry to manual volumetry.** *Neurobiol Aging* 2009;30:1657–76. Epub 2008 Feb 13
4. Good CD, Johnsrude IS, Ashburner J, et al. **A voxel-based morphometric study of ageing in 465 normal adult human brains.** *Neuroimage* 2001;14(1 Pt 1):21–36
5. Grieve SM, Clark CR, Williams LM, et al. **Preservation of limbic and paralimbic structures in aging.** *Hum Brain Mapp* 2005;25:391–401
6. Kalpouzos G, Chetelat G, Baron JC, et al. **Voxel-based mapping of brain gray matter volume and glucose metabolism profiles in normal aging.** *Neurobiol Aging* 2009;30:112–24. Epub 2007 Jul 13
7. Lemaitre H, Crivello F, Grassiot B, et al. **Age- and sex-related effects on the neuroanatomy of healthy elderly.** *Neuroimage* 2005;26:900–11
8. Terribilli D, Schaufelberger MS, Duran FL, et al. **Age-related gray matter volume changes in the brain during non-elderly adulthood.** *Neurobiol Aging* 2009 Mar 10. [Epub ahead of print]
9. Carne RP, Vogrin S, Litewka L, et al. **Cerebral cortex: an MRI-based study of volume and variance with age and sex.** *J Clin Neurosci* 2006;13:60–72
10. Cowell PE, Sluming VA, Wilkinson ID, et al. **Effects of sex and age on regional prefrontal brain volume in two human cohorts.** *Eur J Neurosci* 2007;25:307–18
11. Murphy DG, DeCarli C, McIntosh AR, et al. **Sex differences in human brain morphometry and metabolism: an in vivo quantitative magnetic resonance imaging and positron emission tomography study on the effect of aging.** *Arch Gen Psychiatry* 1996;53:585–94
12. Raz N, Gunning-Dixon F, Head D, et al. **Aging, sexual dimorphism, and hemispheric asymmetry of the cerebral cortex: replicability of regional differences in volume.** *Neurobiol Aging* 2004;25:377–96
13. Xu J, Kobayashi S, Yamaguchi S, et al. **Gender effects on age-related changes in brain structure.** *AJNR Am J Neuroradiol* 2000;21:112–18
14. Nunnemann S, Wohlschlaeger AM, Ilg R, et al. **Accelerated aging of the putamen in men but not in women.** *Neurobiol Aging* 2009;30:147–51. Epub 2007 Jul 3
15. Benedetti B, Charil A, Rovaris M, et al. **Influence of aging on brain gray and white matter changes assessed by conventional, MT, and DT MRI.** *Neurology* 2006;66:535–39
16. Sowell ER, Thompson PM, Toga AW. **Mapping changes in the human cortex throughout the span of life.** *Neuroscientist* 2004;10:372–92
17. De Carli D, Garreffa G, Colonnese C, et al. **Identification of activated regions during a language task.** *Magn Reson Imaging* 2007;25:933–38. Epub 2007 May 23
18. Scazufca M, Menezes PR, Vallada HP, et al. **High prevalence of dementia among older adults from poor socioeconomic backgrounds in Sao Paulo, Brazil.** *Int Psychogeriatr* 2008;20:394–405
19. Scazufca M, Seabra CA. **Sao Paulo portraits: ageing in a large metropolis.** *Int J Epidemiol* 2008;37:721–23. Epub 2007 Jul 31
20. Prince M, Ferri CP, Acosta D, et al. **The protocols for the 10/66 dementia research group population-based research programme.** *BMC Public Health* 2007;7:165
21. Wilson PW, D'Agostino RB, Levy D, et al. **Prediction of coronary heart disease using risk factor categories.** *Circulation* 1998;97:1837–47
22. *Diagnostic and Statistical Manual of Mental Disorders* (4th edition). Washington, DC: American Psychiatric Association; 1994
23. Mazziotta JC, Toga AW, Evans A, et al. **A probabilistic atlas of the human brain: theory and rationale for its development—The International Consortium for Brain Mapping (ICBM).** *Neuroimage* 1995;2:89–101
24. Friston KJ, Holmes AP, Worsley KJ, et al. **Statistic parametric maps in functional imaging: a general linear approach.** *Hum Brain Mapp* 1994;2:189–210
25. Brett M, Johnsrude IS, Owen AM. **The problem of functional localization in the human brain.** *Nat Rev Neurosci* 2002;3:243–49
26. Ey H. **Hughlings Jackson's fundamental principles applied to psychiatry.** Riese H, ed. In: *Historical Explorations in Medicine and Psychiatry*. New York: Springer-Verlag; 1978:204–09
27. Xu Y, Valentino DJ, Scher AI, et al. **Age effects on hippocampal structural changes in old men: the HAAS.** *Neuroimage* 2008;40:1003–15. Epub 2007 Dec 27
28. Mosconi L, De Santi S, Li J, et al. **Hippocampal hypometabolism predicts cognitive decline from normal aging.** *Neurobiol Aging* 2008;29:676–92. Epub 2007 Jan 11
29. Smith CD, Chebrolu H, Wekstein DR, et al. **Age and gender effects on human brain anatomy: a voxel-based morphometric study in healthy elderly.** *Neurobiol Aging* 2007;28:1075–87
30. Fujimoto T, Matsumoto T, Fujita S, et al. **Changes in glucose metabolism due to aging and gender-related differences in the healthy human brain.** *Psychiatry Res* 2008;164:58–72. Epub 2008 Sep 19
31. Keenan PA, Ezzat WH, Ginsburg K, et al. **Prefrontal cortex as the site of estrogen's effect on cognition.** *Psychoneuroendocrinology* 2001;26:577–90
32. Lord C, Buss C, Lupien SJ, et al. **Hippocampal volumes are larger in postmenopausal women using estrogen therapy compared to past users, never users and men: a possible window of opportunity effect.** *Neurobiol Aging* 2008;29:95–101
33. Taki Y, Goto R, Evans A, et al. **Voxel-based morphometry of human brain with age and cerebrovascular risk factors.** *Neurobiol Aging* 2004;25:455–63