

Generic Contrast Agents

Our portfolio is growing to serve you better. Now you have a choice.



[VIEW CATALOG](#)

AJNR

The Effect of Exercise on the Cerebral Vasculature of Healthy Aged Subjects as Visualized by MR Angiography

E. Bullitt, F.N. Rahman, J.K. Smith, E. Kim, D. Zeng, L.M. Katz and B.L. Marks

This information is current as of May 7, 2025.

AJNR Am J Neuroradiol 2009, 30 (10) 1857-1863

doi: <https://doi.org/10.3174/ajnr.A1695>

<http://www.ajnr.org/content/30/10/1857>

ORIGINAL
RESEARCH

E. Bullitt
F.N. Rahman
J.K. Smith
E. Kim
D. Zeng
L.M. Katz
B.L. Marks



The Effect of Exercise on the Cerebral Vasculature of Healthy Aged Subjects as Visualized by MR Angiography

BACKGROUND AND PURPOSE: Prior studies suggest that aerobic exercise may reduce both the brain atrophy and the decline in fractional anisotropy observed with advancing age. It is reasonable to hypothesize that exercise-induced changes to the vasculature may underlie these anatomic differences. The purpose of this blinded study was to compare high-activity and low-activity healthy elderly volunteers for differences in the cerebrovasculature as calculated from vessels extracted from non-invasive MR angiograms (MRAs).

MATERIALS AND METHODS: Fourteen healthy elderly subjects underwent MRA. Seven subjects reported a high level of aerobic activity (64 ± 5 years of age; 5 men, 2 women) and 7, a low activity level (68 ± 6 years of age; 5 women, 2 men). Following vessel segmentation from MRA by an individual blinded to subject activity level, quantitative measures of vessel number, radius, and tortuosity were calculated and histogram analysis of vessel number and radius was performed.

RESULTS: Aerobically active subjects exhibited statistically significant reductions in vessel tortuosity and an increased number of small vessels compared with less active subjects.

CONCLUSIONS: Aerobic activity in elderly subjects is associated with lower vessel tortuosity values and an increase in the number of small-caliber vessels. It is possible that an aerobic exercise program may contribute to healthy brain aging. MRA offers a noninvasive approach to visualizing the cerebral vasculature and may prove useful in future longitudinal investigations.

Aging of the human brain is known to be associated with a variety of anatomic changes, including progressive shrinkage of gray matter,¹⁻⁴ the development of lesions in white matter tracts,⁵ and a decline in fractional anisotropy as seen by MR imaging.^{6,7} Underlying microvascular disease may contribute to many of these changes.⁸⁻¹¹ Larger vessels may also be affected; indeed, a recent MR angiography (MRA) study reported that even the larger vessels perceptible by MRA exhibit a loss of vessel number and a mild increase in vessel tortuosity during healthy aging.¹² The variability in the magnitude of age-related change is large, however, and the brains of some elderly subjects have the characteristics of the brains of much younger individuals.¹³

Several intriguing reports suggest that aerobic exercise training, which is likely to improve cardiovascular status, may reduce structural alterations of the brain normally associated with advanced age.¹⁴⁻¹⁶ Because aerobic exercise is likely to improve cardiovascular status, it is reasonable to hypothesize that the protective effects of aerobic exercise may act via an underlying effect on the cerebral vasculature.

The purpose of the current study was to compare quantitative measures of vessel number, radius, and tortuosity as defined from MRA images of healthy volunteers 60–74 years of age, each of whom self-reported aerobic exercise activity levels as high or low. Because a previous MRA study had associated normal aging with vessel loss and a mild increase in vessel tortuosity,¹² our hypothesis in the current study was that patients with high aerobic activity levels would exhibit a “younger appearing brain” as demonstrated by a larger vessel number and a lower vessel tortuosity value than patients with low-activity levels. Our findings suggest that aerobic activity appears to be associated with a “younger appearing brain” but that further research by using longitudinal studies is required to assess fully the effects of aerobic exercise on the brains of individual subjects imaged during a certain period of time.

Materials and Methods

This Health Insurance Portability and Accountability Act–compliant study was approved by the institutional review board of the University of North Carolina, Chapel Hill. The study was blinded, with patients recruited, examined, and given an activity level classification by clinicians (B.L.M., L.M.K.), data analysis performed on patients’ images by an investigator blinded to patient-activity classification (E.B.), and statistical analysis performed by an independent third group (E.K. and D.Z.). A secondary image processing and statistical analysis were performed at a later time by a fourth group (F.N.R. and J.K.S.), who examined the number of small-diameter vessels in high- and low-activity subjects.

Subject Selection

Healthy volunteers 60–80 years of age were recruited via an advertising campaign and screened by telephone interview, cognitive status questionnaires, and physical examination. Subjects were initially excluded from study via a 20-minute telephone interview for diseases

Received February 23, 2009; accepted after revision April 29.

From the Departments of Surgery (E.B.), Radiology (F.N.R., J.K.S.), Biostatistics (E.K., D.Z.), Emergency Medicine (L.M.K.), and Sports Medicine (B.L.M.), University of North Carolina at Chapel Hill, Chapel Hill, NC.

This work was supported by grant NIH-NIBIB R01EB000219 (E.B.) and a seed grant from the Biomedical Research Imaging Center, University of North Carolina at Chapel Hill (B.L.M.).

Previously presented in part at: Annual Meeting of the Radiological Society of North America, November 30–December 5, 2008; Chicago, Ill.

Please address correspondence to Elizabeth Bullitt, MD, Department of Surgery, CASILab, CB#7062, University of North Carolina at Chapel Hill, Chapel Hill, NC 27599; e-mail: bullitt@med.unc.edu



Indicates open access to non-subscribers at www.ajnr.org

DOI 10.3174/ajnr.A1695

such as diabetes or hypertension; myocardial infarction; transient ischemic attacks; claudication; depression; neurologic deficits; a history of neurologic disease and orthopedic or other conditions that would preclude exercise testing; or any condition, such as implanted metal, that would preclude MR imaging. The remaining subjects were then required to fall within the normal range of the Beck Depression Inventory¹⁷ and the Telephone Interview for Cognitive Status,¹⁸ with a trained physician administering each test. The remaining subjects underwent a full physical examination and, if approved, a monitored maximal graded exercise stress test on a treadmill. No subject required exclusion because of cardiopulmonary disease on physical examination or for development of claudication, chest pain, electrocardiographic changes, or other evidence of vascular disease during the stress test.

A total of 120 subjects were initially screened. Nineteen percent of the initial group was excluded for a history of cardiopulmonary-metabolic disorders; 12%, for head, neck, balance, and cognition disorders; 11%, for contraindication to MR imaging; 6%, for orthopedic limitations precluding them from participating in the treadmill stress test; and 36%, for "other reasons," including inappropriate age range or reluctance to spend the time or answer questions. An additional 4% were unable to tolerate MR imaging. A total of 14 subjects remained for analysis (12%).

It was impossible to screen for all potential variables during this type of pilot study. Within the limits of feasibility, however, the aim was to recruit as homogeneous a patient population as possible. In addition to the physical and psychological screening procedures described above, all subjects were college-educated, all were of upper or upper middle economic level, all reported themselves to be culturally/socially active, all stated that they attempted to solve puzzles regularly (eg, newspaper puzzles), all took vitamin supplements regularly, and all women reported themselves as postmenopausal.

Activity Screening

Subjects were assigned an activity status (high or low) during the initial telephone interview based on self-report of physical activity during the past 10 years. Subjects were again queried about activity levels during the first laboratory appointment and yet again during physical examination. Finally, their reports were compared with a standardized published physical activity rating scale with a range of 0–7.¹⁹

The historically active group ("high activity group") was defined as participating in an aerobic sport/activity regularly for a minimum of 180 minutes per week for the past 10 consecutive years. Aerobic activities included sports such as tennis, swimming, running, biking, triathlons, marathons, soccer, walking, hiking, and basketball games. Other sports were allowable if they met the duration and frequency study requirements (eg, 60-minute sessions 3 days per week or 30-minute sessions 6 days per week) and met the classic definition of "aerobic" (continuous rhythmic movement of 75% of one's body with elevation of the heart rate to approximately 70% of its maximum or a perceived exertion level of at least "moderate"²⁰). The low-activity group was defined as having had no regular physical activity or exercise program for the past 10 consecutive years and as participating in any physical activity <90 minutes per week.

Classification was difficult for only 1 subject. This man was initially assigned to the low-activity group on the basis of his telephone interview. During personal screening, however, he indicated that he walked 4 miles each weekday and climbed mountains every weekend. He was, therefore, reclassified into the high-activity group. On subse-

quent visits, however, he provided equivocal information about his activity level. The clinicians decided to exclude him from study and to attempt to recruit a replacement, but because no further eligible subject was found, he remained on the study.

Of the final 14 patients, 7 were identified as "high" and 7 as "low" activity. Mean and SD were 64 ± 5 years of age in the high-activity group (5 men, 2 women) and 68 ± 6 years in the low-activity group (5 women, 2 men). All high-activity group members had ratings of 6–7 on the physical activity rating scale,¹⁹ and all low-activity group members had ratings of ≤ 4 .

MR Imaging

Images were obtained on a 3T head-only unit, (MAGNETOM Allegra; Siemens, Erlangen, Germany) by using a Siemens CP Tx/Rx head coil. MRA images were acquired by using a 3D time-of-flight sequence without gadolinium injection that covered the entire head by using multiple⁸ overlapping (25%) thin-slab acquisition (MOTSA) and with interpolation on. The sequence also used a magnetization-transfer pulse for background suppression of white matter. The resulting voxel size was $0.5 \times 0.5 \times 0.5$ mm³. The sequence used TR = 27 ms, TE = 3.89 ms, and flip angle = 22°. Image-acquisition time was approximately 15 minutes.

Image Processing

Images were transferred to a computer for processing. It took approximately an hour to analyze each case. The vessel segmentation and analysis programs were C++ programs written by our group and have been previously detailed in the literature. Vessel segmentation was performed from MRA images by using a Hessian-based method that, proceeding from a seed point, defined an image-intensity ridge representing the vessel skeleton and then automatically defined a radius at each skeleton point.²¹ Each segmented vessel represented an individual unbranched structure composed of multiple ordered equally spaced 4D vessel points. Each vessel point comprised the 3 floating-point x, y, z spatial coordinates of the position of the skeleton and the associated radius at that position. The set of individual disconnected segmented vessels was then processed by a second program that, proceeding from user-defined roots, created connected vessel trees.²² To standardize the vessel groups analyzed across patients, we manually defined vessel branch points that could be clearly identified in all subjects. These branch points included the A1 segment, the M1 segment, and the basilar artery proximal to the takeoff of the posterior cerebral arteries. Each image was processed according to these branch points so as to provide 4 anatomically distinct and connected sets of vessels comprising the anterior cerebral circulation (ACA), the posterior circulation, and the left (LMCA) and the right (RMCA) middle cerebral circulations (Fig 1).

Four vessel attributes were then calculated for each of the 4 anatomic regions and for the entire brain:

- 1) **Vessel Number.** The number of individual unbranched vessels.
- 2) **Average Vessel Radius.** The sum of radii at all vessel points divided by the number of vessel points with results in millimeters. Because MRA assesses moving flow, it evaluates only blood flow through the vessel lumen. Vessel wall thickness was thus not depicted or assessed in this study. The vessel-segmentation program requires an initial estimate of scale that is used both to blur the image and to weight vessel-radius calculations from noisy images. The scale used throughout this study was 1 mm. As a result, small vessels <1 mm in diameter (<0.5 mm radius) tended to be reported as having slightly larger radii than indicated by the image-intensity data and vessels >1

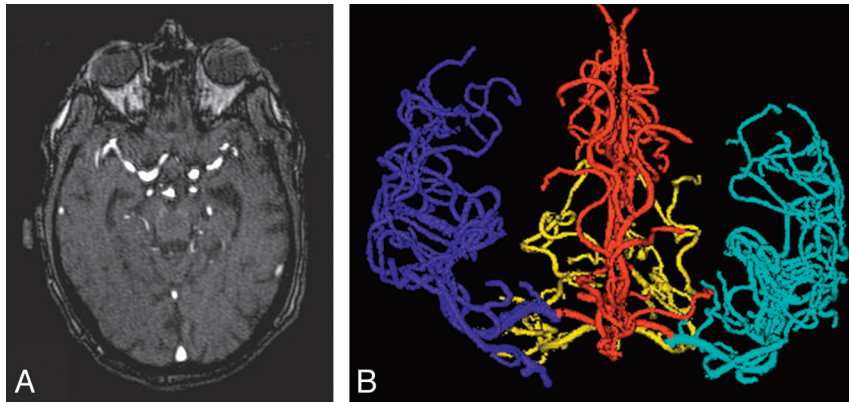


Fig 1. A, Axial section of an MRA image. B, Anteroposterior view of a 3D vessel model generated from MRA. Cyan indicates the left middle cerebral circulation; red, the anterior cerebral distribution; blue, the right middle cerebral circulation; gold, the posterior circulation.




Fig 2. Illustration of abnormal tortuosity. A, Drawing of a healthy intracerebral vessel. The vessel is gently curved. B, Drawing of abnormal tortuosity by SOAM. There are irregular sharp high-frequency low-amplitude curves superimposed on the basic vessel shape. C, Drawing of abnormal tortuosity by ICM. The vessel has elongated and possesses marked C- or S-shaped curves. D, 3D rendering of abnormal SOAM and abnormal ICM values in the same vessel segmented from MRA in 2 different subjects. Left: Healthy vessel. Right: Vessel in a patient with cancer. The vessel possesses abnormal tortuosity by both SOAM and ICM.

mm in diameter tended to be reported as having somewhat smaller radii.

3) Vessel Tortuosity as Calculated by the “Sum of Angles Metric.” Sum of Angles Metric (SOAM) sums angles between consecutive trios of points along a regularly sampled space curve and normalizes by the total path length.²³ Space curves displaying low-frequency high-amplitude curves tend to display high SOAM values. SOAM values are almost invariably elevated in the presence of cancer²³; the other disease states with which it is associated are largely unknown. An advantage of SOAM is that the calculation is largely independent of the length of the vessel segment analyzed. The average SOAM value in radians/centimeter was calculated for each vessel group. Figure 2 illustrates abnormal SOAM tortuosity.

4) Vessel Tortuosity as Calculated by the “Inflection Count Metric.” The Inflection Count Metric (ICM) counts the number of inflection points along a space curve and multiplies this number plus 1 by the total path length and divides by the distance between end points.²³ Space curves that exhibit high-amplitude curves with frequent changes of direction will tend to display high ICM values. Tortuosity values as calculated by ICM or similar metrics tend to be elevated in situations in which an artery elongates and develops large-amplitude curves, as may occur with retinopathy of prematurity, hypertension, arteriovenous malformations, and atherosclerosis.²³ A disadvantage of the ICM metric is that, unlike SOAM, the calculated tortuosity value depends, at least partially, on the length of the vessel defined. A short vessel is inherently incapable of possessing a high ICM value. The advantage of the ICM metric, however, is that it can capture abnormal large-amplitude excursions that SOAM cannot. The average ICM value (a dimensionless number) was calculated for each vessel group. Figure 2 illustrates abnormal ICM tortuosity.

These same image-processing methods have already been used to quantitate differences in cerebral vessel morphology by age, anatomic location, and sex.^{12,24} Initial results in the current study, however, raised a new question about the number of small- and large-radius vessels present in active or inactive subjects. For the current study, we, therefore, performed an additional analysis aimed at defining the number of vessels of large or small radii. A complication was posed by our original method of average-radius calculation, however. As initially defined by our segmentation program, a “vessel” could be long, proceeding past many branch points, or could be short, representing only a few voxels. The “average radius” of a lengthy vessel thus incorporated both large-radius proximal points and smaller radius distal points, whereas the “average radius” of a tiny terminal vessel included only a few points of low-radius values.

For the secondary analysis, it seemed desirable to assess vessel radius in a fashion less dependent on segmented vessel length. For the secondary study, each vessel long enough to proceed past a branch point was, therefore, cut so as to terminate at that branch point; as many new vessels as required were added to continue the main trunk to the next branch point or to the termination of the initially segmented vessel. This approach provided analysis of a larger number of shorter “vessels” that were of relatively uniform width throughout their lengths. Custom scripts written for Matlab 7.6 software (MathWorks, Natick, Mass)²⁵ were used to generate whole-head vessel-radius histograms by sorting the vessels into bins by the size of the average radius in increments of 0.1 mm of each vessel and then by counting the number of vessels in each bin. MRA cannot discriminate vessels smaller than those of the voxel size used during image acquisition. Given the voxel size of $0.5 \times 0.5 \times 0.5 \text{ mm}^3$ used in this study, the smallest potentially discriminable vessel had a diameter of 0.5 mm

Comparison of Vessel Attributes

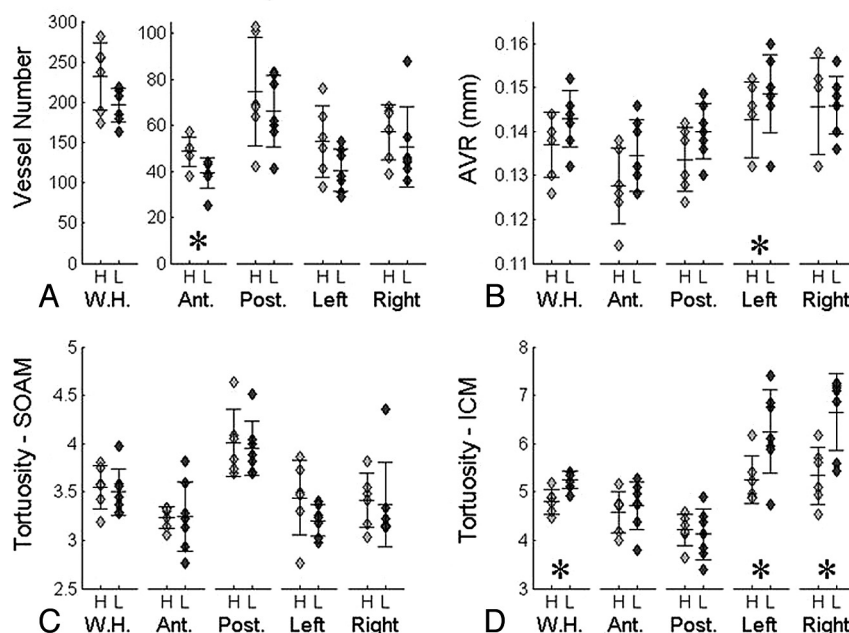


Fig 3. Scatterplots giving vessel-attribute measures in high-activity (light gray) and low-activity (dark gray) subjects. The 3 horizontal lines along each set of scatterplots represent the mean and the mean ± 1 SD. Stars indicate a significant difference ($P < .05$) between subjects of high and low activity as determined by at least 1 of the statistical measures used. A, Vessel number. B, Average vessel radius (AVR). C, Tortuosity measured by SOAM. D, Tortuosity measured by ICM. H indicates high; L, low; W.H., whole-head circulation; Ant, anterior cerebral circulation; Post, posterior circulation; Left, left middle cerebral circulation; Right, right middle cerebral circulation.

and a radius of 0.25 mm. Maximum radius was determined through analysis of the data and was 2.0 mm. The large majority of vessels had calculated radii of 0.5–1.1 mm, with very few vessels possessing radii outside this range. We, therefore, combined all vessels of <0.5-mm radius into a single bin (the bin of smallest radius) and all vessels of >1.1-mm radius into a single bin (the bin of largest radius).

Statistical Analysis

Two-tailed multivariate analysis of variance (MANOVA) was conducted by using the 4 vessel attributes as response variables. Explanatory variables included group type (high or low activity), the 4 anatomic regions analyzed, and interaction terms between group and region. A Wilcoxon rank sum test was also performed for each of the 4 vessel attributes.

After their analysis, the statisticians queried whether a particular patient classified as highly active might have been misclassified because this patient's vessel tortuosity values appeared to resemble those of inactive patients. When this query was passed on to the responsible clinician, the clinician reported that the patient in question was the only individual who had provided inconsistent and changing reports of activity level and perhaps should have been withdrawn from the study. Statistical analysis was, therefore, performed twice, the first time including all of the original 14 subjects (7 active and 7 inactive) and the second time with omission of the patient in question (6 active and 7 inactive subjects).

Analysis of vessel-radius histograms was performed by using Wilcoxon rank sums to compare high- and low-activity groups. Similar to the analyses above, analysis was performed both with and without the subject of questionable activity level.

Results

Aerobically active patients tended to exhibit higher numbers of small vessels and, most prominently and consistently, a

lower vessel-tortuosity value as measured by ICM than did low-activity patients. When all 14 patients were analyzed, multivariate MANOVA analysis found significant differences in the ICM of the LMCA ($P = .032$) and RMCA ($P = .001$) regions. After excluding the patient with an unclear activity level, the reduction in ICM tortuosity values of the highly active group became even more significant in the LMCA ($P = .006$) and RMCA ($P < .001$) regions. No other significant differences in vessel measures were found by multivariate analysis.

When analysis was performed for all 14 subjects by using the Wilcoxon rank sum test, statistically significant differences between high- and low-activity groups were noted for ICM over the whole-head ($P = .038$) and RMCA regions ($P = .004$). When analysis was repeated without the patient of uncertain activity level, these differences became even more pronounced and additional significant differences were noted for vessel number in the ACA region ($P = .024$) and for average radius in the LMCA region ($P = .047$). Figure 3 provides scatter plots for vessel number, radius, and tortuosity for the 13 patients who gave consistent activity-level responses.

When histogram analysis of vessel radii was performed for all 14 subjects, no significant difference was found between the 2 patient groups. When analysis was repeated without the patient of uncertain activity level however, aerobically active patients displayed a trend toward a larger number of small vessels (<0.6-mm average radius) in all anatomic regions studied. This finding reached the level of statistical significance in the whole brain ($P = .039$) and in the regions of LMCA ($P = .014$) and ACA ($P = .032$). No significant difference was noted between activity groups for any other bin representing a larger radius. Indeed, high-activity and low-activity subjects tended to possess close to identical numbers of vessels >0.6 mm in

AVR Histograms

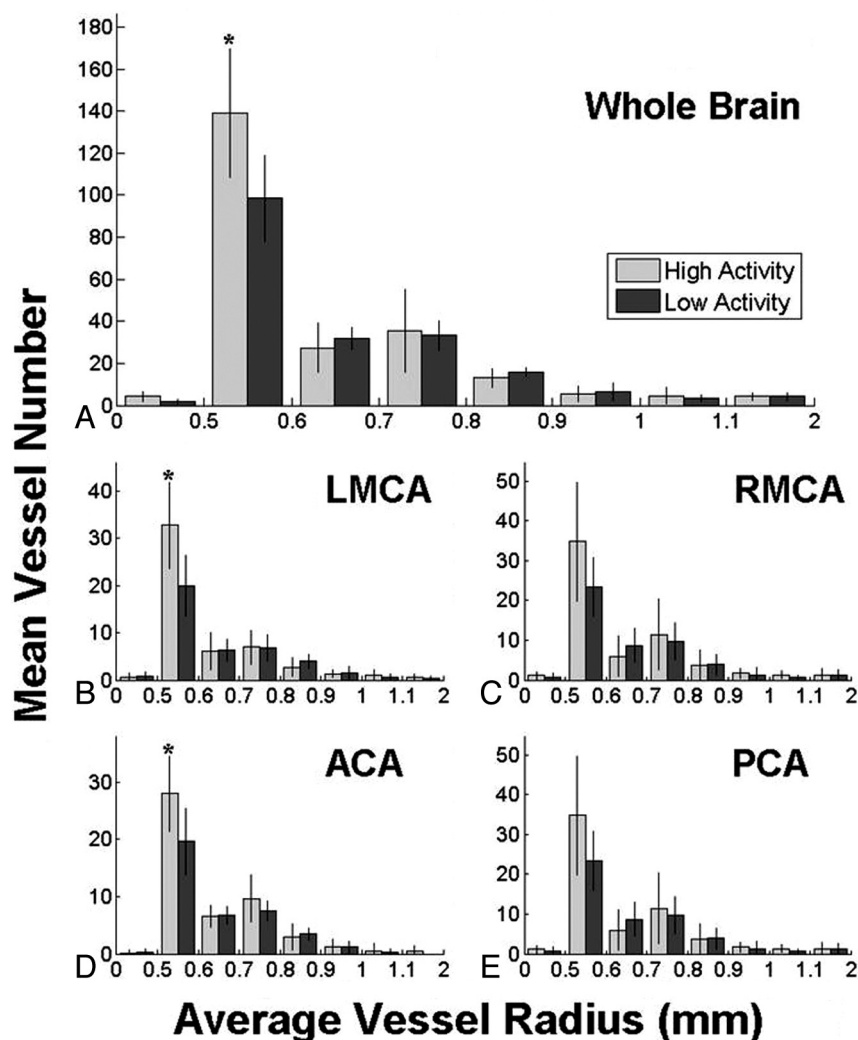


Fig 4. Comparison of high-activity (light gray) and low-activity (dark gray) groups by the number of vessels of graded radius. Colored bars represent the mean value and vertical lines, the SD. Stars denote statistically significant differences ($P < .05$) between activity groups. Note that the smallest and largest bins have ranges of >0.1 mm to encompass all vessels. PCA indicates posterior circulation.

radius regardless of anatomic location. The number of vessels in the smallest radius bin (<0.5 mm) was too small for meaningful analysis. These results are summarized in Fig 4.

Discussion

This blinded study examined quantitative measures of vessel number and shape as defined from noninvasively acquired MRA brain images of 14 healthy elderly subjects. Patients were evenly divided into 2 groups by high and low levels of aerobic activity. Marked differences in vessel tortuosity were observed between groups, with inactive subjects possessing higher vessel tortuosity as measured by ICM regardless of the type of statistical analysis performed. These tortuosity results remained significant even with the inclusion of a patient whose self-reported activity level changed during the study. It is, additionally, striking that the statisticians were able to identify this subject as an outlier without knowledge that the clinician in charge of the study had made the same decision. When statistical analysis was repeated without this problematically classified patient, results even more strongly displayed a de-

crease in vessel tortuosity in active patients and additionally suggested that aerobically active patients may possess an increased number of small vessels (and thus a lower average vessel radius) than low-activity subjects.

By histologic analysis, brain-vessel tortuosity is known to increase with age, hypertension, and other diseases.²⁶⁻²⁸ Histologic studies have also demonstrated that vessel narrowing and/or outright vessel loss occurs with advancing age.^{11,29,30} Although these histologic studies generally address vessels of a diameter smaller than can be seen by MRA, both a reduction in vessel number and/or a reduction in vessel lumen could reduce the number of vessels detected by MRA. In general, MRA cannot distinguish overt vessel loss and the loss of visualizable vessels as a result of decreased flow rate. Reasons for decreased flow rate include decrease in cardiac output, changes in vessel diameter, increased vessel tortuosity, or any combination of these factors.

A recent MRA study in 100 healthy subjects concluded that healthy aging was associated with both a loss in vessel number as perceived by MRA and a mild increase in vessel tortuosity.¹²

In the current study, aerobically active aged patients exhibited lower vessel tortuosity and a reduction in small-vessel loss compared with their less-active equally aged cohorts. The cerebrovascular patterns of the aerobically active patients thus appeared “younger” than those of the relatively inactive patients. Under the assumption that the appearance of imaged vasculature is related to the quality of brain function, this finding could be of significance to all aging subjects.

In the current study, statistically significant vessel tortuosity differences were noted between active and inactive patients when assessed by ICM but not by SOAM. *Webster's New World Dictionary* defines “tortuosity” as “full of twists, turns; crooked,”³¹ but this definition does not differentiate the 2 types of vessel-tortuosity abnormality present in human disease (increases in amplitude versus increases in frequency).²³ In fact, different disease states may induce different types of tortuosity abnormalities, and our approach permits assessing each of the 2 abnormal tortuosity types independently via the 2 metrics, SOAM and ICM.²³ Unfortunately, most clinical articles on cerebrovasculature have assessed “abnormal tortuosity” only subjectively, so it is largely unknown what type of “increased tortuosity” has been previously visualized in histologic studies of aging and hypertension.^{26,27} The current study suggests that aerobically inactive patients may exhibit greater vessel tortuosity produced by vessel elongation and wider expansion curves than their more active cohorts. No difference between groups was apparent when tortuosity was assessed by SOAM, a measure of high-frequency low-amplitude curvature, which is increased in the presence of cancer.^{23,28}

There may be a relationship between tortuosity values as calculated by ICM and the number of small thin vessels that course for only short distances as perceived by MRA. The ICM tortuosity metric is partially dependent on vessel length²³; it is impossible for a very short vessel to possess a high ICM value. The finding of both decreased ICM values and an increased number of vessels of small radius in the aerobically active group may therefore be directly related—both findings could be explained by preservation of small-radius short vessels in aerobically active subjects. Conversely, increased vessel tortuosity may itself reduce the flow rate within each affected vessel, thus leading to poorer visualization by MRA and to an apparent reduction in the number of small vessels. At the present time, it is impossible for us to know which is the cause and which is the effect. It is similarly unknown what the precise relationship between tortuosity and vessel diameter might be, and the study of tortuosity as related to vessel radius, though a highly complex topic, provides fruitful ground for further research.

The 4 anatomic regions analyzed are known to possess inherently different values for vessel tortuosity as measured by either tortuosity metric.^{12,24} This finding is not surprising given the obvious differences in the configuration of the underlying brain. In the current study, we had no reason to expect that any particular anatomic region of the brain would be affected by exercise more than another. The current study suggests that the middle cerebral distributions may be preferentially affected; however, because trends toward the same findings were observed in all anatomic regions, it is possible that future studies involving a larger patient number would reveal statistically significant differences in all 4 anatomic regions.

An important question raised by the current study is whether elderly patients with younger appearing cerebrovascular patterns are more likely to engage in aerobic activity or whether aerobic activity itself is likely to improve brain vasculature directly. The ultimate answer to this question will depend on future longitudinal studies of initially sedentary subjects who undergo an aerobic exercise program with sequential brain imaging. Under this type of longitudinal study, each subject would act as his/her own control, thus simplifying a multiparameter situation that might comprise a plethora of variables, including educational level, medication history, retirement status, preferred diet, and others too numerous to list. Colcombe et al¹⁴ have already reported that an aerobic exercise program can increase brain volume in aged subjects, though the underlying mechanism of this improvement was not explored. Analysis of the vasculature during such a longitudinal study would be of high interest. The current study is in agreement with previously published reports indicating that aerobically active aged patients tend to preserve desirable anatomy better than sedentary subjects,^{14,32} though the current study addressed vascular shape changes rather than brain volumetric determinations or the findings on diffusion images.

Another important question raised by the current study is the extent of correlation between structural and vascular findings. It would be of high interest, for example, to correlate the findings of diffusion tensor imaging with those of vascular imaging. We intend to incorporate such comparisons in future studies.

Three limitations of the study should be noted. First, classification into the high- or low-activity group was based on each subject's report of activity level. Several epidemiologic studies have documented the limitations of self-reports of physical activity.³³⁻³⁷ A more objective means of assessing activity level would be preferable. Such classification will require a future study that uses more objective activity measurement technologies, such as the use of activity-motion monitoring devices.³⁸⁻⁴⁰

Second, the number of patients studied was small, and there was a discrepancy between the number of male and female patients enrolled in each of the 2 activity groups. We do not believe, however, that the calculated differences in vessel-attribute measures between activity groups were produced by sex differences—Bullitt et al¹² analyzed the effects of healthy aging on vessel morphology in 100 patients equally divided by sex and found no significant difference in tortuosity values or vessel number between men and women when men and women of similar ages were compared. Although it would have been desirable to include a much larger number of patients to permit analysis of additional variables such as sex, recruitment for the current study was difficult given the stringent entry requirements and limited funds available. A total of 120 subjects were screened before the final 14 subjects were chosen for analysis. A larger number of subjects would have increased the power of the study, however, and, in addition to enabling the analysis of additional variables, might have allowed several of the nonsignificant trends to reach the level of statistical significance.

Third and finally, MRA cannot visualize vessels smaller than those of the voxel size used during image acquisition. The

smallest discernible vessels in the current study were thus of 0.25-mm radius. Our study was, therefore, not capable of imaging the capillaries and other tiny vessels most frequently analyzed during histologic examination. Other imaging protocols, such as perfusion and permeability imaging, can provide information about tiny vessels lying below the limits of MRA resolution, though such invasive methods cannot provide the quantitative vessel-shape measures available from MRA that we describe here. It would be of high interest to combine the “macro” vessel-imaging capabilities provided by MRA with the “micro” imaging capabilities of perfusion/permeability imaging.

Conclusions

This blinded study analyzed quantitative measures of vessel number and shape as determined from MRA of 14 healthy elderly patients classified into 2 groups by level of aerobic activity. Aged subjects in the high-activity group exhibited statistically decreased vessel tortuosity and an increase in the number of small-diameter vessels, thus producing a vessel morphologic pattern similar to that of younger subjects. These results indicate that aerobic activity may affect the cerebral vasculature. This finding could provide an explanation for the improvement in cerebral anatomy associated with aerobic activity reported by other groups. It remains unclear, however, whether aerobic activity produces anatomic improvements in and of itself or whether patients with younger appearing brains are more likely to engage in aerobic activity. Further work is required to determine if the new initiation of aerobic activity in previously sedentary elderly patients can reverse the cerebrovascular, anatomic, and functional changes associated with advancing age.

References

- Courchesne E, Chisum HJ, Townsend J, et al. Normal brain development and aging: quantitative analysis at in vivo MR imaging in healthy volunteers. *Radiology* 2000;216:672–82
- Matsumae M, Kikinis R, Mórocz, et al. Age related changes in intracranial compartment volumes in normal adults assessed by MRI. *J Neurosurg* 1996;84:982–91
- Peinado MA. Histology and histochemistry of the aging cerebral cortex: an overview. *Microsc Res Tech* 1998;43:1–7
- Resnick SM, Pham DL, Kraut MA, et al. Longitudinal magnetic resonance imaging studies of older adults: a shrinking brain. *J Neurosci* 2003;23:295–301
- Hachinski VC, Potter P, Merskey H. Leuko-araiosis: an ancient term for a new problem. *Can J Neurol Sci* 1986;13(4 suppl):533–34
- Madden DJ, Whiting WL, Huettel SA, et al. Diffusion tensor imaging of adult age differences in cerebral white matter: relation to response time. *Neuroimage* 2004;21:1174–81
- Sullivan EV, Pfefferbaum A. Diffusion tensor imaging and aging. *Neurosci Biobehav Rev* 2006;30:749–61. Epub 2006 Aug 1
- Cullen KM, Kocsi Z, Stone J. Microvascular pathology in the aging human brain: evidence that senile plaques are sites of microhaemorrhages. *Neurobiol Aging* 2006;27:1786–96
- Fernando M, Simpson JE, Matthews F, et al. White matter lesions in an unselected cohort of the elderly: molecular pathology suggests origin from chronic hypoperfusion injury. *Stroke* 2006;37:1391–98
- Buckner RL. Memory and executive function in aging and AD: decline and reserve factors that compensate. *Neuron* 2004;44:195–208
- Brown WR, Moody DM, Thore CR, et al. Vascular dementia in leukoaraiosis may be a consequence of capillary loss not only in the lesions, but in normal-

- appearing white matter and cortex as well. *J Neurol Sci* 2007;257:62–66. Epub 2007 Feb 23
- Bullitt E, Zeng D, Ghosh A, et al. The effects of healthy aging on intracranial blood vessels visualized by magnetic resonance angiography. 2008 May 7. [Epub ahead of print]. Available at: <http://linkinghub.elsevier.com/retrieve/pii/S0197458008001115>. Accessed June 9, 2009
- Creasey H, Rapoport SI. The aging human brain. *Ann Neurol* 2003;17:2–10
- Colcombe SJ, Erickson KI, Scalf PE, et al. Aerobic exercise training increases brain volume in aging humans. *J Gerontol A Biol Sci Med Sci* 2006;61:1166–70
- Marks BL, Madden DJ, Bucur B, et al. Role of aerobic fitness and aging on cerebral white matter integrity. *Ann N Y Acad Sci* 2007;1097:171–74
- Marks BL, Katz LM, Styner M, et al. Aerobic fitness impact on cerebral white matter integrity in the cingulum. *Med Sci Sports Exerc* 2008;40(5)Suppl. 1:S299–300
- Beck AT, Erbaugh J, Ward CH, et al. An inventory for measuring depression. *Arch Gen Psychiatry* 1961;4:561–71
- Brandt J, Folstein S, Folstein M. Differential cognitive impairment in Alzheimer's disease and Huntington's disease. *Ann Neurol* 1988;23:555–61
- Baumgartner TA, Jackson AS. *Measurement for Evaluation in Physical Education and Exercise Science*. Madison, Wis: Brown & Benchmark; 1995:289
- American College of Sports Medicine, ed. *ACSM Exercise Guidelines for Exercise Testing and Training*. New York: Lippincott, Williams & Wilkins; 2006:3–129
- Aylward S, Bullitt E. Initialization, noise, singularities and scale in height ridge traversal for tubular object centerline extraction. *IEEE Trans Med Imaging* 2002;21:61–75
- Bullitt E, Aylward S, Smith K, et al. Symbolic description of intracerebral vessels segmented from magnetic resonance angiograms and evaluation by comparison with x-ray angiograms. *Med Image Anal* 2001;5:157–69
- Bullitt E, Gerig G, Pizer S, et al. Measuring tortuosity of the intracerebral vasculature from MRA images. *IEEE Trans Med Imaging* 2003;22:1163–71
- Bullitt E, Muller K, Jung I, et al. Analyzing attributes of vessel populations. *Med Image Anal* 2005;9:39–49
- The MathWorks. MATLAB, 2008. Version 7.6.0. Available at <http://www.mathworks.com/>. Accessed June 9, 2009
- Spangler KM, Challa VR, Moody DM. Arteriolar tortuosity of the white matter in aging and hypertension: a microradiographic study. *J Neuropathol Exp Neurol* 1994;53:22–26
- Hiroki M, Miyashita K, Oda M. Tortuosity of the white matter medullary arterioles is related to the severity of hypertension. *Cerebrovasc Dis* 2002;13:242–50
- Bullitt E, Lin NU, Smith JK, et al. Blood vessel morphological changes as visualized by MRA during treatment of brain metastases. *Radiology* 2007;245:824–30
- Farkas E, de Vos RA, Donka G, et al. Age-related microvascular degeneration in the human cerebral periventricular white matter. *Acta Neuropathol* 2006;111:150–57
- Uspenskaia O, Liebetrau M, Herms J, et al. Aging is associated with increased collagen type IV accumulation in the basal lamina of human cerebral microvessels. *BMC Neurosci* 2004;5:37–43
- Neufeld V. *Webster's New World Dictionary*. New York: Warner Books; 1990:623
- Marks BL, Katz LM, Nunley DC, et al. Cerebral blood flow and cognitive function is maintained in aerobically active older adults. *Circulation* 2000;102(18):4198 Suppl Oct 31 2000
- Ainsworth BE, Richardson MT, Jacobs DR, et al. Accuracy of recall of occupational physical activity by questionnaire. *J Clin Epidemiol* 1999;52:219–27
- Kurtze N, Rangul V, Hustvedt BE, et al. Reliability and validity of self-reported physical activity in the Nord-Trøndelag Health Study: HUNT 1. *Scand J Public Health* 2008;36:52–61
- Baranowski T. Validity and reliability of self report measures of physical activity: an information-processing perspective. *Res Q Exerc Sport* 1988;59:314–27
- Tudor-Locke CE, Myers AM. Challenges and opportunities for measuring physical activity in sedentary adults. *Sports Med* 2001;31:91–100
- Yore MM, Ham SA, Ainsworth BE, et al. Reliability and validity of the instrument used in BRFSS to assess physical activity. *Med Sci Sports Exerc* 2007;39:1267–74
- Bassett DR, Ainsworth BE, Swartz AM, et al. Validity of four motion sensors in measuring moderate intensity physical activity. *Med Sci Sports Exerc* 2000;32:S471–89
- Chen KY, Bassett DR. The technology of accelerometry-based activity monitors: current and future. *Med Sci Sports Exerc* 2005;37:S490–S500
- Hagstromer M, Oja P, Sjostrom M. Physical activity and inactivity in an adult population assessed by accelerometry. *Med Sci Sports Exerc* 2007;39:1502–08