



**Get Clarity On Generics**

Cost-Effective CT & MRI Contrast Agents

**FRESENIUS  
KABI**

**WATCH VIDEO**

**AJNR**

## **Clinical and Angiographic Follow-Up of Stent-Only Therapy for Acute Intracranial Vertebrobasilar Dissecting Aneurysms**

S.I. Park, B.M. Kim, D.I. Kim, Y.S. Shin, S.H. Suh, E.C. Chung, S.Y. Kim, S.H. Kim and Y.S. Won

This information is current as  
of August 13, 2025.

*AJNR Am J Neuroradiol* 2009, 30 (7) 1351-1356

doi: <https://doi.org/10.3174/ajnr.A1561>

<http://www.ajnr.org/content/30/7/1351>

# ORIGINAL RESEARCH

S.I. Park  
B.M. Kim  
D.I. Kim  
Y.S. Shin  
S.H. Suh  
E.C. Chung  
S.Y. Kim  
S.H. Kim  
Y.S. Won



# Clinical and Angiographic Follow-Up of Stent-Only Therapy for Acute Intracranial Vertebrobasilar Dissecting Aneurysms

**BACKGROUND AND PURPOSE:** Little has been known about the clinical and angiographic follow-up results of stent-only therapy for intracranial vertebrobasilar dissecting aneurysms (VBDA). The purpose of this study was to evaluate the feasibility, safety, clinical, and angiographic follow-up of stent-only therapy for VBDA.

**MATERIALS AND METHODS:** Twenty-seven patients with 29 VBDA (11 ruptured, 18 unruptured), not suitable for deconstructive treatment, underwent stent-only therapy. Feasibility, safety, clinical, and angiographic follow-up were retrospectively evaluated. Angiographic outcomes were compared between single-stent and multiple-stent groups.

**RESULTS:** All attempted stent placements were successfully accomplished without any treatment-related complication. Of the 11 ruptured VBDA, 4 were treated by single stents, 6 by double overlapping stents, and 1 by triple overlapping stents. Of the 18 unruptured VBDA, 6 were treated by stents, and 12 by double overlapping stents. One patient with a ruptured VBDA, treated by single stent, had rebleeding and died. None of the remaining patients had posttreatment bleeding during follow-up (mean, 28 months; range, 7–50 months). Eight patients with ruptured VBDA and all patients with unruptured VBDA had excellent outcomes (modified Rankin Scale, 0–1). The remaining 2 patients with ruptured VBDA were moderately disabled because of the initial damage. Angiographic follow-up was available in 27 VBDA, 4 to 42 months (mean, 12 months) after treatment. Follow-up angiograms revealed complete obliteration of the dissecting aneurysm in 12, partial obliteration in 12, stable in 1, enlargement in 1, and in-stent occlusion in 1. Angiographic improvement (complete or partial obliteration) was more frequent in the multiple-stent group (17/17) than in the single-stent group (7/9;  $P < .05$ ).

**CONCLUSIONS:** In this small series, stent-only therapy was safe and effective in the treatment of VBDA that were not deemed suitable for treatment with parent-artery occlusion.

**A**cute intracranial vertebrobasilar dissecting aneurysm (VBDA) is a well-known cause of acute subarachnoid hemorrhage (SAH) or ischemic stroke of the posterior circulation. Most ruptured VBDA can be treated by deconstructive treatments, which sacrifice the parent artery to obliterate the dissecting aneurysm.<sup>1–4</sup> However, how to manage a ruptured VBDA, which is not suitable for deconstructive treatment, is not well established. Also, there has been controversy on how to manage an unruptured VBDA. Recently, reports of stent-only therapy, a new option for the treatment of VBDA, are increasing.<sup>5–14</sup> However, to our knowledge, little has been known about the clinical and angiographic follow-up results of stent-only therapy for VBDA. The purpose of this study was to retrospectively evaluate the feasibility, safety, and clinical

and angiographic follow-up of stent-only therapy for VBDA, which were not suitable for deconstructive treatment.

## Materials and Methods

### Patients

Our institutional review board approved this retrospective study, and informed patient consent was waived. The diagnosis of VBDA was based on clinical manifestations and findings of radiologic examinations including CT with CT angiography, MR imaging with MR angiography, and conventional angiography. Clinical manifestations suggestive of VBDA included SAH, ischemic symptoms of the brain stem, and/or posterior headache of sudden onset. Radiologic findings of VBDA included symmetric or asymmetric dilation of the affected segment of the vertebrobasilar artery with or without proximal or distal stenosis plus any of the following findings: intramural hematoma, pearl-and-string sign, double-lumen sign, configurational change of the affected segment on serial imaging follow-up, and contrast media stasis at the affected segment on conventional angiography. Incidentally found radiologic abnormalities of the vertebrobasilar artery, which might be suggestive of arterial dissection but without corresponding clinical symptoms, were excluded because the lesions were not thought to be acute dissection but, rather, chronic dissection or other pathologic condition of the artery.

A total of 108 patients with 113 VBDA (59 ruptured and 54 unruptured) were identified at 3 institutions between January 2001 and October 2007. Six patients had bilateral vertebral artery dissections (11 dissecting aneurysms and 1 stenotic vertebral artery dissection).

Received November 12, 2008; accepted after revision January 24, 2009.

From the Department of Radiology (S.I.P.), Soonchunhyang University College of Medicine, Bucheon Hospital, Bucheon, Korea; Department of Radiology (B.M.K., D.I.K.), Yonsei University College of Medicine Severance Hospital, Seoul, Korea; Department of Neurosurgery (Y.S.S.), Catholic University College of Medicine, Seoul, Korea; Department of Radiology (S.H.S.), Kangnam Severance Hospital, Yonsei University College of Medicine, Seoul, Korea; Departments of Radiology (E.C.C.) and Neurosurgery (Y.S.W.), Sungkyunkwan University School of Medicine, Kangbuk Samsung Hospital, Seoul, Korea; and Departments of Radiology (S.Y.K.) and Neurosurgery (S.H.K.), Ajou University College of Medicine, Suwon, Korea.

Please address correspondence to Byung Moon Kim, MD, Yonsei University College of Medicine, Severance Hospital, Seoul, Korea; e-mail: bmoon21@hanmail.net

indicates article with supplemental on-line tables.

DOI 10.3174/ajnr.A1561

Among the 113 VBDA with aneurysmal dilation, 25 VBDA were conservatively managed, 38 were treated by parent-vessel occlusion (internal coil trapping or proximal occlusion), 21 were treated by single or double stent(s) with coiling, and 29 VBDA in 27 patients were treated by stent-only therapy. These 27 patients constituted the population of this study. The patients included 17 men and 10 women (mean age, 46 years; age range, 24–71 years). Eleven patients presented with SAH, 10 with posterior headache of sudden onset, 5 with brain stem infarct, and the remaining 1 with brain stem compression sign 3 years after stem infarct. Two patients had bilateral vertebral dissecting aneurysms: 1 presented with SAH, and the other presented with posterior headache of sudden onset. The 27 patients with VBDA included in our study were treated by stent-only therapy, not by deconstructive treatment, because of involvement of the basilar artery (BA) in 4, involvement of the vertebral arterial segment bearing the origin of the dominant posterior inferior cerebellar artery (PICA) with relatively small size of the anterior inferior cerebellar artery (AICA) in 21, or involvement of bilateral vertebral arterial segments bearing the origin of the PICA in 2.

### **Antiplatelet Medication and Anticoagulation**

Dual antiplatelet therapy (acetylsalicylic acid plus clopidogrel) was routinely given to the patients with unruptured acute intracranial VBDA before and after stent placement, except for 1 patient who was treated in the early period of the collected cases. For the patients with ruptured acute intracranial VBDA, antiplatelet premedication was not given, but a loading dose of dual antiplatelet therapy was given immediately after completion of the procedure. Dual antiplatelet therapy was maintained for 3 to 6 months and then was changed to aspirin monotherapy indefinitely. Anticoagulation was started at the beginning of the procedure, and activated coagulation time was maintained 2 to 3 times the baseline value during the procedure and for 24 to 48 hours after the procedure.

### **Stent Placement for VBDA**

A 6F guiding catheter (Envoy; Cordis, Miami Lakes, Fla) was placed at the cervical portion of the affected vertebral artery. A microcatheter (Excelsior-10; Boston Scientific, Natick, Mass, or Prowler-14, Cordis) was navigated to a distal branch of the posterior cerebral artery with use of a 0.014-inch wire (Synchro, Boston Scientific; or Agility, Cordis), which was then exchanged with a 300-cm-length exchangeable guidewire (Transcend or Choice-PT, Boston Scientific). The microcatheter was retrieved and a balloon-expandable stent or a self-expanding stent was advanced over the prepositioned exchangeable guidewire and was deployed covering the entire dissected segment. The types of stents were determined according to the operator's preference, availability of the stent, and the degree of difference of the vessel diameter between the proximal and distal portions of the affected segment. The number of overlapping stents was determined according to the location of the dissection of the vertebral artery or the basilar artery, tortuosity of the parent artery, and findings on control angiogram just after deployment of the first stent. Technical success was defined by correct placement of the stent(s). The stents used included a self-expanding Neuroform stent (Boston Scientific) and various types of balloon-expandable coronary stents (Vision, Guidant, St. Paul, Minn; FlexMaster, JOMED, Rangendingen, Germany; Driver, Medtronic, Minneapolis, Minn; Zeta, Abbott Vascular, Santa Clara, Calif).

### **Clinical Assessment and Angiographic Follow-up**

The patients were clinically assessed on admission with the Hunt and Hess grading system and were evaluated for complications during and after treatment. Clinical outcome was evaluated at discharge and clinical follow-up according to the modified Rankin Scale score (mRS). Each patient's clinical status at the last clinical follow-up was defined as the final outcome.

Angiographic follow-up was available at least once in 27 VBDA in 25 patients at 4 to 42 months (mean, 12 months) after treatment. The degree of obliteration of the dissecting aneurysmal sac was evaluated by an interventional neuroradiologist, who was not involved in the treatment, and classified into 4 categories: 1) complete obliteration if the dissecting aneurysmal sac was completely obliterated, 2) partial obliteration if the dissecting aneurysmal sac remarkably decreased in size but remained, 3) stable if the dissecting aneurysmal sac showed no remarkable interval change in size and configuration, and 4) aggravation if the dissecting aneurysmal sac increased in size. In-stent occlusion or in-stent stenosis, and patency of the branch vessel or the perforators covered by stents were also evaluated on follow-up angiography.

### **Statistics**

We performed statistical analyses using SPSS for Windows (Version 12.0; SPSS, Chicago, Ill). We then compared angiographic follow-up results of 26 VBDA except for 3 VBDA (2 without angiographic follow-up and 1 in-stent occlusion) between single-stent ( $n = 9$ ) and multiple-stent (double or triple,  $n = 17$ ) groups or between ruptured ( $n = 9$ ) and unruptured ( $n = 17$ ) groups by using the 2-sided  $\chi^2$  test. For comparison, angiographic follow-up results were dichotomized to improvement (complete or partial obliteration) or no improvement (stable or aggravated). Statistical significance was determined by  $P < .05$  for a 95% confidence interval.

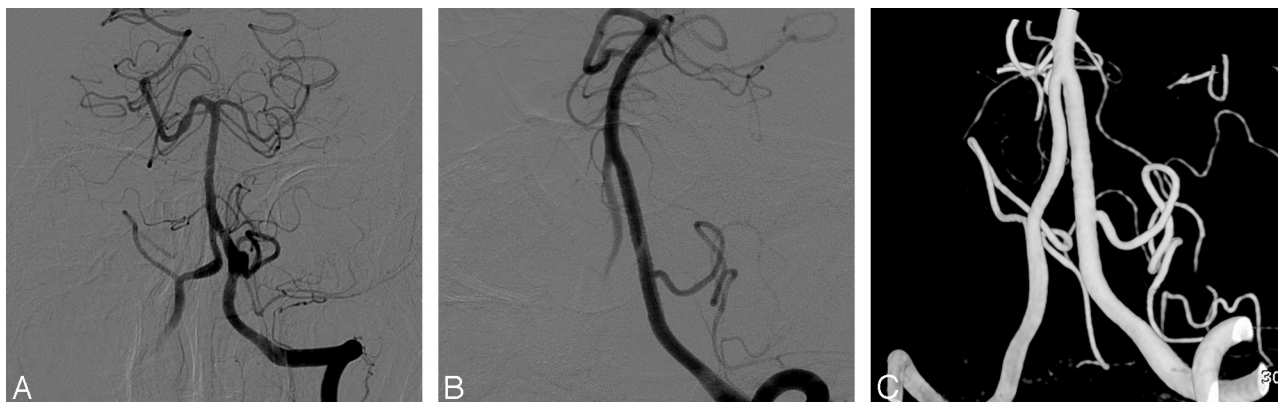### **Results**

Clinical characteristics and clinical and angiographic follow-up results of the patients are summarized in On-line Table 1. Attempted stent placement was successfully accomplished without any treatment-related complication in all of the 29 VBDA in 27 patients.

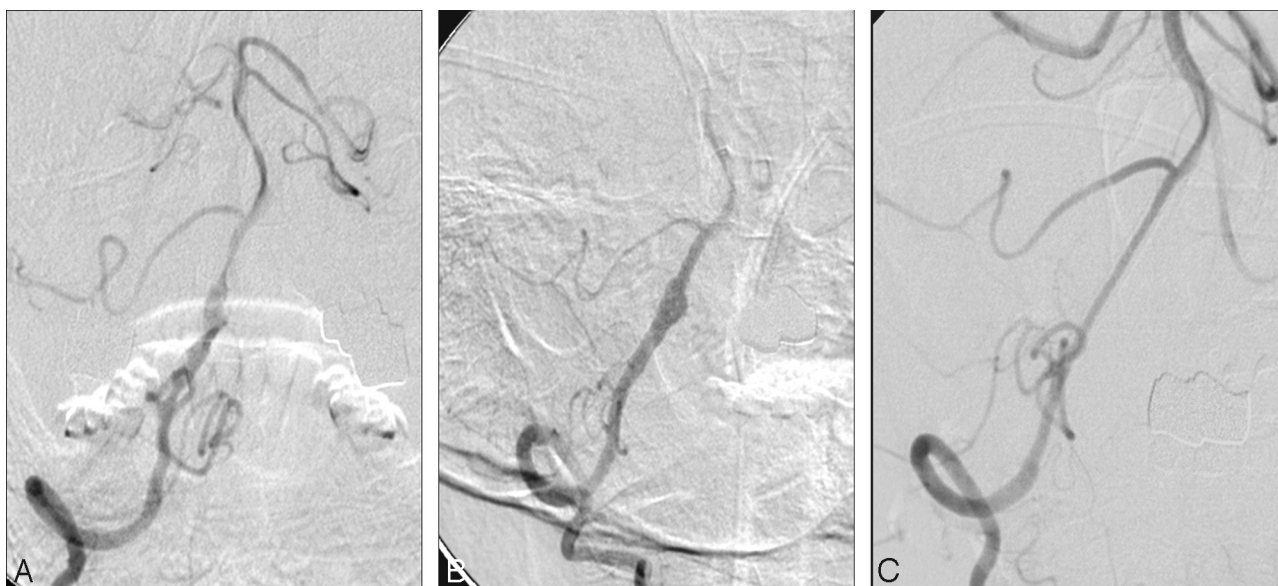
Of the 11 ruptured VBDA, 4 were treated by single stent, 6 by double overlapping stents (Fig 1), and 1 by triple overlapping stent (Fig 2). Of the 18 unruptured VBDA, 6 were treated by single stent and 12 by double stents.

One patient with a ruptured basilar dissecting aneurysm, who underwent single-stent placement, had rebleeding 3 days after treatment and died (Fig 3). Because of a concern about perforator obstruction and a favorable finding on control angiogram just after single-stent placement (Fig 3B), a second stent insertion was not attempted. None of the surviving 26 patients had posttreatment bleeding during the clinical follow-up for 7 to 50 months (mean, 28 months). Eight patients with ruptured VBDA had excellent outcomes (mRS, 0–1). The remaining 2 patients with ruptured VBDA were disabled because of the initial damage (mRS, 3 and 4, respectively). All 16 patients with unruptured VBDA had excellent outcomes without any neurologic deficit (mRS, 0).

On-line Table 2 summarizes the follow-up angiographic results of the VBDA treated by stent only according to presentation and number of overlapping stents. Follow-up angiogram revealed complete obliteration of the VBDA in 12 aneu-



**Fig 1.** Images in a 42-year-old man presenting with an acute SAH. *A*, Left vertebral artery angiogram reveals a dissecting aneurysm with an asymmetrically fusiform appearance at the segment-bearing left posterior inferior cerebellar artery. At 42 months after treatment with double overlapping stents, a left vertebral angiogram (*B*) and 3D reconstruction images (*C*) show complete obliteration of the dissecting aneurysm sac with preservation of the left PICA.



**Fig 2.** Images in a 49-year-old man presenting with an acute SAH. *A*, Right vertebral angiogram reveals irregular dilation of the right intracranial vertebral artery with a pearl-and-string appearance, involving the origin of the right PICA. *B*, Right vertebral angiography 4 days after double-overlapping stent insertion shows partial resolution of the pearl-and-string appearance but reveals enlarged fusiform dilation of the dissected segment. *C*, Six-month follow-up angiogram after third overlapping stent reveals complete obliteration of the fusiform dilation with a preserved PICA and smooth reconstruction of the dissected segment.

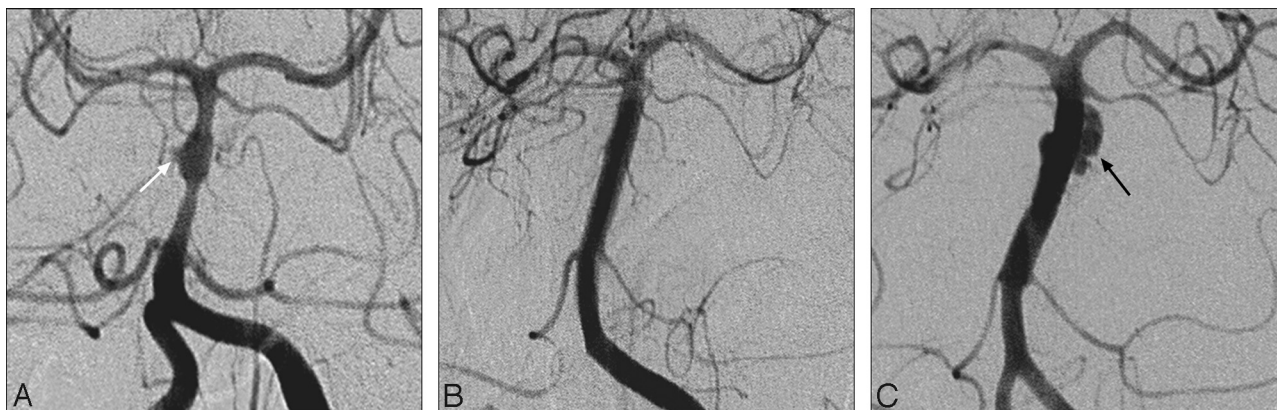
rysms, partial obliteration in 12, stable in 1, and aggravation in 1. Angiographic improvement (complete or partial obliteration) was more frequently observed in the multiple-stent group (17/17 [100%]) than in the single-stent group (7/9 [77.8%];  $P < .05$ ) but was not significantly different between the ruptured group (9/9 [100%]) and the unruptured group (15/17 [88.2%]). We determined to carefully follow up on the VBDA with aggravation because the dissecting aneurysm was unruptured and the patient refused additional treatment. In-stent occlusion was detected on a 4-month follow-up angiogram in 1 unruptured basilar artery dissecting aneurysm treated by double overlapping stents, and the case was presented in a previously published report.<sup>14</sup> The remaining 26 VBDA showed no in-stent stenosis, occlusion of the PICA, or the perforators jailed by the stent.

## Discussion

Acute VBDA can present with SAH, brain stem ischemia, and/or sudden posterior headache. Various endovascular

methods have been used to treat the VBDA, which include proximal occlusion of the parent artery, internal coil obliteration or trapping of the dissected segment of the parent artery, stent-assisted coiling, stent-only therapy with single or multiple stents, and covered stent.<sup>1-18</sup> However, for the VBDA not suitable for deconstructive treatments that occludes the parent artery, the appropriate treatment method has not been well established. In patients who had basilar dissecting aneurysms or dominant vertebral dissecting aneurysms with poor collaterals, internal coil trapping cannot be applied. In patients with ruptured dissecting aneurysms involving the segment bearing PICA origin, proximal occlusion of the parent artery is an option, but this technique does not protect from rebleeding because of retrograde flow to the dissected segment.<sup>3,19-22</sup> Internal coil trapping including the PICA origin may also be considered, especially in acute situations. Pelluso et al<sup>4</sup> reported successful treatment of 2 patients with ruptured vertebral dissections by internal coil trapping including the PICA origin. Those 2 patients had no clinical complication related to





**Fig 3.** Images in a 24-year-old woman presenting with SAH. *A*, Left vertebral angiogram reveals an asymmetrical fusiform dilation with a bleb (white arrow) of the basilar artery. *B*, Left vertebral angiogram immediately after a balloon-expandable coronary stent insertion reveals near-complete obliteration of the dissecting aneurysm sac. *C*, Left vertebral angiogram performed because of rebleeding 3 days after the single-stent placement shows an irregular-shaped and enlarged pseudoaneurysm (black arrow) of the basilar artery.

the PICA occlusion. Also, the same authors reported 6 aneurysms at the PICA origin that were treated by coil occlusion, including the parent PICA in 2 and the VA and PICA origin in 4.<sup>23</sup> Lateral medullary and cerebellar infarction leading to hemiparesis developed in 1 of the 6 patients. These reports suggest that PICA occlusion may be more tolerable than expected. However, it was difficult to predict the consequence of PICA occlusion in ruptured vertebral dissection. In our experience and personal communication with the neurointerventional radiologist colleagues in our country, internal coil trapping including the PICA origin in ruptured vertebral artery dissections resulted in significant complications in 2 of 3 patients, including a massive cerebellar infarction requiring posterior craniectomy for decompression. Additional study on internal coil trapping including the PICA origin for treatment of ruptured vertebral artery dissections may be required. Therefore, our treatment policy was to select the method that did not sacrifice the PICA even in ruptured VBDA involving the PICA origin, unless the ipsilateral AICA was definitely dominant over the PICA.

Recently, much interest has centered on reconstructive endovascular treatment with use of a stent for an intracranial dissecting aneurysm or pseudoaneurysm. Since Lylyk et al<sup>15</sup> reported a case of stent-only therapy for bilateral VA dissecting aneurysms included in a series of stent-assisted coil embolization, an increasing number of cases of stent-only therapy were reported (On-line Table 3).<sup>5-8,10-13,15-17,24,25</sup> However, little has been known about the clinical and angiographic follow-up results of stent-only therapy for VBDAs. The present study, to the best of our knowledge, includes the largest number of the VBDAs treated by stent only.

In review of the literature, 38 intracranial VBDAs, 4 blood-blisterlike aneurysms, and 3 postsurgical pseudoaneurysms in 43 patients were treated by stent-only therapy (On-line Table 3). Two (4.7%) of the 43 patients had a treatment-related complication of occipital infarction, resulting in partial visual field deficit.<sup>10,13</sup> In our study, a technical success rate of 100% was achieved with no treatment-related complications. These findings suggest that stent-only therapy is a technically feasible and safe treatment option for VBDA. Among the 43 patients, 43 aneurysms in 41 patients were followed up with angiography 1 to 18 months after treatment. Of those, 31 (72.1%) re-

vealed complete obliteration of the dissecting aneurysm or pseudoaneurysm sac, 6 (14.0%) revealed partial obliteration, 1 (2.3%) was stable, 2 (4.7%) were enlarged, 1 (2.3%) had recanalization after near-complete obliteration, and 2 (4.7%) had in-stent occlusion. The rate of complete obliteration in our series was lower than that reported in the literature (41.4% vs 71.4%). However, the rate of angiographic improvement (complete or partial obliteration) of our study was similar to that reported in the literature (82.8% vs 86.1%). Angiographic improvement (complete or partial obliteration) was significantly more frequent in the multiple-stent group than in the single-stent group. This finding suggests that multiple overlapping stents may be more effective for obliteration of a dissecting aneurysm sac than a single stent.

In the literature, 2 (4.7%) of 43 cases with follow-up angiography revealed in-stent occlusion, of which 1 patient died from brain stem infarction.<sup>10,25</sup> In our study, 1 (3.7%) of 27 cases with follow-up angiography also showed in-stent occlusion. Of the 3 patients in the literature and in our study, 2 did not receive antiplatelet medication, and the third patient was not compliant with antiplatelet medication. These suggest once again that appropriate antiplatelet medication should be mandatory for all patients who have undergone stent placement. The possibility of the occlusion of the branch vessels or the perforators covered by the stent is another major concern in stent therapy, especially for the perforator-rich vertebrobasilar system. Fortunately, in this study and in the literature, there was no occlusion of the branch vessels or of the perforators jailed by the stents. These correspond with *in vivo* research data with high-porosity stents and the hypothesis that if the pressure gradient across the perforators is maintained and the perforator is covered less than 50% by stent struts, the arteries will remain patent and will remodel around the struts.<sup>17,26-30</sup>

There has been a controversy on whether unruptured VBDAs should be treated or conservatively managed. Because of the retrospective nature of our study, it was determined according to each institution's policy and the patient's choice whether the unruptured VBDA was treated. In our study, none of the unruptured VBDAs bled during follow-up. This may be owing to either the nature of the unruptured VBDA or the effect of stent therapy. To establish an appropriate algo-

rhythm for the management of unruptured VBDA, a prospective study with a larger population of unruptured VBDA may be required.

In animal aneurysm models, stent-only therapy revealed very encouraging results.<sup>29-34</sup> In experimental studies with particle image velocimetry and computational flow dynamics, a stent decreases inflow complexity, inflow momentum and velocity, vorticity, wall shear stress, and wall shear stress rate, and increases intra-aneurysmal blood turnover time by diverting blood flow from the aneurysm and by dispersing the inflow into the aneurysm sac.<sup>35-43</sup> These hemodynamic changes induced by the stent may help to prevent aneurysmal rupture or growth. The hemodynamics can be more favorably changed by decreasing stent porosity and straightening the curvature of the parent vessel segment bearing the aneurysm.<sup>38-43</sup> Stents may work more effectively in vivo than expected in experimental flow dynamic models. Because the vessel is not a rigid pipe, the stent may correct the aneurysm neck-parent artery angle and thereby induce more favorable hemodynamic changes.<sup>13</sup> Also, the vessel wall may interact with the stent, resulting in tissue response at the vessel wall and the aneurysm neck,<sup>30,44,45</sup> which may promote healing response of the dissected vessel wall. Both cases (1 in the literature and 1 in our series), which rebled after stent-only therapy, were located at the basilar artery and underwent single-stent placement.<sup>24</sup> Relatively higher porosity of the single stent and less effective angle correction of the BA might be responsible for rebleeding in the acute phase. The introduction of a newly designed stent with low porosity such as a pipeline may help to overcome limitations of a high-porosity stent and play a pivotal role in the treatment of a dissecting aneurysm as well as of a saccular aneurysm.<sup>30,46</sup>

## Conclusions

Stent-only therapy was safe and effective in the treatment of VBDA that were not deemed suitable for treatment with parent artery occlusion. Multiple overlapping stents seem to be more effective in the obliteration of the dissecting aneurysm sac than a single stent.

## References

- Yamaura I, Tani E, Yokota M, et al. Endovascular treatment of ruptured dissecting aneurysms aimed at occlusion of the dissected site by using Guglielmi detachable coils. *J Neurosurg* 1999;90:853-56
- Kurata A, Ohmomo T, Miyasaka Y, et al. Coil embolization for the treatment of ruptured dissecting vertebral aneurysms. *AJNR Am J Neuroradiol* 2001;22:11-18
- Rabinov JD, Hellinger FR, Morris PP, et al. Endovascular management of vertebrobasilar dissecting aneurysms. *AJNR Am J Neuroradiol* 2003;24:1421-28
- Pelluso JP, van Rooij WJ, Sluzewski M, et al. Endovascular treatment of symptomatic intradural vertebral dissecting aneurysms. *AJNR Am J Neuroradiol* 2008;29:102-06
- Benndorf G, Herbon U, Sollmann WP, et al. Treatment of a ruptured dissecting vertebral artery aneurysm with double stent placement: case report. *AJNR Am J Neuroradiol* 2001;22:1844-48
- Mehta B, Burke T, Kole M, et al. Stent-within-a-stent technique for the treatment of dissecting vertebral artery aneurysms. *AJNR Am J Neuroradiol* 2003;24:1814-18
- Vanninen R, Manninen H, Ronkainen A. Broad-based intracranial aneurysms: thrombosis induced by stent placement. *AJNR Am J Neuroradiol* 2003;24:263-66
- Doerfler A, Wanke I, Egelhof T, et al. Double-stent method: therapeutic alternative for small wide-necked aneurysms. Technical note. *J Neurosurg* 2004;100:150-54
- Hanel RA, Boulos AS, Sauvageau EG, et al. Stent placement for the treatment of nonsaccular aneurysms of the vertebrobasilar system. *Neurosurg Focus* 2005;18:E8
- Fiorella D, Albuquerque FC, Deshmukh VR, et al. Endovascular reconstruction with the Neuroform stent as monotherapy for the treatment of uncoilable intradural pseudoaneurysms. *Neurosurgery* 2006;59:291-300
- Shin YS, Kim HS, Kim SY. Stenting for vertebrobasilar dissection: a possible treatment option for nonhemorrhagic vertebrobasilar dissection. *Neuroradiology* 2007;49:149-56
- Ansari SA, Lassi JP, Nicol E, et al. Thrombosis of a fusiform intracranial aneurysm induced by overlapping Neuroform stents: case report. *Neurosurgery* 2007;60:E950-51
- Zenteno MA, Santos-Franco JA, Freitas-Modenese JM, et al. Use of the sole stenting technique for the management of aneurysms in the posterior circulation in a prospective series of 20 patients. *J Neurosurg* 2008;108:1104-18
- Kim BM, Suh SH, Park SI, et al. Management and clinical outcome of acute basilar artery dissection. *AJNR Am J Neuroradiol* 2008;29:1937-41
- Lylyk P, Cohen JE, Ceratto R, et al. Combined endovascular treatment of dissecting vertebral artery aneurysms by using stents and coils. *J Neurosurg* 2001;94:427-32
- Lubicz B, Collignon L, Lefranc F, et al. Circumferential and fusiform intracranial aneurysms: reconstructive endovascular treatment with self-expandable stents. *Neuroradiology* 2008;50:499-507
- Wakhloo AK, Mandell J, Gounis MJ, et al. Stent-assisted reconstructive endovascular repair of cranial fusiform atherosclerotic and dissecting aneurysms. Long-term clinical and angiographic follow-up. *Stroke* 2008;39:3288-96
- He M, Zhang H, Lei D, et al. Application of covered stent grafts for intracranial vertebral artery dissecting aneurysms. *J Neurosurg* 2009;110:418-26
- Kitanaka C, Morimoto T, Sasaki T, et al. Rebleeding from vertebral artery dissection after proximal clipping. Case report. *J Neurosurg* 1992;77:466-68
- Kawamata T, Tanikawa T, Takeshita M, et al. Rebleeding of intracranial dissecting aneurysm in the vertebral artery following proximal clipping. *Neurol Res* 1994;16:141-44
- Hirano A, Hashi K. [Bleeding from unruptured dissecting aneurysm in the vertebral artery after proximal clipping.] *No Shinkei Geka* 1995;23:1135-39
- Yasui T, Kishi H, Komiyama M, et al. [Rupture mechanism of ruptured intracranial dissecting aneurysm in the vertebral artery following proximal occlusion.] *No Shinkei Geka* 2000;28:345-49
- Pelluso JP, van Rooij WJ, Sluzewski M, et al. Posterior inferior cerebellar artery aneurysms: incidence, clinical presentation, and outcome of endovascular treatment. *AJNR Am J Neuroradiol* 2008;29:86-90
- Kaku Y, Yoshimura S, Yamakawa H, et al. Failure of stent-assisted endovascular treatment for ruptured dissecting aneurysms of the basilar artery. *Neuroradiology* 2003;45:22-26
- Levy EI, Boulos AS, Bendok BR, et al. Brainstem infarction after delayed thrombosis of a stented vertebral artery fusiform aneurysm: case report. *Neurosurgery* 2002;51:1280-84
- Lieber BB, Gounis MJ. The physics of endoluminal stenting in the treatment of cerebrovascular aneurysms. *Neurol Res* 2002;24(suppl 1):S33-S42
- Masuo O, Terada T, Walker G, et al. Study of the patency of small arterial branches after stent placement with an experimental in vivo model. *AJNR Am J Neuroradiol* 2002;23:706-10
- Lopes DK, Ringer AJ, Boulos AS, et al. Fate of branch arteries after intracranial stenting. *Neurosurgery* 2003;52:1275-78; discussion 1278-79
- Wakhloo AK, Schellhammer F, de Vries J, et al. Self-expanding and balloon-expandable stents in the treatment of carotid aneurysms: an experimental study in a canine model. *AJNR Am J Neuroradiol* 1994;15:493-502
- Kallmes DF, Ding YH, Dai D, et al. A new endoluminal, flow-disrupting device for treatment of saccular aneurysms. *Stroke* 2007;38:2346-52
- Turjman F, Acevedo G, Moll T, et al. Treatment of experimental carotid aneurysms by endoprosthesis implantation: preliminary report. *Neurol Res* 1993;15:181-84
- Geremia G, Haklin M, Brennecke L. Embolization of experimentally created aneurysms with intravascular stent devices. *AJNR Am J Neuroradiol* 1994;15:1223-31
- Geremia G, Brack T, Brennecke L, et al. Occlusion of experimentally created fusiform aneurysms with porous metallic stents. *AJNR Am J Neuroradiol* 2000;21:739-45
- Hans FJ, Krings T, Moller-Hartmann W, et al. Endovascular treatment of experimentally induced aneurysms in rabbits using stents: a feasibility study. *Neuroradiology* 2003;45:430-34
- Lieber BB, Stancampiano AP, Wakhloo AK. Alteration of hemodynamics in aneurysm models by stenting: influence of stent porosity. *Ann Biomed Eng* 1997;25:460-69
- Yu SC, Zhao JB. A steady flow analysis on the stented and non-stented sidewall aneurysm models. *Med Eng Phys* 1999;21:133-41
- Rudin S, Wang Z, Kyprianou I, et al. Measurement of flow modification in phantom aneurysm model: comparison of coils and a longitudinally and axially asymmetric stent—initial findings. *Radiology* 2004;231:272-76
- Canton G, Levy DI, Lasheras JC, et al. Flow changes caused by the sequential

- placement of stents across the neck of sidewall cerebral aneurysms. *J Neurosurg* 2005;103:891–902
39. Canton G, Levy DI, Lasheras JC. Hemodynamic changes due to stent placement in bifurcating intracranial aneurysms. *J Neurosurg* 2005;103:146–55
  40. Meng H, Wang Z, Kim M, et al. Saccular aneurysms on straight and curved vessels are subject to different hemodynamics: implications of intravascular stenting. *AJNR Am J Neuroradiol* 2006;27:1861–65
  41. Kim M, Levy EI, Meng H, et al. Quantification of hemodynamic changes induced by virtual placement of multiple stents across a wide-necked basilar trunk aneurysm. *Neurosurgery* 2007;61:1305–12
  42. Kim M, Taulbee DB, Tremmel M, et al. Comparison of two stents in modifying cerebral aneurysm hemodynamics. *Ann Biomed Eng* 2008;36:726–41
  43. Liou TM, Li YC. Effects of stent porosity on hemodynamics in a sidewall aneurysm model. *J Biomech* 2008;41:1174–83
  44. Bai H, Masuda J, Sawa Y, et al. Neointima formation after vascular stent implantation. Spatial and chronological distribution of smooth muscle cell proliferation and phenotypic modulation. *Arterioscler Thromb* 1994;14:1846–53
  45. Wakhloo AK, Tio FO, Lieber BB, et al. Self-expanding nitinol stents in canine vertebral arteries: hemodynamics and tissue response. *AJNR Am J Neuroradiol* 1995;16:1043–51
  46. Fiorella D, Woo HH, Albuquerque FC, et al. Definitive reconstruction of circumferential, fusiform intracranial aneurysms with the pipeline embolization device. *Neurosurgery* 2008;62:1115–20