



Discover Generics

Cost-Effective CT & MRI Contrast Agents



FRESENIUS
KABI

WATCH VIDEO

AJNR

Middle Ear Adenoma: A Challenging Diagnosis

E. Zan, C.J. Limb, J.F. Koehler and D.M. Yousem

AJNR Am J Neuroradiol 2009, 30 (8) 1602-1603

doi: <https://doi.org/10.3174/ajnr.A1534>

<http://www.ajnr.org/content/30/8/1602>

This information is current as
of June 29, 2025.

E. Zan
C.J. Limb
J.F. Koehler
D.M. Yousem



SUMMARY: Middle ear adenomas are rare benign tumors, which can easily be mistaken for other conditions radiologically. They derive from the middle ear mucosa. We report the case of a 48-year-old man with a history of decreased left-sided hearing and intermittent pulsatile tinnitus. High-resolution CT of the temporal bones revealed a well-defined left middle ear soft-tissue attenuation abutting the head of the malleus. Surgical excision revealed a middle ear adenoma.

Since middle ear adenomas were first described by Hyams and Michaels¹ in 1976 and later that year by Derlacki and Barney,² they have become one of the unusual entities listed in the differential diagnosis of a middle ear mass. The clinical presentation and otoscopic and radiologic findings are non-specific. Definitive diagnosis is based on histologic and immunohistochemical examination.³

We report the case of a 48-year-old man with a history of left ear progressive symptoms, whose initial radiologic diagnosis favored glomus tympanicum versus cholesteatoma.

Case Report

A 48-year-old man presented with a history of left ear progressive symptoms for 18 months (decreased hearing, intermittent pulsatile tinnitus, and a sensation of water in the ear canal, which did not clear with the nasal Valsalva maneuver). His otoscopic examination revealed a white smooth teardrop-shaped mass deep to the tympanic membrane, but the tympanic membrane and the external auditory canal were unremarkable. His audiogram showed a mild mixed hearing loss. On reviewing the middle ear through a binocular operating microscope, we found what appeared to be a large smooth flesh-colored mass, which arose to the level of the malleus. Insufflating the external auditory canal with air, we found that the mass appeared to blanch and return to its fleshy color once the pressure was stopped. Due to this finding and the absence of tympanic membrane perforation or chronic ear infection, the patient was referred for a temporal bone CT and octreotide scanning of the head and neck for a probable diagnosis of glomus tympanicum.

Dedicated temporal CT of the left ear revealed a 1.0 × 0.5 cm well-defined lobulated homogeneous soft-tissue-attenuation mass centered at the left cochlear promontory, which extended into the hypotympanum and filled the round window niche and the sinus tympani and also extended over the pyramidal eminence lying directly adjacent to the mastoid portion of the facial nerve. The lesion abutted the head of the malleus without vestibular, cochlear, or frank bony involvement. The octreotide scan demonstrated a left middle ear focus of intense radiotracer activity, most compatible with a neuroendocrine tumor; and on the basis of the findings of CT, the provisional diagnosis was a glomus tympanicum (Figs 1 and 2).

The patient underwent surgery, during which the middle ear mass was resected by using a transmastoid and transcanal approach to the middle ear space, including facial recess dissection. The mass directly abutted not only the malleus but also the stapes, with no evidence of erosion. Pathology revealed a middle ear adenoma (on-line Fig 1). The patient's postoperative examination revealed much-improved hearing. Clinical and radiologic follow-up was recommended because recurrence was possible.

Discussion

Middle ear adenoma is a rare benign epithelial tumor deriving from middle ear mucosal cells with both epithelial and neuroendocrine properties.³ It was first described by Hyams and Michaels¹ in 1976 and later that year by Derlacki and Barney.² The clinical, otoscopic, and imaging findings are nonspecific. The mean age is 45 years with no sex predominance.⁴ The lesion is white, yellow, gray, or reddish-brown; firm; and usually poorly vascularized.⁴ Patients can present with a sense of ear fullness, tinnitus, or unilateral conductive hearing loss at the affected ear.⁴

On high-resolution temporal CT, a relatively well-circumscribed soft-tissue-attenuation enhancing mass is seen without evidence of bone erosion. The lesion may be embedded in the ossicles (Fig 1). MR imaging characteristics of the middle ear adenoma show low-to-intermediate intensity on T1-weighted images, high intensity on T2-weighted images, and enhancement after administration of gadolinium. Even though the tumor can be successfully treated with surgical resection, recurrence is reported and long-term follow-up is usually required.³ The spectrum of differentiation depends on the exocrine (mucinous) and/or neuroendocrine components defined by histologic and immunohistochemical examination.⁵ It is believed that the different names given to the neuroendocrine lesions of the middle ear (carcinoid tumor,⁶ adenoma,^{1,2} adenomatous tumor of the middle ear,² low-grade adenocarcinoma,⁷ monomorphic adenoma and ceruminoma⁸) represent the same tumor with different degrees of glandular and neuroendocrine differentiation.³ Torske and Thompson³ have suggested that carcinoids and adenomas of the middle ear are the same tumors. Others believe that middle ear carcinoid has metastatic potential, so it should be considered as a low-grade malignancy.^{6,4}

The differential diagnosis of benign tumors of the middle ear includes middle ear adenoma, paraganglioma, schwannoma, retrotympanic vascular masses, ceruminous gland adenomas, endolymphatic sac tumor, schneiderian-type mucosal papilloma, and lipoma. However, one should also include meningioma, which extends to the middle ear; chronic otitis media; acquired cholesteatoma; and epidermoid. Middle ear ad-

Received November 26, 2008; accepted after revision January 2, 2009.

From the Russell H. Morgan Department of Radiology and Radiological Science (E.Z., D.M.Y.), and Department of Otolaryngology-Head and Neck Surgery (C.J.L.), The Johns Hopkins Hospital, Baltimore, Md; and Division of Surgical Pathology (J.F.K.), Johns Hopkins Medical Institutions, Baltimore, Md.

Please address correspondence to David M. Yousem, MD, MBA, Russell H. Morgan Department of Radiology and Radiological Science, The Johns Hopkins Hospital, 600 N Wolfe St, Phipps B-112, Baltimore, MD 21287; e-mail: dyousem1@jhu.edu



Indicates article with supplemental on-line figure.

DOI 10.3174/ajnr.A1534

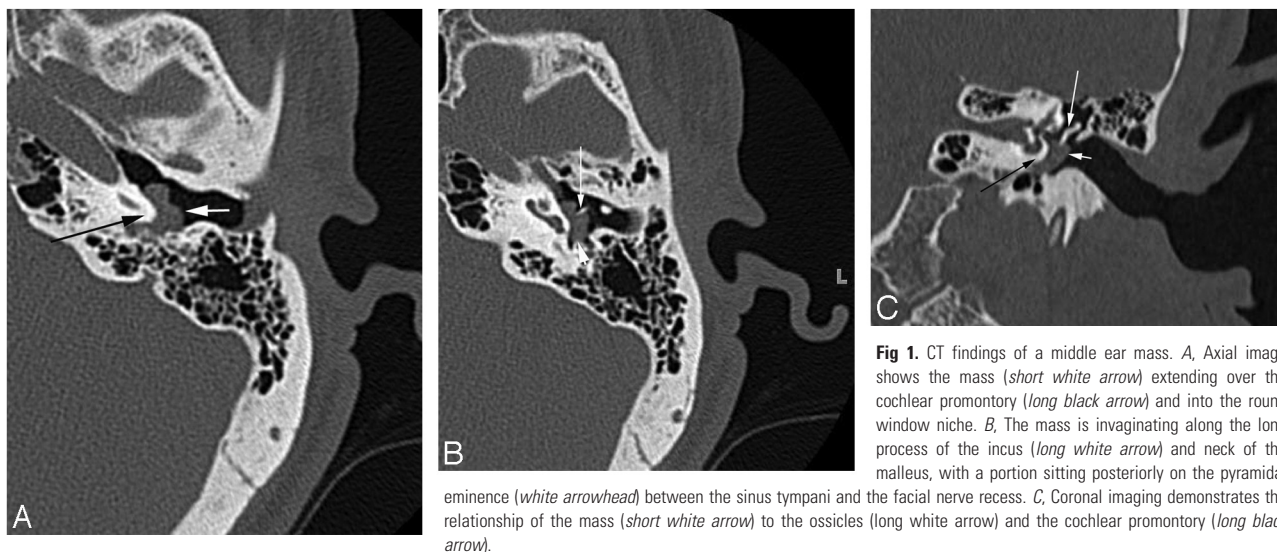


Fig 1. CT findings of a middle ear mass. *A*, Axial image shows the mass (short white arrow) extending over the cochlear promontory (long black arrow) and into the round window niche. *B*, The mass is invaginating along the long process of the incus (long white arrow) and neck of the malleus, with a portion sitting posteriorly on the pyramidal

eminence (white arrowhead) between the sinus tympani and the facial nerve recess. *C*, Coronal imaging demonstrates the relationship of the mass (short white arrow) to the ossicles (long white arrow) and the cochlear promontory (long black arrow).

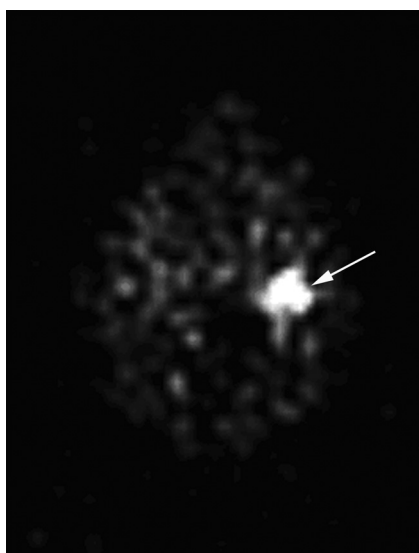


Fig 2. On the octreotide scan, the lesion exhibits avid uptake (arrow), a finding seen in paragangliomas and neuroendocrine tumors of all types.

enomas have a single layer of cuboidal-to-columnar cells and are located in the middle ear. These features differ from those of ceruminous gland adenomas, which are found in the outer ear and contain 2 layers, an inner secretory layer and an outer myoepithelial layer. Differentiation of an endolymphatic sac tumor can be difficult, but it is found in the inner ear and

typically shows bony destruction. Both the ceruminous gland adenoma and endolymphatic sac tumor can extend to the middle ear. Paragangliomas typically display solid nests and a highly vascularized stroma.

Conclusions

Middle ear adenomas are rare benign epithelial tumors deriving from middle ear mucosal cells with both epithelial and neuroendocrine properties. Unfortunately there are no specific imaging findings that indicate the nature of the middle ear tumors. When there is a slow-growing enhancing mass in the middle ear, adenoma should be included in the differential diagnosis.

References

1. Hyams VJ, Michaels L. **Benign adenomatous neoplasm (adenoma) of the middle ear.** *Clin Otolaryngol Allied Sci* 1976;1:17-26
2. Derlacki E, Barney P. **Adenomatous tumors of the middle ear and mastoid.** *Laryngoscope* 1976;86:1123-35
3. Torske K, Thompson L. **Adenoma versus carcinoid tumor of the middle ear: a study of 48 cases and review of the literature.** *Mod Pathol* 2002;15:543-55
4. Michaels L, Soucek S. **Middle ear.** In: Barnes L, Eveson JW, Reichart PA, et al, eds. *Pathology and Genetics of Head and Neck Tumors (WHO Classification of Tumours)*. Lyon, France: IARC Press; 2005:342-50
5. Rosai J. **Disease of middle ear inner ear.** In: *Rosai and Ackerman's Surgical Pathology*. Vol 2. 9th ed. New York: Mosby; 2004: 2776-77
6. Murphy GF, Pilch BZ, Dickerson GR, et al. **Carcinoid tumor of the middle ear.** *Am J Clin Pathol* 1980;73:816-23
7. Ketabchi S, Massi D, Franchi A, et al. **Middle ear adenoma is an amphicrine tumor: why call it adenoma?** *Ultrastruct Pathol* 2001;25:73-78
8. Millis SE, Fechner RE. **Middle ear adenoma: a cytologically uniform neoplasm displaying a variety of architectural patterns.** *Am J Surg Pathol* 1984;8:677-85