



Providing Choice & Value

Generic CT and MRI Contrast Agents



**FRESENIUS
KABI**

CONTACT REP

AJNR

**A New Reference Line for the Brain CT: The
Tuberculum Sellae-Occipital Protuberance
Line is Parallel to the Anterior/Posterior
Commissure Line**

Y.I. Kim, K.J. Ahn, Y.A. Chung and B.S. Kim

This information is current as
of July 7, 2025.

AJNR Am J Neuroradiol 2009, 30 (9) 1704-1708

doi: <https://doi.org/10.3174/ajnr.A1676>

<http://www.ajnr.org/content/30/9/1704>

ORIGINAL
RESEARCH

Y.I. Kim
K.J. Ahn
Y.A. Chung
B.S. Kim

A New Reference Line for the Brain CT: The Tuberculum Sellae-Occipital Protuberance Line is Parallel to the Anterior/Posterior Commissure Line

BACKGROUND AND PURPOSE: CT and MR imaging of the brain have diverged reference lines. Modified Talairach anterior/posterior commissure (ACPC) line is widely accepted as the standard for clinical brain MR imaging, while orbitomeatal line (OML) is used for CT. This study sought to determine an appropriate reference line for brain CT parallel to the ACPC line.

MATERIALS AND METHODS: We measured the angles between the ACPC line and the OML, the line connecting the tuberculum sellae and the internal occipital protuberance (TS-IOP line), and the line connecting the tuberculum sellae and the external occipital protuberance (TS-EOP line) on midsagittal brain MR images of 223 patients. In addition, with the hard palate as the basis, the angles to the ACPC line in the brain MR images and new reference line on the brain CT images from the same patient were measured, and the difference between the 2 angles was calculated in 30 patients. In the same method, the angles to the OML in the brain CT images and the ACPC line on the brain MR images were measured, and their difference was calculated in 30 patients. Then the 2 difference values were compared with verification of the new reference line.

RESULTS: The angles between the ACPC line and both the TS-IOP line ($0.0^\circ \pm 4.0^\circ$) and the TS-EOP line ($0.8^\circ \pm 3.2^\circ$) were significantly smaller than the angles between the ACPC line and the OML ($-12.6^\circ \pm 4.2^\circ$; $P < .05$). In actual scanned images, the angle differences between the TS-OP (TS-IOP + TS-EOP) line and the ACPC line ($0.3^\circ \pm 4.5^\circ$) were statistically smaller than the angles between the OML and the ACPC line ($-6.6^\circ \pm 3.9^\circ$; $P < .05$).

CONCLUSIONS: TS-OP lines are nearly parallel to the ACPC line.

In clinical brain MR imaging, the anterior/posterior commissure (ACPC) line has been widely used as the standard imaging reference line since 1988, when Talairach et al¹⁻³ reported the ACPC line as the reference for co-planar stereotaxis in the human brain.¹⁻³

The original Talairach and Tournoux ACPC line passes through the superior edge of the anterior commissure and the inferior edge of the posterior commissure. It follows a path essentially parallel to the hypothalamus sulcus, thereby dividing the thalamic and the hypothalamic regions.¹ The Talairach ACPC line provides more efficient brain coverage and may lead to more reproducible and readily interpretable clinical brain images.³

With use of CT topography on the basis of x-ray radiography, it is not possible to determine the anterior commissure and posterior commissure, which are anatomic landmarks for the ACPC line. Thus, the ACPC line cannot be used as a reference line for brain CT imaging. As a result, the orbitomeatal line (OML), which connects the outer canthus of the orbit and the center of the external auditory meatus, has been widely used as the traditional imaging reference line in brain CT imaging.

OML is defined by direct visual inspection of the patient and is aligned with a laser on the scanner table because it is based on soft-tissue landmarks. From a historical perspective, this was established as a standard plane for CT scanning of the brain because, in the original water-bath scanners, the chin of the patient had to be placed downward to image the posterior fossa.⁴

The Reid line, or the inferior OML, represents another reference line used when brain CT imaging is performed. This line connects the inferior edge of the orbit and the external auditory meatus. The Reid baseline is often used as the imaging reference line in brain CT scanning, along with the OML.⁴

Because the OML and Reid line do not parallel the ACPC line, the same plane is not viewable by both CT and MR imaging in the same patient, and this nuance makes it very difficult to compare CT and MR images.

Use of OML as the imaging reference line in brain CT scanning has the advantage of allowing for easy identification of the OML in the scout topography. However, at the same time, use of this reference line also presents several disadvantages. For example, there are some patients for whom radiology technologists cannot precisely draw an OML line by using the lateral scout image, in addition to the observation that the posterior fossa may induce beam-hardening artifacts.⁴ Furthermore, because the OML is based on the extracranial skull structure, some problems are expected when this reference is used as a scanning landmark for deep brain structures.⁵

To solve these problems, Weiss et al⁶ suggested a new method of use of an imaging reference line elevated 12° from

Received February 8, 2009; accepted after revision April 22.

From the Department of Radiology (Y.I.K., K.J.A., B.S.K.), Seoul St. Mary's Hospital, College of Medicine, The Catholic University of Korea, Seocho-gu, Seoul, South Korea; and Department of Radiology (Y.A.C.), Incheon St. Mary's Hospital, College of Medicine, The Catholic University of Korea, Boopyung-gu, Incheon, South Korea.

Please address correspondence to Kook Jin Ahn, MD, Department of Radiology, Seoul St. Mary's Hospital, College of Medicine, The Catholic University of Korea, #505 Banpo-dong, Seocho-gu, Seoul, 137-701, South Korea; e-mail: ahn-kj@catholic.ac.kr

DOI 10.3174/ajnr.A1676

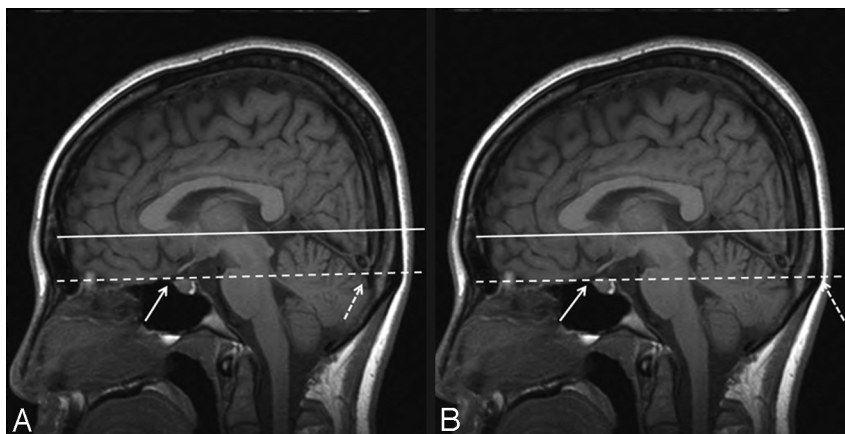


Fig 1. The TS-IOP and TS-EOP lines in the midsagittal T1-weighted image. *A*, The TS-IOP line (dashed line) connects the tuberculum sellae (straight arrow) and the internal occipital protuberance (dashed arrow). The straight line represents the ACPC line that connects the anterior commissure and the posterior commissure. *B*, As shown in *A*, the TS-EOP line (dashed line) connects the tuberculum sellae (straight arrow) and the external occipital protuberance (dashed arrow). The TS-IOP and TS-EOP lines run nearly parallel to the ACPC line.

the hard palate. However, the practical difficulty of using this line for brain CT scanning has prohibited its wide usage.

We have searched for a far more amenable method that would offer a new imaging reference line for brain CT scanning. Because the new imaging reference line runs parallel to the ACPC line, use of this new reference line increases the capacity to make comparisons between brain CT and brain MR imaging.

Materials and Methods

Our study was conducted with 2 primary aims. First, we searched for a landmark that could be used as a new imaging reference line for brain CT. We analyzed this line by measuring the angles between the OML and the ACPC line vs the new reference line and the ACPC line to verify whether the new reference lines were more parallel to the ACPC line than the OML. Second, the superiority of the new reference line in comparison to the OML was analyzed in patients.

The conditions of the new imaging reference line required it to be parallel to the ACPC line in the midsagittal brain MR image. In addition, the line had to be easily visible in the lateral scout image of the brain CT, and it had to be located intracranially to form a reference line that was easily observable by use of scout topography.

From all possible imaging reference lines that satisfy these conditions, the line that extends from the tuberculum sellae to the occipital protuberance in the lateral scout image of the brain CT was selected. Because the skull contains both external and internal occipital protuberances, both the tuberculum sellae-external occipital protuberance (TS-EOP) line and the tuberculum sellae-internal occipital protuberance (TS-IOP) line were considered to be strong candidates as imaging reference lines (Fig 1).

For the purposes of this study, the imaging reference line was the modified Talairach ACPC line that connects the anterior commissure center and the posterior commissure center, rather than the true Talairach ACPC line, which passes through the superior edge of the anterior commissure and the inferior edge of the posterior commissure.⁷ This decision was made because the modified Talairach ACPC line is easier to use in practice, and it reflects the original concept of the Talairach ACPC line.

Angle Measurement

The study received the approval of our institutional review board on May 27, 2006. Because this investigation of angle measurement is a

retrospective review study, it did not require informed consent from the patients.

A total of 245 patients who had brain scans were admitted to the hospital between May 19, 2005, and April 30, 2006, and midsagittal T1-weighted or T2-weighted brain MR images were retrospectively reviewed. Most of the 245 patients had brain MR imaging performed for health promotion screening or because they had complained of a mild headache or dizziness. Patients with any brain pathologic changes (congenital or acquired) that would alter the orientation of the ACPC line or its relationship with the surrounding structures were excluded from the study. A total of 223 patients (109 men and 114 women; age range, 18–88 years; mean age \pm SD, 45.5 \pm 18.8 years) were recruited for the study.

All MR imaging studies were conducted by using 1 of 2 1.5T whole-body MR imaging scanners (Magnetom Vision Plus; Siemens Medical, Erlangen, Germany; and Signa Excite; GE Medical Systems, Milwaukee, Wis) with a 1-channel (Magnetom Vision Plus) or 8-channel (Signa Excite) head coil. Either the sagittal T1-weighted image (TR, 510–570 ms; TE, 14–16 ms; section thickness, 6 mm; number of sections, 19; FOV, 220 \times 220 mm; matrix size, 224–320 \times 512; NEX, 1; acquisition time, 2 min 10 s–2 min 20 s) or the sagittal T2-weighted image (TR, 4000 ms; TE, 100 ms; section thickness, 6 mm; number of sections, 19; FOV, 220 \times 220 mm; matrix size, 224–320 \times 512; NEX, 2; acquisition time, 3 min 2 s–3 min 20 s) was used for the angle measurements.

For each of the 223 midsagittal brain MR images, the angles from the TS-EOP line and the TS-IOP line to the ACPC line were measured to determine the mean angle and SD, respectively. For these measurements, the head extension direction was defined as positive.

These candidate reference lines were compared with the other brain CT imaging reference line, the OML. Thus, the angles from the OML, which was used as the conventional imaging reference line for brain CT imaging, to the ACPC line were measured.

Because the OML could not be viewed in the midsagittal brain MR image, the OML observed in the parasagittal image was projected onto the midsagittal image, and the angle to the ACPC line was subsequently measured.

The differences in the angles among these 3 different lines with respect to the ACPC line were compared by use of the mean value and SD. We obtained all angle measurements using a DICOM viewer (Marosis; Marotech, Seoul, Korea) connected to an applied PACS. To determine whether each mean of the 3 measured angles demonstrated

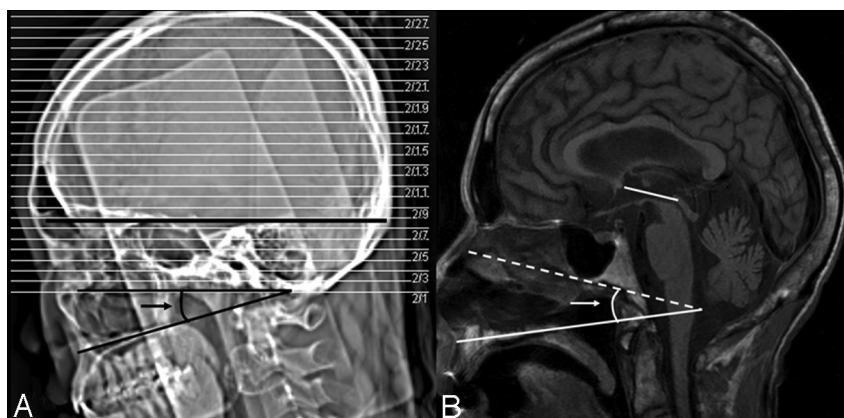


Fig 2. A, Measurement of the angle between the TS-OP line and the hard palate in the lateral scout view of the brain CT (black arrow). B, Measurement of the angle formed by the ACPC line and the hard palate (white arrow) to calculate the angle difference between the TS-OP line and the ACPC line in the midsagittal T1-weighted brain MR image.

significant differences, we conducted statistical analyses using one-way analysis of variance as well as multiple comparisons.

Comparison of Brain CT Scans Based on the New Reference Line and on the OML

We compared brain CT scans based on the TS-OP (TS-IOP + TS-EOP) line with scans based on the OML by using the ACPC line as a reference to verify the superiority of the new brain CT reference line to the previously used OML, and the actual correspondence of the new reference line to the ACPC line during patient scanning. Because these analyses were not retrospective studies, we obtained informed consent from all patients before initiating this set of experiments.

First, the TS-EOP line was set as the imaging reference line for brain CT scanning. When the external occipital protuberance was not easily visible in the lateral scout image, the TS-IOP line with the internal occipital protuberance as a bony landmark was then set as the imaging reference line.

Among the patients who underwent brain MR imaging examination with use of the ACPC reference line, 30 patients (15 men and 15 women; age range, 16–90 years; mean age \pm SD, 52.7 ± 20.3 years) had follow-up brain CT scans performed with the new brain CT protocol with use of the TS-OP line. For comparison, another 30 patients (18 men and 12 women; age range, 21 to 87 years; mean age \pm SD, 55.6 ± 17.8 years) underwent follow-up brain CT with the OML as a reference line instead of the TS-OP line. These patients had previously undergone brain MR imaging examination with the ACPC reference line.

To compare each imaging reference line from the 2 groups, we set the hard palate as the fixed reference structure. This line was easily visualized in the lateral scout image of the brain CT, as well as in the sagittal MR image.

On analysis of the first new reference line group, which used the TS-OP reference line, the difference between the angle of the hard palate to the TS-OP line in the CT topography and the angle of the hard palate to the ACPC line in the T1-weighted sagittal image was calculated for the same patient to determine the angle difference between the TS-OP line and the ACPC line (Fig 2).

Using the same method, we calculated the difference between the angle of the hard palate to the OML in the CT topography, as well as the angle of the hard palate to the ACPC line in the T1-weighted sagittal image in the same patient for the second OML group, in which the OML was used as the reference line.

Statistical *t* tests were then used to determine any significant dif-

Mean and SD of the angle acquired from the reference lines of the 223 midsagittal brain MR images vs the ACPC line*

Reference Lines	Angle Difference to the ACPC Line	SD
TS-EOP line	0.0°	$\pm 4.0^\circ$
TS-IOP line	0.8°	$\pm 3.2^\circ$
OML	-12.6°	$\pm 4.2^\circ$

Note:—ACPC indicates anterior/posterior commissure; TS-EOP, tuberculum sellae and external occipital protuberance; TS-IOP, tuberculum sellae and internal occipital protuberance; OML, orbitomeatal line.

* *P* value: .236 (TS-EOP line vs TS-IOP line), 0 (TS-EOP line vs OML and TS-IOP line vs OML)

ferences between the 2 imaging reference lines (TS-OP line and OML) to the ACPC line.

We acquired all of the brain CT scans using a 64-detector row CT scanner (LightSpeed VCT; GE Healthcare). MR imaging studies were conducted with the same equipment used in the above-mentioned angle measurement study.

Results

Angle Measurement

Analysis of the 223 midsagittal MR images indicated that the mean angle between the TS-EOP line or the TS-IOP line and the ACPC line was $0.0^\circ \pm 4.0^\circ$ and $0.8^\circ \pm 3.2^\circ$, respectively. The mean angle from the OML to the ACPC line was $-12.6^\circ \pm 4.2^\circ$ (Table).

One-way analysis of variance and multiple comparisons revealed a significant difference ($P < .05$) between the TS-OP lines and the OML. However, the angles between the TS-EOP line and the TS-IOP line to the ACPC line did not differ significantly from one another ($P > .05$).

Comparison of Brain CT Scans Based on the New Reference Line and on the OML

For the first new reference line group, which used the TS-OP reference line, the mean difference between the angle of the hard palate to the TS-OP line and the angle of the hard palate to the ACPC line was $0.3^\circ \pm 4.5^\circ$.

In contrast, the mean difference between the angle of the hard palate to the OML and the angle of the hard palate to the ACPC line for the second OML group, which used the OML reference line, was $-6.6^\circ \pm 3.9^\circ$. Thus, the mean angle difference for the new reference line group was significantly smaller than that obtained for the OML group ($P < .05$), and the TS-OP line coincided with the ACPC line very well (Fig 3).

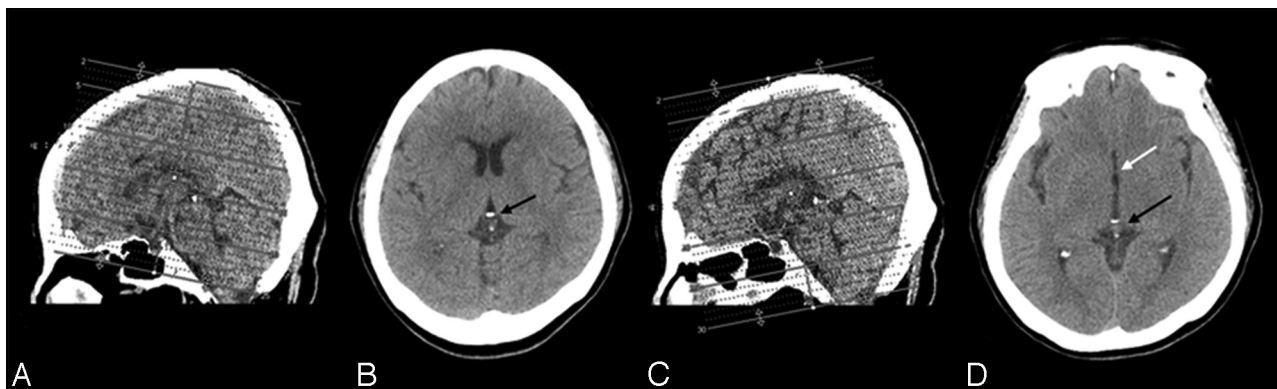

Fig 3. A, Scout topography of OML-based brain CT. B, Brain CT images based on the OML showing only the posterior commissure (black arrow) without inclusion of anterior commissure at the level similar to D. C, Scout topography of TS-OP line-based brain CT showing the scanning reference lines parallel to the line connecting the tuberculum sellae and external occipital protuberance. D, Brain CT image based on the TS-OP line showing both the anterior commissure (white arrow) and posterior commissure (black arrow) at the same level B.

Discussion

Because of the aforementioned disadvantages of using the OML as a reference line for brain CT scanning, several studies have proposed new baselines for brain CT scanning. Shimada⁸ recommended the fronto-occipital pole (FO) line, joining the frontal pole to the occipital pole for observation or measurement of the brain. In 1977, Tokunaga et al⁹ suggested the Glabella-Inion (GI) line as the baseline for brain CT imaging. The GI line was shown to be parallel to the FO line, which was substituted for a line joining the deepest gyral impressions in the frontal and occipital parts of the cranial cavity.

In 1991, Rozeik et al¹⁰ suggested using a line that was 5° lower than the Reid baseline as the imaging reference line for brain CT imaging. The Reid baseline is often called the inferior orbitomeatal line, and it connects the inferior edge of the orbit to the external auditory meatus.⁵ The Reid baseline is often used as the imaging reference line in brain CT imaging, along with the OML. Use of a line that is 5° lower than the Reid baseline as an imaging reference line minimizes interpetrous artifacts.

However, because these reference lines do not run parallel to the ACPC line, obtaining brain CT images parallel to the ACPC line would be very difficult. It is important to note that brain CT images cannot be compared with MR images, as described above.

To solve this problem, Weiss et al⁶ suggested slanting the line 12.0° upward from the hard palate as a baseline for brain CT imaging techniques. According to their results, a line slanted 12.0° upward from the hard palate corresponds to the ACPC line ($\pm 6.1^\circ$); thus, the same axial section image could be acquired by brain CT scanning and MR imaging techniques.

However, use of the hard palate as a landmark can introduce problems, as the hard palate is located at an anatomically distal position to the ACPC line and because the hard palate lies outside of the intracranial cavity, where the brain is located. In addition, it may not be feasible to use a line slanted 12.0° upward from the hard palate as the reference line for brain CT scanning.

In our study, we screened candidates for a new brain CT reference line that would produce axial CT images comparable with the axial brain MR images. We found that the line connecting the tuberculum sellae, which is an elevation located

behind the chiasmatic groove in the sphenoid bone and the occipital protuberance, was parallel to the ACPC line. There are 2 types of occipital protuberance: the internal occipital protuberance indicates the point of intersection of the 4 divisions of the cruciate eminence in the occipital bone, and the external occipital protuberance indicates a bony protuberance located near the middle of the occipital squama.

Our analysis indicated that this line was an appropriate and practical reference line for brain CT scanning. It is noteworthy that the tuberculum sellae and occipital protuberance were easily visible in the lateral scout image of the brain CT image.

The angle formed by either the TS-EOP line or the TS-IOP line and the ACPC line was significantly smaller than that formed by the OML and the ACPC line. The new reference lines and conventional OML were then used for brain CT imaging, and they were compared with the ACPC line in MR images from the same patient. These comparisons revealed that the new reference line for the brain CT image was significantly closer to being parallel with the ACPC line than was the currently used OML.

A direct comparison of the new reference line, the TS-OP line, with the reference line, as suggested by Weiss et al,⁶ was not performed. In their study, the brain MR imaging reference line approximated with the brain CT prescription was the original Talairach ACPC line. However, the modified Talairach ACPC line was used as the reference line in our study. From a technical perspective, comparison of these 2 reference lines was difficult. Thus, a comparison of the TS-OP line with the OML commonly used in practice was performed.

Use of the TS-EOP line or the TS-IOP line as the imaging reference line for brain CT scanning allowed us to acquire brain CT images that were parallel to the ACPC line, which is widely used in brain MR imaging. The use of these new reference lines in brain CT imaging should therefore allow straightforward comparisons between CT and MR imaging of the brain for the same patient or for group analyses.

Hence, comparisons of the results of the 2 imaging methods in the detection of cerebral lesions should be far easier with axial images in which the anatomic locations are unambiguous, as well as in functional brain studies such as perfusion CT and CT angiography, which can now be compared and overlapped with images obtained from brain MR imaging with fewer limitations.

Moreover, because the images are parallel to one another, it is more feasible and more accurate to fuse the CT and MR imaging images and to delineate the target volume exactly on the basis of intensity-modulated radiation therapy or 3D conformal radiation therapy.¹¹ This new baseline can also be used for image-guided therapy with use of CT or CT with MR fusion.¹²

However, in everyday practice, MR imaging and CT section planes are frequently not performed in an identical fashion because the goals of a routine CT scan include images of the sinuses and orbital structures, and images used in 3D image postprocessing. In addition, technical limitations exist in the implementation of spiral CT with angled gantry.

Moreover, there are also disadvantages to having the same-section plane for CT and MR imaging with use of our new reference line. First, the lenses of the eyes are included in the radiation field in their entirety when performing an examination of the whole-brain CT scan. Second, the spiral volume CT examination cannot be performed because of gantry angulation. However, the second issue can be overcome by 3D postprocessing software, which is now commercially available and is installed in most CT equipment for reconstruction of brain CT images parallel to the ACPC line from 0° gantry angulation spiral images.

With regard to CT/positron-emission tomography (PET) images, the new reference line can play a pivotal role in generating comparable brain CT/PET images with respect to the brain MR imaging. After routine 0° angulation images of the brain CT and PET images are obtained, brain CT and PET images that are parallel to the ACPC line can be created with use of the multiplanar reconstruction method, with our TS-OP line as the reference.

It is inevitable that some patients will present for whom it is difficult to view the external occipital protuberance in the lateral scout image. In such cases, the TS-IOP line was used as the imaging reference line. Use of either of these 2 lines as a reference line for brain CT imaging should not create problems for brain CT imaging. Our study detected very minor differences in the angles formed by the TS-EOP line or the TS-IOP line

and the ACPC line. Moreover, both of these lines were significantly closer to being parallel with the ACPC line than the OML or other brain CT reference lines that have been previously proposed.

Conclusions

The TS-EOP and TS-IOP lines for brain CT imaging are nearly parallel with the modified Talairach ACPC line used for performing brain MR imaging, and both can easily be used as a reference line in brain CT scanning.

Use of the TS-EOP or TS-IOP line as a brain CT reference line should facilitate easier and more precise comparisons of brain CT images with brain MR images in numerous clinical situations.

References

1. Talairach J, Tournoux P. *Co-Planar Stereotaxic Atlas of the Human Brain*. New York: Thieme; 1988:122
2. Weiss KL, Dong Q, Weadock WJ, et al. **Multiparametric color-encoded brain MR imaging in Talairach space**. *Radiographics* 2002;22:e3
3. Weiss KL, Pan H, Storrs J, et al. **Clinical brain MR imaging prescriptions in Talairach space: technologist- and computer-driven methods**. *AJNR Am J Neuroradiol* 2003;24:922–29
4. Yeoman LJ, Howarth L, Britten A, et al. **Gantry angulation in brain CT: dosage implications, effect on posterior fossa artifacts, and current international practice**. *Radiology* 1992;184:113–16
5. Gao FQ, Black SE, Leibovitch FS, et al. **A reliable MR measurement of medial temporal lobe width from the Sunnybrook Dementia Study**. *Neurobiol Aging* 2003;24:49–56
6. Weiss KL, Storrs J, Weiss JL, et al. **CT brain prescriptions in Talairach space: a new clinical standard**. *AJNR Am J Neuroradiol* 2004;25:233–37
7. Nowinski WL. **Modified Talairach landmarks**. *Acta Neurochir (Wien)* 2001;143:1045–57
8. Shimada K. *The Brain of Japanese. Lectures on Anthropology and Archaeology*. Tokyo: Yuzankaku; 1939:1–188
9. Tokunaga A, Takase M, Otani K. **The glabella-inion line as a baseline for CT scanning of the brain**. *Neuroradiology* 1977;14:67–71
10. Rozeik C, Kotterer O, Preiss J, et al. **Cranial CT artifacts and gantry angulation**. *J Comput Assist Tomogr* 1991;15:381–86
11. Sato S, Ohye C, Shibasaki T, et al. **Neurophysiological evaluation of the optimum target in gamma thalamotomy: indirect evidence**. *Stereotact Funct Neurosurg* 2005;83:108–12
12. diPierro CG, Francel PC, Jackson TR, et al. **Optimizing accuracy in magnetic resonance imaging-guided stereotaxis: a technique with validation based on the anterior commissure-posterior commissure line**. *J Neurosurg* 1999;90:94–100