



Efficacy and Safety of Ethanol Ablation for Thyroglossal Duct Cysts

S.M. Kim, J.H. Baek, Y.S. Kim, J.Y. Sung, H.K. Lim, H. Choi and J.H. Lee

AJNR Am J Neuroradiol 2011, 32 (2) 306-309

doi: <https://doi.org/10.3174/ajnr.A2296>

<http://www.ajnr.org/content/32/2/306>

This information is current as
of June 19, 2025.

ORIGINAL RESEARCH

S.M. Kim
J.H. Baek
Y.S. Kim
J.Y. Sung
H.K. Lim
H. Choi
J.H. Lee

Efficacy and Safety of Ethanol Ablation for Thyroglossal Duct Cysts

BACKGROUND AND PURPOSE: TGDC is a common congenital neck lesion, which has been treated by surgery. Although surgery is curative, it has drawbacks such as scars and surgical morbidity. Therefore, we applied EA as an alternative treatment technique. The purpose of this study was the evaluation of the efficacy and safety of EA for TGDC.

MATERIALS AND METHODS: Between May 2005 and July 2008, we performed EA in 11 patients with TGDC who refused surgery. All patients were confirmed as having benign lesions before treatment. US-guided aspiration of the cystic fluid was followed by injection of absolute ethanol (99%). The injected volume of ethanol was 50%–80% of the volume of fluid aspirated. We evaluated the therapeutic outcome, including volume reduction of the TGDC, improvement of cosmetic problems and symptoms, and complications.

RESULTS: The initial volume of the cysts ranged from 0.67 to 29.39 mL (mean, 6.0 mL). The procedure was performed in 1–3 sessions (mean, 1.4 sessions). Follow-up US was performed in 10 patients from 3 to 29 months (mean, 13.6 months). The mean volume of the cyst was 6.0 ± 8.4 mL, and volume reduction was 43.9%–100% (mean, 81.3%, $P = .005$) at last follow-up. Therapeutic success (volume reduction of $>50\%$) was observed in 8 patients (8/10, 80%). Significant improvement of symptom ($P = .005$) and cosmetic-grading scores ($P = .003$) was observed at last follow-up. No significant complications were observed during the procedure or follow-up periods.

CONCLUSIONS: EA seems to be an effective and safe treatment method for TGDC.

ABBREVIATIONS: EA = ethanol ablation; FNA = fine-needle aspiration; NA = not available; TGDC = thyroglossal duct cyst; US = ultrasonography; V = volume; VR = volume reduction

T GDC is the most common form of congenital neck cyst and usually presents as a midline neck lump.^{1–3} Patients with TGDC have various problems such as cosmetic concerns, difficulty in breathing, pain, swelling, neck discomfort, and dysphasia. Therefore, surgery has been considered the treatment of choice in this condition.^{2–4}

The simple cyst excision method for TGDC has shown a high recurrence rate of 40%–65%.^{1–6} The recurrence rate could be reduced to 2.6%–5% by the Sistrunk procedure^{2,4,7}; however, surgery still has some drawbacks such as the use of general anesthesia, scars, and surgical morbidity.^{1,2,4–7} Therefore, minimally invasive treatment modalities have the potential to benefit these patients without surgical risk and morbidity.

EA is effective, easy, and safe for the treatment of cystic thyroid lesions.^{8–12} While most previous studies focused on thyroid cysts, only a few cases of TGDC have been reported.^{13,14} Our thyroid team has applied EA to thyroid cysts and TGDC for several years. The purpose of this study was to assess the technical feasibility and evaluate the efficacy and safety of EA for TGDC.

Materials and Methods

Patients

From May 2005 to July 2008, 25 patients were referred to the thyroid center for treatment of TGDC, and a total of 14 patients underwent EA for TGDC. Eleven of these patients (male/female = 3:8; mean age, 34.9 years; range, 23–44 years) were enrolled because they fulfilled the following criteria: cosmetic concerns and/or symptomatic problems such as pain, swelling, discomfort, or dysphasia; a single clinically palpable midline mass in the anterior aspect of the neck that was diagnosed as a benign lesion; a cystic component of $>90\%$ of the total nodule volume; refusal of surgery; TGDC recurring after aspiration of the internal content in at least 2 separated sessions; and follow-up for >3 months.

At enrollment and at each evaluation, patients were asked to rate pressure symptoms on a centimeter visual analog scale as a symptom-grading score (0–10). The physician performed cosmetic grading (grade 1, no palpable mass; grade 2, invisible but palpable mass; grade 3, mass visible only to an experienced clinician; grade 4, easily visible mass). This retrospective study was approved by the institutional review board. Written informed consent was obtained from all patients before the procedure.

Preprocedural Assessment

US, FNA, and clinical concerns were evaluated for all patients before EA. Two radiologists (J.H.B. and Y.S.K.) performed the US for evaluation of nodule characteristics and FNA. We used a 10-MHz linear probe on a real-time US system (Prosound SSD-5000, Aloka, Tokyo, Japan; Aplio SSA-770A, Toshiba Medical Systems, Tokyo, Japan). The nodule volume was calculated with the following equation: $V = \pi abc / 6$, where V is volume; a , the largest diameter; and b and c , the other 2 perpendicular diameters. FNA was preformed at least 2 sepa-

Received April 15, 2010; accepted after revision July 25.

From the Department of Radiology and Research Institute of Radiology (S.M.K., J.H.B., H.K.L., J.H.L.), University of Ulsan College of Medicine, Asan Medical Center, Seoul, Korea; and Departments of Radiology (J.H.B., Y.S.K., J.Y.S.) and Surgery (H.C.), Thyroid Center, Daerim St. Mary's Hospital, Seoul, Korea.

Please address correspondence to Jung Hwan Baek, MD, Department of Radiology and Research Institute of Radiology, University of Ulsan College of Medicine, Asan Medical Center, 388-1 Poongnap-2dong, Songpa-gu, Seoul, 138-736, Korea; e-mail: radbaek@naver.com

DOI 10.3174/ajnr.A2296

Table 1: Summary of initial characteristics, locations, and changes of TGDCs before and after the procedure

No.	Sex	Age (yr)	Location	Index V (mL)	Aspiration V (mL)	V of Ethanol (mL)	Treatment Sessions	Vol (mL) at Follow-Up			Last	VR (%)
								0–6 Months	7–12 Months	12–29 Months		
1	F	30	Suprahyoid	4.83	4	3	1	0.08			0.08	98.3
2	M	40	Suprahyoid	0.67	0.5	0.1	3		0.44	0.28	0.28	58.0
3	F	35	Suprahyoid	0.69	0.5	0.3	1	0.43		0.01	0.01	98.2
4	F	44	Suprahyoid	1.43	1	0.2	2	0.58	1.00	0.80	0.80	43.9
5	F	30	Infrahyoid	2.04	2	0.5	1			0	0	100.0
6	F	30	Infrahyoid	4.15	2	1	2	1.28	0.41	0.27	0.27	93.5
7	M	23	Suprahyoid	1.39	1	0.2	1		0.44	0.71	0.71	48.8
8	F	33	Suprahyoid	11.23	8	4	1	0.04			0.04	99.7
9	M	39	Combined	29.39	25	10	1				NA	NA
10	F	41	Suprahyoid	7.46	3	2	1	2.62		1.08	1.08	85.5
11	F	39	Infrahyoid	2.76	3	1	1	1.62	0.35		0.35	87.5
Mean		34.9 ± 6.3		6.0 ± 8.4	4.6 ± 7.1	2.0 ± 2.9	1.4 ± 0.7	0.95 ± 0.94	0.50 ± 0.27	0.45 ± 0.42	0.36 ± 0.38	81.3 ± 22.3

rate times in all patients. During FNA, we aspirated the internal fluid as much as possible by using a 21-ga needle; then FNA was performed in the solid portion and/or cyst wall. An experienced thyroid cytologist reviewed the FNA slide carefully.

Procedure

EA was performed by the same radiologists (J.H.B. and Y.S.K.), with the patient in the supine position with mild neck extension. After skin sterilization with 70% ethanol, a 21-ga needle was inserted into the cyst and connected to a 10-mL syringe. To prevent leakage of ethanol, we performed the needle puncture at the most nondependent portion of the lesion; then, we aspirated the internal content. If aspiration of the internal content was not feasible, we exchanged the 21-ga needle for a large-bore needle (16- or 14-ga needle) and connected it to a 50-mL syringe or suction pump (Aspiratore SP 30; Markos-Mefar, Bovezzo, Italy).¹² After aspiration of the cystic content as much as possible, we performed irrigation of the cyst wall by using normal saline to remove debris or viscous materials coating the inner wall of the cyst. Then 99% sterile ethanol was injected through the same needle. The amount of injected ethanol was approximately 50%–80% of the aspirated fluid. When leakage of ethanol through the puncture site was suggested on real-time US, ethanol injection was stopped. After 10 minutes with the needle in place, the injected ethanol was removed completely. Then the needle was withdrawn, and the patient remained under observation for 30 minutes. Additional EA was performed when the cosmetic score had not improved (cosmetic grading score, 3–4) and/or symptomatic problems (symptomatic grading score, >3) were incompletely resolved during the follow-up period.

Follow-Up

The clinical symptoms and US examination were re-evaluated at 1-, 3-, 6-, and 12-month follow-up examinations after EA. We evaluated the efficacy of EA by measuring the volume reduction of the treated nodules and by checking the improvement of symptomatic and cosmetic problems. The technical success of EA was defined by volume reduction of >50%. We also checked any adverse events during the procedure and follow-up period to assess complications of EA.

Statistical Analysis

Statistical analysis was performed with the Statistical Package for the Social Sciences software, Version 12.0 (SPSS, Chicago, Illinois). The Wilcoxon signed rank test was used to compare nodule volumes, symptom grading scores, and cosmetic grading scores before and after EA. The level of significance was defined as $P < .05$.

Table 2: Therapeutic efficacy by symptom scores and cosmetic scores, before and after the procedure^a

No	Initial Score		Last Score	
	Symptom	Cosmetic	Symptom	Cosmetic
1	5	4	1	1
2	3	4	2	3
3	3	4	0	1
4	3	4	1	3
5	4	3	0	1
6	5	4	0	1
7	3	4	3	2
8	5	4	0	1
9	5	4	0	1
10	5	4	0	1
11	3	4	1	1
Mean	4.0 ± 1.0	3.9 ± 0.3	0.7 ± 1.0	1.5 ± 0.8

^a Patients rated symptom scores on a visual analog scale of 0–10. Physicians evaluated the cosmetic grade as grade 1, no palpable mass; grade 2, invisible but palpable mass; grade 3, mass visible only to an experienced clinician; and grade 4, easily visible mass. Initial status versus last examination of symptom scores ($P = .005$). Initial status versus last examination of cosmetic grades ($P = .003$).

Results

Initial characteristics, locations, and changes in volume of TGDC are summarized in Table 1. Cosmetic- and symptom-grading scores before the procedure and at last follow-up examination are summarized in Table 2. Regarding the location of TGDCs, 7 cases were suprahyoid (Fig 1), 3 were infrahyoid (Fig 2), and 1 was a combined (suprahyoid and infrahyoid) type. Six cases of TGDC had viscous internal contents, and the others had bloody internal contents.

Evaluation of the cosmetic- and symptom-grading scores was available in all 11 patients. However US examinations were available in 10 patients because 1 patient (patient 9) refused US examination at follow-up because of improved symptoms.

The mean index volume of TGDC was 6.0 ± 8.4 mL (range, 0.67–29.39 mL). The mean volume of the aspirated internal content was 4.6 ± 7.1 mL (range, 0.5–25 mL), and the mean aspirated volume was 76.6% of the initial volume. The mean amount of ethanol injected was 2.0 ± 2.9 mL (range, 0.1–10 mL), which was 45% of the aspirated volume. We performed EA in only 1 session in 8 patients, in 2 sessions in 2 patients, and in 3 sessions in 1 patient. The mean number of ablation sessions was 1.4 ± 0.7 (range, 1–3).

The mean clinical follow-up period of 11 patients was

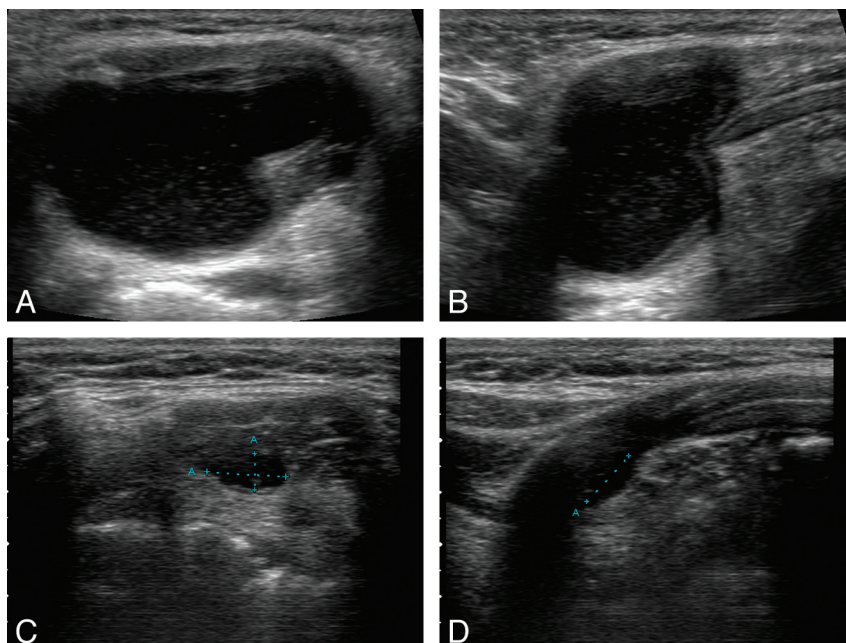


Fig 1. A 41-year-old woman (patient 10). Axial (A) and longitudinal (B) sonograms show the TGDC in a suprahyoid location ($2.0 \times 2.3 \times 3.1$ cm; volume, 7.46 mL) filled with fluid. Axial (C) and longitudinal (D) sonograms obtained 13 months after EA show marked shrinkage of the TGDC. ($0.35 \times 0.6 \times 0.76$ cm; volume, 1.08 mL; volume reduction, 85.5%)

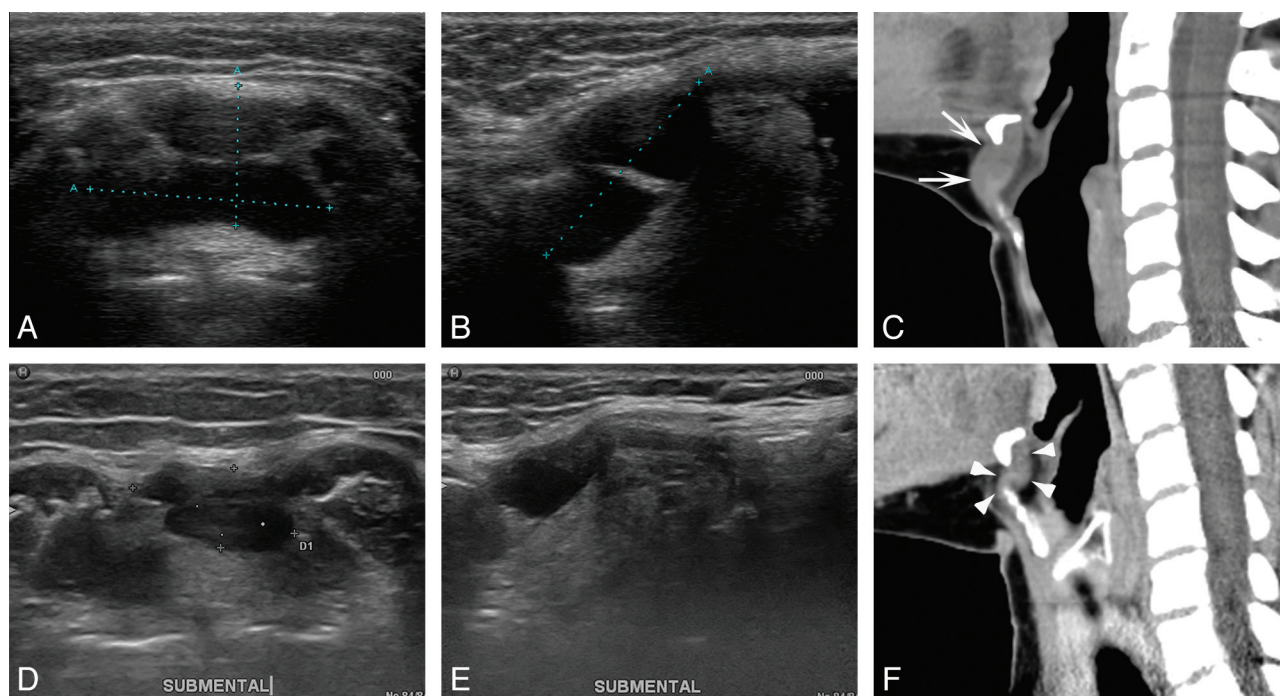


Fig 2. A 39-year-old woman (patient 11). Axial (A) and longitudinal (B) sonograms show a multiloculated TGDC in an infrahyoid location ($1.2 \times 2.0 \times 2.2$; volume, 2.76 mL). Sagittal CT scan (C) shows that the TGDC wraps around the hyoid bone (arrows). Axial (D) and longitudinal (E) sonograms and a sagittal CT scan (F) obtained 11 months after EA. Arrowheads indicate shrinkage of the TGDC ($0.66 \times 0.85 \times 1.18$; volume, 0.35 mL; volume reduction, 87.5%).

14.4 ± 6.9 months (range, 3–29 months). The mean follow-up period of 10 patients who underwent US examinations was 13.6 ± 8.1 months (range, 3–29 months). The mean volume reductions at 0–6, 6–12, 12–29 months, and last follow-up examinations were $67.3\% \pm 24.6\%$, $62.1\% \pm 28.5\%$, $75.4 \pm 24.3\%$, and $81.3\% \pm 22.3\%$, respectively. Technical success (volume reduction of $>50\%$ in US examination) was achieved in 8 of 10 patients (Figs 1 and 2). At last follow-up examinations, the volume of the treated TGDCs had decreased signif-

icantly from 6.0 ± 8.4 mL to 0.36 ± 0.38 mL ($P = .005$). Also the mean symptoms and cosmetic-grading scores had improved significantly from 4.0 ± 1.0 to 0.7 ± 1.0 ($P = .005$) and from 3.9 ± 0.3 to 1.5 ± 0.8 ($P = .003$), respectively.

Repeat EA was performed in 3 patients (3/11, 27%). All patients had a cosmetic grading score of 4 and a symptomatic grading score of >3 . One showed improvement after the second treatment, and 2 actually had residual clinical symptoms and cosmetic problems. Three patients with a suprahyoid-

type TGDC had incompletely resolved clinical problems (Table 2). Among them, 1 patient (patient 7) re-presented with recurrent symptoms at 13 months after EA. No complications such as hematoma, infection, skin necrosis, or vocal cord palsy were encountered, but mild pain related to the procedure occurred.

Discussion

This study demonstrated that EA was effective and safe for patients with TGDC who refused surgery. The volume of TGDC and patients' clinical problems improved significantly without major complications.

TGDC is the most common congenital neck mass, which arises from remnants of the embryonic thyroglossal duct from the base of the tongue to the thyroid isthmus.^{2,5,15,16} TGDCs have been detected in 7% of the overall population and are commonly located in the midline infrahyoid position (61%) between the thyroid gland and the hyoid bone.^{15,16} After Sistrunk¹⁷ described the classic surgical management, the recurrence rate of TGDC after surgery decreased significantly.^{2,4,7} However, surgery still has complications, including general anesthesia, surgical morbidity, and scars.^{2,4-7} Because of the drawbacks of surgery, a nonsurgical minimally invasive alternative treatment technique for TGDC has been needed.

In a Medline search, minimally invasive therapy for TGDC has been reported by using picibanil (OK-432) or ethanolamine oleate. The main advantages of minimally invasive therapy are low morbidity and complication rates.^{13,14,18} Kim et al¹⁸ described OK-432 therapy for TGDC, and the success rate was found to be 45.5% (5/11) without significant complications. Previous reports of EA for TGDC indicated that successful treatment was achieved in 60% of patients.^{13,14} These reports enrolled only 5 patients and showed relatively lower success rates than those of our study (80%). Baskin¹³ reported that the viscous internal content of the TGDC was difficult to aspirate. Therefore, injection of ethanol was difficult, and injected ethanol had insufficient contact with the inner surface of the cyst. Hence, they used a large-bore 14-ga needle in case of a mucus-like fluid cyst. Fukumoto et al¹⁴ tried gentle massage by hand to ensure that the ethanol would come into contact with inner surface of the cyst. In our study, 6 cases of TGDC had a viscous internal content; however, we nearly completely aspirated the viscous content by changing the 21-ga needle for a large-bore needle (16- or 14-ga needle) as our team had proposed in a previous study.¹² Then we performed saline irrigation to remove viscous material coating the cyst wall. Those techniques may have improved technical success rate in this study.

Three patients had incompletely resolved clinical problems at last follow-up. The cause of incomplete treatment is unclear; however, we suggest that it may be related to the long embryonic pathway of the TGDC, which occurs from the foramen cecum of the tongue base to the thyroid bed.^{2,5,15,16} Because of their anatomic association with the oral cavity, TGDCs are prone to infection and recurrence. Up to one-third of patients present with a concurrent or previous history of infection in the cyst.¹⁹

Repeat EA showed low efficacy in this study. Among 3 patients with repeat EA, 2 (67%) had technical failure. This study result was similar to that for thyroid cysts by Bennedbaek and

Hegedus.⁸ They performed EA for 33 thyroid cysts: Twenty-one patients were cured after the first EA; 4, after the second EA; and 2, after the third EA. On the basis of their results, the efficacy of EA would be markedly decreased by repeating EA (ie, from 63.6%, 33.3%, and finally to 25%). We also found the treatment efficacy of repeat EA for TGDC to be decreased, as in EA for thyroid cysts. Baskin¹³ also reported recurrence after 3 sessions of EA.

Kim et al¹⁸ reported that transient mild local pain and low-grade fever were observed, but there were no significant treatment-related complications. In their study, some patients complained of mild pain and discomfort related to needle puncture; however, there were no significant complications.

The present study had the following limitations: First, the mean follow-up period (14.4 ± 6.9 month) was relatively short. Second, only 11 patients were enrolled. Further study on a larger scale will be necessary.

In conclusion, EA seems to be an effective and safe alternative treatment method for the patients with TGDC who refuse surgery.

Acknowledgments

We thank to Haengil Im and Bonnie Hami, MA, for their editorial assistance in preparing the manuscript.

References

- Mondin V, Ferlito A, Muzzi E, et al. **Thyroglossal duct cyst: personal experience and literature review.** *Auris Nasus Larynx* 2008;35:11–25
- Hirshoren N, Neuman T, Udassin R, et al. **The imperative of the Sistrunk operation: review of 160 thyroglossal tract remnant operations.** *Otolaryngol Head Neck Surg* 2009;140:338–42
- Shah R, Gow K, Sobol SE. **Outcome of thyroglossal duct cyst excision is independent of presenting age or symptomatology.** *Int J Pediatr Otorhinolaryngol* 2007;71:1731–35
- Perkins JA, Inglis AF, Sie KC, et al. **Recurrent thyroglossal duct cysts: a 23-year experience and a new method for management.** *Ann Otol Rhinol Laryngol* 2006;115:850–56
- Myer CM, Cotton RT. **Congenital thyroid cysts and ectopic thyroid.** In: Falk SA, ed. *Thyroid Disease: Endocrinology, Surgery, Nuclear Medicine and Radiotherapy.* New York: Raven Press; 1990:381–88
- Ostlie DJ, Burjonrappa SC, Snyder CL, et al. **Thyroglossal duct infections and surgical outcomes.** *J Pediatr Surg* 2004;39:396–99, discussion 396–99
- Bennett KG, Organ CH, Williams GR. **Is the treatment for thyroglossal duct cysts too extensive?** *Am J Surg* 1986;152:602–05
- Bennedbaek FN, Hegedus L. **Treatment of recurrent thyroid cysts with ethanol: a randomized double-blind controlled trial.** *J Clin Endocrinol Metab* 2003;88:5773–77
- Del Prete S, Caraglia M, Russo D, et al. **Percutaneous ethanol injection efficacy in the treatment of large symptomatic thyroid cystic nodules: ten-year follow-up of a large series.** *Thyroid* 2002;12:815–21
- Lee SJ, Ahn IM. **Effectiveness of percutaneous ethanol injection therapy in benign nodular and cystic thyroid diseases: long-term follow-up experience.** *Endocr J* 2005;52:455–62
- Zingrillo M, Torlontano M, Chiarella R, et al. **Percutaneous ethanol injection may be a definitive treatment for symptomatic thyroid cystic nodules not treatable by surgery: five-year follow-up study.** *Thyroid* 1999;9:763–67
- Sung JY, Baek JH, Kim YS, et al. **One-step ethanol ablation of viscous cystic thyroid nodules.** *AJR Am J Roentgenol* 2008;191:1730–33
- Baskin HJ. **Percutaneous ethanol injection of thyroglossal duct cysts.** *Endocr Pract* 2006;12:355–57
- Fukumoto K, Kojima T, Tomonari H, et al. **Ethanol injection sclerotherapy for Baker's cyst, thyroglossal duct cyst, and branchial cleft cyst.** *Ann Plast Surg* 1994;33:615–19
- Allard RH. **The thyroglossal cyst.** *Head Neck Surg* 1982;5:134–46
- Topf P, Fried MP, Strome M. **Vagaries of thyroglossal duct cysts.** *Laryngoscope* 1988;98:740–42
- Sistrunk WE. **The surgical treatment of cysts of the thyroglossal tract.** *Ann Surg* 1920;71:121–22
- Kim MG, Kim SG, Lee JH, et al. **The therapeutic effect of OK-432 (picibanil) sclerotherapy for benign neck cysts.** *Laryngoscope* 2008;118:2177–81
- Foley DS, Fallat ME. **Thyroglossal duct and other congenital midline cervical anomalies.** *Semin Pediatr Surg* 2006;15:70–75