



## Get Clarity On Generics

Cost-Effective CT & MRI Contrast Agents



FRESENIUS  
KABI

WATCH VIDEO

# AJNR

## Patterns of Regional Spread for Esthesioneuroblastoma

M.C. Howell, B.F. Branstetter IV and C.H. Snyderman

*AJNR Am J Neuroradiol* 2011, 32 (5) 929-933

doi: <https://doi.org/10.3174/ajnr.A2401>

<http://www.ajnr.org/content/32/5/929>

This information is current as  
of August 14, 2025.

M.C. Howell  
B.F. Branstetter IV  
C.H. Snyderman

# Patterns of Regional Spread for Esthesioneuroblastoma

**BACKGROUND AND PURPOSE:** ENB is a rare malignant neoplasm that affects the anterior skull base. Disease stage is a significant predictor of survival, in particular the presence or absence of lymph node metastases. Multiple studies have identified the cervical lymph nodes as the most frequent site of spread; however, no studies have attempted to characterize the radiographic appearance of metastatic lymph nodes or identify the primary nodal drainage for these tumors.

**MATERIALS AND METHODS:** We retrospectively reviewed the medical records and imaging examinations of patients with a pathologically proved diagnosis of ENB from a single tertiary care institution from 2004 to 2010. A head and neck radiologist with 9 years of experience in evaluating ENB reviewed the imaging of all patients with lymph node metastases to confirm the lymph node findings.

**RESULTS:** Spread of ENB to cervical lymph nodes was discovered in 14/48 patients (29%). Of the 14 patients, 5 (36%) were discovered to have lymph node involvement at initial staging, while 9 (64%) showed development of disease in the cervical nodes on surveillance examinations. Level II lymph nodes were the most frequently involved (13/14 cases). Levels I (57%) and III (50%) nodes and RPNs (43%) were also frequently involved. Metastatic lymph nodes were predominantly solid and demonstrated marked contrast enhancement, often approaching the degree of enhancement of nearby blood vessels. Metastatic nodes were moderately or highly FDG-avid.

**CONCLUSIONS:** ENB exhibits a predictable pattern of metastasis to cervical lymph nodes, typically spreading first to level II nodes, with frequent involvement of level I and III nodes and RPNs. Metastatic lymph nodes have characteristic imaging features that can assist radiologists in the identification of nodal disease.

**ABBREVIATIONS:** ENB = esthesioneuroblastoma; FDG = fluorodeoxyglucose; PET/CT = combined positron-emission tomography/CT; RPN = retropharyngeal lymph node; TNM = tumor-node-metastasis

ENB, also known as olfactory neuroblastoma, is a malignant neoplasm of neuroectodermal origin. It is believed to arise from the olfactory epithelium lining the upper third of the nasal septum, the cribriform plates, and the superior turbinates.<sup>1</sup> First described by Berger et al in 1924,<sup>2</sup> ENB is a rare tumor, accounting for only 3%–6% of intranasal cancers.<sup>3,4</sup> As such, much about its biology, clinical behavior, and optimal treatment remains poorly understood.

ENB presents clinically with unilateral nasal obstruction or epistaxis. While often indolent, it is nonetheless aggressive, characterized by local invasion as well as regional and distant metastases. Local invasion occurs most frequently into the paranasal sinuses, orbits, and anterior cranial fossa. Metastases most frequently involve the cervical lymph nodes, with distant metastasis reported to the lungs, liver, and bone.<sup>3,5,6</sup> There is no universally accepted staging system, but several have been proposed. Kadish et al<sup>5</sup> developed the first and most widely used system, but it has been criticized for requiring surgical staging, lacking prognostic value, and not incorporating metastatic spread. The modified Kadish staging system includes a fourth stage for patients with nodal or distant metastases.<sup>7</sup> The Dulguerov staging system uses the TNM classification and incorporates imaging data, thus allowing staging

of patients treated with chemoradiation or otherwise deemed inoperable.<sup>6</sup>

Disease stage on diagnosis, in particular the presence or absence of lymphatic spread, has been shown to be a significant predictor of survival.<sup>4,6,8</sup> Multiple studies have identified the cervical lymph nodes as the most common site of spread, but no studies have attempted to characterize lymphatic spread in the neck.<sup>4,7,9–11</sup> The route of lymphatic spread in other head and neck cancers has been more thoroughly studied and often demonstrates specific patterns.<sup>12,13</sup> Notably, nasopharyngeal carcinoma has been shown to spread primarily to the RPNs.<sup>14</sup> This has important implications for both diagnosis and treatment because the RPNs cannot be palpated and can be difficult to approach surgically. Two recent case series have presented a total of 6 patients with ENB metastasizing to the RPNs.<sup>15,16</sup> It is unclear from previous studies whether these are rare occurrences or common but unrecognized routes of spread.

While the definitive diagnosis of ENB rests on histopathologic examination, imaging plays a key role in staging the disease. The appearance of ENB on CT and MR imaging is not specific, but these imaging modalities have been shown, in many studies, to be effective at identifying the extent of tumor expansion across the cribriform plate and into the orbit and brain, as well as in the identification of metastatic lymph nodes.<sup>17–20</sup> Despite several studies describing in detail the appearance of primary ENB on CT and MR imaging, no study, to our knowledge, has specifically detailed the appearance of metastatic cervical lymph nodes.

Received July 16, 2010; accepted after revision September 19.

From the Departments of Radiology (M.C.H., B.F.B.) and Otolaryngology (B.F.B., C.H.S.), University of Pittsburgh School of Medicine, Pittsburgh, Pennsylvania.

Please address correspondence to Barton F. Branstetter IV, MD, UPMC Presbyterian Hospital, 200 Lothrop, PUH, D-132, Pittsburgh, PA 15213 e-mail: branstetterbf@upmc.edu

DOI 10.3174/ajnr.A2401

Table 1: Modified Dulguerov TNM staging	
Staging	Description
Primary tumor	
T1	Tumor involving the nasal cavity and/or paranasal sinuses (excluding sphenoid), sparing the most superior ethmoidal cells
T2	Tumor involving the nasal cavity and/or paranasal sinuses (including the sphenoid) with extension to or erosion of the cribriform plate
T3	Tumor extending into the orbit or protruding into the anterior cranial fossa
T4	Tumor involving the brain
Lymph nodes	
	No regional lymph node metastasis
N1	Metastasis in a single ipsilateral lymph node, $\leq 3$ cm in greatest dimension
N2A	Metastasis in a single ipsilateral lymph node $>3$ cm but not $>6$ cm in greatest dimension
N2B	Metastasis in multiple ipsilateral lymph nodes, none $>6$ cm in greatest dimension
N2C	Metastasis in bilateral or contralateral lymph nodes, none $>6$ cm in greatest dimension
N3	Metastasis in a lymph node $>6$ cm in greatest dimension
Distant metastasis	
M0	No evidence of distant metastasis
M1	Evidence of distant metastasis

The primary objective of our study was to describe the patterns of spread of ENB into the cervical lymph nodes. The secondary objective of our study was to describe the imaging appearance of metastatic cervical lymph nodes from ENB.

## Materials and Methods

We retrospectively reviewed the electronic medical records to identify patients with a diagnosis of ENB at the University of Pittsburgh Medical Center. We included only those patients with histopathologically confirmed ENB, either newly diagnosed or referred to our institution, who had undergone staging or restaging imaging with CT, MR imaging, or PET/CT. Our institutional review board approved this study.

All patients were staged according to a modified Dulguerov TNM staging system, with nodal stage based on the American Joint Committee on Cancer staging system for cancer of the nasal cavity and paranasal sinuses, as shown in Table 1.<sup>6,21</sup> One of 2 fellowship-trained Certificate of Added Qualification—certified neuroradiologists with clinical focus in head and neck radiology initially interpreted all examinations for clinical purposes. One head and neck radiologist (B.F.B.), with 9 years of experience evaluating ENB, performed a second review of the examinations of all patients with surgically proved lymph node metastases, to confirm or further define the pattern of spread and size of the largest lymph node as well as to characterize the appearance of metastatic lymph nodes on CT and PET/CT.

Lymph nodes were classified according to surgical levels, with the following additional categories: RPNs and parotid/facial nodes.<sup>12</sup> We evaluated 3 characteristics of the imaging appearance of metastatic lymph nodes: 1) the proportion of the node that enhanced with contrast, as a means of characterizing nodes as cystic or solid in appearance, 2) the degree of contrast enhancement, and 3) the degree of FDG avidity. Because standardized uptake values are not considered a reliable measure of malignancy, FDG avidity was subjectively categorized as absent, low, moderate, or high. The degree of contrast enhancement was compared with that of neck arteries and submandib-

Table 2: Tumor histopathologic grade and TNM stage <sup>a</sup>	
Tumor Characteristics	No. of Patients (%)
Hyams grade	
I	3 (12)
II	17 (65)
III	6 (23)
IV	0 (0)
Tumor stage	
Primary tumor	
T1	21 (49)
T2	10 (23)
T3	4 (9)
T4	8 (19)
Lymph nodes	
N0	38 (88)
N1	1 (2)
N2B	1 (2)
N2C	3 (7)
Distant metastasis	
M0	42 (98)
M1	1 (2)

<sup>a</sup> Of the 26 patients with pathology-reported Hyams grade, 77% had low-grade ENB (grade I or II). Tumor was found to have spread beyond in the nasal cavity and paranasal sinuses in 51% of patients, most frequently invading the cribriform plate (23%). Five patients (11%) were found to have cervical metastasis at initial staging.

ular glands. Enhancement was categorized as absent (equal to that of noninvolved lymph nodes), mild (equal to or less than that of submandibular glands), moderate (between that of glands and arteries), or maximal (equal to that of neck arteries). All CT scans were obtained with 100–125 mL of contrast, by using a 45-second imaging delay.

Median overall survival was determined for patients with a new diagnosis of ENB and was calculated from the date of histopathologic confirmation of disease. Median progression-free survival, defined as the time period between diagnosis of ENB and radiographic or histopathologic evidence of disease progression, was also calculated for all patients with a new diagnosis of ENB.

## Results

We identified 48 patients with histopathologically confirmed ENB, including 43 (90%) with a primary diagnosis of ENB and 5 (10%) referred to our center for treatment of disease recurrence. Of the 48 patients, 33 (69%) were male and 15 (31%) were female. The mean age at diagnosis was 50 years, with a range of 14–88 years.

Pathologic grade based on the Hyams grading scale was present in the pathology reports of 26 patients (Table 2); 20 (77%) were considered low-grade (grade I or II), while only 6 (23%) cases were considered high-grade (grade III or IV).<sup>1</sup> Table 2 also presents the TNM staging, based on clinical and radiologic data, for the 43 patients for whom staging data were available. Most of the patients presented with T1 disease (confined to the nasal cavity or paranasal sinuses). Only 5 (12%) patients presented with nodal disease at initial staging. Distant metastasis to the lungs was present in 1 patient at initial staging.

All patients except 1 (98%) were treated with surgery for the primary tumor, either complete resection or debulking. A majority of patients (54%) were also treated with radiation therapy, while 25% underwent chemotherapy. The 1 patient not treated with surgery was a 14-year old girl with metastatic

**Table 3: Locations and imaging appearance of cervical lymph node spread<sup>a</sup>**

Lymph Nodes	No. of Patients (%)
Location ( <i>n</i> = 14)	
Level I	8 (57)
Level II	13 (93)
Level III	7 (50)
Level IV	1 (7)
Level V	3 (21)
Level VI	0 (0)
Level VII	0 (0)
RPN	6 (43)
General appearance on CT ( <i>n</i> = 14)	
Completely cystic (no solid areas on CT)	0 (0)
Predominantly cystic (<25% solid in appearance)	1 (7)
Moderately cystic (25%–49% solid)	0 (0)
Moderately solid (50%–74% solid)	0 (0)
Predominantly solid (75%–99%)	4 (29)
Completely solid (100% solid)	9 (64)
Degree of contrast enhancement on CT ( <i>n</i> = 14)	
None (no enhancing tissue visualized)	0 (0)
Mild (similar in density to normal lymph nodes)	1 (7)
Moderate (similar in density to glandular tissue)	7 (50)
Maximal (similar in density to vessels)	6 (43)
FDG avidity ( <i>n</i> = 12)	
Low	3 (25)
Medium	5 (42)
High	4 (33)

<sup>a</sup> Metastases to level II lymph nodes occur in almost all patients with cervical disease. Levels I and III occur in >50% of patients, while RPNs are present in 43% of patients. On imaging, metastatic cervical lymph nodes are predominantly solid, with moderate-to-maximal contrast enhancement and medium-to-high FDG avidity.

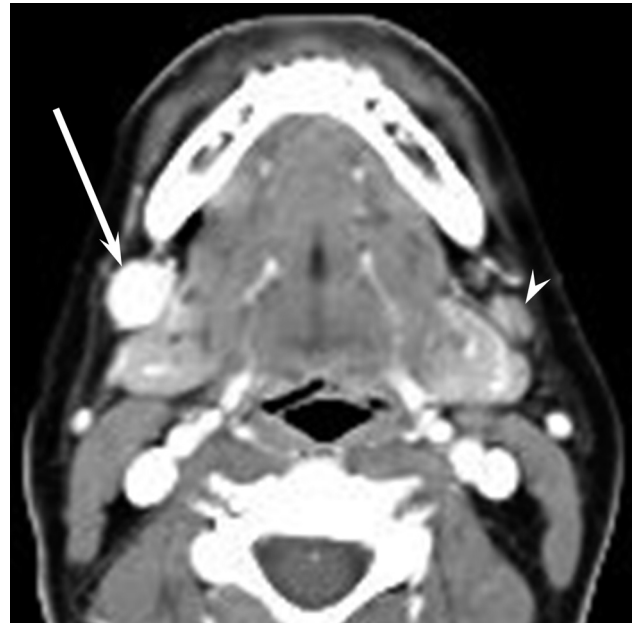disease on presentation, who was treated with chemoradiation and showed no evidence of disease at her most recent follow-up 5 years after diagnosis.

Evidence of progression was eventually found in 10 of the 43 patients (23%) who were initially diagnosed at our institution. The median time interval to recurrence in these 10 patients was 45 months (range, 16–101 months). The cervical lymph nodes were the most frequent site of progression, discovered in 7 patients, representing 16% of all patients and 70% of patients with disease progression. Of the 7 patients with treatment failure in the neck, 4 had no evidence of local progression at the time that nodal disease was discovered. Furthermore, none of the patients with treatment failures in the neck had evidence of nodal disease at the time of initial staging. Local progression was discovered in 6/43 patients (14%), and distant metastases were discovered in 4/43 patients (9%).

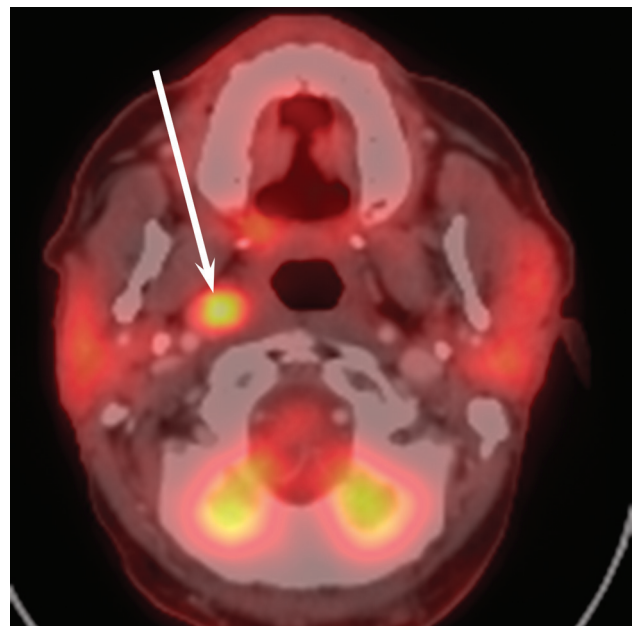
Spread of disease to the cervical lymph nodes was discovered in 14/48 patients (29%). Of the 14 patients, 5 (36%) were discovered to have lymph node involvement at initial staging, while 9 (64%) developed progressive disease in the cervical nodes on radiologic follow-up.

Level II lymph nodes were the most frequently involved, discovered in 13/14 (93%) cases (Table 3). Level I and III nodes and RPNs were also frequent sites of involvement, found in 8/14 (57%), 7/14 (50%), and 6/14 (43%) cases respectively. Levels IV and V were involved only in cases with disease widely metastatic to the neck nodes.

On CT, metastatic lymph nodes were predominantly to completely solid in appearance (Table 3). In only 1 patient was a predominantly cystic metastatic node seen on CT. Addition-



**Fig 1.** Contrast-enhanced axial CT image from a PET/CT examination demonstrating EMB metastasis (arrow) in a right zone IB lymph node. The metastatic lymph node demonstrates maximal contrast enhancement, similar in attenuation to arteries. A normal contralateral lymph node is indicated (arrowhead) for comparison.



**Fig 2.** Combined PET/CT axial image demonstrating ENB metastasis (arrow) in an RPN. The metastasis demonstrates avid FDG uptake.

ally, metastatic lymph nodes always showed some degree of contrast enhancement, with 13/14 (93%) showing moderate-to-maximal enhancement (Fig 1). Two patients with cervical metastases did not have a staging PET/CT. Of the 12 patients with PET/CT studies, most metastatic lymph nodes were moderately to highly FDG-avid (Fig 2), with only 3/12 (25%) patients having metastatic lymph nodes with low FDG avidity. The lymph nodes with low avidity were solid nodes of intermediate size that had varied enhancement characteristics.

The median follow-up in the 40 patients with a primary diagnosis of ENB was 41 months. Only 1 patient was docu-



mented as having died as a result of progression of ENB. The median documented period of progression-free survival in the 43 patients with a primary diagnosis of ENB was 31 months, with 33 patients (77%) showing no evidence of disease progression at their most recent follow-up.

## Discussion

While ENB remains a poorly understood tumor, metastasis to cervical lymph nodes is well-documented and has been shown to be a significant predictor of survival.<sup>6,7,8</sup> In our study, we found an incidence of cervical lymph node metastasis of 29%, similar to several previous studies and meta-analyses showing incidences of 20%–30%.<sup>4–6,8–11,13,22</sup>

The patterns of nodal metastasis are well-understood in many head and neck cancers, but to our knowledge, no previous study has sought to describe the specific route of nodal spread in ENB. Our study suggested some predictable patterns of cervical node metastases. Level II nodes were involved in almost all patients with nodal disease. The involvement of level II nodes is not surprising given their known drainage of the nasal cavity and nasopharynx and frequent involvement in other carcinomas from this region.<sup>12–14,23</sup> Levels I and III nodes were involved at least 50% of the time.

The RPNs primarily drain the nasopharynx, paranasal sinuses, soft palate, oropharynx, and middle ears. Given the location of ENBs in the nasal cavity and paranasal sinuses, it is conceivable that the RPNs would serve as a route of metastatic spread. Our study discovered RPN involvement in 43% of patients with nodal disease. This finding in conjunction with 2 recent case series documenting histopathologically proved metastasis to the RPNs indicates that radiologists should be vigilant in exploring the retropharyngeal space when interpreting imaging studies of patients with ENB.<sup>15,16</sup> This is particularly important given the difficulty in clinically assessing RPNs and the fact that they are not always included in neck dissections. In fact, 1 patient in our series underwent a neck dissection after multiple nodes were identified clinically. The patient did not undergo a staging PET/CT before the surgery, but a follow-up PET/CT showed metastatic disease in RPNs, a finding that might have caused the oncologists to defer surgery if it had been identified preoperatively.

While the prognostic significance of the specific nodes involved in cervical metastasis was not studied, understanding the routes of lymphatic spread is important for several reasons. First, understanding the most frequently occurring sites of metastatic spread can help guide radiologists when reviewing staging imaging, as well as surgeons performing neck dissections. Second, some authors have advocated elective neck dissection or irradiation in clinically negative necks.<sup>9,11,22</sup> Kadish et al<sup>5</sup> found the rate of nodal disease to be <20% of patients and, therefore, not warranting elective treatment. However more recent studies have found the rate of cervical nodal disease to be >20%.<sup>9–11,22</sup> These apparent higher rates of nodal disease may be due to such factors as improvements in diagnostic techniques or longer follow-up. In either case, a clear understanding of both the frequency and route of cervical nodal spread is imperative in determining whether elective neck therapy should be undertaken. In this study, only 10% of patients were identified as having nodal involvement at initial

staging; however, 19% of patients developed disease progression to the cervical lymph nodes during posttherapy surveillance. Of the 7 patients with treatment failures in the neck, none had nodal involvement at staging, while more than half had progression in the neck despite no evidence of disease at the site of the original tumor. These findings indicate that neither absence of nodal disease on staging nor complete excision of the original tumor guarantees prevention of cervical metastasis.

Our study was limited by its retrospective nature. Also, although all patients had pathologic confirmation of cervical lymphadenopathy, not all nodes were resected in every patient (eg, RPNs were often spared in patients who also had anterior neck disease). The relatively small number of patients with lymphadenopathy prevents us from establishing precise percentages for characterizing the metastatic nodes, but multi-institutional studies would be needed to produce a substantially larger sample of this rare disease.

CT, MR imaging, and PET/CT are complementary in the staging of ENB. CT provides the best information about invasion into bony structures such as the cribriform plate. MR imaging is superior in delineating the soft-tissue extent of the primary tumor, differentiating tumor from postobstructive inflammatory sinus disease, and detecting recurrent or metastatic disease at an early stage.<sup>9–11,22,24</sup> PET/CT is most useful for detecting regional and distant disease. Nodal metastases in our series showed marked contrast enhancement in most cases. Although lymph nodes of <1 cm are generally assumed to be benign, strongly enhancing nodes in the setting of ENB should be considered suspicious. Purely cystic nodes are infrequent (we identified none in our series). Because metastatic nodes are almost always moderately to strongly FDG-avid, PET/CT is an appropriate method for detecting nodal metastases.

## Conclusions

Regional metastases from ENB primarily drain to level II cervical nodes, with level I and level III nodes and RPNs frequently involved. Metastatic nodes from ENB most frequently are solid, enhance briskly, and have strong FDG avidity. Thus, PET/CT should be considered for the staging, restaging, and posttreatment surveillance of patients with ENB.

## References

1. Hyams VJ. **Olfactory neuroblastoma.** In: Hyams VJ, Baksakis JG, Michaels L, eds. *Tumors of the Upper Respiratory Tract and Ear.* Washington DC: Armed Forces Institute of Pathology; 1988:240–48
2. Berger L, Luc R, Richard D. **L'esthesioneuroepitheliome olfactif.** *Bull Assoc Fr Etude Cancer* 1924;13:410–21
3. Broich G, Pagliari A, Ottaviani F. **Esthesioneuroblastoma: a general review of the cases published since the discovery of the tumour in 1924.** *Anticancer Res* 1997;17:2683–706
4. Jethanamest D, Morris LG, Sikora AG, et al. **Esthesioneuroblastoma: a population-based analysis of survival and prognostic factors.** *Arch Otolaryngol Head Neck Surg* 2007;133:276–80
5. Kadish S, Goodman M, Wang CC. **Olfactory neuroblastoma: a clinical analysis of 17 cases.** *Cancer* 1976;37:1571–76
6. Dulguerov P, Calcaterra T. **Esthesioneuroblastoma: the UCLA experience 1970–1990.** *Laryngoscope* 1992;102:843–49
7. Morita A, Ebersold MJ, Olsen KD, et al. **Esthesioneuroblastoma: prognosis and management.** *Neurosurgery* 1993;32:706–14
8. Dulguerov P, Allal AS, Calcaterra TC. **Esthesioneuroblastoma: a meta-analysis and review.** *Lancet Oncol* 2001;2:683–90
9. Beitler JJ, Fass DE, Brenner HA, et al. **Esthesioneuroblastoma: is there a role for elective neck treatment?** *Head Neck* 1991;13:321–26

10. Davis RE, Weissler MC. Esthesioneuroblastoma and neck metastasis. *Head Neck* 1992;14:477–82
11. Rinaldo A, Ferlito A, Shaha AR, et al. Esthesioneuroblastoma and cervical lymph node metastases: clinical and therapeutic implication. *Acta Otolaryngol* 2002;122:215–21
12. Som PM. Lymph nodes of the neck. *Radiology*. 1987 165:593–600
13. Ferlito A, Shaha AR, Rinaldo A. Retropharyngeal lymph node metastasis from cancer of the head and neck. *Acta Otolaryngol* 2002;122:556–60
14. King AD, Ahuja AT, Leung SF, et al. Neck node metastases from nasopharyngeal carcinoma: MR imaging of patterns of disease. *Head Neck* 2000;22:275–81
15. Kim HJ, Kim J, Yoon JH. Retropharyngeal lymph node metastasis from olfactory neuroblastoma: a report of two cases. *Eur Arch Otorhinolaryngol* 2006;263:778–82
16. Zollinger LV, Wiggins RH 3rd, Cornelius RS, et al. Retropharyngeal lymph node metastasis from esthesioneuroblastoma: a review of the therapeutic and prognostic implications. *AJNR Am J Neuroradiol* 2008;29:1561–63. Epub 2008 May 22
17. Davis WL, Harnsberger HR, Smoker WR, et al. Retropharyngeal space: evaluation of normal anatomy and diseases with CT and MR imaging. *Radiology* 1990;174:59–64
18. Derdeyn CP, Moran CJ, Wippold FJ, et al. MRI of esthesioneuroblastoma. *J Comput Assist Tomogr* 1994;18:16–21
19. Pickuth D, Heywang-Kobrunner SH, Spielmann RP. Computed tomography and magnetic resonance imaging features of olfactory neuroblastoma: an analysis of 22 cases. *Clin Otolaryngol* 1999;24:457–61
20. Pickuth D, Heywang-Kobrunner SH. Imaging of recurrent esthesioneuroblastoma. *Br J Radiol* 1999;72:1052–57
21. Page DL, Fleming ID, Fritz A, et al. *AJCC Cancer Staging Manual*. 6th ed. New York: Springer-Verlag; 2002
22. Monroe AT, Hinerman RW, Amdur RJ, et al. Radiation therapy for esthesioneuroblastoma: rationale for elective neck irradiation. *Head Neck* 2003;29:529–34
23. Shah JP. Patterns of cervical lymph node metastasis from squamous carcinomas of the upper aerodigestive tract. *Am J Surg* 1990;160:405–09
24. Ahmad A, Branstetter BF. CT versus MR: still a tough decision. *Otolaryngol Clin North Am* 2008;41:1–22