



## Get Clarity On Generics

Cost-Effective CT & MRI Contrast Agents



FRESENIUS  
KABI

WATCH VIDEO

# AJNR

## Immediate and Midterm Results following Treatment of Recently Ruptured Intracranial Aneurysms with the Pipeline Embolization Device

W. McAuliffe and J.D. Wenderoth

This information is current as of August 9, 2025.

*AJNR Am J Neuroradiol* 2012, 33 (3) 487-493

doi: <https://doi.org/10.3174/ajnr.A2797>

<http://www.ajnr.org/content/33/3/487>

ORIGINAL  
RESEARCH

W. McAuliffe  
J.D. Wenderoth

# Immediate and Midterm Results following Treatment of Recently Ruptured Intracranial Aneurysms with the Pipeline Embolization Device

**BACKGROUND AND PURPOSE:** A number of flow-diverting devices have become available for endovascular occlusion of cerebral aneurysms. This article reports immediate and midterm results in recently ruptured aneurysms treated with the PED.

**MATERIALS AND METHODS:** A prospective registry was established at 3 Australian neurointerventional sites to collect data on ruptured and unruptured aneurysms treated with PED during a 12-month period from August 2009. From this data base of 65 patients, 11 cases of recent aneurysmal SAH were examined. Relevant data including antiplatelet therapy, technical issues, complications, and imaging findings during at least a 6-month period of follow-up were collected and analyzed.

**RESULTS:** Eleven patients had acutely ruptured aneurysms with SAH. Clinical follow-up was available on all cases with imaging follow-up at 6 months in 9 patients. Two patients died from rebleeding during the acute illness. There was no other procedural or delayed significant symptomatic morbidity. Eight aneurysms were occluded with a single case of residual body filling.

**CONCLUSIONS:** PED should be used in SAH with caution, reserved for suitable patients concomitantly treated with endosaccular coiling if possible.

**ABBREVIATIONS:** mRS = modified Rankin Scale; PcomA = posterior communicating artery; PED = Pipeline Embolization Device; WFNS = World Federation of Neurosurgery

Endovascular treatment has become a major technique for ruptured and unruptured aneurysms since publication of the International Subarachnoid Aneurysm Trial<sup>1</sup> in 2002. Additional advances with the use of complex coils,<sup>2</sup> balloon remodelling,<sup>3,4</sup> “bioactive” coils,<sup>5-7</sup> and stent-assisted coiling<sup>8-11</sup> have occurred, facilitating treatment of wide-neck aneurysms. More recently, a number of flow-diverting devices have become available and are under evaluation.<sup>12-16</sup>

Published midterm results<sup>17-19</sup> have demonstrated that treatment of wide-neck aneurysms with PED (Chestnut Medical Technologies, Menlo Park, California) reconstruction of the parent vessel is achieved safely. Acute treatment of difficult lesions such as blister aneurysms by using a stent or stent-assisted coiling, in the setting of SAH, has also been reported.<sup>20</sup> The purpose of this report was to analyze early clinical experience with the PED in the setting of SAH.

## Materials and Methods

### Patient Population

This series represents a subset of a prospective case registry of all patients with lesions suitable for PED treated at 3 Australian neurointerventional centers between August 2009 and August 2010. Each case was reviewed by a multidisciplinary team; before general release of the PED, individual application for use of the PED on compassionate grounds was sought from hospital administration and the Thera-

peutic Goods and Services Administration. Written informed consent was obtained. The PED was only used in patients in whom other endovascular or surgical options were thought to carry higher morbidity and in 3 patients in whom endovascular therapy had failed in the same admission to control the aneurysm. Data were collected prospectively with respect to aneurysm morphology, symptoms, previous treatment, antiplatelet and anticoagulation regimen, and technical and clinical complications. Follow-up for at least 6 months evaluated occlusion, mass effect, delayed complications, ongoing antiplatelet therapy, and in-stent stenosis.

### Antiplatelet and Anticoagulation Schedule

A variety of protocols was used depending on operator and clinical circumstances (Table). Most (7 cases) had a loading dose of 300–600 mg of clopidogrel and 300 mg of aspirin at the time of the procedure. One patient was on long-term clopidogrel for cardiac disease. One center had access to a point-of-care platelet inhibition unit and could prescribe additional clopidogrel in patients with measured inadequate platelet inhibition. Dual antiplatelet medication was prescribed for 6 months in the anterior circulation and for  $\leq 12$  months in the posterior circulation. Patients were monitored for clopidogrel compliance by direct questioning. Aspirin therapy was intended to be lifelong. All patients had procedural intravenous heparin with an activated clotting time of  $>200$ . Nine of 11 patients had heparin infusion for at least 24 hours postprocedure (activated partial thromboplastin time,  $\times 2$  normal).

### Procedure

Therapy was undertaken with the patient under general anesthesia. All PEDs were deployed through a Marksman (ev3, Irvine, California) 2.8F microcatheter. Additional PEDs were deployed at the discretion of the operator and were placed if there was an ongoing jet or inadequate neck coverage. Ideally, stasis and a contrast/blood layer were

Received May 26, 2011; accepted after revision June 16.

From the Neurological Intervention and Imaging Service Western Australia (W.M.), Sir Charles Gairdner Hospital, Perth, Australia; Prince of Wales Hospital (J.D.W.), Sydney, Australia; and Liverpool Hospital (J.D.W.), Sydney, Australia.

Please address correspondence to William McAuliffe, MD, Neurological Intervention and Imaging Service Western Australia, First Floor G Block, Sir Charles Gairdner Hospital, Verdun St, Nedlands, Perth 6009, Australia; e-mail: willmca@inet.net.au

<http://dx.doi.org/10.3174/ajnr.A2797>

# Patient, aneurysm, and treatment summary characteristics

Patient	Sex/ Age (yr)	WFNS Grade at Time of PED	Days after SAH at Time of PED Placement	Aneurysm Site	Type	Sac Size (mm)	Previous Treatment	No. of PEDs	Additional Coils at Time of PED	Clopidogrel/Aspirin (mg) Loading	mRS <sup>a</sup>	Aneurysm Occluded (at 6 mo)
1	M/48	1	24	Basilar trunk	B	2	Nil	2	No	600/300	0	Yes
2	F/56	2	2	Superior hypophyseal	S	21	Nil	3	No	600/300	6	Died
3	M/64	1	4	Basilar tip/P1	S	12	Nil	1	Yes	600/300	0	Yes
4	F/49	1	21	Superior hypophyseal	S	10	Nil	1	Yes	300/300	0	Yes
5	F/52	2	11	P1/P2	B	12	Coils and stent (day 2)	1	Yes	300/300	2	Filling
6	M/51	3	26	Vertebral	B	2	Nil	1	No	450/150	2	Yes
7	M/56	2	1	Basilar trunk	F	21	Nil	2	Yes	Long-term daily 75/100	1	Yes
8	F/50	1	16	PcomA	F	12	Nil	2	No	75/150 5-Day loading	0	Yes
9	F/37	5	1	Dorsal paraclinoid ICA	F	34	Nil	2	No	300/300	6	Died
10	F/64	4	8 <sup>b</sup>	Dorsal paraclinoid ICA	B	2	Coils and stent (day 1)	1	Yes	75/150 7 Days	4	Yes
11	F/41	1	21	P1/P2	B	6	Coils (day 1)	1	No	75/150 5-Day loading	0	Yes

**Note:**—B indicates blister; F, fusiform; S, saccular.

<sup>a</sup> mRS at 1 month posttreatment.

<sup>b</sup> Bleed day 1 and second bleed on day 8.

observed at the cessation of the procedure. Where possible, coils were deployed in the aneurysm before PED deployment or after “jailing” a microcatheter.

## Discharge and Follow-Up

Clinical follow-up was performed at 1 and 6 months, in addition to independent evaluation by a neurosurgeon. Patients were also seen more regularly if they had complex problems. A 6-month control angiogram was performed and reviewed by 2 interventional neuroradiologists. Further angiography was performed if the aneurysm was open or in-construct narrowing was present.

## Study End Points

The primary end point was development of complications leading to patient morbimortality from the time of PED placement to 6 months. All clinical incidents (TIA, stroke, SAH, or mass effect) in the first 6 months posttreatment were documented. The secondary end point was the angiographic appearance at 6 months with assessment of aneurysm closure and parent vessel stenosis. Extended follow-up was undertaken beyond 6 months in cases with nonocclusion of aneurysm or in-stent stenosis.

## Results

### Patient and Aneurysm Characteristics

Data on 65 patients were collected between August 2009 and August 2010. From this cohort, 11 cases of acute SAH were identified. Six patients were treated between day 1 and 14 post-SAH. Five others were treated between day 15 and 26. Details of the clinical status, aneurysm morphology, and therapy of patients are summarized in the Table. There were 7 women and 4 men with age range of 41–69 years.

Aneurysm morphology, treatment, and outcome are documented in the Table. There were 8 fusiform and 3 saccular aneurysms in the cohort of 11 cases. Of the fusiform aneurysms, 5 were blister or posterior circulation dissecting blister-like type (1 ICA, 1 basilar trunk, 1 vertebral artery, and 2 P1/P2). These showed typical features of small irregular lesions with poorly defined wide necks and angiographic evidence of

growth and morphologic instability with time. Three of these had failed previous endovascular treatment (2 stent/coil, 1 coils only) during the same admission.

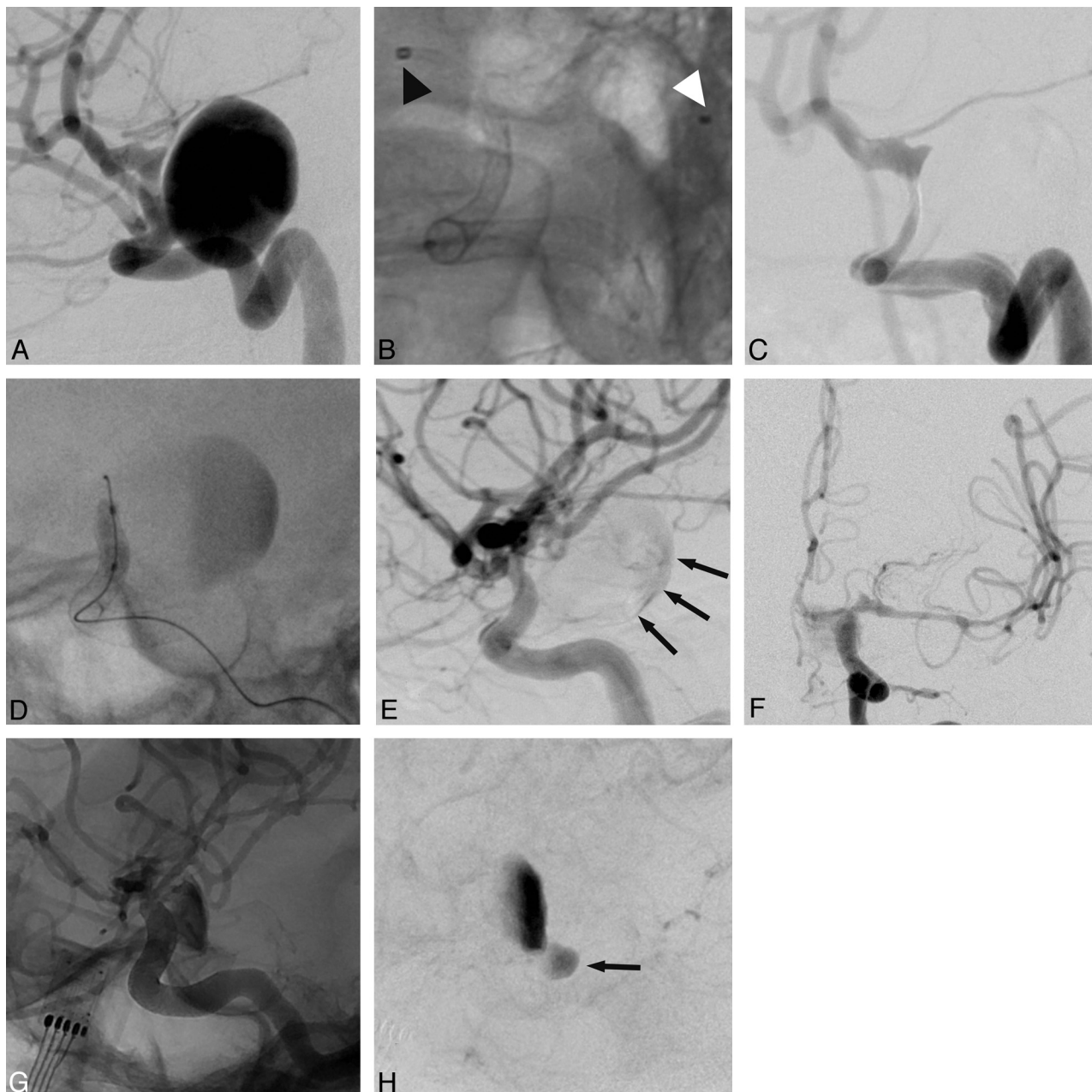
### Treatment and Procedural Outcomes

Six patients received coils as well as PEDs during their cumulative treatment. Of the 5 who received only a PED in their treatment, 2 had dissecting blisterlike lesions with no sac to hold the coils and 1 was treated in a delayed fashion (16 days postictus). Twenty-one-millimeter (patient 2) and 34-mm (patient 9) aneurysms were treated acutely with PED only. Patient 2 was intended to have PED/coiling (Fig 1). Both died of aneurysm rerupture during their acute admission.

### Acute Procedural Technical and Clinical Complications

A poorly opened PED requiring angioplasty occurred in 1 patient, patient 2 (Fig 1); 2 PEDs were deployed with an Echelon-10 microcatheter (ev3) jailed in the aneurysm sac with the expressed intent of coiling the sac after PED deployment. However, after deployment of 2 PEDs, there was poor flow in the carotid siphon, causing concerns of raised intrasaccular pressure, despite no demonstrable aneurysm filling. The microcatheters were sequentially removed to determine if they were the cause of diminished flow. This proved not to be the case, and angioplasty of the PED was performed, which restored flow in the parent vessel. The coiling opportunity had been lost because the jailed catheter had been removed. Minimal clot on the surface of the PED was demonstrated with no evidence of distal embolism. The clot was lysed with 3 mg of intra-arterial abciximab. The patient awoke intact and unchanged in condition.

Two patients experienced acute aneurysm rerupture and died. One of these, patient 2, developed upper limb weakness on day 8 and elevated transcranial Doppler velocities. The patient was emergently prepared for angiography but had a rapid decline in consciousness on the way to the angiography suite. CT demonstrated additional SAH, and severe vasospasm of the M1 segment (distal to the treated aneurysm) was docu-



**Fig 1.** A 56-year-old patient 2 with a poorly opened PED requiring angioplasty. All images (unless stated) are left ICA angiograms in the lateral projection. Images A–E are day 2 after SAH. *A*, Subtracted image of 21-mm superior hypophyseal aneurysm. *B*, Nonsubtracted image demonstrates the PED in the ICA with a delivery catheter tip (*black arrowhead*) and jailed microcatheter tip (*white arrowhead*) in the aneurysm with the intention of coiling the aneurysm after PED deployment. *C*, Subtracted image after 2 PEDs were implanted. Despite sequential removal of both microcatheters, there is ongoing marked stenosis of the ICA with no aneurysm filling. *D*, Nonsubtracted image demonstrates an angioplasty balloon within the PED. Note contrast stasis in the sac. *E*, Subtraction image postangioplasty documents a normal-caliber ICA with a PED now fully open. Minimal dependent filling of the aneurysm (*small black arrows*) without discernible inflow jet is seen. Because the jailed microcatheter was removed before angioplasty, coiling of the sac is not possible. The patient did well but developed symptomatic vasospasm and right upper limb weakness and dysphasia day 8 post-SAH. Because she was being prepared for angiography with a view to angioplasty, the aneurysm reruptured and she became obtunded, requiring intubation. CT (not shown) demonstrated increased SAH, and emergency angiography was immediately performed. *F*, Anteroposterior subtracted DSA of the left ICA demonstrates severe M1 vasospasm. *G* and *H*, Lateral unsubtracted DSA (*G*) and lateral subtracted DSA (*H*) demonstrate aneurysm refilling with a new rupture point locule (*black arrow*). Balloon angioplasty and deployment of an additional PED (not shown) was performed, but the patient remained in poor condition and died 3 days later.

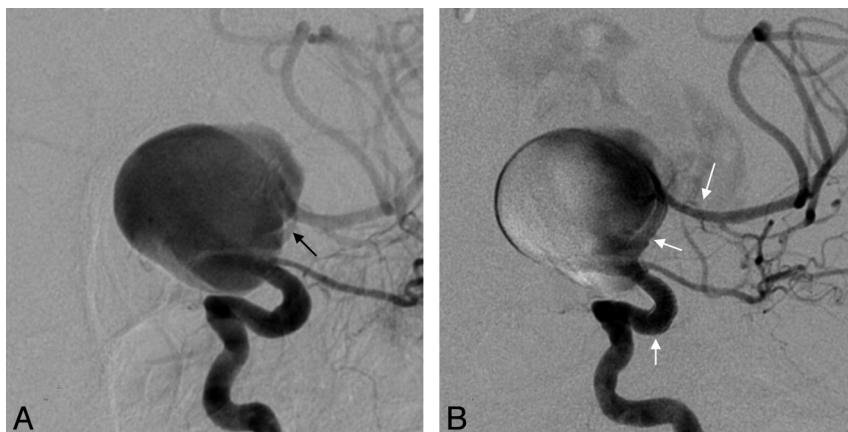
mented on angiography (Fig 1), potentially pressurizing the sac. At this time, balloon angioplasty of the M1 was performed, and a third PED was deployed. The patient died 3 days later.

Patient 9, WFNS grade 5, had a fusiform 34-mm paraclinoid carotid aneurysm with no normal parent vessel lumen at the aneurysm interface (Fig 2). On close inspection, there was some smooth narrowing of the parent vessel distal to the neck,

possibly due to extrinsic compression. Two PEDs were telescoped across the aneurysm, and the aneurysm re-ruptured immediately after deployment of the second device. Active treatment was withdrawn, and the patient died during the next 24 hours.

PED migration requiring additional treatment occurred in a single case (patient 1) with a 2-mm dissecting blisterlike aneurysm in the distal basilar trunk. A single PED migrated





**Fig 2.** Acute aneurysm rupture on PED deployment. Patient 9 presented with SAH, WFNS grade 5, and a 34-mm fusiform paraclinoid aneurysm treated on day 1 with 2 PEDs. *A*, Anteroposterior oblique left ICA DSA demonstrates the same narrowing of the terminal ICA (black arrow) distal to the fusiform aneurysm neck. *B*, Two PEDs have been deployed (white arrows outlining the proximal PED, point of overlap of the 2 PEDs in the previously narrowed portion of the distal ICA, and the distal PED in the proximal MCA M1 segment). Note the aneurysm is rerupturing with contrast extravasation superior to the dome. The patient died the same day.

caudally for 5 minutes, uncovering the neck and necessitating placement of a second PED with no consequence. Migration was related to inadequate distal purchase, unsheathing the PED rather than pushing the device out of the catheter, and the tendency for the device to seek a larger diameter (“melon seed”).

A cerebellar bleed related to anticoagulation and a lacunar infarct occurred in the same patient (patient 3) who had a basilar tip/P1 fusiform aneurysm treated with coils and PED. The patient was confused on day 1 postprocedure. CT demonstrated a left cerebellar tonsillar 2-cm hematoma and a small 5-mm anterior right thalamic lacune. The patient settled within 48 hours with no morbidity and was discharged home 13 days post-SAH with an mRS score of 0 at 1 month.

Three patients failed initial endovascular therapy, which necessitated PED deployment as a salvage procedure during their admission for SAH.

Patient 5 presented with WFNS 4 with a fusiform dissecting blisterlike aneurysm of the left P1/P2 segment aneurysm (Fig 3), originally treated with a Solitaire stent (ev3) and coils. Due to the nature of the aneurysm, MRA was performed on day 11, demonstrating a large recurrence. The patient was now WFNS grade 2 and was immediately treated with additional coils and PED placement.

Patient 11 presented with a WFNS grade 1 SAH and a 7-mm dissecting blisterlike aneurysm at the left P1/P2 junction. The aneurysm was treated on day 1 with coil occlusion, resulting in a residual 1-mm neck. Due to the etiology of the aneurysm, a check angiogram was obtained at day 7 demonstrating an acute 6-mm recurrence. A decision was made to wait before treating the recurrence with PED. This occurred without incident on day 21 post-SAH.

Patient 10 presented with a WFNS grade 3 SAH due to a blister aneurysm of the right dorsal paraclinoid ICA. This was treated on the day 1 with 2 coils and a Solitaire stent. A check angiogram was obtained at day 7 to exclude early regrowth, and the aneurysm remained secure. On day 8, the patient rebled and deteriorated to WFNS grade 4. Angiography confirmed a 2-mm recurrence of the aneurysm proximal and superior to the existing coils. A microcatheter was placed in the recurrent aneurysm through the stent, and 2 additional coils

were deployed. This procedure was followed immediately by a PED because the patient was already receiving clopidogrel and aspirin due to the previously inserted stent. DSA at 1 month demonstrated aneurysm occlusion, but the patient did not improve and had a poor outcome (mRS 4).

No patient had a TIA, stroke, new-onset mass effect, or delayed aneurysm rupture during outpatient follow-up.

#### **Aneurysm Closure at Imaging Follow-Up**

Nine patients were available for follow-up (2 deaths). Eight had DSA (7 at 6 months and 1 at 1 month) with 1 patient (patient 6) undergoing MRA at 6 and 12 months due to chronic renal failure. Eight aneurysms were occluded with a single case of residual body filling (Fig 3) in patient 5 who had a pre-existing stent in situ.

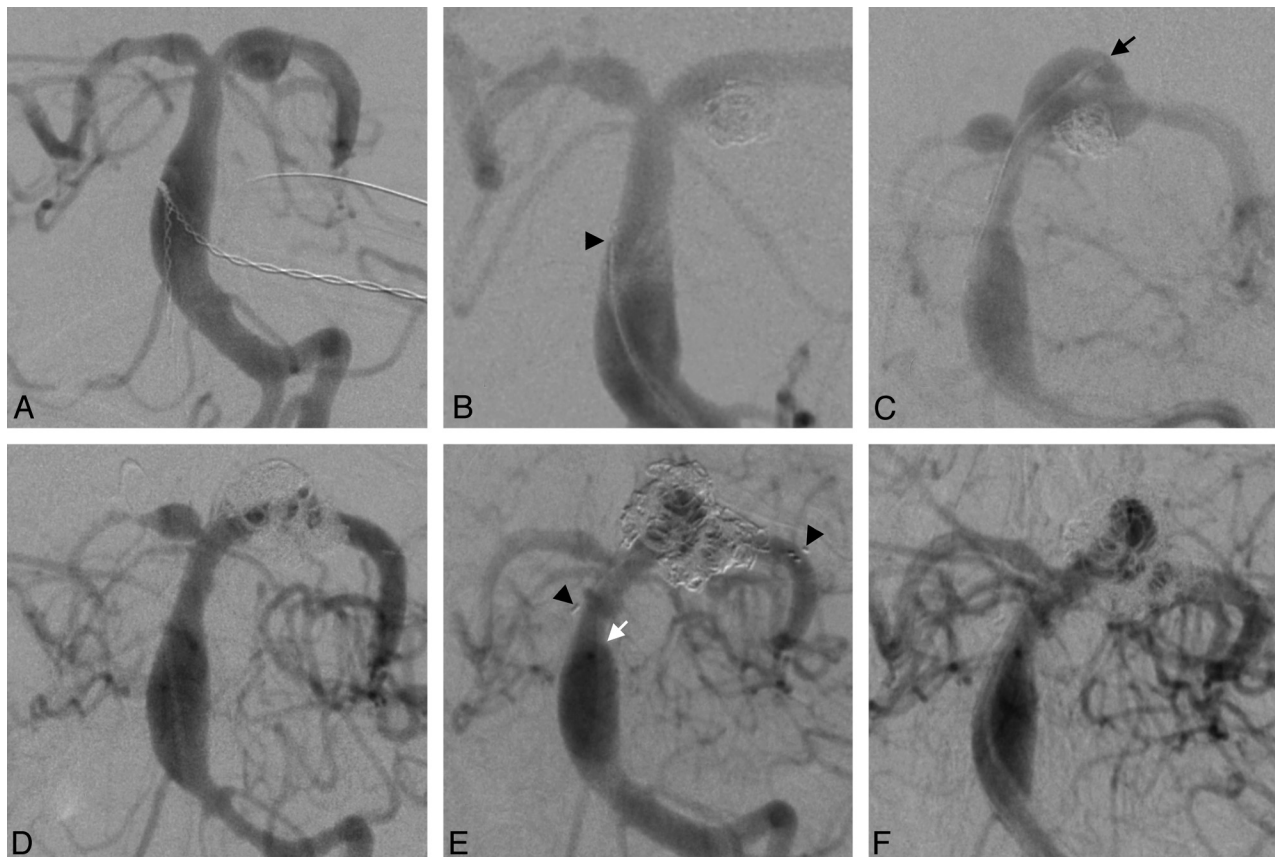
#### **In-Stent Stenosis**

In 1 case, patient 4, treated with coils and a PED, 50% in-construct stenosis was detected at 6 months. Dual antiplatelet agents were maintained, and the narrowing decreased to 25% at 10-month DSA (Fig 4) and <20% after 14 months.

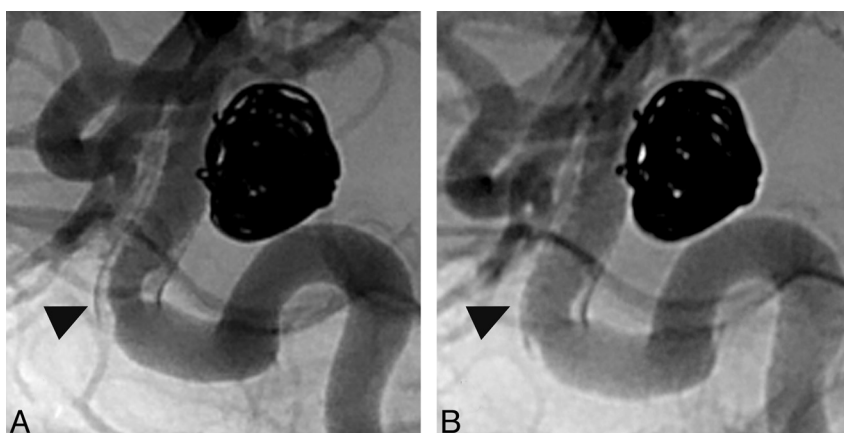
#### **Discussion**

Endovascular treatment of ruptured aneurysms in the setting of SAH is most safely performed with coils. Wide-neck, blister, and dissecting blisterlike aneurysms are difficult to treat with both open and endovascular techniques. A balloon-assisted technique may not be possible in all small blister or dissecting blisterlike aneurysms, fusiform aneurysms, and some wide-neck aneurysms in which the native vessel is incorporated into the neck of the aneurysm. Treatment of acutely ruptured aneurysms with stent placement/coils is problematic because of the perceived requirement for concomitant antiplatelet medication, particularly clopidogrel, during the time of acute SAH. External ventricular drainage and the potential for aneurysm rehemorrhage (particularly if the aneurysm sac is not tightly packed with coils) is a concern.

There are a number of articles outlining the treatment of acutely ruptured wide-neck<sup>21,22</sup> or acute blister aneurysms<sup>23–25</sup> with stents and/or coils, for which coil placement is difficult or impossible. Tahtinen et al<sup>21</sup> treated 61 patients



**Fig 3.** Nonoccluded blister aneurysm previously treated with stent/coil combination. Patient 5 presented with SAH and a blister aneurysm of the left P1/P0 segment, initially treated with a Solitaire stent and coils. All images are subtracted DSA of the left vertebral artery in an anteroposterior transfacial projection. *A*, A 6-mm fusiform blister-type aneurysm projects inferiorly. Note the dilated basilar trunk. *B*, An aneurysm secured with coils passes through a nondetected Solitaire stent. The black arrowhead designates the nondetached proximal marker of the stent. *C*, Enlarging fusiform blister aneurysm day 11 after MRA (not shown), performed the same, day demonstrates recurrence of the aneurysm. A PED has been deployed in the left P1 segment, across the aneurysm and into the basilar trunk. A microcatheter is jailed in the sac (small black arrow) precoiling. *D*, Postcoiling angiogram shows a secured aneurysm and good filling of left posterior cerebral artery. The patient developed vasospasm subsequently, which was treated with balloon angioplasty of the ICA and middle cerebral arteries bilaterally (not shown), and made a good recovery. *E*, Six-month angiogram shows some body filling contained within the coils. Note that the proximal margin of the PED (small white arrow) is proximal to the proximal marker of the stent (black arrowhead). The distal marker of the stent within the P1/P2 segment junction is also shown (black arrowhead). The patient's clopidogrel was stopped as a consequence of the change, but aspirin was continued. *F*, Ten-month angiogram shows a stable appearance. No action has been taken thus far, and a follow-up angiogram in 12 months is scheduled because there is a reluctance to overlap the PED in the basilar tip and trunk.



**Fig 4.** In-construct stenosis. Patient 4 lives in a remote location and has a 10-mm superior hypophyseal aneurysm treated with coils and PED 21 days post-SAH. ICA angiography in lateral projection. *A*, Unsubsctracted image at 6 months demonstrates aneurysm occlusion with dense coil packing. Fifty percent focal stenosis within the proximal margin of the PED (black arrowhead) is seen with a longer segment of neointimal hyperplasia throughout the construct. *B*, Unsubsctracted image at 10 months documents that focal stenosis is reduced as is the extent of neointimal hyperplasia (black arrowhead).

with wide-neck aneurysms (including 3 vertebral dissections) within 72 hours of the onset of SAH by using Neuroform stents (Boston Scientific, Natick, Massachusetts) and coils. In-

travenous heparin and aspirin were given during the procedure, and 300 mg of clopidogrel was given postprocedure. In 10% of patients, stent deployment was not successful; 19.8%

(12/61) had complications directly due to primary stent/coil treatment (7 thromboembolic events requiring abciximab and 4 aneurysm perforations) or due to early rebleeding of the aneurysm (1 patient). Thirty-day mortality was 20% with favorable Glasgow Outcome Score of 4 or 5 in 69%. Katsaridis et al<sup>22</sup> reported a subcohort of 33 acutely ruptured aneurysms within a population of 54 cases treated intraprocedurally with Neuroform 2 stents (Boston Scientific) and coils with intraoperative heparin and postoperative clopidogrel, aspirin, and low-molecular-weight heparin. There were no procedure-related clinical complications, and 2 technical issues were encountered with no clinical sequelae. Good outcome (mRS score, 0–3) was seen in 64%, with 21% having a poor outcome and 15% resulting in death. Angiographic follow-up, however, for assessment of the durability of treatment was limited in the patients with SAH.

In acute carotid blister aneurysms or dissecting dissecting blisterlike posterior circulation aneurysms, treatment with coils alone is problematic. Lee et al<sup>25</sup> reported 9 patients with blister aneurysm cases, 6 treated with Neuroform stents and coils initially; 4 of these subsequently had aneurysm recurrence requiring placement of an additional stent. Three others were primarily treated with covered stents. One patient in this small group died acutely due to vessel rupture during stent placement. The 8 survivors had a good outcome. Park et al<sup>24</sup> reported acute blister aneurysm recurrence in all 4 cases in the setting of acute endovascular reconstructive therapy (3 coiling, 1 stent-coiling). Two of these had failed surgical treatment before endovascular therapy. The authors advocated endovascular trapping in these cases due to the high recurrence rate, but another group reported very poor outcome with acute vessel sacrifice in the setting of acute SAH, mainly due to vasospasm.<sup>26</sup> Meckel et al<sup>20</sup> reported 12 blister or dissecting blisterlike posterior circulation ruptured aneurysms treated acutely with stent-assisted coiling in 11 and double stent placement alone in 1. Two patients rebled, 1 of whom died. Three required retreatment, with 2 having parent vessel occlusion in the acute admission and 1 undergoing delayed vessel sacrifice. All 11 survivors had an excellent outcome and angiographic appearance, but primary endovascular treatment failed in 4/12.

The development of flow diverters to reconstruct vessels and occlude aneurysms has created much interest,<sup>27–31</sup> and recent PED series<sup>17–19</sup> showed occlusion rates of 93% and 94% at 6-month follow-up in large or wide-neck aneurysms, with low morbidity. The Pipeline for the Intracranial Treatment of Aneurysms trial<sup>19</sup> studied 31 aneurysms with no recent history of SAH. Lylyk et al<sup>17</sup> described a series of 63 aneurysms, without recent SAH, though 7 patients had had previous SAH treated remotely by endovascular means. Byrne et al<sup>32</sup> reported the use of another flow diverter, Silk (Balt Extrusion, Montmorency, France), in 10 patients with previously ruptured aneurysms, but only 4 were treated within 30 days of hemorrhage. The application of these devices in the setting of acute SAH in aneurysms is not well-documented in the literature.

Kulcsar et al<sup>33</sup> described 2 patients with aneurysms <2 mm presenting with acute SAH, primarily treated with the Silk stent at 10 and 24 days after the initial bleed. The first was a carotid blister aneurysm, and the patient was premedicated

with 100 mg of aspirin and 75 mg of clopidogrel for 3 days. The second was a basilar tip aneurysm, and the patient was loaded with 300 mg of both aspirin and clopidogrel. Follow-up angiography demonstrated some in-stent narrowing in one and stenosis of the superior cerebellar artery origin in the other. Both had excellent outcomes and aneurysm obliteration.

Our population varied from that in other published series in that it consisted of 11 patients with acute SAH treated with PED: 6 in the first 2 weeks (including 4 within 72 hours of ictus) and 5 in the third or fourth week. Five were acute ICA blister or posterior circulation dissecting blisterlike lesions, and 3 of these recurred acutely after failing primary endovascular therapy of coils (1 patient) or a Solitaire stent and coils (2 patients) during the same admission, with 1 patient representing with a second SAH. The mortality rate was 18.2% with 2 ruptures but with no procedure-related symptomatic significant morbidity in the other 9 patients.

The 6-month occlusion rate of (8/9) in our small series is consistent with that in previous reports,<sup>17–19</sup> with the only nonoccluded aneurysm, initially treated with stent/coils, appearing stable at follow-up.

The literature has recently highlighted delayed rupture related to flow division in elective cases.<sup>34,35</sup> Kulcsar et al<sup>34</sup> documented 13 patients with delayed rupture following Silk stent placement. Two of these may have had acute SAH at presentation. In our series, 2 patients died from aneurysm rerupture in the setting of acute SAH. It is our practice to only use a stent in SAH if necessary and, wherever possible, to coil the aneurysm at the time of stent placement, because stent or PED deployment does not necessarily lower pressure in the fundus of the aneurysm. Although it may be easier to coil the aneurysm by using a jailed microcatheter after deploying the PED, it may be better to coil as much as possible first, with balloon assistance if practicable, deploy the PED, and then complete the coiling. This will maximize fundus protection in the acute setting. Alternatively, it could be argued that acute fundus protection with coils, followed by delayed PED at 1–2 months, could be undertaken in appropriate situations (such as the case described in Fig 1).

Cebral et al<sup>35</sup> highlighted the possible role of parent vessel stenosis in aneurysm rupture post-PED, suggesting that coiling these aneurysms may also be required in that setting. In retrospect, patient 9 did have a degree of smooth narrowing in the ICA distal to the neck, which did improve a little in diameter post-PED, though the M1 was more gracile. Treatment of any type of this particular aneurysm will continue to be challenging in the setting of SAH.

## Conclusions

PED reconstruction of acutely ruptured wide-neck aneurysms or dissecting blisterlike aneurysms without a well-defined sac is possible, but caution needs to be exercised in cases of acute SAH. Ancillary attenuated coiling of the sac is warranted in patients with acute SAH or in other high-risk situations (such as stenosis in the parent vessel), by using the PED as a coil scaffold rather than a flow-diverter for acute aneurysm treatment in appropriate cases. Staged treatment with PED, temporizing with balloon-assist coiling acutely, is an option. It may be better to avoid conventional stent-assisted coiling in



the acute setting, if possible, as the occlusion rate with PED is lower if deployed inside a stent.

Disclosures: Jason D. Wenderoth—Consultancy: ev3, Comments: proctoring for deployment of PED.

## References

- Molyneux A, Kerr R, Stratton I, et al. International Subarachnoid Aneurysm Trial (ISAT) of neurosurgical clipping versus endovascular coiling in 2143 patients with ruptured intracranial aneurysms: a randomised trial. *Lancet* 2002;360:1267–74
- Taschner CA, Thines L, El-Mahdy M, et al. GDC 360 degrees for the endovascular treatment of intracranial aneurysms: a matched-pair study analysing angiographic outcomes with GDC 3D coils in 38 patients. *Neuroradiology* 2009;51:45–52
- Moret J, Cognard C, Weill A, et al. Reconstruction technic in the treatment of wide-neck intracranial aneurysms: long-term angiographic and clinical results—apropos of 56 cases [in French]. *J Neuroradiol* 1997;24:30–44
- Sluzewski M, van Rooij WJ, Beute GN, et al. Balloon-assisted coil embolization of intracranial aneurysms: incidence, complications, and angiography results. *J Neurosurg* 2006;105:396–99
- White PM, Lewis SC, Nahser H, et al. HydroCoil Endovascular Aneurysm Occlusion and Packing Study (HELPS trial): procedural safety and operator-assessed efficacy results. *AJNR Am J Neuroradiol* 2008;29:217–23
- Geyik S, Ertugrul O, Yavuz K, et al. Comparison of bioactive coils and bare platinum coils for treatment of intracranial aneurysms: a matched-pair analysis. *J Neurosurg* 2010;112:709–13
- Katsaridis V, Papagiannaki C, Violaris C. Guglielmi detachable coils versus Matrix coils: a comparison of the immediate post-treatment results of the embolization of 364 cerebral aneurysms in 307 patients: a single-center, single-surgeon experience. *AJNR Am J Neuroradiol* 2006;27:1841–48
- Yavuz K, Geyik S, Saatci I, et al. WingSpan stent system in the endovascular treatment of intracranial aneurysms: clinical experience with midterm follow-up results. *J Neurosurg* 2008;109:445–53
- Weber W, Bendszus M, Kis B, et al. A new self-expanding nitinol stent (Enterprise) for the treatment of wide-necked intracranial aneurysms: initial clinical and angiographic results in 31 aneurysms. *Neuroradiology* 2007;49:555–61
- Lylyk P, Cohen JE, Ceratto R, et al. Combined endovascular treatment of dissecting vertebral artery aneurysms by using stents and coils. *J Neurosurg* 2001;94:427–32
- Fiorella D, Albuquerque FC, Deshmukh VR, et al. Usefulness of the Neuroform stent for the treatment of cerebral aneurysms: results at initial (3–6-mo) follow-up. *Neurosurgery* 2005;56:1191–201, discussion 1201–02
- Fiorella D, Kelly ME, Albuquerque FC, et al. Curative reconstruction of a giant midbasilar trunk aneurysm with the Pipeline embolization device. *Neurosurgery* 2009;64:212–17, discussion 217
- Fiorella D, Albuquerque F, Gonzalez F, et al. Reconstruction of the right anterior circulation with the Pipeline embolization device to achieve treatment of a progressively symptomatic, large carotid aneurysm. *J NeuroInterv Surg* 2010;2:31–37
- Kamran M, Yarnold J, Grunwald IQ, et al. Assessment of angiographic outcomes after flow diversion treatment of intracranial aneurysms: a new grading schema. *Neuroradiology* 2011;53:501–08
- Kulcsar Z, Ernemann U, Wetzel SG, et al. High-profile flow diverter (Silk) implantation in the basilar artery: efficacy in the treatment of aneurysms and the role of the perforators. *Stroke* 2010;41:1690–96
- Lubicz B, Collignon L, Raphaeli G, et al. Flow-diverter stent for the endovascular treatment of intracranial aneurysms: a prospective study in 29 patients with 34 aneurysms. *Stroke* 2010;41:2247–53
- Lylyk P, Miranda C, Ceratto R, et al. Curative endovascular reconstruction of cerebral aneurysms with the Pipeline embolization device: the Buenos Aires experience. *Neurosurgery* 2009;64:632–42, discussion 642–43, quiz N636
- Szikora I, Berentei Z, Kulcsar Z, et al. Treatment of intracranial aneurysms by functional reconstruction of the parent artery: the Budapest experience with the Pipeline embolization device. *AJNR Am J Neuroradiol* 2010;31:1139–47
- Nelson PK, Lylyk P, Szikora I, et al. The Pipeline embolization device for the intracranial treatment of aneurysms trial. *AJNR Am J Neuroradiol* 2011;32:34–40
- Meckel S, Singh TP, Undren P, et al. Endovascular treatment using predominantly stent-assisted coil embolization and antiplatelet and anticoagulation management of ruptured blood blister-like aneurysms. *AJNR Am J Neuroradiol* 2011;32:764–71
- Tahtinen OI, Vanninen RL, Manninen HI, et al. Wide-necked intracranial aneurysms: treatment with stent-assisted coil embolization during acute (<72 hours) subarachnoid hemorrhage—experience in 61 consecutive patients. *Radiology* 2009;253:199–208
- Katsaridis V, Papagiannaki C, Violaris C. Embolization of acutely ruptured and unruptured wide-necked cerebral aneurysms using the Neuroform 2 stent without pretreatment with antiplatelets: a single center experience. *AJNR Am J Neuroradiol* 2006;27:1123–28
- Kim BM, Chung EC, Park SI, et al. Treatment of blood blister-like aneurysm of the internal carotid artery with stent-assisted coil embolization followed by stent-within-a-stent technique: case report. *J Neurosurg* 2007;107:1211–13
- Park JH, Park IS, Han DH, et al. Endovascular treatment of blood blister-like aneurysms of the internal carotid artery. *J Neurosurg* 2007;106:812–19
- Lee BH, Kim BM, Park MS, et al. Reconstructive endovascular treatment of ruptured blood blister-like aneurysms of the internal carotid artery. *J Neurosurg* 2009;110:431–36
- Meling TR, Sorteberg A, Bakke SJ, et al. Blood blister-like aneurysms of the internal carotid artery trunk causing subarachnoid hemorrhage: treatment and outcome. *J Neurosurg* 2008;108:662–71
- Fiorella D, Woo HH, Albuquerque FC, et al. Definitive reconstruction of circumferential, fusiform intracranial aneurysms with the Pipeline embolization device. *Neurosurgery* 2008;62:1115–20, discussion 1120–21
- Wanke I, Forsting M. Stents for intracranial wide-necked aneurysms: more than mechanical protection. *Neuroradiology* 2008;50:991–98
- Augsburger L, Farhat M, Raymond P, et al. Effect of flow diverter porosity on intraaneurysmal blood flow. *Klin Neuroradiol* 2009;19:204–14
- Kallmes DF, Ding YH, Dai D, et al. A new endoluminal, flow-disrupting device for treatment of saccular aneurysms. *Stroke* 2007;38:2346–52
- Kallmes DF, Ding YH, Dai D, et al. A second-generation, endoluminal, flow-disrupting device for treatment of saccular aneurysms. *AJNR Am J Neuroradiol* 2009;30:1153–58
- Byrne JV, Beltechi R, Yarnold JA, et al. Early experience in the treatment of intra-cranial aneurysms by endovascular flow diversion: a multicentre prospective study. *PLoS One* 2010;5:pii:e12492
- Kulcsar Z, Wetzel SG, Augsburger L, et al. Effect of flow diversion treatment on very small ruptured aneurysms. *Neurosurgery* 2010;67:789–93
- Kulcsar Z, Houdart E, Bonafe A, et al. Intra-aneurysmal thrombosis as a possible cause of delayed aneurysm rupture after flow-diversion treatment. *AJNR Am J Neuroradiol* 2011;32:20–25
- Cebral JR, Mut F, Raschi M, et al. Aneurysm rupture following treatment with flow-diverting stents: computational hemodynamics analysis of treatment. *AJNR Am J Neuroradiol* 2011;32:27–33