



## Get Clarity On Generics

Cost-Effective CT & MRI Contrast Agents



FRESENIUS  
KABI

WATCH VIDEO

# AJNR

## Comparison of Contrast Effect on the Cochlear Perilymph after Intratympanic and Intravenous Gadolinium Injection

M. Yamazaki, S. Naganawa, M. Tagaya, H. Kawai, M. Ikeda, M. Sone, M. Teranishi, H. Suzuki and T. Nakashima

This information is current as of August 10, 2025.

*AJNR Am J Neuroradiol* 2012, 33 (4) 773-778

doi: <https://doi.org/10.3174/ajnr.A2821>

<http://www.ajnr.org/content/33/4/773>

## ORIGINAL RESEARCH

M. Yamazaki  
S. Naganawa  
M. Tagaya  
H. Kawai  
M. Ikeda  
M. Sone  
M. Teranishi  
H. Suzuki  
T. Nakashima



# Comparison of Contrast Effect on the Cochlear Perilymph after Intratympanic and Intravenous Gadolinium Injection

**BACKGROUND AND PURPOSE:** 3D-FLAIR imaging 24 hours after intratympanic gadolinium injection (IT-method) or 4 hours after IV injection (IV-method) has been used to visualize the endolymphatic hydrops in Ménière disease. The purpose of this study was to compare the degree of perilymph enhancement with the 2 methods and the perilymph contrast-effect difference with the IV-method in both sides in patients with unilateral Ménière disease.

**MATERIALS AND METHODS:** Sixty-one patients with Ménière disease or sudden SNHL were included in this study. Thirty-nine patients who underwent the unilateral IT-method (Gd-DTPA was diluted 8-fold with saline) and 22 patients who underwent the IV-method (a double-dose of Gd-HP-DO3A; 0.4 mL/kg body weight [ie, 0.2 mmol/kg body weight]) at 3T were analyzed retrospectively. Regions of interest of the cochlear perilymph and the medulla oblongata were determined on each image, and the signal-intensity ratio between the 2 (CM ratio) was subsequently evaluated. The differences in the CM ratio between the 2 methods (Student *t* test) and the IV-method CM ratio between the affected and unaffected sides in patients with unilateral Ménière disease (paired *t* test) were evaluated.

**RESULTS:** The IT-method CM ratio ( $2.98 \pm 1.15$ ,  $n = 39$ ) was higher than the IV-method CM ratio ( $1.61 \pm 0.60$ ,  $n = 44$ ;  $P < .001$ ). In patients with unilateral Ménière disease who underwent the IV-method ( $n = 9$ ), the CM ratio of the affected side ( $1.86 \pm 0.74$ ) was higher than that of the unaffected side ( $1.29 \pm 0.31$ ,  $P < .05$ ).

**CONCLUSIONS:** In general, the IT-method provides higher perilymph enhancement than the IV-method. In the patients with unilateral Ménière disease who underwent the IV-method, the affected side had a higher contrast effect.

**ABBREVIATIONS:** CM = cochlea/medulla oblongata; CWM = cerebellar white matter/medulla oblongata; Gd-DTPA = gadolinium-diethylene-triamine pentaacetic acid; Gd-HP-DO3A = gadoteridol; IT = intratympanic; r1 = T1 relaxivity; SNHL = sensorineural hearing loss

**F**LAIR imaging is a sensitive technique for the detection of high-protein-content fluid or tissue in the CSF such as in acute meningitis or subarachnoid hemorrhage and various cystic intracranial mass lesions.<sup>1,2</sup> 3D-FLAIR imaging can minimize the undesired ghosts of CSF flow<sup>3</sup> and enable recognition of the subtle compositional changes in lymph fluid in the inner ear.<sup>4-6</sup> In addition, increased signal intensity of the diseased inner ear can also be observed on 3D-FLAIR imaging shortly after IV gadolinium injection; this technique has been reported to be useful for pathophysiologic analysis of the inner ear in many auditory diseases, such as sudden SNHL, cholesteatoma, cochlear otosclerosis, and vestibular schwannoma.<sup>7-10</sup>

3D-FLAIR imaging 24 hours after intratympanic gadolin-

ium injection (IT-method) has been reported to visualize perilymph and endolymph fluid separately and to enable preliminary prediction of drug distribution to the inner ear, such as gentamicin and steroids.<sup>11-14</sup> The sensitivity of gadolinium-agent detection in perilymph 24 hours after intratympanic gadolinium injection on 3D-FLAIR has been reported to be superior to that on 3D-T1-weighted imaging or on the 3D-constructive interference in steady state sequence,<sup>15</sup> suggesting that 3D-FLAIR would be most suited for signal-intensity-alteration assessment 24 hours after intratympanic gadolinium injection. On the other hand, 3D-FLAIR imaging 4 hours after IV gadolinium injection (IV-method) also has been recently reported to visualize perilymph and endolymph fluid separately, in a less invasive manner than the IT-method, and also enables ascertaining the presence of endolymphatic hydrops in bilateral cochleae.<sup>16,17</sup> Consequently, both the IT-method and IV-method are useful techniques for clarification of the inner ear clinical condition, though a statistical analysis of signal-intensity differences in the perilymph fluid between the 2 methods has not been previously reported, to our knowledge. The principal purpose of the present study was to evaluate the signal intensity of the cochlear perilymph by using both the IT-method and IV-method and to clarify the differences in contrast effect between these 2 techniques. In addition, the contrast effect difference in the cochlear perilymph with the IV-method between affected and unaffected sides in patients with unilateral Ménière disease was also evaluated to

Received January 11, 2011; accepted after revision July 8.

From the Departments of Radiology (M.Y., S.N., H.K.) and Otorhinolaryngology (M.Tagaya, M.S., M.Teranishi, H.S., T.N.), Nagoya University Graduate School of Medicine, Nagoya, Japan; and Department of Radiological Technology (M.I.), Nagoya University School of Health Sciences, Nagoya, Japan.

This work was supported by a Grant-in-Aid for Scientific Research (B) 22390233 from the Japan Society for the Promotion of Science.

Please address correspondence to Masahiro Yamazaki, MD, Department of Radiology, Nagoya University Graduate School of Medicine, 65 Tsurumai-cho, Showa-ku, Nagoya, 466-8550, Japan; e-mail: yamazaki@med.nagoya-u.ac.jp



Indicates open access to non-subscribers at [www.ajnr.org](http://www.ajnr.org)

<http://dx.doi.org/10.3174/ajnr.A2821>

infer the condition of the blood-labyrinth-barrier permeability of patients with Ménière disease.

## Materials and Methods

### Study Population

The records of 61 consecutive patients who underwent the IT-method (39 patients) or the IV-method (22 patients) of MR imaging of the inner ear at our hospital from October 2008 to January 2010 were retrospectively examined. The number of patients who underwent the IT-method was larger than that of patients who underwent the IV-method because the IT-method was performed in clinical research before the administration of the IV-method. The 39 IT-method patients (19 men, 20 women; 16–80 years of age; mean age, 49.9 years), 33 with clinically diagnosed Ménière disease (17 men, 16 women; 16–80 years of age; mean age, 50.0 years) and 6 with sudden SNHL (2 men, 4 women; 26–67 years of age; mean age, 49.8 years), underwent unilateral intratympanic administration of Gd-DTPA (Magnevist; Bayer Schering, Osaka, Japan). These patients were evaluated for clinically severe vertigo or hearing loss and underwent intratympanic gadolinium injection for simulation of intratympanic injection therapy with gentamicin to control severe vertigo or with steroids to treat SNHL.<sup>18–21</sup> On the other hand, the 22 IV-method patients (9 men, 13 women; 21–76 years of age; mean age, 49.0 years), 17 with clinically diagnosed Ménière disease (7 men, 10 women; 21–74 years of age; mean age, 46.6 years) and 5 with sudden SNHL (2 men, 3 women; range, 42–76 years of age; mean age, 57.2), underwent IV administration of Gd-HP-DO3A (ProHance; Eisai, Tokyo, Japan). These patients were evaluated for vertigo for which we were not planning to administer intratympanic injection therapy immediately because the degree of vertigo was not severe enough to restrict daily life, with bilateral disease presentation or before the application of initial therapies such as administration of isosorbide or systemic steroid therapy. These decisions concerning which method to apply were made by otorhinolaryngologists in charge clinically, because there are no categorical sorting criteria in the choice of the IT- and IV-methods at present. In the present study, IV administration of Gd-HP-DO3A was performed as a double dose (0.4 mL/kg body weight [ie, 0.2 mmol/kg body weight]). Although the standard dose of gadolinium contrast agent is 0.2 mL/kg body weight, a dose of 0.4 mL/kg body weight is permitted only for Gd-HP-DO3A in our country by the Japanese governmental health insurance system if the aim is to visualize metastatic brain tumors. Therefore, we used Gd-HP-DO3A for a double-dose IV administration with written informed consent from all patients for research funded by the Japan Society for the Promotion of Science. The gadolinium contrast agents used in the IT-method and IV-method were different because the evaluation of endolymphatic hydrops by the IT-method by using Gd-DTPA was performed in clinical research before the administration of the IV-method using a double dose of Gd-HP-DO3A. The Gd-DTPA was used for the IT-method at least until January 2010 because there was an accumulation of data on the IT-method with Gd-DTPA before the administration of IV-method with a double-dose of Gd-HP-DO3A. We obtained written informed consent from all patients and study approval from the Ethics Review Committee of our institution (approval numbers 369, 369-2, 369-3, and 369-4).

### Intratympanic Gadolinium Injection

Intratympanic injection of gadolinium was performed as reported previously<sup>11</sup> in a study that indicated a delay of 24 hours between

intratympanic gadolinium injection and MR imaging to be optimal for allowing wide gadolinium distribution in the perilymphatic space of the labyrinth.

Briefly, Gd-DTPA (500 mmol/L) was diluted 8-fold with saline (volume/volume 1:7) and injected intratympanically by using a 23-ga needle and a 1-mL syringe after the patient was placed in the supine position with the head turned approximately 30° away from the sagittal line toward the healthy ear. The diluted Gd-DTPA was injected until a backflow of fluid into the external ear was observed through a microscope, resulting in an injected volume of 0.4–0.5 mL per patient. After the injection, the patient remained in the supine position for 60 minutes with the head turned approximately 60° away from the sagittal line toward the healthy ear. Gentamicin or steroids were not injected at the same time as Gd-DTPA. All patients underwent MR imaging 24 hours after intratympanic gadolinium injection.

### IV Gadolinium Injection

All patients underwent IV administration of a double dose (0.4 mL/kg body weight, [ie, 0.2 mmol/kg body weight]) of Gd-HP-DO3A. Although the standard dose of gadolinium contrast agent is 0.2 mL/kg body weight, a dose of 0.4 mL/kg body weight is permitted only for Gd-HP-DO3A in our country by the Japanese governmental health insurance system if the aim is to visualize metastatic brain tumors. Therefore, we used Gd-HP-DO3A for a double-dose IV administration with written informed consent from all patients and study approval from the Ethics Review Committee of our institution as a research funded by Japan Society for the Promotion of Science. All patients underwent MR imaging 4 hours after IV gadolinium injection because a delay of 4 hours between IV gadolinium injection and MR imaging is reported to be optimal to allow wide gadolinium distribution in the perilymphatic space of the labyrinth.<sup>22</sup>

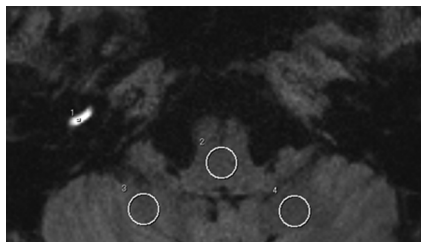
### MR Imaging Protocol

All scans were performed on a 3T MR imaging scanner (Magnetom Trio; Siemens, Erlangen, Germany) by using a receive-only 32-channel phased-array coil. Patients underwent 3D-FLAIR imaging 24 hours after intratympanic injection of diluted Gd-DTPA or 4 hours after IV injection of a double-dose of Gd-HP-DO3A.

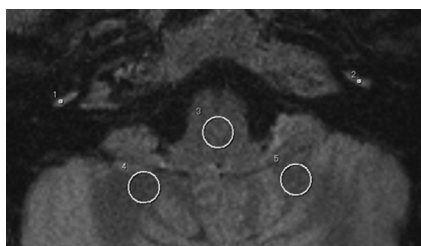
The parameters for 3D-FLAIR were as follows: TR, 9000 ms; TE<sub>eff</sub>, 458 ms; TI, 2500 ms; variable flip-angle echo-train with average flip angle, 120°; echo-train length, 119; matrix size, 256 × 256; 48 axial 0.8-mm thick sections covering the labyrinth with 180 × 150 mm FOV; generalized autocalibrating partially parallel acquisition acceleration factor, 2; voxel size, 0.7 × 0.7 × 0.8 mm; NEX, 2; scanning time, 5 minutes 26 seconds; readout bandwidth, 592 Hz/pixel; and echo spacing, 3.7 ms.

### MR Imaging Evaluation and Statistical Analysis

We analyzed images on a PACS workstation (Rapid Eye Station; Toshiba Medical Systems, Otawara, Japan) (Figs 1 and 2). For each patient who underwent intratympanic gadolinium injection, we determined a circular 0.6-mm<sup>2</sup> region of interest of the injected-side cochlea and a circular 50-mm<sup>2</sup> region of interest of the medulla oblongata on 3D-FLAIR images at a workstation. In the same way, for each patient who underwent IV gadolinium injection, we determined a circular 0.6-mm<sup>2</sup> region of interest of both cochleae and a circular 50-mm<sup>2</sup> region of interest of the medulla oblongata on 3D-FLAIR images. Instead of the vestibule, we chose the cochlea for the assessment of inner ear contrast effect because the presumed location of diffusion of intratympanically injected gadolinium from the middle



**Fig 1.** A 3D-FLAIR image at the level of the cochlear basal turns after intratympanic gadolinium injection of the right side (IT-method) of a 63-year-old woman with right sudden SNHL is presented. The intratympanic gadolinium injection was administered 24 hours before MR imaging, and the right cochlear basal turn has extremely high signal intensity. On this image, a 0.6-mm<sup>2</sup> circular region of interest on the scala tympani of the cochlear basal turn of the gadolinium-injected side, a 50-mm<sup>2</sup> circular region of interest on the center of the medulla oblongata, and a 50-mm<sup>2</sup> circular region of interest on the cerebellar white matter of both cerebellar hemispheres are set.



**Fig 2.** A 3D-FLAIR image at the level of the cochlear basal turns after IV gadolinium injection (IV-method) of a 21-year-old woman with bilateral Ménière disease is presented. The IV gadolinium injection was administered 4 hours before MR imaging, and both cochlear basal turns have high signal intensity. On this image, a 0.6-mm<sup>2</sup> circular region of interest on the scala tympani of both cochlear basal turns, a 50-mm<sup>2</sup> circular region of interest on the center of the medulla oblongata, and a 50-mm<sup>2</sup> circular region of interest on the cerebellar white matter of both cerebellar hemispheres are set.

ear to inner ear is the round window. On each cochlea, we set the region of interest on the scala tympani of the basal turn because the gadolinium agent injected into the tympanic cavity distributes into the perilymph space of the scala tympani through the round window initially and elevation of the cochlear signal intensity is most easily observed at this position 24 hours after intratympanic gadolinium injection.<sup>11</sup> Intravenously administered gadolinium agent also distributes into the perilymph space of the scala tympani through the blood-perilymph barrier, and elevation of the cochlear basal turn signal intensity is most easily observed 4 hours after IV gadolinium injection on 3D-FLAIR in human subjects.<sup>16,22,23</sup> The region of interest of the medulla oblongata was set on the center of the medulla oblongata at the identical section of the basal turn of the cochlea. The region of interest of the medulla oblongata did not include the signal intensity of CSF or vessels. We evaluated the ratio of the cochlear signal intensity of each cochlea to that of the medulla oblongata (CM ratio). The IT-method CM ratio was evaluated only on the gadolinium-injected side, whereas the IV-method CM ratio was evaluated on both sides. In calculating the CM ratio, we selected the medulla oblongata for reference to enable statistical comparison of the cochlear signal intensity of the IT-method and IV-method and to enable statistical comparison of the cochlear signal intensity of both sides with the IV-method.<sup>10,15</sup> The results by simple measurement of the signal-intensity ratio on MR imaging have been reported to correlate well with those by a more quantitative method.<sup>24</sup> We determined the circular 50 mm<sup>2</sup> regions of interest for cerebellar white matter of both cerebellar hemispheres at the identical section of the basal turn of the cochlea on each image and evaluated the ratio of the signal intensity of each cerebellar white matter to that of the medulla oblongata (WM

ratio) to estimate the uniformity of the magnetic field. One radiologist (M.Y.), with knowledge of prior intratympanic or IV gadolinium injection and diagnoses, performed these measurements. Blinded measurement of the signal intensity without the knowledge of which method was performed was not feasible in the present study because the IT-method patients represented high signal intensity of the unilateral inner ear, while the IV-method patients represented the contrast effect on both inner ears. To ensure the reliability of the signal intensity measured in the small region of interest of the cochlea and to diminish the measurement error, we determined every region of interest twice for each patient on different days and averaged the signal intensities of the 2 measurements for analysis.

A Student *t* test was used to compare the differences in CM ratio between the IT-method and the IV-method, and in the mean age between IT-method and IV-method patients. A paired *t* test was used to compare the differences in the IV-method CM ratio between the affected and unaffected sides in patients with unilateral Ménière disease (affected and unaffected sides were determined by clinical assessments of hearing loss, tinnitus, and aural fullness) and to compare the WM ratio between right and left sides. The Fisher exact probability test was used to compare the difference in sex ratio between IT-method and IV-method patients. In this study, *P* < .05 represented statistical significance.

The existence or nonexistence of gross body motion, which induces motion artifacts, visible signal intensity abnormalities of medulla oblongata (eg, infarction, degenerative disorder), or mastoid air cells (eg, otitis media, cholesterol granuloma) was assessed visually at the time of cochlear analysis. The existence or nonexistence of side effects (eg, nausea, vomiting, exanthem, subjective exacerbation of vertigo, or hearing loss) attributed to the IT-method or IV-method was also observed.

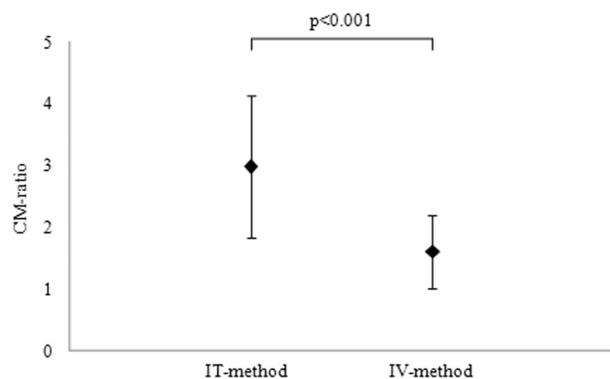
In 5 patients with sudden SNHL who underwent the IV-method, 3 patients had bilateral hearing loss (the average hearing levels with the average score at 500, 1000, and 2000 Hz were >50 dB) and 2 patients had unilateral loss. In those 3 patients who had bilateral hearing loss, 2 had simultaneous occurrence of sudden SNHL of both ears, and the other patient had a history of sudden SNHL, which resulted in sustained hearing loss and metachronous onset of sudden SNHL of the other side. The IV-method CM ratio of the 2 unaffected ears, which did not have severe hearing loss (the average hearing levels as the average score at 500, 1000, and 2000 Hz were <40 dB), of the 2 patients with unilateral sudden SNHL was observed to evaluate the contrast effect of the cochleae, which were regarded as controls 4 hours after double-dose IV gadolinium injection.

## Results

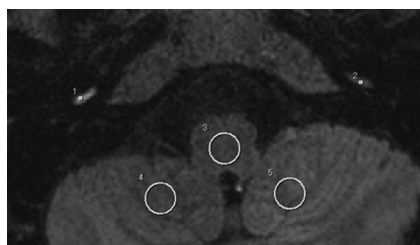
No image of any patient showed gross body motion during the examination or visible abnormality of the medulla oblongata or mastoid air cells. The mean age and the sex ratio did not differ significantly between the IT-method and IV-method patients (*P* = .83 for mean age, *P* = .38 for sex ratio). The WM ratio between the right and left sides did not differ significantly for either method (IT-method: right side mean WM ratio, 1.01 ± 0.09; range, 0.86–1.29; left side mean WM ratio, 1.02 ± 0.12; range, 0.80–1.28; *P* = .66; IV-method: right side mean WM ratio, 0.97 ± 0.09; range, 0.82 to 1.12; left side mean WM ratio, 0.98 ± 0.10; range, 0.80–1.17; *P* = .79).

The IT-method CM ratio (2.98 ± 1.15; range, 0.43–4.63; *n* = 39) was significantly higher than the IV-method CM ratio (1.61 ± 0.60; range, 0.95–3.66; *n* = 44) (*P* < .001, Fig 3). In the

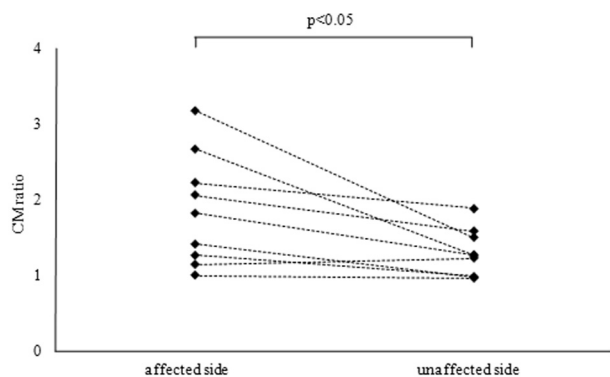




**Fig 3.** Signal-intensity ratios between the cochlea and medulla oblongata (CM ratio) on 3D-FLAIR imaging 24 hours after intratympanic gadolinium injection (IT-method) and 3D-FLAIR imaging 4 hours after IV gadolinium injection (IV-method). The IT-method CM ratio ( $2.98 \pm 1.15$ ; range, 0.43–4.63;  $n = 39$ ) is significantly higher than the IV-method CM ratio ( $1.61 \pm 0.60$ ; range, 0.95–3.66;  $n = 44$ ) ( $P < .001$ ).



**Fig 4.** A 3D-FLAIR image at the level of the cochlear basal turns after IV gadolinium injection (IV-method) in a 36-year-old woman with right-sided unilateral Ménière disease is presented. The IV gadolinium injection was administered 4 hours before MR imaging, and the right cochlear basal turn has higher signal intensity than the left cochlear basal turn. On this image, a 0.6-mm<sup>2</sup> circular region of interest on the scala tympani of both cochlear basal turns, a 50-mm<sup>2</sup> circular region of interest on the center of the medulla oblongata, and a 50-mm<sup>2</sup> circular region of interest on the cerebellar white matter of both cerebellar hemispheres are set.



**Fig 5.** Signal-intensity ratios between the cochlea and medulla oblongata (CM ratio) of affected and unaffected sides in patients with unilateral Ménière disease who underwent 3D-FLAIR imaging 4 hours after IV gadolinium injection (IV-method) ( $n = 9$ ). The identical patients' affected- and unaffected-side CM ratios are connected by the dotted lines. The mean CM ratio of the affected side ( $1.86 \pm 0.74$ ; range, 0.99–3.17) is statistically higher than that of the unaffected side ( $1.29 \pm 0.31$ ; range, 0.95–1.88) ( $P < .05$ ).

patients with unilateral Ménière disease who underwent the IV-method ( $n = 9$ ), the CM ratio of the affected side ( $1.86 \pm 0.74$ ; range, 0.99–3.17) was significantly higher than that of the unaffected side ( $1.29 \pm 0.31$ ; range, 0.95–1.88) ( $P < .05$ ; Figs 4 and 5). The IT-method CM ratio ( $2.98 \pm 1.15$ ; range, 0.43–4.63;  $n = 39$ ) was significantly higher than the IV-method CM ratio in the affected side in patients with unilat-

eral Ménière disease ( $1.86 \pm 0.74$ ; range, 0.99–3.17;  $n = 9$ ) ( $P < .01$ ). No side effects were observed in either IT- or IV-method patients. In 2 unaffected ears of 2 patients with unilateral sudden SNHL who underwent the IV-method, the average hearing levels as the average score at 500, 1000, and 2000 Hz and the CM ratio were as follows: 23.3 dB, 1.02; 38.3 dB, 1.32.

## Discussion

To the best of our knowledge, this is the first report to describe the differences in contrast effect in the cochlear perilymph between gadolinium contrast agents injected either intratympanically or intravenously in human patients. Both methods have recently been applied to the in-depth investigation of endolymphatic hydrops clinically. The results of the present study suggest that the IT-method provides higher perilymph enhancement than the IV-method in general. Usually gadolinium agents injected either intratympanically or intravenously are distributed in the perilymph but not in the endolymph. Therefore, the IT-method can provide stronger endolymph/perilymph contrast in general, thereby enabling the observer to more precisely estimate the degree of endolymphatic hydrops. In addition, the IT-method is a useful preliminary prediction tool of drug distribution to the inner ear, such as the distribution of gentamicin and steroids after intratympanic administration.<sup>11–14</sup> For the patients with an inner ear disorder who have restrictions in daily life caused by vertigo or hearing loss, further imaging investigation of the inner ear and preliminary prediction of drug distribution to the inner ear are extremely important matters to improve their quality of life. Therefore, the features of the IT-method observed in the present study warrant considering their advantage for the close investigation of inner ear disorders.

On the other hand, the IT-method has some restrictions. It is capable of detailed investigation of endolymphatic hydrops only on the gadolinium-injected side. Therefore, the patients whose ears need to be investigated on both sides have to be injected twice. In addition, the patients have to undergo additional injection in case the adhibition of intratympanic drug injection therapies were decided. Furthermore, in the IT-method group of the present study, the SD of the CM ratio was larger than that of the IV-method group, and in some patients the CM ratio was extremely low. Two IT-method patients had a CM ratio  $< 0.70$ , while the lowest CM ratio of the IV-method group was 0.95. These results suggest inadequate transition of the gadolinium agent from the tympanic cavity to the perilymph space through the round window in some patients and that the degree of the contrast effect of perilymph after intratympanic gadolinium injection may have larger interindividual differences than that after IV injection. The permeability of the round window was reported to be poor in 13% of ears in patients with inner ear disorders who underwent intratympanic gadolinium injection.<sup>25</sup> In such patients with inadequate transition of gadolinium agent to the perilymph, detailed evaluation of endolymphatic hydrops is difficult and insufficient drug distribution from the tympanic cavity to the inner ear is anticipated, though it is difficult to predict the degree of gadolinium transition before an MR imaging examination. In the present study, 2 patients underwent both the IT-method and the IV-method. These patients had an ex-

tremely inadequate transition of gadolinium agent from tympanic cavity to the perilymphatic space after intratympanic gadolinium injection. It may be useful to compare gadolinium agent transition from the tympanic cavity to the perilymphatic space with a control group who do not have inner ear disorders for further investigation of round window permeability, and it should be a future research project.

The IV-method has features complementary to the IT-method. The IV-method is capable of detailed investigation of endolymphatic hydrops in both ears, though in general, the degree of perilymph enhancement is lower with the IV-method than the IT-method. In the present study, the procedure of IV gadolinium injection in the IV-method was the same as that in normal clinical use, though the dose was doubled for our study. Therefore, the difficulty level of the procedure and invasiveness would be lower than those in the IT-method. In addition, the results of the present study suggest that the variability of the degree of perilymph enhancement is also likely to be less with the IV-method. Consequently, steady enhancement would be expected by using the IV-method. Furthermore, a recent report suggests that a heavily T2-weighted 3D-FLAIR technique would improve the sensitivity of low-concentration gadolinium contrast detection.<sup>26</sup> Although the heavily T2-weighted 3D-FLAIR technique would be preferable to detect low-concentration gadolinium in the inner ear (eg, 4 hours after single-dose IV gadolinium injection), we applied conventional 3D-FLAIR in the present study to compare the IT- and IV-method contrast effect differences because the number of the patients undergoing conventional 3D-FLAIR after intratympanic or double-dose IV gadolinium injection was larger than that of the patients undergoing the heavily T2-weighted 3D-FLAIR at present. On the other hand, the IV-method cannot provide a preliminary prediction of drug distribution to the inner ear from the tympanic cavity, which is possible with the IT-method.

In patients with unilateral Ménière disease who underwent the IV-method, the contrast effect of the affected side was significantly higher than that of the unaffected side, which is similar to the results of a previous study by Tagaya et al,<sup>27</sup> in which they analyzed almost the same patient groups from our institution, though the observer and the references for cochlear signal intensity calculation were different. The results of the present study and of the previous report suggest increased permeability of the blood-labyrinth barrier (more precisely, the blood-perilymph barrier) on the affected side of patients with unilateral Ménière disease. This increased permeability of the blood-labyrinth barrier may have a role in the pathologic condition of Ménière disease, though further investigation is required to clarify this matter.

In 2 unaffected ears of 2 patients with unilateral sudden SNHL who underwent the IV-method, the average hearing levels as the average score at 500, 1000, and 2000 Hz and the CM ratio were as follows: 23.3 dB, 1.02; 38.3 dB, 1.32. In the previous unilateral IT-method study, which applied methods completely identical to those in the present study, the mean CM ratio for the gadolinium noninjected side was  $0.52 \pm 0.14$  (range, 0.30–0.76;  $n = 21$ ).<sup>15</sup> The CM ratio of the 2 unaffected ears of 2 patients with unilateral sudden SNHL who underwent double-dose IV gadolinium injection in the present study was higher than that for the gadolinium noninjected side

in the previous study. Furthermore, another previous study revealed the cochlear fluid enhancement 4 hours after single-dose IV gadolinium injection on 3D-FLAIR in healthy subjects.<sup>22</sup> Therefore, the cochlear enhancement should be observed 4 hours after double-dose IV gadolinium injection in healthy people, though further investigation is required to clarify this matter because the number of controls in the present study was too small for statistical analysis.

In the present study, no side effects relating to gadolinium injection were observed. In animal experiments by using intratympanic gadolinium injection, gadolinium was diluted 8-fold with saline, which is the concentration of gadolinium used in the previous and the present human studies, and showed no marked effect on the stria vascularis.<sup>28</sup> The reports describing intratympanic gadolinium injection in human subjects have been published from several institutions, including ours,<sup>11–15,23–25,29–31</sup> and no marked side effects in the inner ear relating to intratympanic gadolinium injection have been reported on clinical application at present, to the best of our knowledge. In addition, intravenously administered gadolinium has been reported to infiltrate inner ear perilymph,<sup>16,17,22,23</sup> and no marked side effects in the inner ear relating to IV gadolinium injection have been reported in the clinical application at present. Therefore, gadolinium agent use in the clinical setting appears safe for inner ear imaging, but future study requires continued vigilance regarding the small possibility of side effects.

The limitations of the present study were that the signal-intensity measurement was semiquantitative without the use of external phantoms for reference, the size of the region of interest of the cochlea was small, only 1 radiologist performed the measurements, the gadolinium contrast agents used in the IT-method and IV-method were different, control study of contrast effect between these agents was not done, the IT-method was invasive, and the IT-method was not performed on both sides in all patients. Although the signal-intensity measurement was semiquantitative, the results by simple measurement of signal-intensity ratio on MR imaging have been reported to correlate well with those obtained by a more quantitative method.<sup>24</sup> In addition, we believe that the small size of the region of interest of the cochleae does not seriously affect the results of the present study because the gadolinium agent distribution to the perilymph was detected on all images, allowing the region of interest to be set with accuracy. To ensure the reliability of the signal intensity measured in the small region of interest of the cochlea and to diminish the measurement error, we determined every region of interest twice for each patient on different days and averaged the signal intensities of the 2 measurements for analysis. Although the gadolinium contrast agents used in the IT-method and IV-method were different and a control study of contrast effect between these agents was not done (Gd-DTPA for the IT-method: molecular weight, 742.79; osmotic pressure ratio to saline, approximately 7; viscosity, 3.03 mPa·s, 37°C; and T1  $r_1$ , 4.9 mmol/L<sup>-1</sup>·s<sup>-1</sup>; Gd-HP-DO3A for the IV-method: molecular weight, 558.69; osmotic pressure ratio to saline, approximately 2; viscosity, 1.3 mPa·s, 37°C; and  $r_1$ , 4.6 mmol/L<sup>-1</sup>·s<sup>-1</sup>), these differences in the gadolinium contrast agents would not have seriously affected the results of the present study, because the  $r_1$  of Gd-DTPA and Gd-HP-DO3A is ap-

proximately equal. The fact that the IT-method was not performed on both sides has the potential to bias the results, but injecting gadolinium agent into both sides in all patients should be considered carefully because the IT-method has an invasive character compared with the IV-method.

## Conclusions

Overall, the results of the present study suggest that in general, the IT-method provides higher perilymph enhancement than the IV-method. Although the IT-method has higher perilymph enhancement and prediction ability of intratympanically injected drug transition to the inner ear, the IV-method is less invasive and enables observation of the bilateral cochlear condition steadily. Consequently, the appropriate technique must be chosen with consideration of the clinical characteristics of each patient. In addition, the affected-side cochlea had higher contrast effect compared with the unaffected side in patients with unilateral Ménière disease who underwent the IV-method. This difference in the contrast effect may reflect the pathologic condition of Ménière disease.

## Acknowledgments

We thank the radiologic technologists of the MR imaging unit at our institution for their contribution to the MR imaging examinations.

## References

- Melhem ER, Jara H, Eustace S. Fluid-attenuated inversion recovery MR imaging: identification of protein concentration threshold for CSF hyperintensity. *AJR Am J Roentgenol* 1997;169:859–62
- Mishra AM, Reddy SJ, Husain M, et al. Comparison of the magnetization transfer ratio and fluid-attenuated inversion recovery imaging signal intensity in differentiation of various cystic intracranial mass lesions and its correlation with biological parameters. *J Magn Reson Imaging* 2006;24:52–56
- Naganawa S, Koshikawa T, Nakamura T, et al. Comparison of flow artifacts between 2D-FLAIR and 3D-FLAIR sequences at 3T. *Eur Radiol* 2004;14:1901–08
- Sugiura M, Naganawa S, Sato E, et al. Visualization of a high protein concentration in the cochlea of a patient with a large endolymphatic duct and sac, using three-dimensional fluid-attenuated inversion recovery magnetic resonance imaging. *J Laryngol Otol* 2006;120:1084–86
- Sugiura M, Naganawa S, Teranishi M, et al. Inner ear hemorrhage in systemic lupus erythematosus. *Laryngoscope* 2006;116:826–28
- Otake H, Sugiura M, Naganawa S, et al. 3D-FLAIR magnetic resonance imaging in the evaluation of mumps deafness. *Int J Pediatr Otorhinolaryngol* 2006;70:2115–17
- Sugiura M, Naganawa S, Teranishi M, et al. Three-dimensional fluid-attenuated inversion recovery magnetic resonance imaging findings in patients with sudden sensorineural hearing loss. *Laryngoscope* 2006;116:1451–54
- Sone M, Mizuno T, Sugiura M, et al. Three-dimensional fluid-attenuated inversion recovery magnetic resonance imaging investigation of inner ear disturbances in cases of middle ear cholesteatoma with labyrinthine fistula. *Otol Neurotol* 2007;28:1029–33
- Sugiura M, Naganawa S, Sone M, et al. Three-dimensional fluid attenuated inversion recovery magnetic resonance imaging findings in a patient with cochlear otosclerosis. *Auris Nasus Larynx* 2008;35:269–72
- Yamazaki M, Naganawa S, Kawai H, et al. Increased signal intensity of the cochlea on pre- and post-contrast enhanced 3D-FLAIR in patients with vestibular schwannoma. *Neuroradiology* 2009;51:855–63
- Nakashima T, Naganawa S, Sugiura M, et al. Visualization of endolymphatic hydrops in patients with Ménière's disease. *Laryngoscope* 2007;117:415–20
- Naganawa S, Sugiura M, Kawamura M, et al. Imaging of endolymphatic and perilymphatic fluid at 3T after intratympanic administration of gadolinium-diethylene-triamine pentaacetic acid. *AJNR Am J Neuroradiol* 2008;29:724–26. Epub 2008 Jan 9
- Naganawa S, Satake H, Iwano S, et al. Imaging endolymphatic hydrops at 3 Tesla using 3D-FLAIR with intratympanic Gd-DTPA administration. *Magn Reson Med Sci* 2008;7:85–91
- Teranishi M, Naganawa S, Katayama N, et al. Image evaluation of endolymphatic space in fluctuating hearing loss without vertigo. *Eur Arch Otorhinolaryngol* 2009;266:1871–77
- Yamazaki M, Naganawa S, Kawai H, et al. Signal alteration of the cochlear perilymph on 3 different sequences after intratympanic Gd-DTPA administration at 3 Tesla: comparison of 3D-FLAIR, 3D-T1-weighted imaging, and 3D-CISS. *Magn Reson Med Sci* 2010;9:65–71
- Nakashima T, Naganawa S, Teranishi M, et al. Endolymphatic hydrops revealed by intravenous gadolinium injection in patients with Ménière's disease. *Acta Otolaryngol* 2010;130:338–43
- Tagaya M, Teranishi M, Naganawa S, et al. 3 Tesla magnetic resonance imaging obtained 4 hours after intravenous gadolinium injection in patients with sudden deafness. *Acta Otolaryngol* 2010;130:665–69
- Schwaber MK. Transtympanic gentamicin perfusion for the treatment of Ménière's disease. *Otolaryngol Clin North Am* 2002;35:287–95
- De Stefano A, Dispenza F, De Donato G, et al. Intratympanic gentamicin: a 1-day protocol treatment for unilateral Ménière's disease. *Am J Otolaryngol* 2007;28:289–93
- Haynes DS, O'Malley M, Cohen S, et al. Intratympanic dexamethasone for sudden sensorineural hearing loss after failure of systemic therapy. *Laryngoscope* 2007;117:3–15
- Ahn JH, Han MW, Kim JH, et al. Therapeutic effectiveness over time of intratympanic dexamethasone as salvage treatment of sudden deafness. *Acta Otolaryngol* 2008;128:128–31
- Naganawa S, Komada T, Fukatsu H, et al. Observation of contrast enhancement in the cochlear fluid space of healthy subjects using a 3D-FLAIR sequence at 3 Tesla. *Eur Radiol* 2006;16:733–37
- Zou J, Poe D, Bjelke B, et al. Visualization of inner ear disorders with MRI in vivo: from animal models to human application. *Acta Otolaryngol Suppl* 2009;560:22–31
- Naganawa S, Ishihara S, Iwano S, et al. Estimation of gadolinium-induced T1-shortening with measurement of simple signal intensity ratio between the cochlea and brain parenchyma on 3D-FLAIR: correlation with T1 measurement by T1 scout sequence. *Magn Reson Med Sci* 2010;9:17–22
- Yoshioka M, Naganawa S, Sone M, et al. Individual differences in the permeability of the round window: evaluating the movement of intratympanic gadolinium into the inner ear. *Otol Neurotol* 2009;30:645–48
- Naganawa S, Kawai H, Sone M, et al. Increased sensitivity to low concentration gadolinium contrast by optimized heavily T2-weighted 3D-FLAIR to visualize endolymphatic space. *Magn Reson Med Sci* 2010;9:73–80
- Tagaya M, Yamazaki M, Teranishi M, et al. Endolymphatic hydrops and blood-labyrinth barrier in Ménière's disease. *Acta Otolaryngol* 2011;131:474–79
- Kakigi A, Nishimura M, Takeda T, et al. Effects of gadolinium injected into the middle ear on the stria vascularis. *Acta Otolaryngol* 2008;128:841–45
- Fukuoka H, Tsukada K, Miyagawa M, et al. Semi-quantitative evaluation of endolymphatic hydrops by bilateral intratympanic gadolinium-based contrast agent (GBCA) administration with MRI for Meniere's disease. *Acta Otolaryngol* 2010;130:10–16
- Fiorino F, Pizzini FB, Beltramello A, et al. MRI performed after intratympanic gadolinium administration in patients with Ménière's disease: correlation with symptoms and signs. *Eur Arch Otorhinolaryngol* 2011;268:181–87
- Horii A, Osaki Y, Kitahara T, et al. Endolymphatic hydrops in Meniere's disease detected by MRI after intratympanic administration of gadolinium: comparison with sudden deafness. *Acta Otolaryngol* 2011;131:602–09. Epub 2011 Feb 23