



Get Clarity On Generics

Cost-Effective CT & MRI Contrast Agents



FRESENIUS
KABI

WATCH VIDEO

AJNR

A Case of Delayed Encephalopathy after Carbon Monoxide Poisoning Longitudinally Monitored by Diffusion Tensor Imaging

H. Kuroda, K. Fujihara, S. Takahashi, Y. Shinozawa and Y. Itoyama

This information is current as of August 10, 2025.

AJNR Am J Neuroradiol 2012, 33 (4) E52-E54

doi: <https://doi.org/10.3174/ajnr.A2600>

<http://www.ajnr.org/content/33/4/E52>

CASE REPORT

H. Kuroda
K. Fujihara
S. Takahashi
Y. Shinozawa
Y. Itoyama

A Case of Delayed Encephalopathy after Carbon Monoxide Poisoning Longitudinally Monitored by Diffusion Tensor Imaging

SUMMARY: A woman with DE after CO poisoning was longitudinally evaluated by DTI, performed during the following periods: at the phase of acute CO poisoning, the lucid interval, neurologic deterioration due to DE, and neurologic recovery. The present case revealed the long-term course of DTI parameters after CO poisoning and the usefulness of DTI for quantifying neurologic damage after CO poisoning.

ABBREVIATIONS: ADC = apparent diffusion coefficient; CO = carbon monoxide; DE = delayed encephalopathy; DTI = diffusion tensor imaging; FA = fractional anisotropy; GCS = Glasgow Coma Scale; HBO = hyperbaric oxygen therapy; WM = white matter

CO is one of the leading causes of poisoning worldwide. Clinical manifestations of acute CO poisoning include headache, dizziness, weakness, and consciousness disturbance. Severe CO poisoning often results in a fatal outcome, and if victims recover from acute poisoning, some develop DE, clinically characterized by relapsed consciousness disturbance, seizure, cognitive impairment, and movement disorders such as parkinsonism.¹ DE is caused by demyelination of WM, but no effective treatments or established methods for its early detection are available.

DTI, detecting the mobility of free water molecules, has been recently used to assess WM damage due to various neurologic diseases.² Although DTI has also been used to detect DE,^{3,4} the long-term course of DTI parameters after CO poisoning is still unclear. We herein report a case with DE after CO poisoning longitudinally monitored by DTI.

Case Report

A 45-year-old woman who inhaled charcoal gas in an attempted suicide was taken by ambulance to a hospital in 2008. Her consciousness level on admission was 8 on the GCS, and her arterial carboxyhemoglobin level was 23.5%. She was treated with HBO at 2.8 atm an hour per session, 7 sessions a week. She became alert (GCS 15) on the fourth day in the hospital, though conventional brain MR imaging showed necrotic lesions of the bilateral globus pallidus. Mini-Mental State Examination scores were subnormal (24/30) on the 17th day. Conventional MR imaging on the 23rd day showed no apparent change from the initial MR imaging. However, DTI indicated that FA and ADC values had begun to decline from the initial ones.

Her mental state deteriorated rapidly from the 24th day, with appearance of WM abnormalities detectable by conventional MR imaging. According to her clinical and radiologic course, she was diagnosed as having DE. Consequently, she was treated with HBO again and with intravenous corticosteroids and edaravone, a free

radical scavenger. Nevertheless, her neurologic deterioration persisted; furthermore, MR imaging on the 31st day showed rapid expansion of WM abnormalities with continuous decline of FA and ADC values. The neurologic deterioration peaked on the 35th day, when she had moderate consciousness disturbance (GCS 11) with parkinsonism. ADC and FA values reached their lowest on the 38th and the 54th day, respectively. From the 35th day, her consciousness began to improve gradually, and she became lucid again on the 57th day. After 3 months of rehabilitation, she was discharged from the hospital without any neurologic deficits. On the 366th day after CO exposure, conventional MR imaging showed no abnormality in the WM except mild brain atrophy. Her clinical course, transition of DTI parameters, and MR imaging findings are shown in Fig 1.

Discussion

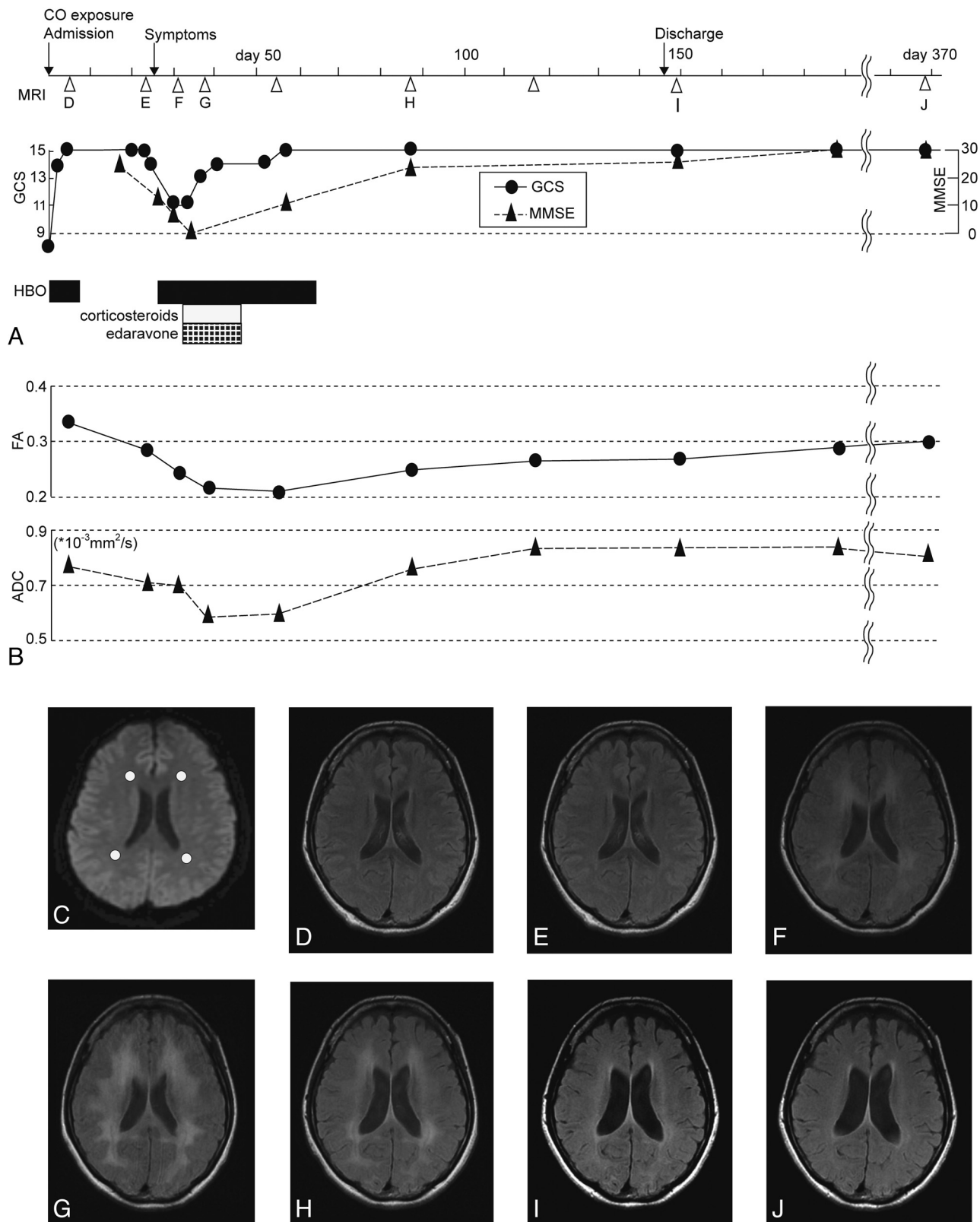
In the present case, FA values began to decline in the lucid interval, before clinical symptoms of DE, and the degree of FA reduction correlated well with neurologic deficits. Meanwhile, ADC values also began to decline in the lucid interval and started to increase before FA, concurrent with consciousness recovery; thereafter, ADC became higher than the initial value. Heretofore, some reports have shown the diagnostic prospectivity of DTI for DE, demonstrating the FA decreasing in correlation with neurologic deficits and increasing gradually after neurologic improvements,^{3,4} though there were no definite patterns of the transition of ADC values. In those studies, DTI was performed after the onset of DE or 1 time only, so the transition of DTI parameters before clinical symptoms was not clarified. The present case confirmed the reports that FA decreases in parallel with neurologic deficits. Additionally, this case indicates that FA values began to decrease earlier than previously thought. Concerning ADC variation, it is possible that ADC values may differ, depending on the period of measurement or the disease severity. We performed DTI relatively early, and ADC values reached their lowest approximately 2 weeks after the onset of DE. Hence, if DTI analysis starts later, ADC reduction will not be detectable. In other pathologic conditions such as traumatic brain injury, ADC reduction is considered to reflect brain damage due to cytotoxic edema.⁵ In a similar manner, ADC reduction in

Received January 17, 2011; accepted January 20.

From the Departments of Neurology (H.K., K.F., Y.I.) and Diagnostic Radiology (S.T.), Tohoku University Graduate School of Medicine, Sendai, Japan, and Tohoku University Hospital Emergency Center (Y.S.), Sendai, Japan.

Please address correspondence to Hiroshi Kuroda, MD, Department of Neurology, Tohoku University Graduate School of Medicine, 1-1 Seiryomachi, Aobaku, Sendai, 980-8574, Japan; e-mail: dakuro@med.tohoku.ac.jp

<http://dx.doi.org/10.3174/ajnr.A2600>



Disclosures: Dr Fujihara serves on scientific advisory boards for Bayer Schering Pharma, Biogen Idec and Merck Serono; has received funding for travel and received speaker honoraria from Bayer Schering Pharma, Biogen Idec, Eisai Inc, Mitsubishi Tanabe Pharma Corporation, Astellas Pharma Inc, Takeda Pharmaceutical Company Limited, and Asahi Kasei Kuraray Medical Co, Ltd; serves on the editorial board of *Clinical and Experimental Neuroimmunology*; receives royalties from the publication of *Clinical Practice Guide of Orthopedic Surgery* (Bunkodo, 2007); and has received research support from Bayer Schering Pharma, Biogen Idec Japan, Asahi Kasei Kuraray Medical Co, The Chemo-Sero-Therapeutic Research Institute, Teva Pharmaceutical K.K., Mitsubishi Tanabe Pharma Corporation, Teijin Pharma, Eisai Inc, Kowa Pharmaceuticals America, Inc, and the Grants-in-Aid for Scientific Research from the Ministry of Education, Science and Technology of Japan. Dr Itoyama has received speaker honoraria from Bayer Schering Pharma and has received research support from Grants-in-Aid for Scientific Research from the Ministry of Education, Science and Technology, and the Ministry of Health, Labor and Welfare of Japan.

References

1. Choi IS. **Delayed neurologic sequelae in carbon monoxide intoxication.** *Arch Neurol* 1983;40:433–35
2. Werring DJ, Clark CA, Barker GJ, et al. **Diffusion tensor imaging of lesions and normal-appearing white matter in multiple sclerosis.** *Neurology* 1999;52:1626–32
3. Terajima K, Igarashi H, Hirose M, et al. **Serial assessments of delayed encephalopathy after carbon monoxide poisoning using magnetic resonance spectroscopy and diffusion tensor imaging on 3.0T system.** *Eur Neurol* 2008;59:55–61. Epub 2007 Oct 4
4. Beppu T, Nishimoto H, Ishigaki D, et al. **Assessment of damage to cerebral white matter fiber in the subacute phase after carbon monoxide poisoning using fractional anisotropy in diffusion tensor imaging.** *Neuroradiology* 2010;52:735–43
5. Chu Z, Wilde EA, Hunter JV, et al. **Voxel-based analysis of diffusion tensor imaging in mild traumatic brain injury in adolescents.** *AJNR Am J Neuroradiol* 2010;31:340–46