



Get Clarity On Generics

Cost-Effective CT & MRI Contrast Agents



FRESENIUS
KABI

WATCH VIDEO

AJNR

Location of the Clot and Outcome of Perfusion Defects in Acute Anterior Circulation Stroke Treated with Intravenous Thrombolysis

N. Sillanpää, J.T. Saarinen, H. Rusanen, I. Elovaara, P. Dastidar and S. Soimakallio

This information is current as of August 20, 2025.

AJNR Am J Neuroradiol 2013, 34 (1) 100-106

doi: <https://doi.org/10.3174/ajnr.A3149>

<http://www.ajnr.org/content/34/1/100>

Location of the Clot and Outcome of Perfusion Defects in Acute Anterior Circulation Stroke Treated with Intravenous Thrombolysis

N. Sillanpää, J.T. Saarinen, H. Rusanen, I. Elovaara, P. Dastidar, and S. Soimakallio



ABSTRACT

BACKGROUND AND PURPOSE: The location of the clot is a major determinant of ischemic stroke outcome. We studied the impact of the location (ICA, proximal M1 segment of the MCA, distal M1 segment, and M2 segment and more distally) of the clot on the CT perfusion parametric maps, the mismatch ratio, the amount of salvaged brain tissue, and the imaging and clinical outcomes in a retrospective acute (<3 hours) stroke cohort treated with intravenous thrombolysis.

MATERIALS AND METHODS: We reviewed 105 patients who underwent admission multimodal CT that revealed an occluded vessel on CTA. CT perfusion was successfully performed in 58 patients (55%). Differences among the parameters in different vessel positions were studied with the ANCOVA by using onset-to-imaging time as a covariate followed by pair-wise testing.

RESULTS: There were no significant differences in potential confounding variables among the groups. A clot proximal to the M2 segment produced a significantly larger defect on the MTT map. A clot in the ICA resulted in a significantly larger CBV lesion compared with the distal M1 segment, the M2 segment, and the M3 segment. In general, a more proximal thrombus created a larger CBV defect. The fraction of penumbra that was salvaged at 24 hours was higher in the more distal vessel positions.

CONCLUSIONS: Admission CBV defects are larger in proximal vessel occlusions. More of the penumbra can be salvaged if the occlusion is located distally. This effect seems to reach a plateau in the distal M1 segment of the MCA.

ABBREVIATIONS: ANCOVA = analysis of covariance; ASPECTS = Alberta Stroke Program Early CT Score; CBS = clot-burden score; ICC = intraclass correlation coefficient; mRS = modified Rankin Scale

The time from the onset of stroke symptoms to possible reperfusion of ischemic brain tissue determines functional outcome because the duration of parenchymal ischemia dictates the progression of irreversible changes and the size of the infarct core.^{1,2} In the absence of sufficient collateral circulation, recanalization is a necessary though not sufficient condition for good imaging and clinical outcome.² The location, volume, and composition of the clot determine the effectiveness of intravenous rtPA in dissolving the occluding thrombus.³⁻¹⁵ The location and

volume of the thrombus provide independent prognostic factors, with proximal high-volume clots predicting poor clinical outcome compared with distal low-volume clots.³⁻¹²

Multimodal CT imaging may improve the prognosis of patients with acute stroke.¹⁶ The heart of the multimodal approach is the perfusion study, which allows detection of the infarct core and the penumbra and the quantification of salvageable brain tissue. This can be accomplished with high accuracy and full anatomic coverage by using perfusion and diffusion-weighted MR imaging. CTP has emerged as an alternative to MR imaging.^{17,18}

We reviewed retrospectively the clinical and imaging data of 105 patients with acute (<3 hours) anterior circulation stroke who underwent multimodal CT assessment that revealed an occluded vessel at CTA and subsequently received intravenous rtPA. Fifty-eight (55%) of these patients were adequately evaluated with CTP. We studied the impact of the location (ICA, proximal M1 segment of the MCA, distal M1 segment, and M2 segment and more distally) of the clot on the CTP parametric maps, the mismatch ratio, the proportion of salvaged brain tissue, the 24-hour imaging outcome, and the 3-month clinical outcome.

Received February 4, 2012; accepted May 16.

From the Medical Imaging Center (N.S., P.D., S.S.), Tampere University Hospital, Tampere, Finland; Department of Neurology (J.T.S., I.E.), School of Medicine, University of Tampere, Tampere, Finland; and Department of Neurology (H.R.), Oulu University Hospital, Oulu, Finland.

This study was supported by the Tampere University Hospital governmental subsidy (EVO) funds for clinical research.

Please address correspondence to Niko Sillanpää, MD, Medical Imaging Center, Tampere University Hospital, PL 2000, 33521, Tampere, Finland; e-mail: niko.sillanpaa@pihlajalinna.fi

<http://dx.doi.org/10.3174/ajnr.A3149>

MATERIALS AND METHODS

Study Population

Our retrospective observational cohort study was approved by Tampere University (Hospital) review board. Altogether 315 patients with anterior or posterior circulation ischemic stroke from January 2004 to December 2007 were treated with thrombolytic therapy and had a 3-month follow-up after the thrombolysis at the department of neurology of the Tampere University (Hospital). CTA had been performed in 285 patients (90%), and CTP, in 245 patients (78%). The thrombolytic therapy protocol used was similar to the American Heart Association guidelines.¹⁹ Inclusion criteria for the study were acute anterior circulation ischemic stroke, vessel occlusion confirmed with CTA, a successfully performed CTP study, treatment with a standard intravenous rtPA administration regimen (Actilyse; Boehringer-Ingelheim, Ingelheim, Germany), and a total dose of 0.9 mg/kg, from which 10% was given as a bolus and the remaining 90%, as a continuous infusion for 1 hour. From 2004 to 2007, intra-arterial interventions were not performed for anterior circulation occlusions at our institution.

Participants and Variables

Baseline characteristics included age, sex, prestroke mRS, times from symptom onset to the imaging and the initiation of intravenous rtPA, and stroke clinical risk factors (hypertension, diabetes, coronary heart disease, atrial fibrillation). These data were collected from the patient records. Clinical evaluation results had been prospectively stored according to a specific protocol. These data contained the NIHSS score at the time of initiation of the rtPA. Information from relatives, occupational therapists, and physiotherapists stored in medical records provided useful information for the assessment of a patient's health before stroke. Follow-up NCCT scans and NIHSS scores were obtained for all patients 24 hours after the administration of the thrombolytic agent. The 3-month mRS was the clinical outcome measure. In the years from 2004 to 2005, this score was prospectively recorded on the basis of a follow-up visit to neurologist and from 2006 to 2007 according to a phone interview by a neurologist. All these prospectively stored clinical data were carefully evaluated for possible errors.

Imaging Parameters

CT scans were obtained by using 2 different multidetector scanners: LightSpeed 16-section (GE Healthcare, Milwaukee, Wisconsin) and Brilliance 64-section (Philips Healthcare, Best, the Netherlands). The imaging procedures and the parameters used are described extensively in our previous study available on-line as an open-access article at the Web site of the publisher.²⁰

Image Analysis

The NCCT examinations were reviewed by using dedicated medical imaging workstations. CTP and CTA images were analyzed, and areas and volumes were measured with Advantage workstation, Version 3.2 (GE Healthcare). MTT and CBV maps were generated with the CT Perfusion 3 software (GE Healthcare). The anterior cerebral artery was used as a source for the arterial input function, and the region of interest for the venous output func-

tion was positioned in the superior sagittal sinus. ASPECTS was assigned for NCCT and CTP maps. The principles of ASPECTS and the evaluation of CTP ASPECTS mismatch have been described in previous studies.^{20,21} ASPECTS was considered not interpretable if either of the 2 reference levels was not covered. MTT maps were used to detect tissue at risk, and CBV maps were used to approximate the infarct core.

In the detection of a perfusion defect, we adopted a semiquantitative approach in which the presence of a defect was determined from color-coded maps visually, by comparing the appearance of the affected location with that of the healthy tissue on the contralateral side. The area of the defect was measured in the ASPECTS levels used in some analyses to increase accuracy and resolution. We required this area to have a mean MTT > 7 seconds (or mean CBV < 2.3 mL/100 g, correspondingly) in accordance with Wintermark et al.²² Further validation was performed by requiring mean relative MTT > 249% for the penumbra and mean relative CBF < 31% and mean relative CBV < 58% for the infarct core compared with the contralateral side.^{23,24}

CTA images were studied by examining the raw data and maximum-intensity-projection images. The location of the clot was recorded on the basis of the most proximal position of the occlusion. The M1 segment of the MCA was divided into 2 parts of equal length: the proximal and the distal half. The principles of the CBS system have been described in recent studies.^{9,10}

The ASPECTSs were assigned, the location of the clot was determined, and the CBS was rated independently by 2 radiologists. In cases in which the findings differed, a consensus was reached. The examinations were reviewed in the order NCCT-CTA-CTP, paralleling that of the clinical workflow. The reviewers were blinded to the clinical data, apart from the side and nature of the acute symptoms. Perfusion defect areas and final infarct volumes were measured by 1 radiologist.

The ICC between a staff radiologist and an experienced neuro-radiologist were calculated for a test sample ($n = 20$): $ICC_{CBS} = 0.87$, $ICC_{NCCT0\text{ hours}} = 0.86$, $ICC_{MTT} = 0.79$, $ICC_{CBV} = 0.73$, and $ICC_{NCCT24\text{ hours}} = 0.93$. Median interobserver agreement indices for areas and volumes were $AREA_{MTT} = 68\%$, $AREA_{CBV} = 90\%$, and $VOLUME_{INFARCT} = 80\%$. Cohen κ for the location of the clot was 0.94.

Statistics

The data were analyzed with the Statistical Package for the Social Sciences, Version 18 (SPSS, Chicago, Illinois). Patients with mRS ≤ 2 at 90 days were considered to have experienced good clinical outcome. The threshold for statistical significance was .05. Group comparisons were performed for baseline variables by using 1-way ANOVA or the Fisher exact test. ANCOVA was used for the imaging parameters with onset-to-imaging time as a covariate. Pair-wise post hoc testing was done by using Šidák correction for multiple comparisons.

RESULTS

Baseline Characteristics

There were 105 (37% of all patients treated with intravenous rtPA during the study period) patients who had anterior circulation clots visible on CTA. Thrombus was not detected in 142 (50%)

Baseline characteristics in different clot locations^a

	ICA (n = 9)	M1P (n = 9)	M1D (n = 11)	M2+M3 (n = 29)	P
Age (yr)	70.2 ± 9.7	68.2 ± 16.2	70.5 ± 15.3	69.4 ± 11.7	.98
Female sex	3 (33)	3 (33)	8 (72)	14 (48)	.24
Admission NIHSS	18.2 ± 3.5	14.0 ± 4.5	12.3 ± 5.4	8.7 ± 5.3	<.001
mRS, prestroke	0.7 ± 0.5	0.7 ± 0.7	0.6 ± 0.7	0.8 ± 0.6	.93
Onset to treatment (min)	138 ± 30	133 ± 43	117 ± 16	133 ± 28	.35
Onset to imaging (min)	99 ± 25	90 ± 31	82 ± 17	100 ± 31	.33
Admission NCCT ASPECTS	8.2 ± 1.7	7.8 ± 2.2	9.5 ± 0.9	9.0 ± 1.8	.12
Hemorrhagic complication	1 (11)	0 (0)	0 (0)	1 (3)	.37

Note:—M1P indicates the proximal M1 segment; M1D, the distal M1 segment; M2+M3, M2 and M3 segments.

^a All values are mean ± SD or number of patients (percentage).

patients, and 38 (13%) patients had a posterior circulation clot. CTP was successfully completed in 58 of the 105 patients (55%) with an anterior circulation clot. These 58 patients constituted the study cohort. Eleven patients were not imaged with CTP; 9 studies were excluded because of poor technical quality; and 27 studies were excluded because either ASPECTS level was not covered, thus not permitting scoring. A perfusion defect was detected in 57 (98%) cases. The median age of the patients was 72 years (interquartile range, 63–81 years; 48% women). The median NIHSS score at admission was 12 (interquartile range, 6–17; 33% had an NIHSS score <8; 36% had an NIHSS score >15), and 24 hours later, the median NIHSS score was 5. The median mRS score was 1 preictally and 2 three months later. At 24 hours, a local hemorrhagic complication (hemorrhagic infarction1, hemorrhagic infarction2, parenchymal hemorrhage1, parenchymal hemorrhage2) was detected in 2 patients (3.4%), and 1 patient (1.7%) had parenchymal hemorrhage distant from the site of the infarct (remote parenchymal hemorrhage1, remote parenchymal hemorrhage2).

Location of the Clot and Outcome of the Perfusion Defect

The differences in age, sex, prestroke mRS scores, and the number of hemorrhagic complications were not statistically significant between the different vessel positions (Table). The admission NIHSS score decreased proportionately in the more distal sites of occlusion. There were no statistically significant differences between the onset-to-treatment times, onset-to-imaging times, or the ASPECTS for NCCT at admission.

Thirty-four patients (59%) experienced favorable 3-month clinical outcomes (mRS ≤2). The difference in good outcome between the 2 most proximal clot locations (ICA and proximal M1 segment) and between the 2 most distal clot locations (distal M1 segment and combined M2 and M3) were not statistically significant, whereas the difference between these 2 groups was highly significant ($P < .001$, Fig 1A). The mid-M1 segment was a determinant for good clinical outcome, with the more distal clot locations predicting good clinical outcome. This is reflected in the imaging outcome. A clot in the ICA or the proximal M1 segment of the MCA resulted in a significantly larger infarct compared with an occluded distal M1 segment or the combined M2 and M3 segment group (Fig 1B, -C).

A thrombus located in the M2 or M3 segments of the MCA produced a significantly smaller perfusion defect compared with all of the 3 more proximal vessel positions, which did not have any




FIG 1. The 3-month clinical outcome and the 24-hour NCCT imaging outcome. Mean values. Error bars indicate 1 SD. The P value for ANCOVA (adjusted for onset-to-imaging time) is given in the lower right-hand corner of each panel. Brackets and P values indicate differences between individual groups. M1P indicates the proximal M1 segment; M1D, the distal M1 segment; M2+M3, M2 and M3 segments.

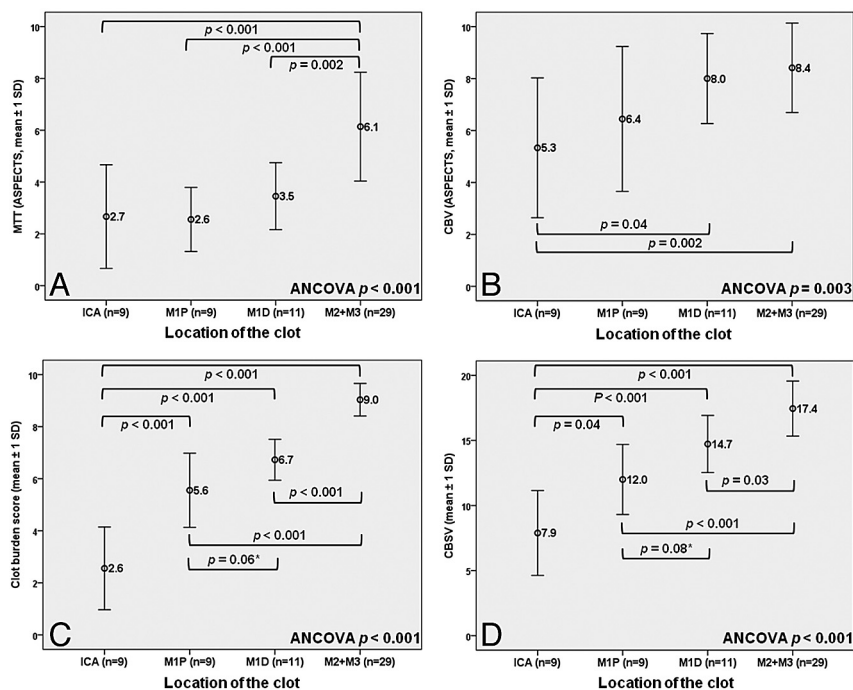


FIG 2. The admission CTP and CTA parameters in different clot locations. Mean values. Error bars indicate 1 SD. The *P* value for ANCOVA (adjusted for onset-to-imaging time) is given in the lower right-hand corner of each panel. Brackets and *P* values indicate differences between individual groups. The asterisk indicates not significant. M1P indicates the proximal M1 segment; M1D, the distal M1 segment; M2 + M3, M2 and M3 segments.

statistically significant differences (Fig 2A). Occlusion of the distal M1 segment resulted in a slightly smaller MTT defect compared with the ICA or the proximal M1 segment, but the difference was not statistically significant. A clot in the ICA caused a significantly larger lesion in the CBV map compared with the distal M1 segment and the combined M2 and M3 segment group (Fig 2B). In general, a more proximal thrombus was associated with a larger CBV defect on the admission CTP. The CBS and the sum of CBS and CBV ASPECTS¹¹ increased almost linearly from proximal-to-distal vessel positions, which is, in part, to be expected because the CBS contains information about the location of the clot (Fig 2C, -D).

A clot in the M2 or M3 segment of the MCA produced a significantly smaller MTT-CBV mismatch (penumbra) and a smaller amount of salvaged brain tissue, which essentially reflects the vascular anatomy (Figs 3A, -B and 4A). However, there was a nonsignificant trend toward a larger proportion of salvageable brain tissue when moving from proximal to distal vessel positions (Fig 3C). In addition, the fraction of penumbra that was salvaged at 24 hours on the basis of the NCCT findings was higher in the more distal vessel positions (Fig 4B, -C). This is probably due to treatment effect, collateral circulation, and higher frequency of spontaneous recanalization, especially in the distal M1 segment (Fig 4A). However, most of the differences between individual vessel positions were not statistically significant.

DISCUSSION

We studied the impact of the location of the clot on the CTP maps, the derived variables describing the penumbra and the salvaged

brain tissue, and the clinical and imaging outcome. There were no statistically significant differences between the various vessel locations in age, onset-to-imaging times, onset-to-treatment times, pre-stroke functional status, or acute ischemic changes on the admission NCCT.

The mid-M1 segment essentially acted as a divider between poor and good clinical outcome. The 24-hour NCCT ASPECTS behaved in a manner consistent with the functional outcome, with clear grouping in the 2 proximal (the ICA and proximal M1 segment) and the 2 distal (the distal M1 segment and the combined M2 and M3 segments) vessel positions. The picture was statistically less clear when the total infarct volume was considered, with only the differences between the ICA and the other vessel positions being statistically significant. However, the difference between the means of the proximal and the distal M1 segment was 2.4-fold. Furthermore, a previous study has suggested that an infarct volume of >70 cm³ leads to poor clinical outcome.¹ This threshold is close to the mean infarct volume in the proximal M1 segment (64.3

cm³). The additional functional and anatomic imaging provided insight into clinical and imaging outcomes.

Occlusion in the 3 most proximal vessel positions produced a significantly larger defect in the MTT map than an M2 or M3 occlusion, which is to be expected from blood vessel and vascular territory anatomy. Correspondingly, the absolute size of the penumbra was significantly smaller in the combined M2 and M3 group. The relative size of the penumbra, compared with the size of the total perfusion defect, was larger in the 3 distal vessel positions, though the difference was not statistically significant, because patients with an occlusion of the ICA had significantly larger lesions in the CBV maps compared with the proximal M1 segment and the combined M2 and M3 group.

In general, there was a significant trend toward larger defects in the CBV map when moving from a distal to a more proximal vessel position. Considering that there were no significant differences in baseline variables, it appears that irreversible ischemic changes develop at a faster pace when the perfusion defect is larger. This can be conceivably attributed to more profound ischemia in the core region of a large perfusion defect. This is consistent with the finding by Gasparotti et al,²⁵ who observed that patients with acute stroke with a carotid T occlusion have larger lesions on the admission CBV maps compared with patients with occlusion of the M1 segment. In a study by Yoo et al,¹ patients with a large lesion in the diffusion-weighted images of admission MR imaging invariably had an acute occlusion of the ICA.

A significantly larger proportion of the penumbra is, on average, saved by the intravenous rtPA or spontaneous recanalization in the more distal vessel positions. This effect seems to reach its

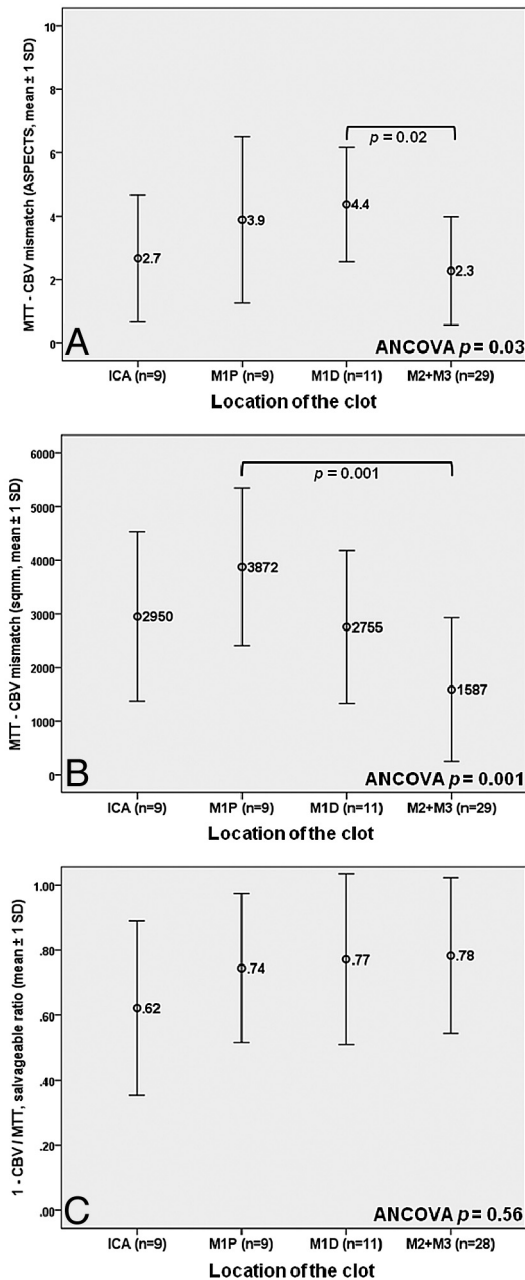


FIG 3. Analysis of the perfusion mismatches. Mean values. Error bars indicate 1 SD. The P value for ANCOVA (adjusted for onset-to-imaging time) is given in the lower right-hand corner of each panel. Brackets and P values indicate differences between individual groups. A, Calculations were made using ASPECTS scores. B and C, Calculations were made by using area measurements in the ASPECTS sections. The asterisk indicates not significant. M1P indicates the proximal M1 segment; M1D, the distal M1 segment; M2+M3, M2 and M3 segments.

maximum in the distal M1 segment. This outcome is probably a result of reperfusion by the emerging collateral circulation and decreased clot burden in the more distal vessel positions as reflected by the significantly smaller clot-burden scores, which potentially increase the rate and the pace of recanalization.

Some studies have addressed the effect of clot location on recanalization and clinical and imaging outcome in the context of intravenous rtPA. None of these studies used CTP. Del Zoppo et al³ used DSA to find that the M2 and M3 segments are more likely

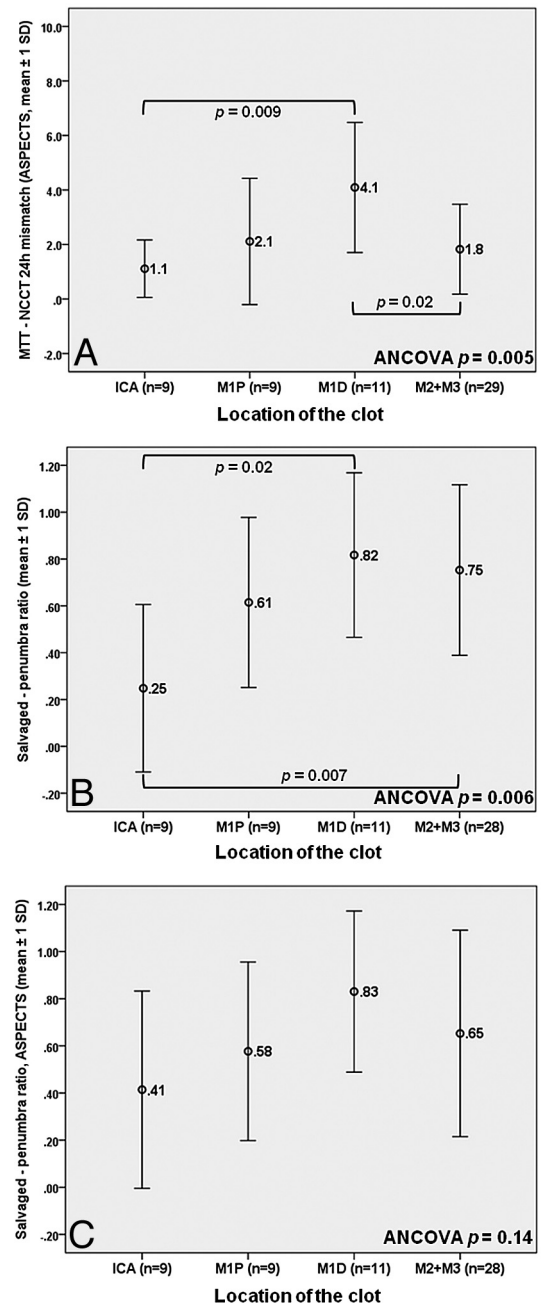


FIG 4. Analysis of the perfusion-NCCT 24-hour mismatches and the fate of the penumbra. Mean values. Error bars indicate 1 SD. The P value for ANCOVA (adjusted for onset-to-imaging time) is given in the lower right-hand corner of each panel. Brackets and P values indicate differences between individual groups. A and C, Calculations were made using ASPECTS scores. B, Calculations were made by using area measurements in the ASPECTS sections. The asterisk indicates not significant. M1P indicates the proximal M1 segment; M1D, the distal M1 segment; M2+M3, M2 and M3 segments.

to undergo recanalization than the M1 segment and the ICA. Saqqur et al⁵ arrived at similar results using repeated transcranial Doppler sonography in studying recanalization and its effect on 3-month clinical outcome. Still other studies with more heterogeneous setups have reported that large-vessel occlusions are less likely to recanalize and predict poor outcome.^{4,7,8} These findings are in congruence with our results.

A prognostic variable that combines the CBV ASPECTS and

the clot-burden scores has been introduced recently.¹¹ A threshold value of 15 in the prediction of good clinical outcome was derived for this variable.¹¹ This result is compatible with our findings of the distal M1 segment having a mean score of 14.7 and the combined M2 and M3 group having a mean score of 17.4, and the 2 more proximal vessel positions having mean scores of 7.9 and 12.0.

Our study is limited by the retrospective design and sample size. The distribution of the patients as to different clot locations was uneven, with half of the patients in the combined M2 and M3 group. However, there were no significant differences in the baseline variables that could be potential confounders between the groups. Because of the study design, direct data on vessel recanalization or reperfusion were not available for most patients. The craniocaudal coverage of the CTP was 20 mm at minimum. Because of this, the size of the perfusion defect was estimated by using ASPECTS and area measurements in the ASPECTS sections. MTT maps potentially overestimate the size of the perfusion defect, while CBV maps may overestimate or underestimate the volume of the irreversibly damaged brain parenchyma, and there is vendor variability in CTP results.²⁶

CONCLUSIONS

The impact that location of the clot has on the findings of CTP examination of the anterior circulation has been seldom directly addressed in previous studies, especially in the context of early intravenous rtPA therapy. A clot proximal to the M2 segment led to a large defect in the admission MTT map with a nonsignificant trend of smaller perfusion defects distally in the 3 more proximal vessel positions. The admission CBV defect was larger in the case of more proximal vessel occlusions, though there were no significant differences in the onset-to-imaging time between the groups. A larger fraction of the penumbra could be salvaged if the occlusion was located more distally. This effect seems to reach a plateau in the distal M1 segment. This is reflected in the clinical outcome with the 2 proximal (the ICA and the proximal M1 segment) clot locations predicting poor outcome, whereas patients with more distal (the distal M1 segment and combined M2 and M3 segments) clots experienced significantly better outcomes.

Disclosures: Harri Rusanen—UNRELATED: Payment for Lectures (including service on Speakers Bureaus): payment for 1 lecture from Beohringer Ingelheim. Irina Elovaara—UNRELATED: Board Membership: Biogen, Merck-Serono, Bayer Schering, Teva, Sanofi Aventis, Consultancy: Merck-Serono, Bayer Schering, Teva, Sanofi Aventis, Grants/Grants Pending: Biogen, Payment for Lectures (including service on Speakers Bureaus): lectures in meetings organized by Biogen, Merck-Serono, Bayer Schering, Teva, Sanofi Aventis, Sanquin.

REFERENCES

1. Yoo AJ, Verduzco LA, Schaefer PW, et al. MRI-based selection for intra-arterial stroke therapy: value of pretreatment diffusion-weighted imaging lesion volume in selecting patients with acute stroke who will benefit from early recanalization. *Stroke* 2009;40:2046–54
2. Soares BP, Tong E, Hom J, et al. Reperfusion is a more accurate predictor of follow-up infarct volume than recanalization: a proof of concept using CT in acute ischemic stroke patients. *Stroke* 2010;41:e34–40
3. del Zoppo GJ, Poeck K, Pessin MS, et al. Recombinant tissue plasminogen activator in acute thrombotic and embolic stroke. *Ann Neurol* 1992;32:78–86
4. Zangerle A, Kiechl S, Spiegel M, et al. Recanalization after thrombolysis in stroke patients: predictors and prognostic implications. *Neurology* 2007;68:39–44
5. Saqqur M, Uchino K, Demchuk AM, et al, for the CLOTBUST Investigators. Site of arterial occlusion identified by transcranial Doppler predicts the response to intravenous thrombolysis for stroke. *Stroke* 2007;38:948–54
6. Gralla J, Burkhardt M, Schroth G, et al. Occlusion length is a crucial determinant of efficiency and complication rate in thrombectomy for acute ischemic stroke. *AJNR Am J Neuroradiol* 2008;29:247–52
7. Linfante I, Llinas RH, Selim M, et al. Clinical and vascular outcome in internal carotid artery versus middle cerebral artery occlusions after intravenous tissue plasminogen activator. *Stroke* 2002;33:2066–71
8. Smith WS, Tsao JW, Billings ME, et al. Prognostic significance of angiographically confirmed large vessel intracranial occlusion in patients presenting with acute brain ischemia. *Neurocrit Care* 2006;4:14–17
9. Puetz V, Dzialowski I, Hill MD, et al. Calgary CTA Study Group: Intracranial thrombus extent predicts clinical outcome, final infarct size and hemorrhagic transformation in ischemic stroke: the clot burden score. *Int J Stroke* 2008;3:230–36
10. Puetz V, Dzialowski I, Hill MD, et al. Malignant profile detected by CT angiographic information predicts poor prognosis despite thrombolysis within three hours from symptom onset. *Cerebrovasc Dis* 2010;29:584–91
11. Sillanpaa N, Saarinen JT, Rusanen H, et al. The clot burden score, the Boston Acute Stroke Imaging Scale, the cerebral blood volume ASPECTS and two novel imaging parameters in the prediction of clinical outcome of ischemic stroke patients receiving intravenous thrombolytic therapy. *Neuroradiology* 2011 Sep 9. [Epub ahead of print]
12. Kim YS, Garami Z, Mikulik R, et al, for the CLOTBUST Collaborators. Early recanalization rates and clinical outcomes in patients with tandem internal carotid artery/middle cerebral artery occlusion and isolated middle cerebral artery occlusion. *Stroke* 2005;36:869–71
13. Schellinger PD, Chalela JA, Kang DW, et al. Diagnostic and prognostic value of early MR imaging vessel signs in hyperacute stroke patients imaged <3 hours and treated with recombinant tissue plasminogen activator. *AJNR Am J Neuroradiol* 2005;26:618–24
14. Liebeskind DS, Sanossian N, Yong WH, et al. CT and MRI early vessel signs reflect clot composition in acute stroke. *Stroke* 2011;42:1237–43
15. Kim EY, Heo JH, Lee SK, et al. Prediction of thrombolytic efficacy in acute ischemic stroke using thin-section noncontrast CT. *Neurology* 2006;67:1846–48
16. Obach V, Oleaga L, Urrea X, et al. Multimodal CT-assisted thrombolysis in patients with acute stroke: a cohort study. *Stroke* 2011;42:1129–31
17. Rai AT, Carpenter JS, Peykanu JA, et al. The role of CT perfusion imaging in acute stroke diagnosis: a large single-center experience. *J Emerg Med* 2008;35:287–92
18. Wintermark M, Meuli R, Browaeys P, et al. Comparison of CT perfusion and angiography and MRI in selecting stroke patients for acute treatment. *Neurology* 2007;68:694–97
19. Adams HP Jr, Brodt TG, Furlan AJ, et al. Guidelines for thrombolytic therapy for acute stroke: a supplement to the guidelines for the management of patients with acute ischemic stroke—a statement for healthcare professionals from a Special Writing Group of the Stroke Council, American Heart Association. *Circulation* 1996;94:1167–74
20. Sillanpaa N, Saarinen JT, Rusanen H, et al. CT perfusion ASPECTS in

the evaluation of acute ischemic stroke: thrombolytic therapy perspective. *Cerebrovasc Dis Extra* 2011;1:6–16

21. Lin K, Rapalino O, Law M, et al. Accuracy of the Alberta Stroke Program Early CT Score during the first 3 hours of middle cerebral artery stroke: comparison of noncontrast CT, CT angiography source images, and CT perfusion *AJNR Am J Neuroradiol* 2008;29:931–36
22. Wintermark M, Flanders AE, Velthuis B, et al. Perfusion-CT assessment of infarct core and penumbra: receiver operating characteristic curve analysis in 130 patients suspected of acute hemispheric stroke. *Stroke* 2006;37:979–85
23. Kamalian S, Kamalian S, Konstas AA, et al. CT perfusion mean transit time maps optimally distinguish benign oligemia from true “at-risk” ischemic penumbra, but thresholds vary by postprocessing technique. *AJNR Am J Neuroradiol* 2012;33:545–49
24. Campbell BC, Christensen S, Levi CR, et al. Cerebral blood flow is the optimal CT perfusion parameter for assessing infarct core. *Stroke* 2011;42:3435–40
25. Gasparotti R, Grassi M, Mardighian D, et al. Perfusion CT in patients with acute ischemic stroke treated with intra-arterial thrombolysis: predictive value of infarct core size on clinical outcome. *AJNR Am J Neuroradiol* 2009;30:722–27
26. Konstas AA, Lev MH. CT perfusion imaging of acute stroke: the need for arrival time, delay insensitive, and standardized postprocessing algorithms? *Radiology* 2010;254:22–25