



Get Clarity On Generics

Cost-Effective CT & MRI Contrast Agents



FRESENIUS
KABI

WATCH VIDEO

AJNR

This information is current as
of August 25, 2025.

Validity of Intervertebral Bone Cement Infusion for Painful Vertebral Compression Fractures Based on the Presence of Vertebral Mobility

K. Yokoyama, M. Kawanishi, M. Yamada, H. Tanaka, Y.
Ito, M. Hirano and T. Kuroiwa

AJNR Am J Neuroradiol 2013, 34 (1) 228-232

doi: <https://doi.org/10.3174/ajnr.A3160>

<http://www.ajnr.org/content/34/1/228>

Validity of Intervertebral Bone Cement Infusion for Painful Vertebral Compression Fractures Based on the Presence of Vertebral Mobility

K. Yokoyama, M. Kawanishi, M. Yamada, H. Tanaka, Y. Ito, M. Hirano, and T. Kuroiwa

EBM
2

ABSTRACT

BACKGROUND AND PURPOSE: It is uncertain whether analgesic effects of vertebroplasty in patients with painful VCF are actually attributable to intervertebral cement infusion. This study aims to assess the validity of cement infusion performed for pain relief based on the presence or absence of pseudoarthrosis.

MATERIALS AND METHODS: We compared therapeutic effects between PVP and vertebral perforation without bone cement infusion in patients with painful VCF. The subjects were 64 patients undergoing PVP (PVP group) and 67 undergoing vertebral perforation (perforation group). In all patients, preoperative dynamic radiography was performed to assess the presence of vertebral mobility. Patients were classified into 2 groups, those with and those without vertebral mobility, and changes in VAS and ADL scores before and after surgery were compared between the PVP and perforation groups.

RESULTS: Regarding patients with vertebral mobility, VAS improved during the 3 months immediately after surgery in the PVP group compared with the perforation group ($P < .05$). Although no significant difference in postoperative ADL scores was observed between the 2 treatment groups, the scores 3 months after surgery were better in the PVP group than in the perforation group. Meanwhile, in the subgroup of patients without vertebral mobility, both treatments produced marked pain relief, but the difference was not significant ($P > .05$). Moreover, there was no difference in ADL scores between the 2 treatment groups.

CONCLUSIONS: Intervertebral cement infusion exerts analgesic effects in patients with VCF with pseudoarthrosis. However, in those without vertebral mobility, the analgesic effects of vertebroplasty are the same regardless of bone cement infusion.

ABBREVIATIONS: ADL= activities of daily living; PVP= percutaneous vertebroplasty; STIR = short τ inversion recovery; VAS= visual analogue scale; VCF= vertebral compression fractures

Vertebroplasty using bone cement is well known to provide marked relief of prolonged pain from VCF and to improve ADL for patients.^{1,2} However, at present, a major placebo component to the analgesic effects exerted by vertebroplasty cannot be ruled out.^{3,4} There are many reports of randomized studies comparing conservative therapies and revealing the usefulness of vertebroplasty.^{1,2} Because the natural course of VCF remarkably impacts therapeutic effects, a simple comparison with patients receiving conservative therapy is insufficient to demonstrate

whether intervertebral bone cement infusion actually contributes to pain relief. Kallmes et al⁵ and Buchbinder et al⁶ compared therapeutic effects between vertebroplasty and a sham subcutaneous puncture as a control procedure to demonstrate the efficacy of bone cement infusion, but efficacy could not be confirmed. However, the presence or absence of pseudoarthrosis was not considered in these studies. Vertebroplasty for VCF was originally a procedure expected to exert analgesic effects via injection of bone cement into vertebral bodies destabilized by pseudoarthrosis.^{7,8} In patients without pseudoarthrosis, no theoretic evidence exists for performing this procedure. We assessed the validity of intervertebral bone cement infusion for treating painful VCF based on the presence or absence of pseudoarthrosis. In patients with and without vertebral mobility before surgery, considered separately, the therapeutic effects of vertebroplasty were compared with those of the vertebral perforation procedure in which vertebral bodies were not injected with bone cement but rather were only perforated.

Received February 29, 2012; accepted after revision March 18.

From the Department of Neurosurgery (K.Y., M.K., M.Y., H.T., Y.I., M.H.), Takeda General Hospital, Fushimi, Kyoto; and Departments of Neurosurgery and Surgical Pathology (T.K.), Osaka Medical College, Takatsuki, Osaka, Japan.

Please address correspondence to Kunio Yokoyama, Department of Neurosurgery, Takeda General Hospital, 28-21, Ishidamoriminami-machi, Fushimi, Kyoto City, Kyoto 601-1495, Japan; e-mail: neu100@poh.osaka-med.ac.jp

EBM
2 Evidence-Based Medicine Level 2.

<http://dx.doi.org/10.3174/ajnr.A3160>

MATERIALS AND METHODS

Subjects

Four hundred and thirteen patients (610 treated vertebral bodies) with osteoporotic VCF visited our institution between January 2003 and April 2011. In all cases, despite long-term conservative therapy at local hospitals, pain had shown no alleviation and all underwent surgery at our institution. Patients with 2 or more treated vertebral bodies or a history of treatment were excluded. This study thus involved 131 consecutive patients (131 vertebral bodies) who underwent surgery between January 2006 and April 2011. In the first half of the study period, from January 2006 to August 2009, PVP was performed in 64 patients (PVP group). In the second half of the study period, from September 2009 to April 2011, percutaneous vertebral perforation, in which vertebral bodies were not injected with bone cement but rather were only perforated, was performed in 67 patients (perforation group). We excluded those who insisted on bone cement infusion and did not undergo vertebral perforation. In all patients, simple dynamic lumbar radiography, lumbar CT, and lumbar MR imaging were performed before surgery to assess the presence or absence of vertebral mobility. We sufficiently explained treatment procedures and enrollment in this study to the patients and obtained their informed consent.

Inclusion and Exclusion Criteria

The inclusion criteria were 1) VCF with 0%–90% loss of vertebral body height on x-ray of the spine; 2) severe back pain related to a single VCF refractory to analgesic medication for at least 2 weeks; 3) pain with a VAS score of 5 or higher interfering with ADL, tapping pain at the spinal process of the fractured vertebral body; and 4) the high signal intensity on STIR imaging and low signal intensity on T1WI in the affected vertebral body.

The exclusion criteria were 1) uncorrected coagulopathy, 2) local or systemic infection, 3) secondary osteoporosis, 4) inability to give informed consent, 5) impaired cardiopulmonary function, 6) dementia, 7) painless VCF, 8) spinal metastatic cancer, and 9) neurologic symptoms.

Surgical Procedures

Percutaneous Vertebral Body Perforation (Perforation Group). We previously reported the surgical procedure of percutaneous vertebral body perforation.⁹ All patients were operated on by 1 of the authors (M.K.), who previously performed 610 vertebroplasties. Surgery was performed with the patient in the prone position under local anesthesia. Under C-arm guidance, 13-ga biopsy needles were inserted via bilateral transpedicular routes into the anterior third of the vertebral body. Blood or effusion in the vertebral body was aspirated. Next, contrast medium was injected through the bilateral needles, and the position of the tip of each needle, its communication with the vertebral vein, and the efflux pattern of the contrast medium were then checked. Finally, irrigation with 50 mL of saline was performed via each needle. Surgery was completed by withdrawing both needles.

Percutaneous Vertebroplasty (PVP Group). All patients were operated on by 1 of the authors (M.K.). Surgery was performed with

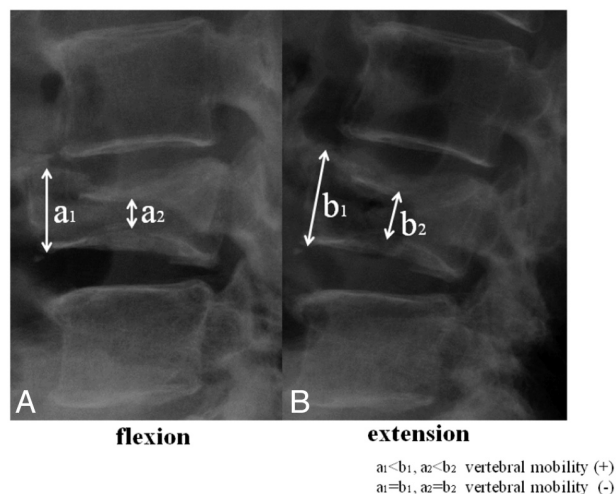


FIG 1. Characteristic preoperative lateral radiographs of patient with VCF with pseudoarthrosis (A, flexion; B, extension). The collapsed L4 vertebral body shows dynamic mobility. Vertebral body height increased with extension stress.

Table 1: Baseline characteristics of patients treated for VCF

	PVP Group (n = 67)	Perforation Group (n = 64)	P Value
Mean age (years)	77.1 ± 7.2	76.7 ± 7.6	.38
Male:Female	12:55	11:53	.99
Mean interval (days)	159.6 ± 250	125.1 ± 204	.74
Treated level (T1–L2)	52 (77.7%)	49 (76.6%)	.89
Preop VAS	7.2 ± 1.6	7.5 ± 1.7	.83
Preop mobility of fracture	23 (34.3%)	32 (50%)	.08

Note:—Preop indicates preoperative.

the patient in the prone position under local anesthesia. Under C-arm guidance, a 13-ga biopsy needle was inserted via a unilateral transpedicular route into the anterior third of the vertebral body. Contrast medium was injected through the needle, and the position of the tip of the needle and the efflux pattern of the contrast medium were then checked. A polymethylmethacrylate mixture was injected into the vertebral body. Surgery was completed by withdrawing the needle. During cement injection, fluoroscopic monitoring with a C-arm unit was used in both planes.

Outcome Evaluation

Pain was evaluated before and at 2 days (next day), 1 week, and 3 months after surgery using a VAS on a numeric rating system (10 = maximum pain to 0 = no pain). ADL were evaluated before the surgery, 2 days (next day) after surgery, and 3 months after surgery using the following 5-point scale: grade 0 = complete independence; grade 1 = light assistance and being able to walk with a stick; grade 2 = moderate assistance and needing a wheelchair for locomotion; grade 3 = major assistance and mostly staying in bed; and grade 4 = a bed-ridden state and needing total assistance. First, we compared postoperative changes in VAS and ADL scores between patients with and without vertebral mobility in each treatment group, respectively. Next, we compared scores between the PVP and perforation groups based on the presence of vertebral mobility. The presence or absence of mobility of the affected vertebral bodies before surgery was assessed with dy-

Table 2: Comparison of VAS between vertebral mobility and nonvertebral mobility

	PVP			Perforation		
	Vertebral Mobility +	Vertebral Mobility -	P Value	Vertebral Mobility +	Vertebral Mobility -	P Value
Preop	7.17 ± 1.75	7.21 ± 1.58	.835	6.78 ± 1.83	7.42 ± 1.43	.237
Day 2	1.39 ± 1.67	1.65 ± 1.95	.818	3.28 ± 2.67	2.37 ± 2.38	.193
Day 7	1.45 ± 1.79	1.22 ± 1.64	.619	3.54 ± 2.70	2.00 ± 2.36	.025
Day 90	1.50 ± 1.60	1.46 ± 3.02	.658	3.21 ± 2.83	1.65 ± 2.06	.037

Note:—Preop indicates preoperative.

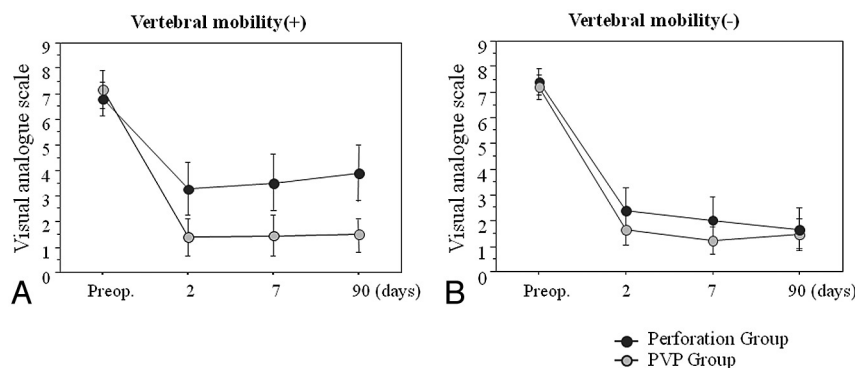


FIG 2. Relationships between reduction in postoperative VAS and presence of vertebral mobility. We compared pain relief between the perforation and PVP groups. A, Patients with vertebral mobility; (B) patients without vertebral mobility.

dynamic radiography. Conventional lateral, lateral flexion, and extension stress radiography were performed. Vertebral body height was measured to assess vertebral mobility. If there was even a little difference in vertebral body height between lateral flexion and extension, as shown in the Fig 1 images, vertebral mobility was judged to be present. Then, the frequency of new fractures 12 months after surgery was compared between the 2 treatment groups. The presence or absence of new fractures was determined by the appearance of high signal intensity on STIR imaging and low intensity on T1WI in other vertebral bodies.

Statistical Analysis

Statistical analyses were performed using Stat View 5.0 software (SAS Institute, Cary, North Carolina). For comparison of demographic characteristics, VAS scores on follow-up, and complications between the 2 groups, we applied the Mann-Whitney *U* test or the Fisher exact test. All data are presented as mean ± standard deviation, and differences were considered statistically significant at a *P* value <.05.

RESULTS

The demographic data of the PVP and perforation groups are presented in Table 1. There were no significant differences in age, sex ratio, localization of treated vertebral bodies, preoperative VAS scores, or symptom duration (*P* > .05). Preoperative dynamic radiography revealed mobility of vertebral bodies in 23 PVP group (34.3%) and 32 perforation group (50%) patients.

In the PVP group, VAS scores were markedly decreased immediately after surgery in both groups of patients (those with and those without vertebral mobility), and no significant difference was observed for 3 months (*P* > .05, Table 2). On the other hand, in the perforation group, postoperative improvement of VAS scores was poorer in patients with, than in those without, verte-

bral mobility, and a significant difference was observed from postoperative day 7 and onward (day 7 to day 90, *P* < .05, Table 2).

In patients with preoperative vertebral mobility, VAS scores were significantly improved immediately after surgery—and this was sustained for 3 months—in the PVP group compared with the perforation group (*P* < .05; Fig 2, Table 3). However, in patients without vertebral mobility, no significant difference was observed in postoperative improvement of VAS scores between the PVP and perforation groups (*P* > .05; Fig 2, Table 3).

Concerning changes in ADL scores, there was no statistically significant difference between the 2 treatment groups for the first 3 months after surgery, regardless of the presence or absence of vertebral mobility. However, in patients with vertebral mobility, ADL scores were better in the PVP than in the perforation group.

During the 12-month postoperative follow-up period, new fractures occurred in 28.4% of patients in the PVP group. This frequency was significantly higher than the 9.8% in the perforation group (*P* < .01). In cases with vertebral mobility especially, though a new fracture occurred in 1 of 32 (3.1%) perforation group patients, new fractures occurred in 9 of 23 (39.1%) PVP group patients (Table 4).

DISCUSSION

We performed vertebral perforation, in which vertebral bodies were not injected with bone cement but were only perforated, as the control procedure against vertebroplasty for painful VCF. The former procedure is a modification of bone marrow decompression performed for painful fractures. Bone marrow decompression was previously performed for pain due to long bone fractures and so on, based on the theory that the onset of fracture pain is closely associated with bone marrow edema.¹⁰⁻¹⁸ Past reports suggest that bone marrow decompression may reduce intramedullary pressure in vertebral bodies and cause changes in blood circulation.¹⁰⁻¹⁸ Some clinicians regard these procedures as treatment. In fact, anticipating analgesic effects, we have also performed these procedures for patients with painful VCF. However, because vertebral bodies are also perforated before bone cement infusion, even in vertebroplasty, the difference between vertebroplasty and vertebral perforation is based on whether or not bone cement was infused. Thus, we speculated that the significance of intervertebral bone cement infusion

Table 3: Comparison of VAS and ADL scores between PVP and perforation groups based on the presence of vertebral mobility

	Vertebral Mobility +			Vertebral Mobility -		
	PVP	Perforation	P Value	PVP	Perforation	P Value
VAS						
Preop	7.17 ± 1.75	6.78 ± 1.83	.63	7.21 ± 1.58	7.42 ± 1.43	.622
Day 2	1.39 ± 1.67	3.28 ± 2.67	.014	1.65 ± 1.95	2.37 ± 2.38	.217
Day 7	1.45 ± 1.79	3.54 ± 2.70	.004	1.22 ± 1.64	2.00 ± 2.36	.243
Day 90	1.50 ± 1.60	3.21 ± 2.83	.029	1.46 ± 3.02	1.65 ± 2.06	.701
ADL Score						
Preop	1.65 ± 0.88	1.62 ± 0.74	.823	1.86 ± 0.85	1.96 ± 0.71	.623
Day 2	1.22 ± 0.90	1.74 ± 0.81	.109	1.44 ± 0.75	0.95 ± 0.72	.151
Day 90	1.04 ± 0.88	1.35 ± 0.81	.197	1.07 ± 1.07	0.82 ± 0.66	.615

Note:—Preop indicates preoperative. ADL were evaluated using the following 5-point scale outlined in the text.

Table 4: Incidence of new vertebral compression fracture after surgery

	PVP Group	Perforation Group	P Value
Vertebral mobility +	9/23 (39.1%), adjacent fx (6/9)	1/32 (3.1%), adjacent fx (1/1)	<.01
Vertebral mobility -	10/44 (22.7%), adjacent fx (7/10)	4/19 (21.1%), adjacent fx (3/4)	.44
Total	19/67 (28.4%)	5/51 (9.8%)	<.01

Note:—Statistical analysis was performed with Fisher exact test. fx indicates fracture.

could be demonstrated by comparing analgesic effects between these treatment procedures.

According to the results of this study, analgesic effects were significantly higher in patients with vertebral mobility in the PVP group than in those in the perforation group, and postoperative improvement of ADL scores was observed in the former group. It has been noted that stabilization of destabilized vertebral bodies is necessary for pain relief in patients with pseudoarthrosis.^{7,8} Our results confirmed that bone cement infusion truly plays an important role in analgesic effects on fractured vertebral bodies with vertebral mobility. Meanwhile, marked analgesic effects were also observed in patients without vertebral mobility in the PVP group. Because the pain mechanism has not been elucidated in patients with VCF without vertebral mobility, the mechanism by which bone cement infusion exerts analgesic effects remains unknown. More importantly, the analgesic effects obtained in the patients with VCF without vertebral mobility in the perforation group without bone cement infusion were approximately the same as the effects obtained in the PVP group. Because pain may be spontaneously relieved in patients without vertebral mobility, it also cannot be ruled out that the analgesic effects observed in both treatment groups might have been a placebo. This result does not affirm that bone cement infusion is necessary for patients with fractures without vertebral mobility. This is also reflected by the fact that no difference was observed in changes in ADL scores between the 2 treatment groups. Because pathologic conditions and pain mechanisms differ between VCF with and without vertebral mobility,¹⁹ treatment procedures need to be selected according to pathologic conditions. Many past randomized studies involved patients with bone marrow edema detected by preoperative MR imaging, and both pathologic conditions are included.^{1,5,6} Thus, if only patients with pseudoarthrosis had been included in the assessment, we consider the difference in therapeutic effects to possibly have been more apparent between the

vertebroplasty and control groups. We previously reported on the analgesic effects of vertebral perforation on painful VCF.⁹ In this study, the results of multivariate analysis revealed that the analgesic effects were low in patients with severe collapse of vertebral bodies before surgery. As a possible explanation for this, we noted that VCF patients with severe collapse had a longer time since onset and higher frequency of vertebral mobility than those with mild collapse. However, the presence or absence of vertebral mobility was not assessed.⁹

We demonstrated that intervertebral bone cement infusion apparently contributes to pain relief in patients with painful VCF with vertebral mobility. However, the incidence of new fractures after surgery is extremely high. This should be adequately understood by patients before surgery. On the other hand, it is not certain whether intervertebral bone cement infusion per se contributes to pain relief in patients with fractures lacking vertebral mobility. Given the risk of complications associated with bone cement infusion, we advocate caution in the application of vertebroplasty.

Limitations

In the present study, we used vertebral perforation as a control procedure against PVP to assess the validity of bone cement infusion. As noted above, there is no conclusive evidence that treatment with only puncture of vertebral bodies per se has no analgesic effect on compression fracture. Thus, it is not certain whether this treatment is appropriate as a control procedure. However, if a difference in therapeutic effects is observed between the 2 treatment groups, we consider this to demonstrate the therapeutic significance of intervertebral bone cement infusion.

Second, the patients were not randomized, and vertebral perforation was not performed under blinded conditions because those undergoing the procedure were preoperatively informed that bone cement would not be injected. However, the patients enrolled in this study were assigned to treatment procedures according to study period. PVP was performed in those enrolled during the first half of the study period and vertebral perforation in those enrolled during the second half. Thus, at least the treatment selection was not biased. Moreover, because all patients in this study underwent surgery with an expectation of analgesic effects from it, we consider a large difference in placebo effects between the treatment groups to be unlikely.

REFERENCES

1. Klazen CA, Lohle PN, de Vries J, et al. **Vertebroplasty versus conservative treatment in acute osteoporotic vertebral compression fractures (VERTOS II): an open-label randomised trial.** *Lancet* 2010;25:1085–92
2. Rousing R, Hansen KL, Andersen MO, et al. **Twelve-months follow-up in forty-nine patients with acute/semiacute osteoporotic vertebral fractures treated conservatively or with percutaneous vertebroplasty: a clinical randomized study.** *Spine* 2010;35:478–82
3. Miller FG, Kallmes DF, Buchbinder R. **Vertebroplasty and the placebo response.** *Radiology* 2011;259:621–25
4. Luetmer MT, Kallmes DF. **Have referral patterns for vertebroplasty changed since publication of the placebo-controlled trials?** *AJNR Am J Neuroradiol* 2011;32:647–48
5. Kallmes DF, Comstock BA, Heagerty PJ, et al. **A randomized trial of vertebroplasty for osteoporotic spinal fractures.** *N Engl J Med* 2009;361:569–79
6. Buchbinder R, Osborne RH, Ebeling PR, et al. **A randomized trial of vertebroplasty for painful osteoporotic vertebral fractures.** *N Engl J Med* 2009;361:557–68
7. Jang JS, Kim DY, Lee SH. **Efficacy of percutaneous vertebroplasty in the treatment of intravertebral pseudarthrosis associated with noninfected avascular necrosis of the vertebral body.** *Spine* 2003;28:1588–92
8. Kim DY, Lee SH, Jang JS. **Intravertebral vacuum phenomenon in osteoporotic compression fracture: report of 67 cases with quantitative evaluation of intravertebral instability.** *J Neurosurg* 2004;100:24–31
9. Yokoyama K, Kawanishi M, Yamada M, et al. **Comparative study of percutaneous vertebral body perforation and vertebroplasty for the treatment of painful vertebral compression fractures.** *AJNR Am J Neuroradiol* 2011;33:685–89
10. Arnoldi CC. **Intravertebral pressures in patients with lumbar pain.** *Acta Orthop Scand* 1972;43:109–17
11. Arnoldi CC. **Intraosseous hypertension a possible cause of low back pain.** *Clin Orthop* 1976;115:30–34
12. Spencer DL, Ray RD, Spigos DG, et al. **Intraosseous pressure in the lumbar spine.** *Spine* 1981;6:159–61
13. Ochia RS, Ching RP. **Internal pressure measurements during burst fracture formation in human lumbar vertebrae.** *Spine* 2002;27:1160–67
14. Arnoldi CC, Linderholm H, Müssbichler H. **Venous engorgement and intraosseous hypertension in osteoarthritis of the hip.** *J Bone Joint Surg* 1972;54: 409–21
15. Arnoldi CC, Lemperg K, Linderholm H. **Intraosseous hypertension and pain in the knee.** *J Bone Joint Surg* 1975;57:360–63
16. Lemperg RK. **The significance of intraosseous pressure in normal and disease states with special reference to the intraosseous pain engorgement syndrome.** *Clin Orthop* 1978;136:143–56
17. Azuma H. **Intraosseous pressure as a measure of hemodynamic changes in bone marrow.** *Angiology* 1964;15:396–406
18. Esses SI, Moro JK. **Intraosseous vertebral pressures.** *Spine* 1992;17: S155–59
19. Kawaguchi S, Horigome K, Yajima H, et al. **Symptomatic relevance of intravertebral cleft in patients with osteoporotic vertebral fracture.** *J Neurosurg Spine* 2010;13:267–75