



Get Clarity On Generics

Cost-Effective CT & MRI Contrast Agents



FRESENIUS
KABI

WATCH VIDEO

AJNR

Hyperintense Vessels on T2-PROPELLER-FLAIR in Patients with Acute MCA Stroke: Prediction of Arterial Stenosis and Perfusion Abnormality

S.J. Ahn, S.H. Suh, K.-Y. Lee, J.H. Kim, K.-D. Seo and S. Lee

This information is current as
of August 13, 2025.

AJNR Am J Neuroradiol 2015, 36 (11) 2042-2047

doi: <https://doi.org/10.3174/ajnr.A4423>

<http://www.ajnr.org/content/36/11/2042>

Hyperintense Vessels on T2-PROPELLER-FLAIR in Patients with Acute MCA Stroke: Prediction of Arterial Stenosis and Perfusion Abnormality

S.J. Ahn,  S.H. Suh, K.-Y. Lee, J.H. Kim, K.-D. Seo, and S. Lee

ABSTRACT

BACKGROUND AND PURPOSE: Fluid-attenuated inversion recovery hyperintense vessels in stroke represent leptomeningeal collateral flow. We presumed that FLAIR hyperintense vessels would be more closely associated with arterial stenosis and perfusion abnormality in ischemic stroke on T2-PROPELLER-FLAIR than on T2-FLAIR.

MATERIALS AND METHODS: We retrospectively reviewed 35 patients with middle cerebral territorial infarction who underwent MR imaging. FLAIR hyperintense vessel scores were graded according to the number of segments with FLAIR hyperintense vessels in the MCA ASPECTS areas. We compared the predictability of FLAIR hyperintense vessels between T2-PROPELLER-FLAIR and T2-FLAIR for large-artery stenosis. The interagreement between perfusion abnormality and FLAIR hyperintense vessels was assessed. In subgroup analysis (9 patients with MCA horizontal segment occlusion), the association of FLAIR hyperintense vessels with ischemic lesion volume and perfusion abnormality volume was evaluated.

RESULTS: FLAIR hyperintense vessel scores were significantly higher on T2-PROPELLER-FLAIR than on T2-FLAIR (3.50 ± 2.79 versus 1.21 ± 1.47 , $P < .01$), and the sensitivity for large-artery stenosis was significantly improved on T2-PROPELLER-FLAIR (93% versus 68%, $P = .03$). FLAIR hyperintense vessels on T2-PROPELLER-FLAIR were more closely associated with perfusion abnormalities than they were on T2-FLAIR ($\kappa = 0.64$ and $\kappa = 0.27$, respectively). In subgroup analysis, FLAIR hyperintense vessels were positively correlated with ischemic lesion volume on T2-FLAIR, while the mismatch of FLAIR hyperintense vessels between the 2 sequences was negatively correlated with ischemic lesion volume ($P = .01$).

CONCLUSIONS: In MCA stroke, FLAIR hyperintense vessels were more prominent on T2-PROPELLER-FLAIR compared with T2-FLAIR. In addition, FLAIR hyperintense vessels on T2-PROPELLER-FLAIR have a significantly higher sensitivity for predicting large-artery stenosis than they do on T2-FLAIR. Moreover, the areas showing FLAIR hyperintense vessels on T2-PROPELLER-FLAIR were more closely associated with perfusion abnormality than those on T2-FLAIR.

ABBREVIATIONS: FHV = FLAIR hyperintense vessel; GRE = gradient-echo; T_{max} = time-to-maximum

FLAIR hyperintense vessels (FHVs) are frequently encountered in acute ischemic stroke. Two types of FHVs, proximal and distal, have different clinical implications.¹ Proximal FHVs, which are frequently observed proximal to or within the Sylvian fissure, can be used as a marker for arterial occlusion and are presumably the result of the thrombus or slow collateral flow.²⁻⁴

Distal FHVs, which are present distal to the Sylvian fissure, may indicate collateral flow and salvageable brain parenchyma in acute stroke; angiography reveals that they are more related to retrograde collateral flow from arteries unaffected by occlusion.^{1,5} Recently, distal FHVs have been studied more due to their clinical importance.^{6,7}


Technically, in the setting of normal hemodynamics, the blood vessels show dark signal intensity on spin-echo sequences such as FLAIR because of the dephasing effect from mixed spin-echoes and stimulated echoes, as well as the disrupted spin-echo mechanism due to through-plane blood motion. The retrograde slow flow results in the loss of this flow void phenomenon, and vessels appear hyperintense against the dark CSF background.⁸⁻¹⁰

The PROPELLER technique has been implemented with conventional MR images to reduce motion-induced artifacts and increase

Received January 23, 2015; accepted after revision April 19.

From the Departments of Radiology (S.J.A., S.H.S.) and Neurology (K.-Y.L., J.H.K., K.-D.S.), Yonsei University College of Medicine, Seoul, Korea; Severance Institute for Vascular and Metabolic Research (S.H.S., K.-Y.L.), Yonsei University, Seoul, Korea; and Global Applications and Workflow (S.L.), GE Healthcare, Seoul, Korea.

Please address correspondence to Kyung-Yul Lee, MD, PhD, Department of Neurology, Gangnam Severance Hospital, Yonsei University, College of Medicine, 211 Eonju-ro, Gangnam-gu, Seoul 135-720, Korea; e-mail: kylee@yuhs.ac

 Indicates article with supplemental on-line photo.

<http://dx.doi.org/10.3174/ajnr.A4423>

image quality.^{11–13} The PROPELLER technique may affect hyperintense vessels on T2-FLAIR.

We hypothesized that FHV's are assessed better on T2-PROPELLER-FLAIR than on T2-FLAIR and that FHV's are more closely associated with arterial stenosis and perfusion abnormality in ischemic stroke on T2-PROPELLER-FLAIR than on T2-FLAIR.

MATERIALS AND METHODS

Patients

We retrospectively screened consecutive patients who presented to our tertiary referral medical center. We included patients with acute middle cerebral artery territory ischemic stroke within 1 week of symptom onset. They underwent advanced MR imaging. All of the patients included in the study showed restricted diffusion in the MCA territory on diffusion-weighted imaging. We excluded patients with transient ischemic attack, multiple infarctions other than in MCA territories, or lacunar infarction. Our institutional review board approved this retrospective study.

MR Imaging Protocols

Patients were imaged with a 3T MR imaging unit (Discovery MR750; GE Healthcare, Milwaukee, Wisconsin). Our advanced MR imaging protocol for acute stroke included DWI, T2-FLAIR, T2-PROPELLER-FLAIR, gradient-echo (GRE), bolus-tracking perfusion-weighted imaging, intracranial and extracranial con-

trast-enhanced MR angiography, and intracranial time-of-flight MRA. FLAIR images were acquired with following parameters: TR/TE = 12,000/140 ms; TI = 2500 ms; flip angle = 110°; section thickness = 4 mm; gap = 1 mm; FOV = 210 × 210 mm; matrix = 352 × 353; and 30 contiguous sections for a total acquisition of 3 minutes 20 seconds. PROPELLER-T2-FLAIR images were also acquired with commercially available 2D sequences: TR/TE = 8800/120 ms; TI = 2200 ms; flip angle = 142°; and they matched resolution with T2-FLAIR. Total acquisition time for T2-PROPELLER-FLAIR was 3 minutes 30 seconds.

Image Analysis

Two readers independently assessed either T2-FLAIR or T2-PROPELLER-FLAIR. The first review of images was randomly selected by the study coordinator; the remainder of the sequences were reviewed 1 week later. The reviewers were blinded to clinical history and imaging sequences and assessed FHV's and parenchymal ischemic lesions on both sequences.

To compare FHV's on both sequences, we used FHV scores, modifying a previous method.⁶ In brief, images were scored from zero to 7 points by counting the number of MCA-Alberta Stroke Program Early CT Score territories in which FHV's were present.¹⁴ FHV's were counted when they appeared as linear or serpentine hyperintensities corresponding to a typical arterial course on at least 2 consecutive axial sections. The MCA ASPECTS territories are composed of 7 territories: I and M1–M3 at the level of the basal ganglia and M4–M6 at the level of the ventricles immediately above the basal ganglia. I represents the insular ribbon. M1 represents the anterior MCA cortex corresponding to the frontal operculum, M2 represents the MCA cortex lateral to the insular ribbon corresponding to the anterior temporal lobe, and M3 represents the posterior MCA cortex corresponding to the posterior temporal lobe. M4, M5, and M6 represent the anterior, lateral, and posterior MCA territories immediately superior to M1, M2, and M3, respectively.

To compare the parenchymal ischemic lesions on both sequences, we calculated the contrast-to-noise ratio between the parenchymal ischemic lesion and adjacent white matter. The contrast-to-noise ratio was defined as $(SI_{\text{lesion}} - SI_{\text{WM}})/SD_n$, where SD_n is the SD of background noise. Signal intensities (SI s) of the lesion and WM were assessed by circular ROI measurements (area = 20 mm²), which were placed identically on both sequences. For qualitative assessment, 2 readers recorded parenchymal ischemic lesions while evaluating FHV's. The diagnostic sensitivity for parenchymal ischemic lesions of both sequences was calculated. The standard reference was DWI.

A third experienced reader gauged the time-to-maximum (T_{max}) map of PWI with the same scoring system. A T_{max} map was generated by using perfusion-processing software (FuncTool; GE Healthcare). The number of MCA-ASPECTS territories with delayed perfusion was counted instead of the FHV's. The ischemic lesion volume and perfusion abnormality

Table 1: Characteristics and MRA findings of study patients^a

Features	
No. of patients	35
Age (yr) (mean)	65.1
Female sex	12/35 (34)
Hypertension	15/35 (42)
Diabetes mellitus	11/35 (31)
Median time interval from symptom onset to MRI (hr) (IQR)	23.4 (9.62–57.5)
MRA findings	
Large-artery stenosis or occlusion ^b	28/35 (80)
MCA horizontal segment	12 (34)
MCA insular segment	5 (15)
MCA cortical segment	1 (3)
Distal ICA	3 (8)
Proximal ICA	7 (20)
Negative	7 (20)

Note:—IQR indicates interquartile range.

^a Unless otherwise specified, data are the number of patients, with percentages in parentheses.

^b Represents ≥50% stenosis or occlusion of the large artery.

Table 2: Comparison of FHV's and parenchymal ischemic lesions between T2-FLAIR and T2-PROPELLER-FLAIR^a

	T2-FLAIR	T2-PROPELLER-FLAIR	P Value
FHV's			
FHV score	1.21 ± 1.47	3.50 ± 2.79	<.01
Parenchymal ischemic lesions			
CNR	20.93 ± 8.61	8.43 ± 3.51	<.01
Sensitivity ^b	148/153 (96.7)	149/153 (97.4)	1.00

Note:—CNR indicates contrast-to-noise ratio: $(SI_{\text{lesion}} - SI_{\text{WM}})/SD_n$.

^a FHV scores were defined by counting the number of MCA-ASPECTS territories in which FHV's were present.

^b Sensitivity for the detection of acute and old ischemic lesions. Data are the number of ischemic lesions and percentages.

volume were also measured by using DWI and the T_{\max} map, respectively, with the reader blinded to the FHV scores. DICOM formats of DWI and the T_{\max} map were imported into ImageJ software (National Institutes of Health, Bethesda, Maryland) by using a measurement stack plug-in to calculate volumes. ROIs were drawn along the borders of the high-signal area on DWI and the delayed perfusion area on the T_{\max} map, compared with the contralateral area of each section. The arterial stenotic lesion was determined by MRA in conjunction with DWI, T_{\max} , T2-FLAIR, and T2-PROPELLER-FLAIR.

Statistical Analysis

FHV scores and contrast-to-noise ratios for ischemic lesions between T2-FLAIR and T2-PROPELLER-FLAIR were compared by using a paired Student *t* test. The diagnostic sensitivities for parenchymal ischemic lesions were compared using the McNemar test. The interobserver agreement between the 2 readers was evaluated with κ statistics.

The sensitivity and specificity of T2-FLAIR and T2-PROPELLER-FLAIR for predicting large-artery stenosis ($\geq 50\%$) and occlusion were also compared by using the McNemar test. The interagreement between both sequences and perfusion abnormality was assessed by κ statistics.

For the correlation with ischemic lesion volume and perfusion abnormality volume, subgroup analysis was performed. Due to the homogeneity of the occlusion site and the degree of stenosis, only 9 patients with horizontal segment occlusion were included. Spearman correlation analysis was used to explore the relationship among the FHV score on T2-FLAIR, FHV score on T2-PROPELLER-FLAIR, FHV mismatch, initial ischemic lesion volume, and initial perfusion abnormality volume. FHV mismatch was calculated by (FHV scores on T2-PROPELLER-FLAIR – FHV scores on T2-FLAIR) / FHV scores on T2-PROPELLER-FLAIR. Statistical analysis was performed by using commercial software (MedCalc, Version 10.1.2.0; MedCalc Software, Mariakerke, Belgium). A *P* value $< .05$ was statistically significant.

RESULTS

Thirty-five patients fulfilled the inclusion criteria (Table 1). The mean age was 65.1 years, and 34% of patients were women. The median time from symptom onset to MR imaging was 23.4 hours (interquartile range, 9.62–57.5 hours). Large-artery stenosis ($\geq 50\%$) or occlusion was seen in 28/35 patients (80%) in the following areas: the MCA horizontal segment (12/35, 34%), the MCA insular segment (5/35, 15%), the MCA cortical segment (1/35, 3%), the distal internal carotid artery (3/35, 8%), and the proximal ICA (7/35, 20%). Mild stenosis or negative findings were observed in 7/35 patients (20%).

The FHV score of T2-PROPELLER-FLAIR was significantly higher than that of T2-FLAIR in patients with acute MCA territory infarction (3.50 ± 2.79 versus 1.21 ± 1.47 , $P < .01$, Table 2). The contrast-to-noise ratio between parenchymal ischemic lesions and adjacent WM on T2-PROPELLER-FLAIR was significantly lower than that on T2-FLAIR (8.43 ± 3.51 versus 20.93 ± 8.61 , $P < .01$). However, the diagnostic sensitivity for parenchymal ischemic lesions on both sequences was not significantly different ($P = 1.00$). Of 153 ischemic lesions, 148 ischemic lesions

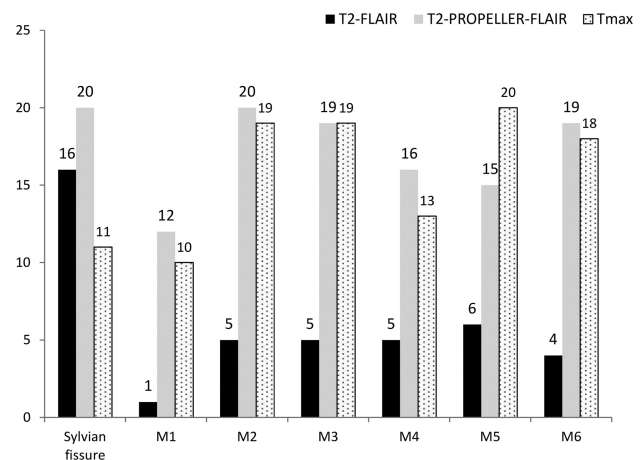


FIG 1. The distribution of FHV and perfusion abnormality in each MCA-ASPECTS territory. The black, gray, and dotted bars represent the frequency of FHV and perfusion abnormality for T2-FLAIR, T2-PROPELLER-FLAIR, and T_{\max} , respectively.

Table 3: The predictability of FHV for large-artery stenosis on T2-FLAIR and T2-PROPELLER-FLAIR^a

	T2-FLAIR	T2-PROPELLER-FLAIR	P Value
Arterial stenosis or occlusion on MRA	28/35 (80%)		
Incidence of FHV	19/35 (54%)	26/35 (74%)	.06
Predictability ^b			
True-positive	19	26	
True-negative	7	7	
False-positive	0	0	
False-negative	9	2	
Sensitivity	68%	93%	.03
Specificity	100%	100%	

^a Data are the number of patients and percentages.

^b Represents the diagnostic value for the prediction of large-artery stenosis or occlusion.

(96.7%) were detected on T2-FLAIR. Meanwhile, of 153 ischemic lesions, 149 (97.4%) were detected on T2-PROPELLER-FLAIR. The interobserver agreement between the 2 readers assessing FHV and parenchymal lesions for T2-FLAIR and T2-PROPELLER-FLAIR was excellent ($\kappa = 0.83$ and 0.87 for the FHV score, $\kappa = 0.98$ and 0.98 for parenchymal ischemic lesions).

The FHV were most frequently present in the Sylvian fissure on T2-FLAIR (16/35, 45%, Fig 1). FHV were also seen in M5 (6/35, 17%), M2, M3, M4 (5/35, 14% for each), M6 (4/35, 11%), and M1 (1/35, 3%). The FHV were most frequently present in the Sylvian fissure and M2 on the T2-PROPELLER-FLAIR (20/35, 57% for each); FHV were seen less frequently in M3 and M6 (19/35, 54% for each), M4 (16/35, 46%), M5 (15/35, 43%), and M1 (12/35, 34%). Perfusion abnormalities were observed in M5 (20/35, 57%), M2 (19/35, 54%), M3 (19/35, 54%), M6 (18/35, 51%), M4 (13/35, 37%), the Sylvian fissure (11/35, 31%), and M1 (10/35, 28%).

FHV were depicted in 19/35 patients (54%) on T2-FLAIR and in 26/35 patients (74%) on T2-PROPELLER-FLAIR. The sensitivity of T2-PROPELLER-FLAIR for predicting large-artery stenosis or occlusion was 93%, which is significantly higher than that of T2-FLAIR, 68% ($P = .03$). However, the specificities of both sequences were 100% (Table 3).

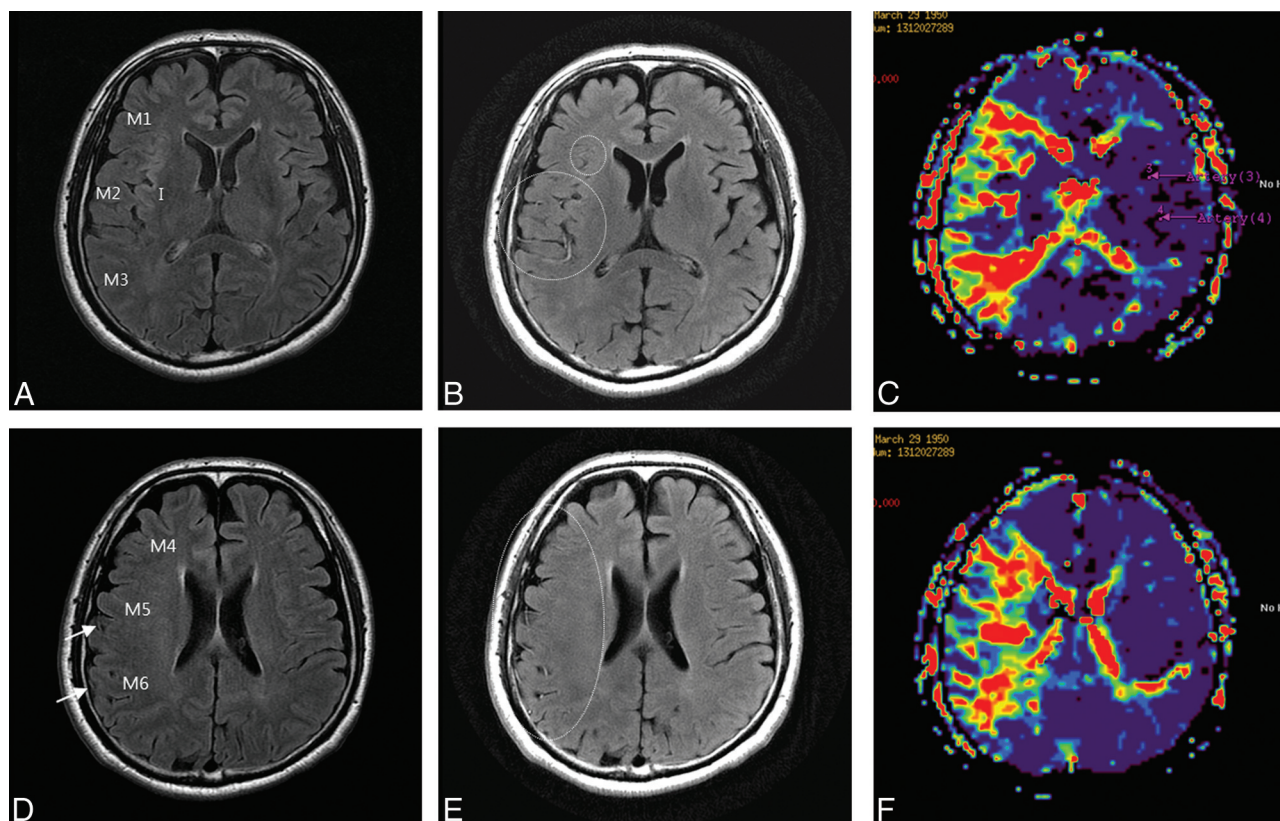


FIG 2. A 63-year-old man with right MCA territory infarction. FHVs on T2-FLAIR at the level of the basal ganglia (A) were not seen, whereas FHVs on T2-PROPELLER-FLAIR (B) were seen in the Sylvian fissure, M1, M2, and M3 (dotted circle). On the T_{\max} map (C), FHVs were well-matched with perfusion abnormality. FHVs on T2-FLAIR at the level of the ventricle above the basal ganglia (D) were seen in the M5 and M6 territory (arrow), whereas FHVs on T2-PROPELLER-FLAIR (E) were seen in all territories (dotted circle). On T_{\max} (F), FHVs on T2-PROPELLER-FLAIR were well-matched with perfusion abnormality.

Table 4: Associations among FHV scores, ischemic lesion volume, and perfusion abnormality volume in 9 patients with MCA horizontal segment occlusion

	Ischemic DWI Lesion Volume (r) ^a	Perfusion Abnormality Volume (r) ^a
Median (IQR) (mL)	4.74 (1.76–11.57)	64.91 (60.33–70.31)
FHV scores on T2-FLAIR	0.86, 0.01	0.28, 0.43
FHV scores on T2-PROPELLER-FLAIR	0.38, 0.34	0.79, 0.02
FHV mismatch ^b	−0.79, 0.01	0.33, 0.42

^a r closer to 1 represents a positive correlation. r closer to −1 represents a negative correlation.

^b Calculated by (FHV scores on T2-PROPELLER-FLAIR − FHV scores on T2-FLAIR) / FHV scores on T2-PROPELLER-FLAIR.

Territories in which FHVs were present on T2-PROPELLER-FLAIR were more closely associated with perfusion abnormality than on T2-FLAIR ($\kappa = 0.64$ and 0.27 , respectively; Fig 2, On-line Fig 1).

In 9 patients with stroke with total occlusion of the MCA horizontal segment, FHV scores on T2-FLAIR showed a significant positive correlation with ischemic DWI lesion volume ($r = 0.86$, $P = .01$), while FHV scores on T2-FLAIR showed no significant relationship with perfusion abnormality volume ($r = 0.28$, $P = .43$). FHV scores on T2-PROPELLER-FLAIR did not show a significant relationship with ischemic lesion volume ($r = 0.38$, $P = .34$), whereas FHV scores on T2-PROPELLER-FLAIR showed a significant positive correlation with perfusion abnormality volume ($r = 0.79$, $P = .02$). FHV mismatch was significantly negatively correlated with ischemic DWI lesion volume ($r = -0.79$, $P = .01$). FHV mismatch did not show a signifi-

cant relationship with perfusion abnormality volume ($r = 0.33$, $P = .42$, Table 4).

DISCUSSION

This study found that in patients with MCA stroke, FHVs were more prominent and observed in a wider territory on T2-PROPELLER-FLAIR than on T2-FLAIR. FHVs on T2-PROPELLER-FLAIR had significantly higher sensitivity for predict-

ing large-artery stenosis or occlusion than on T2-FLAIR. The areas showing FHVs on T2-PROPELLER-FLAIR were associated with perfusion abnormality. Moreover, increased FHV mismatch between T2-FLAIR and T2-PROPELLER-FLAIR was associated with decreased infarct volume in patients with MCA horizontal segment occlusion.

These results have clinical impact. FHVs on T2-PROPELLER-FLAIR may be used as a second-look sequence in conjunction with MRA for detecting arterial stenosis in patients with MCA stroke. FHVs on T2-FLAIR and T2-PROPELLER-FLAIR may have the potential for use in evaluating collateral status and predicting prognosis in patients with MCA stroke.

FHVs on T2-PROPELLER-FLAIR were seen in a wider territory than those on T2-FLAIR. Previous studies reported that FHVs are prominent within the Sylvian fissure.^{6–15} This might be because the larger arteries have a slower flow speed than the smaller distal arteries

under the same perfusion pressure. Hohenhaus et al⁶ reported that FHV were predominantly located in the distal central surface area (M2 and M5 region and the Sylvian fissure). However, we found fewer FHV in the distal central surface areas (M2 and M5 regions) and other distal cortical regions (M1, M3, M4, and M6) on T2-FLAIR. On the other hand, FHV were prominent even in distal cortical regions on T2-PROPELLER-FLAIR.

The prominence of FHV on T2-PROPELLER-FLAIR could be explained by the following: Cerebral arteries exhibit pulsatile and anatomic positional changes.¹⁶ This motion can lead to image blurring or signal loss and could affect the small-caliber distal cerebral artery in particular due to small voxel size.¹⁷ PROPELLER corrects the motion of objects by repetitive sampling in the central *k*-space.¹⁸ Thus, we speculate that PROPELLER could overcome the blurring or signal loss induced by cerebral artery motion.

Many institutions use limited, short MR imaging protocols that require <20 minutes of imaging. Because the optimal stroke protocol may include only 1 sequence, either conventional T2-FLAIR or T2-PROPELLER-FLAIR, the contrast-to-noise ratio between parenchymal ischemic lesions and adjacent WM is reduced on T2-PROPELLER-FLAIR images compared with T2-FLAIR. T2-FLAIR can estimate the onset time in patients with acute ischemic stroke and may be helpful in assessing wake-up strokes.¹⁹ Although qualitative analysis showed that there was no significant difference between the 2 sequences for the detection of acute ischemic lesions, the contrast-to-noise ratio for parenchymal lesions on T2-PROPELLER-FLAIR could affect the estimation of onset time, resulting in a different treatment plan (On-line Fig 2).

Cosnard et al²⁰ reported that FHV correspond to MRA evidence of stenosis or occlusion. The sensitivity and specificity were 65% and 85%, respectively. Kamran et al¹⁵ reported that all 30 of their patients with FHV had large-vessel occlusion or severe stenosis ($\geq 90\%$), implying that the specificity of FHV was 100%. Iancu-Gontard et al²¹ reported that the concordance between FHV and stenosis on angiography was significantly higher for the MCA territory compared with the anterior cerebral artery territory. Schellinger et al² compared the vessel signs among CT, FLAIR, and GRE for the prediction of vessel status and found that FHV were more sensitive than the other modalities (sensitivity for FLAIR, 65.9%; CT, 40%; GRE, 34.1%). The specificity of FHV was 75%. On the basis of previous studies, FHV on T2-FLAIR have high specificity but relatively low sensitivity for the prediction of large-artery stenosis; this finding is consistent with our results, which show a sensitivity of 68% and a specificity of 100%. However, we found that the sensitivity of FHV is significantly increased (93%) when combined with the PROPELLER technique. T2-PROPELLER-FLAIR exhibited 2 false-negative cases in which collateral flows were too fast to show arterial hyperintensities. In one of the true-positive cases, arterial stenosis in the MCA cortical segment was difficult to detect, depending only on MRA. Nevertheless, occlusion of the distal arteries was detected in conjunction with FHV on T2-PROPELLER-FLAIR (On-line Fig 3). Thus, FHV on T2-PROPELLER-FLAIR may be used as a second-look sequence for the detection of arterial stenosis in patients with stroke. Moreover, the application of T2-

PROPELLER-FLAIR might be extended to cohorts with brain tumor or neurodegenerative diseases in which MRA is not routinely performed.

Toyoda et al²² reported that in 35 of 40 patients with acute ischemic stroke, areas of intra-arterial signal distribution were equal to the regions of abnormal perfusion. However, their detailed method for analysis was not explained. Gawlitza et al²³ reported that there was significant correlation between the degree of the FHV sign and PWI lesion volume, but they did not compare FHV signs with PWI territory by territory. Kwag et al²⁴ recently reported that MR imaging with a radial *k*-space filling (BLADE; Siemens, Erlangen, Germany), which is a similar technique provided by other MR imaging manufacturers, also improved hyperintense vessels on T2-FLAIR. They proposed that this technique may be helpful for detecting penumbra if it is used right after DWI. However, they did not compare FHV with perfusion abnormalities. We analyzed the relationship between FHV signs and perfusion abnormalities territory by territory. Our results indicated that territories in which FHV were present on T2-PROPELLER-FLAIR matched perfusion abnormalities better than those of T2-FLAIR. Perfusion abnormalities included the infarct core, penumbra, and benign oligemia. Currently, there is no threshold for differentiating the spectrum of perfusion abnormalities. Because FHV exhibited a wider territory on T2-PROPELLER-FLAIR than on T2-FLAIR and a stronger association with perfusion abnormality, we presume that FHV are closer to wide benign oligemia territory on T2-PROPELLER-FLAIR than they are on T2-FLAIR. Further studies are needed for validation of this assumption.

In our subgroup analysis, higher FHV scores on T2-FLAIR were related to larger ischemic DWI lesion volumes. The higher the FHV mismatch was between the 2 sequences, the smaller the ischemic DWI lesion volume was. This phenomenon might be explained by the following: FHV on both sequences lie within the spectrum of poor and good collaterals. Because FHV on T2-FLAIR reflect relatively slow collateral flows, they may represent “poor” collaterals,^{25,26} while FHV on T2-PROPELLER-FLAIR reflect relatively fast and slow collaterals, implying a mixture of “poor” and “good” collaterals. Thus, the mismatch in FHV scores between the 2 sequences may represent the “good” collaterals. However, our results should be cautiously interpreted. Previously, Lee et al¹ demonstrated the existence of FHV on T2-FLAIR with smaller ischemic lesion volume, which was interpreted as “good” collaterals compared with the absence of FHV. Therefore, it is difficult to simply define FHV on T2-FLAIR as “poor” collaterals. In addition, as mentioned above, T2-PROPELLER-FLAIR may miss extremely fast and good collaterals, which can result in false-negative arterial stenosis results. Future studies with a larger and homogeneous population of patients with stroke are needed to investigate this issue. Moreover, considering that FHV are free from the technical difficulties of PWI, such as arterial input function measurement and complicated deconvolution methods,²⁷ FHV may be of value in ongoing research on leptomeningeal collateralization in stroke.

There were some limitations in this study. First, the number of cases was small and might not be sufficient to determine the exact diagnostic value for T2-PROPELLER-FLAIR. However, the diag-

nostic value of T2-FLAIR was consistent with that in previous studies and was thus presumed to be credible. Second, our cohort was heterogeneous, with patients representing both the acute and subacute stages of MCA stroke. The median time from onset to imaging was 23 hours, beyond the time window for IV or intra-arterial therapy. Thus, our results should be carefully applied in clinical practice. However, our results may serve as a cornerstone for future studies with a larger and more homogeneous population to validate and extend these results.

CONCLUSIONS

Our study showed that in patients with MCA stroke, FHV were more prominent and observed across a wider territory on T2-PROPELLER-FLAIR than on T2-FLAIR. In addition, FHV on T2-PROPELLER-FLAIR have a significantly higher sensitivity for predicting large-artery stenosis or occlusion than on T2-FLAIR. Moreover, the areas showing FHV on T2-PROPELLER-FLAIR were more closely associated with perfusion abnormality than those on T2-FLAIR, reflecting leptomeningeal collateral circulation.

Disclosures: Sangwoo Lee—UNRELATED: Employment: GE Healthcare.

REFERENCES

- Lee KY, Latour LL, Luby M, et al. Distal hyperintense vessels on FLAIR: an MRI marker for collateral circulation in acute stroke? *Neurology* 2009;72:1134-39 CrossRef Medline
- Schellinger PD, Chalela JA, Kang DW, et al. Diagnostic and prognostic value of early MR imaging vessel signs in hyperacute stroke patients imaged <3 hours and treated with recombinant tissue plasminogen activator. *AJNR Am J Neuroradiol* 2005;26:618-24 Medline
- Assouline E, Benziane K, Reizine D, et al. Intra-arterial thrombus visualized on T2* gradient echo imaging in acute ischemic stroke. *Cerebrovasc Dis* 2005;20:6-11 CrossRef Medline
- Lee JY, Lee KY, Suh SH. Different meaning of vessel signs in acute cerebral infarction. *Neurology* 2010;75:668 CrossRef Medline
- Sanossian N, Saver JL, Alger JR, et al. Angiography reveals that fluid-attenuated inversion recovery vascular hyperintensities are due to slow flow, not thrombus. *AJNR Am J Neuroradiol* 2009;30:564-68 CrossRef Medline
- Hohenhaus M, Schmidt WU, Brunecker P, et al. FLAIR vascular hyperintensities in acute ICA and MCA infarction: a marker for mismatch and stroke severity? *Cerebrovasc Dis* 2012;34:63-69 CrossRef Medline
- Haussen DC, Koch S, Saraf-Lavi E, et al. FLAIR distal hyperintense vessels as a marker of perfusion-diffusion mismatch in acute stroke. *J Neuroimaging* 2013;23:397-400 CrossRef Medline
- Tsushima Y, Endo K. Significance of hyperintense vessels on FLAIR MRI in acute stroke. *Neurology* 2001;56:1248-49 CrossRef Medline
- Storey P, Atanasova IP, Lim RP, et al. Tailoring the flow sensitivity of fast spin-echo sequences for noncontrast peripheral MR angiography. *Magn Reson Med* 2010;64:1098-108 CrossRef Medline
- Park J, Kim EY. Contrast-enhanced, three-dimensional, whole-brain, black-blood imaging: application to small brain metastases. *Magn Reson Med* 2010;63:553-61 CrossRef Medline
- Chen X, Xian J, Wang X, et al. Role of periodically rotated overlapping parallel lines with enhanced reconstruction diffusion-weighted imaging in correcting distortion and evaluating head and neck masses using 3 T MRI. *Clin Radiol* 2014;69:403-09 CrossRef Medline
- Fries P, Runge VM, Kirchin MA, et al. Diffusion-weighted imaging in patients with acute brain ischemia at 3 T: current possibilities and future perspectives comparing conventional echoplanar diffusion-weighted imaging and fast spin echo diffusion-weighted imaging sequences using BLADE (PROPELLER). *Invest Radiol* 2009;44:351-59 CrossRef Medline
- Forbes KP, Pipe JG, Karis JP, et al. Improved image quality and detection of acute cerebral infarction with PROPELLER diffusion-weighted MR imaging. *Radiology* 2002;225:551-55 CrossRef Medline
- Pexman JH, Barber PA, Hill MD, et al. Use of the Alberta Stroke Program Early CT Score (ASPECTS) for assessing CT scans in patients with acute stroke. *AJNR Am J Neuroradiol* 2001;22:1534-42 Medline
- Kamran S, Bates V, Bakshi R, et al. Significance of hyperintense vessels on FLAIR MRI in acute stroke. *Neurology* 2000;55:265-69 CrossRef Medline
- Umeda Y, Ishida F, Hamada K, et al. Novel dynamic four-dimensional CT angiography revealing 2-type motions of cerebral arteries. *Stroke* 2011;42:815-18 CrossRef Medline
- Gumus K, Keating B, Poser BA, et al. Prevention of motion-induced signal loss in diffusion-weighted echo-planar imaging by dynamic restoration of gradient moments. *Magn Reson Med* 2014;71:2006-13 CrossRef Medline
- Pipe JG. Motion correction with PROPELLER MRI: application to head motion and free-breathing cardiac imaging. *Magn Reson Med* 1999;42:963-69 CrossRef Medline
- Aoki J, Kimura K, Iguchi Y, et al. FLAIR can estimate the onset time in acute ischemic stroke patients. *J Neurol Sci* 2010;293:39-44 CrossRef Medline
- Cosnard G, Duprez T, Grandin C, et al. Fast FLAIR sequence for detecting major vascular abnormalities during the hyperacute phase of stroke: a comparison with MR angiography. *Neuroradiology* 1999;41:342-46 CrossRef Medline
- Iancu-Gontard D, Oppenheim C, Touze E, et al. Evaluation of hyperintense vessels on FLAIR MRI for the diagnosis of multiple intracerebral arterial stenoses. *Stroke* 2003;34:1886-91 CrossRef Medline
- Toyoda K, Ida M, Fukuda K. Fluid-attenuated inversion recovery intraarterial signal: an early sign of hyperacute cerebral ischemia. *AJNR Am J Neuroradiol* 2001;22:1021-29 Medline
- Gawlitza M, Gragert J, Quäsching U, et al. FLAIR-hyperintense vessel sign, diffusion-perfusion mismatch and infarct growth in acute ischemic stroke without vascular recanalisation therapy. *J Neuroradiol* 2014;41:227-33 CrossRef Medline
- Kwag E, Lim SM, Park JE, et al. Arterial hyperintensity on BLADE fluid-attenuated inversion recovery images (FLAIR) in hyperacute territorial infarction: comparison with conventional FLAIR. *Eur Radiol* 2014;24:2045-51 CrossRef Medline
- Ebinger M, Kufner A, Galinovic I, et al. Fluid-attenuated inversion recovery images and stroke outcome after thrombolysis. *Stroke* 2012;43:539-42 CrossRef Medline
- Giot M, Gauvrit JY, Cordonnier C, et al. Prognostic value of hyperintense vessel signals on fluid-attenuated inversion recovery sequences in acute cerebral ischemia. *Eur Neurol* 2007;57:75-79 CrossRef Medline
- Latchaw RE, Yonas H, Hunter GJ, et al. Guidelines and recommendations for perfusion imaging in cerebral ischemia: a scientific statement for healthcare professionals by the writing group on perfusion imaging, from the Council on Cardiovascular Radiology of the American Heart Association. *Stroke* 2003;34:1084-104 CrossRef Medline