



Discover Generics

Cost-Effective CT & MRI Contrast Agents



WATCH VIDEO

AJNR

Embryologic Anatomic Variations: Challenges in Intra-Arterial Chemotherapy for Intraocular Retinoblastoma

C. Paruthi, V. Gupta and N. Khandelwal

AJNR Am J Neuroradiol 2016, 37 (11) E71-E72

doi: <https://doi.org/10.3174/ajnr.A4905>

<http://www.ajnr.org/content/37/11/E71>

This information is current as
of June 3, 2025.

Embryologic Anatomic Variations: Challenges in Intra-Arterial Chemotherapy for Intraocular Retinoblastoma

We read the article on intraocular chemotherapy for retinoblastoma by Bertelli et al,¹ e-published in February 2016, with considerable interest. It gives excellent insight into the adaptable approaches of the procedure described. The authors have mainly described 3 patterns of drug delivery in their patients: a fixed pattern through the ophthalmic artery, a fixed pattern through branches of the external carotid artery (ECA), and a variable pattern via either of these. They have also mentioned the “Japanese technique.”² The authors have also highlighted difficulties in direct ophthalmic artery catheterization due to its acute takeoff from the internal carotid artery, where primary shaping of the catheter can be attempted. In cases in which the choroid blush via the ophthalmic artery was not seen, catheterization of the ECA branches was also performed.

In our experience, sometimes even shaping the microcatheter does not allow ophthalmic artery catheterization. In such cases, if a choroid blush is seen only via the ophthalmic artery and not through the middle meningeal artery, the Japanese technique might be helpful. However, sometimes even this may be challenging due to presence of embryologic vascular variations. The case in point was an 11-month-old female child with grade D retinoblastoma in the left eye, refractory to systemic chemotherapy. A left internal carotid artery angiogram revealed a type 1 persistent trigeminal artery (PTA) arising from the vertical portion of the cavernous segment, with an approximate 4-mm caliber (Fig 1A). The left ophthalmic artery had an acute angled takeoff from the ICA (Fig 1A), and attempts to cannulate it with straight and angled microcatheters were unsuccessful. Tumor blush and choroid blush were, however, seen only via the ophthalmic artery on the left ICA injection. Left ECA and selective left middle meningeal artery runs did not show any choroid blush or reformation of the ophthalmic artery. Therefore, a 4 × 7 mm hypercompliant bal-


loon was inflated in the left ICA, distal to the ophthalmic artery origin. A microcatheter run with its tip in the ICA at the level of left ophthalmic artery origin revealed no opacification of the ophthalmic artery due to preferential retrograde flow across the PTA into the posterior circulation (Fig 1B). Ophthalmic artery flow was re-established on restoration of forward flow after balloon deflation. The only option left was using 2 balloons, one at the former position and the other at the PTA origin, followed by injection of the drug in the segment between these 2 balloons. However, due to the excessive complication risk anticipated due to the presence of 2 balloons in a single artery of an infant,³ this was not attempted. The patient was thus referred for surgical management.

Although the authors have highlighted different approaches to successfully treating intraocular retinoblastomas via the endovascular route, knowledge of embryologic variations in the involved vascular territory and their hemodynamic effects is also essential to prevent failure.

REFERENCES

1. Bertelli E, Leonini S, Galimberti D, et al. **Hemodynamic and anatomic variations require an adaptable approach during intra-arterial chemotherapy for intraocular retinoblastoma: alternative routes, strategies, and follow-up.** *AJNR Am J Neuroradiol* 2016;37:1289–95 CrossRef Medline
2. Yamane T, Kaneko A, Mohri M. **The technique of ophthalmic arterial infusion therapy for patients with intraocular retinoblastoma.** *Int J Clin Oncol* 2004;9:69–73 CrossRef Medline
3. Suzuki S, Yamane T, Mohri M. **Selective ophthalmic arterial injection therapy for intraocular retinoblastoma: the long-term prognosis.** *Ophthalmology* 2011;118:2081–87 CrossRef Medline

 C. Paruthi

 V. Gupta

 N. Khandelwal

Department of Radio-Diagnosis
Postgraduate Institute of Medical Education and Research
Chandigarh, India

<http://dx.doi.org/10.3174/ajnr.A4905>

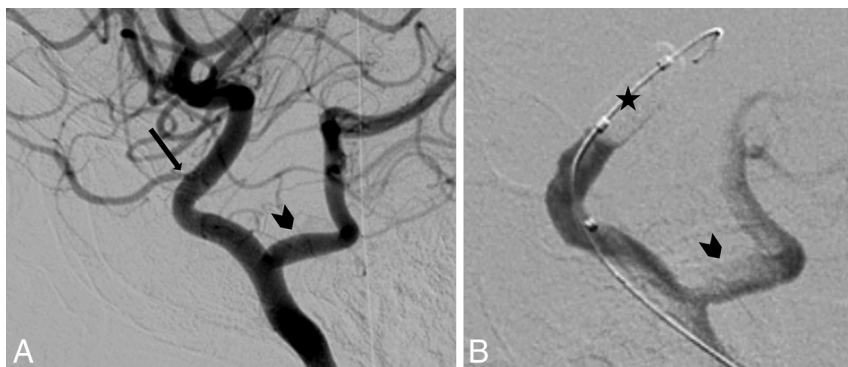

FIG 1. A, Left internal carotid artery run showing ophthalmic artery takeoff at an acute angle (*arrow*) and a type 1 persistent trigeminal artery (*arrowhead*). B, Left internal carotid artery microcatheter run after inflation of a hypercompliant balloon within its lumen distal to the origin of ophthalmic artery (*star*), showing no opacification of the ophthalmic artery and preferential flow across the persistent trigeminal artery (*arrowhead*).