



Discover Generics

Cost-Effective CT & MRI Contrast Agents



FRESENIUS
KABI

WATCH VIDEO

AJNR

Echogenic Periventricular Halo: Normal Sonographic Finding or Neonatal Cerebral Hemorrhage

Edward G. Grant, Dieter Schellinger, James D. Richardson, Mary Lee Coffey and James G. Smirniotopoulos

This information is current as of June 20, 2025.

AJNR Am J Neuroradiol 1983, 4 (1) 43-46
<http://www.ajnr.org/content/4/1/43>

Echogenic Periventricular Halo: Normal Sonographic Finding or Neonatal Cerebral Hemorrhage

Edward G. Grant¹
 Dieter Schellinger
 James D. Richardson
 Mary Lee Coffey
 James G. Smirniotopoulos

Intracranial sonographic evaluation of the normal neonate frequently reveals an echogenic halo about the lateral ventricles. This periventricular halo is seen to varying degrees when scanning in both semiaxial and parasagittal planes in almost all normal infants. Among 180 consecutive premature neonates scanned serially with real-time sonography, two were prospectively diagnosed as having a form of periventricular echogenicity that was abnormal and represented periventricular hemorrhage. This hemorrhage completely surrounded the lateral ventricles and was intensely echogenic, as echogenic as the choroid plexus. This abnormal periventricular echogenicity was reproducible from multiple scan planes and hemorrhage was confirmed by computed tomography (CT). By contrast, CT scans obtained on another 53 of the 180 premature infants failed to reveal evidence of any abnormality corresponding to the periventricular echogenicity. Both neonates with periventricular hemorrhage developed bilateral multiseptate areas of porencephaly as sequelae to their hemorrhages. The differentiation between normal periventricular echogenicity and periventricular hemorrhage therefore attains great significance to the sonographer.

Sonography is now established as the primary method for recognizing neonatal intracranial hemorrhage [1-3], and the findings in the various forms of cerebroventricular hemorrhage are well known [4-6]. Specifically, intraparenchymal hemorrhage is represented by areas of increased echogenicity within the relatively hypoechoic cerebral tissues [7]. Most cerebroventricular hemorrhages in premature infants originate in the germinal matrix [8]. If they extend into neighboring brain tissue they usually remain localized in anatomic areas contiguous with the germinal matrix [7, 9].

This paper addresses another form of neonatal cerebral hemorrhage, which is rare and which has a sonographic appearance distinctly different from the common intracerebral hematoma described above. While the latter is usually localized within one or two adjacent lobes of one hemisphere, the two patients presented here had a form of cerebral hemorrhage where blood surrounded both lateral ventricles. This resulted in a sonographic image where one hemisphere represented a mirror image of the other with a broad band of high-level echoes surrounding the ventricles.

In tandem with this yet unreported form of neonatal periventricular hemorrhage we describe a periventricular echogenic halo. This is frequently observed on normal cerebral sonograms and may be mistaken for hemorrhage. Methods for differentiating the two are discussed.

Materials and Methods

One hundred eighty premature neonates were examined using an Advanced Technology Laboratories Mark III real-time sector scanner with the 5 MHz transducer having a 90° field of vision. The transfontanelle scanning approach was used and sections in the semicoronal and parasagittal planes were obtained in every examination. Full details of this scanning

This article appears in the January/February 1983 issue of *AJNR* and the April 1983 issue of *AJR*.

Received April 28, 1982; accepted after revision August 19, 1982.

¹All authors: Department of Radiology, Georgetown University Hospital, 3800 Reservoir Rd., N.W., Washington, DC 20007. Address reprint requests to E. G. Grant.

AJNR 4:43-46, January/February 1983
 0195-6108/83/0401-0043 \$00.00
 © American Roentgen Ray Society

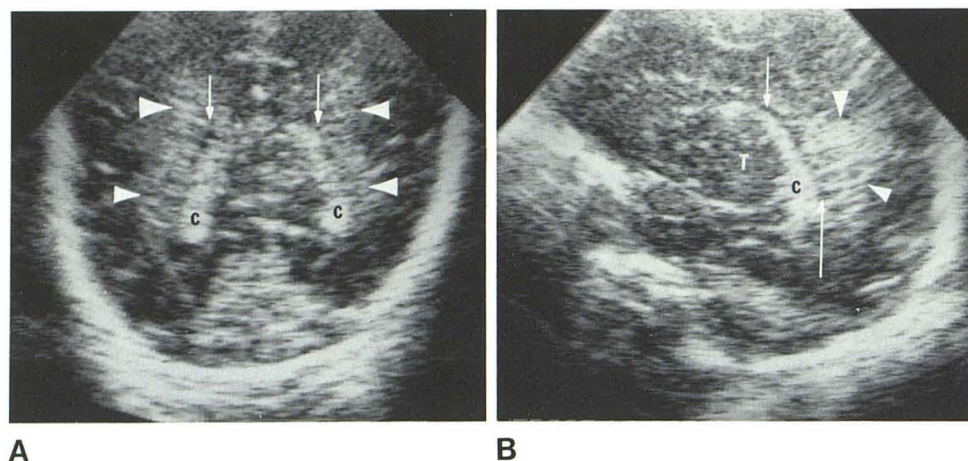


Fig. 1.—Normal subject. Semiaxial (A) and parasagittal (B) sonograms. Normal periventricular echogenic halo (arrows). Irregular, poorly defined borders. Separation from hyperechoic choroid plexus (C) by thin line of anechoic CSF (arrowheads). T = thalamus.

technique are available in recent publications [5, 10, 11].

All neonates were below 1,750 g at birth and less than 33 weeks gestational age. Scanning was performed on "inborn" premature neonates within 72 hr of birth and "outborn" infants were generally examined within 48 hr of admission. Follow-up sonograms were obtained on all neonates with abnormal scans at 1 week intervals during the infant's stay in the Intensive Care Nursery. Two consecutive normal scans (first between days 1 and 3, second at 1–2 weeks) were believed sufficient to discontinue further sonographic evaluations unless intracranial pathology was suspected later for clinical reasons. Most infants did undergo a final sonogram before discharge from the nursery. In this pool of neonates the "normal" periventricular halo of increased echogenicity was observed at sonography to some degree in virtually all cases, while only two children were diagnosed as having bilateral periventricular hemorrhage. Correlative CT scans were obtained on a total of 55 patients. In the two cases of bilateral periventricular hemorrhage the diagnosis was confirmed by CT. In the other 53 cases no abnormality could be identified that would have corresponded to or otherwise explained the echo-halo, seen on presumably normal sonograms.

Results

Normal Periventricular Echogenicity

In normal neonates hyperechoic areas are frequently noted to parallel the ventricles on semiaxial scans (fig. 1A). The normal periventricular echogenicity is always less than that of the choroid plexus. The lateral borders of these hyperechoic areas are poorly defined and there is always a thin anechoic line representing cerebrospinal fluid (CSF) between the choroid plexus and the hyperechoic area. On parasagittal sections in the areas above the trigones, regions may be identified that are highly echogenic, but always less so than the choroid plexus. These areas should be separated from the choroid by a rim of anechoic CSF and their outer borders are usually irregular. The normal periventricular echodense halo is also homogeneously echogenic throughout (fig. 1B).

These areas of increased echogenicity are not readily identified if one scans in a perpendicular plane. The periventricular echogenicity seen on the semiaxial scan will not

reappear as a definite hyperechoic area lateral to the ventricles on the parasagittal scan. The same is true of the normal periventricular echogenicity surrounding the superior border of the trigones. One cannot reproduce a corresponding area of echogenicity when scanning in axial planes superior to the trigone and occiput. This is distinct from periventricular hemorrhage, which can be identified easily in several scan planes.

Periventricular Hemorrhage

Both neonates with periventricular hemorrhage were of 30 weeks gestational age by menstrual history. Case 1, a girl, weighed 1,148 g at birth and was still clinically well at age 5 months. Case 2, a boy, weighed 1,300 g and died at 3 weeks of age with several problems, the most prominent of which was pulmonary disease. Both neonates were diagnosed as having periventricular hemorrhage at sonography and exhibited zones of intense echogenicity around the ventricles (figs. 2A and 2B). These areas were of higher reflectivity than that seen around the ventricles in normal infants, and focal areas of extremely high echogenicity were scattered through the periventricular hemorrhage in case 2 (fig. 3). The original scans of both neonates showed loss of the anechoic demarcations between the choroid plexus and the normal periventricular echogenicity. This reappeared as the ventricles expanded and anechoic CSF separated the choroid and periventricular hemorrhage. In the areas where the ventricles alone could be identified, they seemed to contain relatively little blood. The periventricular hemorrhages were well defined in both cases and could be reproduced from any scanning angle. CT scanning revealed similar dense areas of hemorrhage surrounding both lateral ventricles (fig. 2C).

Follow-up scans revealed relatively mild posthemorrhagic ventricular dilatation in both infants. Eventually multiseptate anechoic regions developed about the lateral ventricles, which had the sonographic appearance of periventricular porencephalic cysts with internal septations (figs. 2D and 2E).

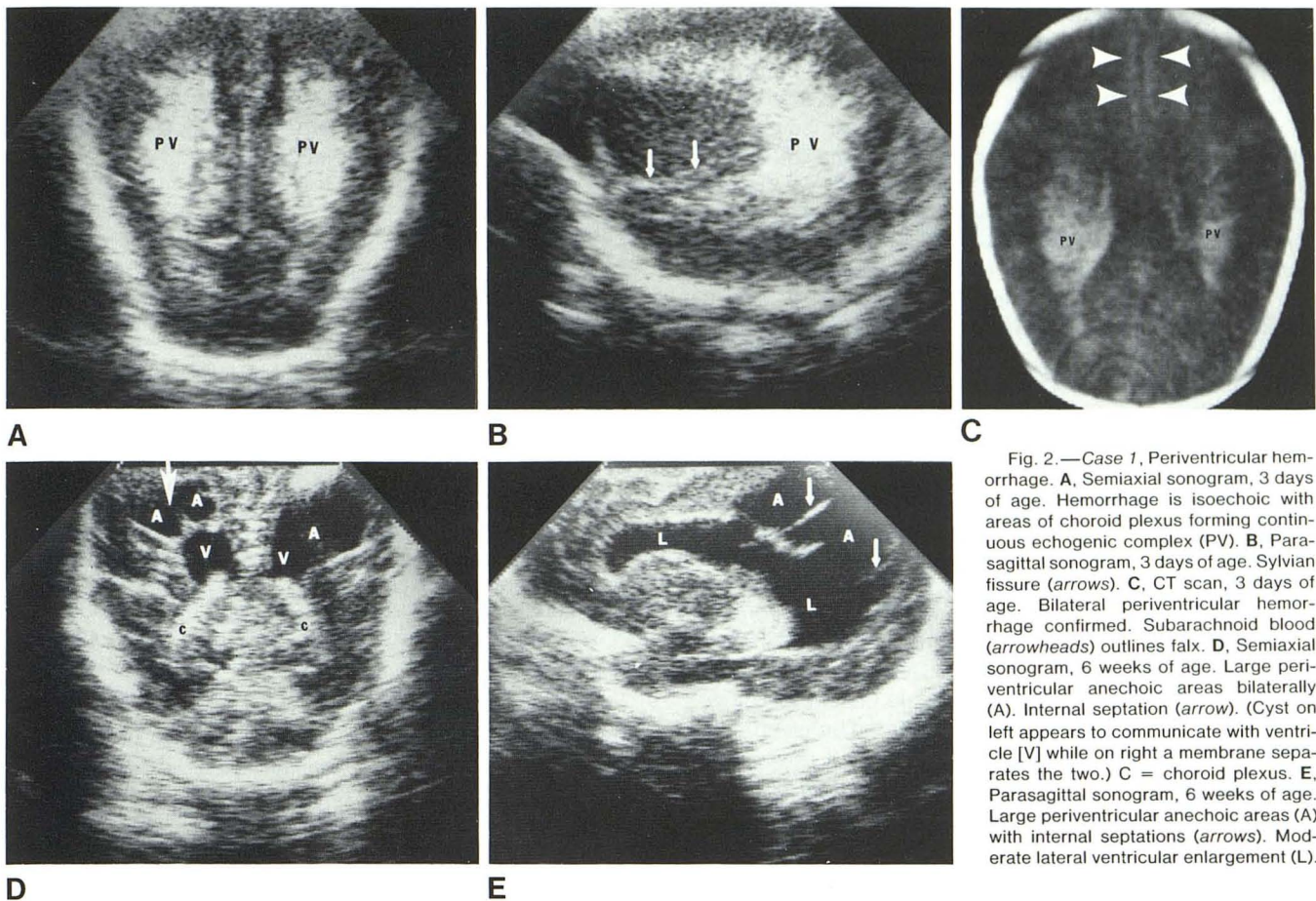


Fig. 2.—Case 1, Periventricular hemorrhage. **A**, Semiaxial sonogram, 3 days of age. Hemorrhage is isoechoic with areas of choroid plexus forming continuous echogenic complex (PV). **B**, Parasagittal sonogram, 3 days of age. Sylvian fissure (arrows). **C**, CT scan, 3 days of age. Bilateral periventricular hemorrhage confirmed. Subarachnoid blood (arrowheads) outlines falx. **D**, Semiaxial sonogram, 6 weeks of age. Large periventricular anechoic areas bilaterally (arrowheads) outlines falx. **E**, Parasagittal sonogram, 6 weeks of age. Large periventricular anechoic areas (A) with internal septations (arrows). Moderate lateral ventricular enlargement (L).

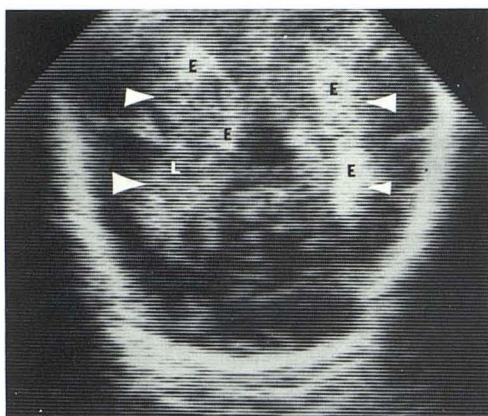


Fig. 3.—Case 2. Semiaxial sonogram, 2 days of age. Bilateral periventricular hemorrhage (arrowheads). Inhomogeneous hemorrhagic echo pattern; some areas are extremely echogenic (E), others less echogenic (L).

Discussion

Normal sonographic anatomy and sonographic findings of intraparenchymal hemorrhage in the neonatal brain have

been investigated by a number of authors [7, 9, 11]. The common periventricular echogenicity described in this article has not been discussed previously, though its similarity to a severe yet unusual form of intracranial hemorrhage gives it great importance to the sonographer. The actual cause of this frequently observed echo-halo remains speculative. One might be tempted to relate it to the dense vascular plexus normally surrounding the lateral ventricles in the fetus [8]. On the other hand, this echogenicity may merely represent a scanning artifact. The high-level periventricular echo zones clearly displayed on horizontal sonograms are not reproducible in sagittal planes. Conversely, they may be unmistakably present on sagittal images, but absent or topographically mismatched on horizontal planes. We have not been successful in eliminating them by changing gain settings or transducers.

Because of our inability to convincingly demonstrate these echogenic areas in several scan planes, we tend to believe they are artifactual. On the other hand, in two cases with verified periventricular hemorrhage, echogenicity was present from any scanning angle.

This rare, diffuse, bilateral periventricular hemorrhage that we have described may represent primary white matter hemorrhage as opposed to the more common germinal

matrix bleed. The paucity of intraventricular hematoma in the presence of widespread, bilateral hemorrhage exclusively into white matter suggests a different etiology. The periventricular white matter is known to be a preferred site for perinatal ischemia, and bleeding into an ischemic or infarcted territory would present a plausible explanation for this type of cerebral hemorrhage. Armstrong and Norman [12] connect periventricular hemorrhage with severe birth asphyxia. Pape and Wigglesworth [8] describe similar white matter hemorrhage occurring in association with bacterial and viral meningoencephalitis. Prematurity then, with its associated apnea, bradycardia, various electrolyte imbalances, and hypoxia may also be a predisposing factor toward this type of hemorrhage.

Both infants with periventricular hemorrhage eventually developed mild ventricular dilatation and an array of adjacent porencephalic cysts. We previously reported that all premature neonates who experienced intraparenchymal hemorrhage beyond the germinal matrix develop porencephaly [9]. Apparently, this unusual form of periventricular hemorrhage follows the same pattern. A third case of multiseptate periventricular porencephaly was encountered in another 5-week-old premature infant on a predischarge sonogram. The sonographic findings were identical with the late changes observed in the two cases described above. We have to infer that this patient also suffered periventricular hemorrhage. Previous sonograms at 2 and 8 days of life were normal. We assume that the bleeding had occurred after these initial scans and thus remained undetected. The absence of these late changes in the rest of our patient sample would lend credence to the notion that the usually observed periventricular halo is indeed a normal finding.

To differentiate the two forms of periventricular echogenicity, all scans should be obtained in two planes. For diagnosis of periventricular hemorrhage, the sonographic changes should be reproducible in all scan planes. Normal periventricular echogenicity should also never be as reflective as the choroid plexus. Internal inhomogeneity of the echogenic halo would support hemorrhage, as would loss of the anechoic line of CSF separating the choroid plexus and the normal periventricular halo before the onset of

posthemorrhagic ventricular enlargement.

We conclude, therefore, that recognition of this normal periventricular echogenic halo attains diagnostic significance and must be differentiated from the unusual form of bilateral periventricular hemorrhage, also presented here, which may produce a similar image.

REFERENCES

1. Grant EG, Borts FT, Schellinger D, McCullough DC, Sivasubramanian KN, Smith Y. Real time ultrasonography of neonatal intraventricular hemorrhage and comparison with computed tomography. *Radiology* **1981**;139:687-691
2. Johnson ML, Rumack CM, Mannes EJ, Appareti KE. Detection of neonatal intracranial hemorrhage utilizing real-time and static ultrasound. *JCU* **1981**;9:427-433
3. Mack LA, Wright K, Hirsch JH, et al. Intracranial hemorrhage in premature infants: accuracy of sonographic evaluation. *AJR* **1981**;137:245-250
4. London DA, Carroll BA, Enzmann DR. Sonography of ventricular size and germinal matrix hemorrhage in premature infants. *AJNR* **1980**;1:295-300
5. Grant EG, Schellinger D, Borts FT et al. Real-time sonography of the infant and neonatal head. *AJNR* **1980**;1:487-492
6. Sauerbrei EE, Digney M, Harrison PB, Cooperberg PL. Ultrasonic evaluation of neonatal intracranial hemorrhage and its complications. *Radiology* **1981**;139:677-685
7. Grant EG, Borts F, Schellinger D, McCullough DC, Smith Y. Sonographic findings in cerebral intraparenchymal hemorrhage in neonates. *AJNR* **1981**;2:129-132
8. Pape KE, Wigglesworth JS: *Haemorrhage, ischemia and the perinatal brain*. Philadelphia: Lippincott, **1979**
9. Grant EG, Kerner M, Schellinger D, et al. Evolution of porencephalic cysts from intraparenchymal hemorrhage in neonates: sonographic evidence *AJNR* **1982**;3:47-50
10. Babcock DS, Han BK. The accuracy of high resolution, real time ultrasonography of the head in infancy. *Radiology* **1981**;139:667-676
11. Shuman WP, Rogers JV, Mack LA, Alford EC, Christie DP. Real time sonographic sector scanning of the neonatal cranium: technique and normal anatomy. *AJNR* **1981**;2:349-356
12. Armstrong D, Norman MG. Periventricular leukomalacia in neonates. Complications and sequelae. *Arch Dis Child* **1974**;49:367-375