



Get Clarity On Generics

Cost-Effective CT & MRI Contrast Agents



FRESENIUS
KABI

WATCH VIDEO

AJNR

CT of brain: technique for comparative postmortem slicing.

J P Nguyen, A Gaston, F Louarn, C Marsault, E Bargiotas, J Wallman and J Poirier

AJNR Am J Neuroradiol 1983, 4 (2) 191-193

<http://www.ajnr.org/content/4/2/191.citation>

This information is current as
of August 14, 2025.

CT of Brain: Technique for Comparative Postmortem Slicing

J. P. Nguyen,¹ A. Gaston,² F. Louarn,³ C. Marsault,² E. Bargiotas,² J. Wallman,² and J. Poirier⁴

Traditionally, the fixed brain is sliced into sections in a coronal or horizontal plane for neuropathologic analysis. Computed tomography (CT) requires a reconsideration of this procedure and development of methods that allow for correlation of anatomopathologic aspects of lesions with corresponding CT scan images [1, 2]. This has been proposed by many authors and several techniques for accomplishing this have been presented [3, 4]. However a simple method without complex equipment is needed so that it will be used on a routine basis. The procedure we developed satisfies these criteria and is the substance of this paper. This method was applied with success on the brains of 20 patients who underwent CT examination prior to death.

Method

The principle of the method is to find the angle at which the CT scan images were made relative to an arbitrary baseline, to reference this to a lateral skull radiograph, and then to cut the brain at the same angle [5]. We chose a line drawn between the base of occipital and temporal poles as our baseline because the brain will sit on this baseline when the brainstem is removed. The steps are illustrated in figure 1.

1. A CT scan image is selected from the last study prior to the patient's death; a line is drawn from the anterior border of the scan picture bisecting the image of the cranium (fig. 1A). The distances from this anterior border (marked P) are measured to the anterior (A) and posterior (B) borders of the cranium (i.e., PA and PB). These distances are measured on each CT scan slice of the study. The values, $a = PA$ and $b = PB$, obtained are multiplied by the magnification factor of the scanner, which for our scanner (Siemens Somatom SD), is indicated by a line to the right of the image and represents 5 cm. For further accuracy these numbers should be also multiplied by the magnification factor of a standard lateral skull film (usually 1.10).

2. A series of parallel lines spaced according to the

thickness of the scan slices is drawn on graph tracing paper. To the right, a line P is drawn perpendicular to the parallel lines. This line represents all of the point Ps obtained in part 1, or the anterior borders of all scan slices. The adjusted measurements obtained in part 1 are marked on the appropriate parallel line as points A, B, A1, B1, etc. (fig. 1B). In figure 1B a lateral image of the skull has been drawn in to facilitate the explanation of what the points represent.

3. The tracing paper is then placed over a lateral radiograph of the cranium and oriented to obtain as close a fit as possible of the points with the outer table of the skull (fig. 1C). Being careful not to disturb the orientation, one of the parallel lines is traced onto the radiograph. Thus the scanning plane relative to the skull has been transferred to a lateral view of the skull. With the aid of the lateral radiograph and the calculated reference plane one can reference the CT scan plane to the brain itself. On the radiograph a line is drawn connecting the base of the middle fossa T, to the torcula O (fig. 1D). This is our arbitrary baseline, which is useful because this line represents the base of the occipital and temporal lobes. The angle α between the intersecting lines is the scan plane angle relative to the baseline.

Neuropathologic Procedure

At autopsy the brain is removed and fixed in the traditional manner. The last CT scan is selected and the scan plane determined as in the preceding discussion. The fixed brain is held in such a position that the cerebellum and brainstem are transected, by a knife, parallel to the baseline. This allows the brain to be placed so that it rests on the temporal and occipital lobes (i.e., on the baseline) (fig. 2A).

A simple platform (fig. 2A) was constructed with articulating arms attached at one end that can be secured at variable angles relative to the base. With the brain placed on the platform the articulating arms are fixed at the scan plane angle α . The brain is held to keep it from slipping and a thin knife is slid along the arms creating the first scan-brain

Received November 4, 1981; accepted after revision October 20, 1982.

¹ Department of Neurosurgery, Hôpital Henri Mondor, 94010 Creteil Cedex, France.

² Department of Neuroradiology, Hôpital Henri Mondor, 51 av. du Mal de Lattre de Tassigny, 94019 Creteil Cedex, France. Address reprint requests to A. Gaston.

³ Department of Neurology, Hôpital Henri Mondor, 94010 Creteil Cedex, France.

⁴ Department of Neuropathology, Hôpital Henri Mondor, 94019 Creteil Cedex, France.

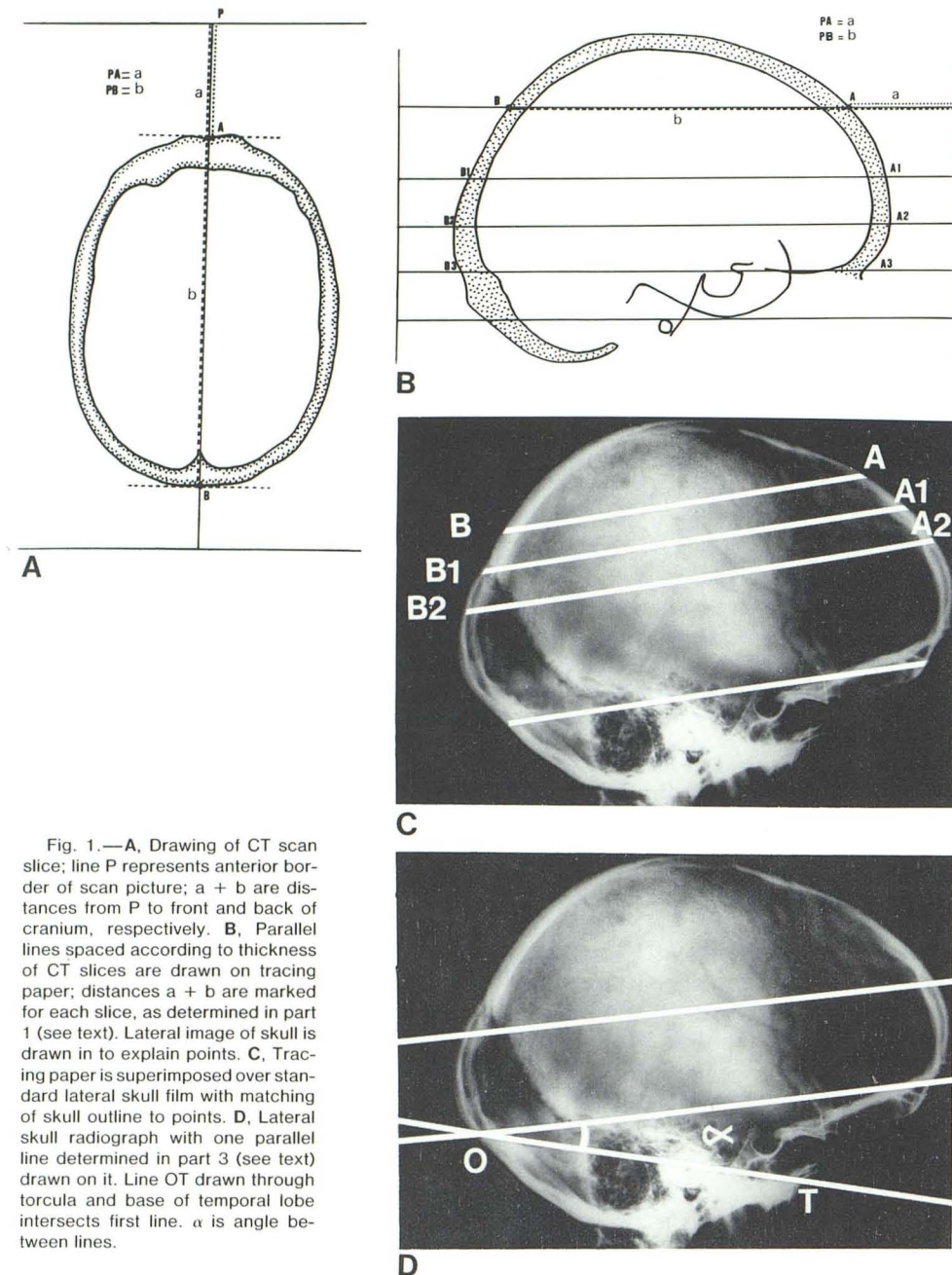


Fig. 1.—A, Drawing of CT scan slice; line P represents anterior border of scan picture; $a + b$ are distances from P to front and back of cranium, respectively. B, Parallel lines spaced according to thickness of CT slices are drawn on tracing paper; distances $a + b$ are marked for each slice, as determined in part 1 (see text). Lateral image of skull is drawn in to explain points. C, Tracing paper is superimposed over standard lateral skull film with matching of skull outline to points. D, Lateral skull radiograph with one parallel line determined in part 3 (see text) drawn on it. Line OT drawn through torcula and base of temporal lobe intersects first line. α is angle between lines.

section equivalent (fig. 2B).

Subsequent slices are made parallel to this cut at intervals determined by distances between scan slices. We use an electric rotary blade which allows for parallel slices free of knife marks. All brain slices are compared with the corresponding CT scan images and photographed rapidly. The whole procedure is not much more time-consuming than traditional brain sectioning, typically requiring 20 min per brain.

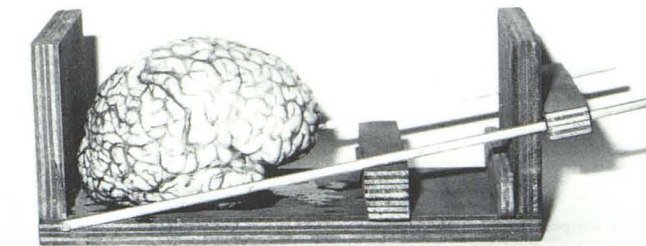
Limits

Some technical inadequacies, such as poor quality of the last CT scan, prevent good identification of the CT scan

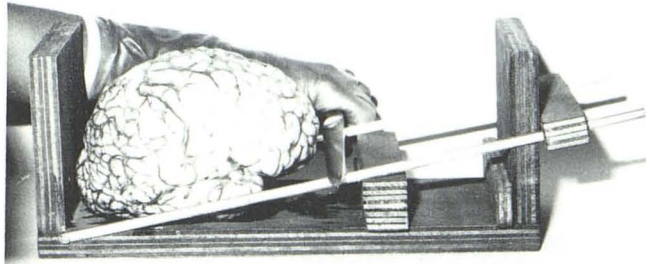
plane, particularly if there are motion artifacts or recentering of the patient within the scan circle during scanning.

Our procedure allows an angular error of $\pm 2^\circ$ in identification of the CT scan reference plane; however, care must be taken to secure the articulating arms of the brain cutting platform to maintain the scan plane angle. Collection of slices on transparent Plexiglas or a piece of radiographic film allows us to examine and photograph them without disturbing the anatomy (fig. 3).

Finally, for certain brain disorders, if a long period has elapsed between the last CT scan and the patient's death, the pathologic material may be nonrepresentative; for instance brain liquefaction after prolonged ischemia.



A



B

Fig. 2.—A, Simple frame with articulating arms allowing for brain cutting in plane of CT. Brain "sits" on line OT (fig. 1D). Articulating arm is positioned at angle α with respect to platform. B, Knife slid along arm of device to create first correlative CT scan brain slice.

ACKNOWLEDGMENT

We thank Martine Favolini whose pathologic technique aided us in this work.

REFERENCES

1. Kistler JP, Hochberg FH, Brooks BR, New PFJ, Schnur J. Computerized axial tomography: clinico-pathologic correlation. *Neurology* (NY) **1975**;25:201-209
2. Jacobs L, Kinkel W, Heffner RR. Autopsy correlation of CT: experience with 6000 CT scans. *Neurology* (NY) **1976**;26:1111-1118
3. Matsui T, Hirano A. *An atlas of the human brain for CT*. Stuttgart: Fischer-Verlag, **1978**
4. Anders U, Bergstrom K, Spannare B, Olsson Y. Reliability of CT in assessing histopathological features of malignant supratentorial gliomas. *J Comput Assist Tomogr* **1981**;5:625-636
5. Nguyen JP, Van Effentere R, Fohano D, Robert G, Sichez JP, Gardeur D. Méthode pratique de repérage spatial pré-opératoire des petites néoformations intra-crâniennes à partir des données de la tomodensitométrie. *Neurochirurgie* **1980**;26:333-339

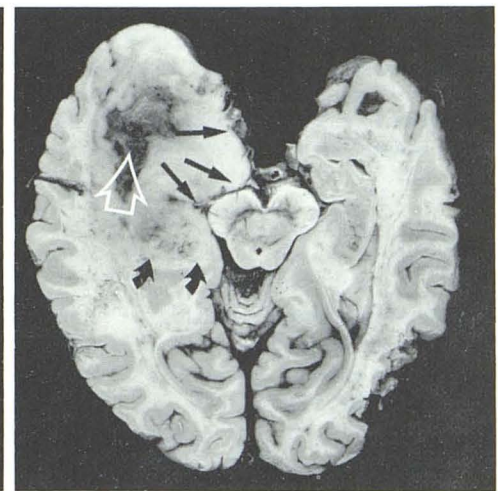
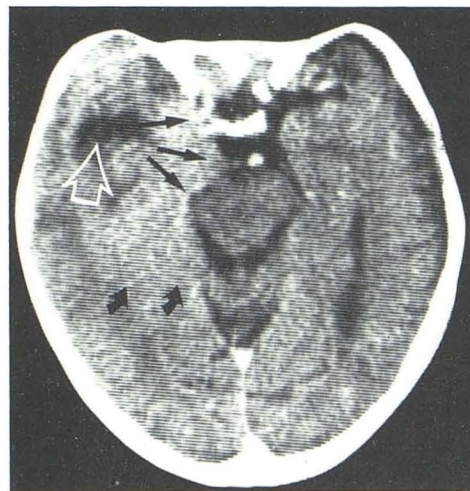


Fig. 3.—Example of good CT-pathologic correlation with our method. Uncal herniation and compression of left cerebral peduncle (straight arrows). Other aspects of lesion easily compared (other arrows).