



Get Clarity On Generics

Cost-Effective CT & MRI Contrast Agents

 FRESENIUS
KABI

[WATCH VIDEO](#)

AJNR

Evaluation of prototype equipment for digital subtraction angiography in diagnosing intracranial lesions.

M Takahashi, Y Hirota, H Bussaka, T Tsuchigame, M Miyawaki, S Ueno, Y Matsukado and Y Hirata

This information is current as
of August 17, 2025.

AJNR Am J Neuroradiol 1983, 4 (3) 259-262
<http://www.ajnr.org/content/4/3/259>

Evaluation of Prototype Equipment for Digital Subtraction Angiography in Diagnosing Intracranial Lesions

Mutsumasa Takahashi,¹ Yoshihisa Hirota,¹ Hiromasa Bussaka,¹ Tadatosh Tsuchigame,¹ Masayuki Miyawaki,¹ Sukeyoshi Ueno,¹ Yasuhiko Matsukado,² and Yoshibumi Hirata²

Two prototype units for digital subtraction angiography have been developed by Japanese manufacturers. Their performance in demonstrating various intracranial lesions in 121 patients was evaluated. Comparison with conventional selective catheter angiography was possible in 77 patients. Digital subtraction angiography proved useful in preoperative evaluation of pituitary tumors when transsphenoidal surgery was being considered; demonstration of faint tumor stains which might be missed on conventional angiography; demonstration of larger aneurysms, arteriovenous malformations, and tumors as a screening technique; demonstration of abnormalities involving the dural sinuses; and follow-up of patients after surgery or embolization.

The usefulness of digital subtraction angiography (DSA) has been established for evaluation of the aorta and its primary branches, especially for delineation of the extracranial carotid and vertebral arteries [1-6]. Several recent reports have demonstrated the value of DSA in the intracranial vascular system [7-10]. Japanese manufacturers have developed two prototype units for DSA. We have evaluated their clinical usefulness in diagnosing intracranial diseases.

Equipment and Technique

Two DSA imaging systems (Hitachi and Shimadzu, respectively) were used in this study [11]. The major components and capabilities of each unit are outlined in table 1. Both units have U-arm assemblies that can position the x-ray tube and image intensifier for any desired projection while maintaining the patient in a comfortable position on a floating table top.

The output signal of the image intensifier-television camera system is digitized by an analog-digital converter in which digital information is formed on 512×512 pixels, 8-9 bits deep. Digital information is fed into the image processing assembly after logarithmic amplification, where two to eight frames are combined and subtracted from the mask images to form the final digital images. Up to 32 serial digital images can be stored in real time in the frame memories, while additional images are transferred to other recording units as necessary (Hitachi) or recorded on a video disk recorder (Shimadzu). Using the host computer, image manipulations such as remasking, edge enhancement, image smoothing, image magnification, r-adjustment, and changing of window level and width can be carried out.

Subjects and Methods

DSA was performed on 121 patients with known or suspected intracranial lesions. In 77 cases conventional cerebral angiography was performed within 2 weeks of DSA. Most cerebral angiograms were obtained using transfemoral catheter techniques with biplane stereoscopic magnification.

Patients were denied food and water before the procedure. In most cases, a 16 gauge, 15-cm-long Teflon needle was inserted in the antecubital vein. When the thoracic artery and its branches were examined together or when placement of the needle in the antecubital vein was unsuccessful, an angiographic catheter (5.5 French) was inserted in the femoral vein using the Seldinger technique and advanced under fluoroscopy into the inferior vena cava near the right atrium. Forty ml of 76% meglumine and sodium diatrizoate solution was injected mechanically at a flow rate of 12-15 ml/sec, using a pressure injector. A 20-25 ml solution of 5% glucose or saline was layered over the contrast medium. At 5-8 sec after initial injection, serial images were obtained at a rate of one/sec for 20 sec or two/sec for 5 sec, followed by one/sec for 10 sec. The beginning of the exposure varied according to heart rate. Filming of the first series of images in each patient generally began slightly earlier than filmings of later series, which were adjusted after review of the first series.

Straight anteroposterior and lateral projections were obtained routinely. Caldwell projections were frequently useful for delineation of the horizontal portion of the anterior and middle cerebral arteries. Towne projections were used for posterior fossa lesions. Slightly oblique lateral projections were obtained to avoid overlapping or superposition of the carotid siphon. The patient with normal renal function can withstand three or four injections.

The results of DSA were graded as: (1) excellent, when findings were comparable or superior to those obtained by conventional angiography; (2) good, when useful information was obtained, but with significant chance of error; (3) fair, when no diagnostic information was obtained, although intracranial vessels were visualized; and (4) poor, when the study was unsuccessful or uninterpretable.

Results

In 18 (14.9%) of 121 patients, DSA was judged excellent or as diagnostic as conventional angiography for evaluation of intracranial lesions. In 17 cases (14%), studies were technically unsuc-

¹ Department of Radiology, Kumamoto University School of Medicine, Honjo 1-1-1, Kumamoto, Japan 860. Address reprint requests to M. Takahashi.

² Department of Neurosurgery, Kumamoto University School of Medicine, Kumamoto, Japan 860.

cessful or uninterpretable. In the great majority (70.8%) of cases, results of DSA fell between these two extremes (table 2). Most "poor" examinations were secondary to misregistration artifacts from patient motion and technical difficulties encountered during the early phase of clinical trials.

Brain Tumors

Larger tumors and vascular tumors were diagnosed easily by DSA, whereas smaller tumors (diameter <3 cm) and avascular tumors were difficult to diagnose.

Tumor stains were clearly demonstrated by DSA. Meningiomas in the suprasellar area, olfactory groove, and planum sphenoidale were better delineated by DSA than by conventional angiography (fig. 1). This was due partly to higher contrast sensitivity and partly to bilateral blood supply to the tumors, both sides being opacified during DSA.

The superior sagittal sinus was clearly visualized with DSA and invasion of the superior sagittal sinus was demonstrated in two convexity meningiomas (fig. 2).

In patients with intrasellar tumors, DSA provided enough information to recommend transsphenoidal hypophysectomy.

TABLE 1: DSA Prototype System Components and Capabilities

Component	Manufacturer	
	Hitachi	Shimadzu
Generator	150 kVp, 1,300 mA	150 kVp, 1,000 mA
X-ray tube	450 kH, 0.8/1.3 mm focus	400 kH, 1.0 mm focus
Image intensifier	22.9 cm, 17.8 cm Csl	22.9 cm Csl
Grid	8:1, 28 line pairs/cm, wood	10:1, 32 line pairs/cm, glass fiber
TV camera	Plumbicon, 525 lines, 5 MHz, SNR 650:1	Plumbicon, 525 lines, 5 MHz, SNR 450:1
Amplification	Logarithmic or linear	Logarithmic or linear
A/D converter	9 bit, 20 MHz	8 bit, 10 MHz
Digital memory	512 × 512 × 16 bits (×2) 512 × 512 × 10 bits (18–30)	512 × 512 × 13 bits (×2)

Note.—Csl = cesium iodide; SNR = signal-to-noise ratio; A/D = analog-to-digital.

Cerebral Aneurysms

Larger cerebral aneurysms and their necks were clearly demonstrated by DSA, which was as diagnostic as conventional angiography (fig. 3). There was considerable difficulty in diagnosing smaller aneurysms, particularly when the diameter of the aneurysm was less than twice the diameter of the parent artery.

Arterial spasm secondary to subarachnoid hemorrhage was observed with some difficulty, although theoretically such physiologic activity should be more readily demonstrated by DSA. DSA could be repeated easily to monitor such conditions.

Arteriovenous Malformations

Arteriovenous malformations were demonstrated to good advantage. The feeding arteries and draining veins were visualized with DSA as well as by conventional angiography (fig. 4). Even a 1 cm arteriovenous malformation was clearly shown.

Arterial Occlusive Diseases

Arterial occlusions and stenoses of more than 50% were demonstrated in larger vessels such as the internal carotid arteries, horizontal parts of the anterior and middle cerebral arteries, and basilar and proximal posterior cerebral arteries (fig. 5). Occlusions in smaller vessels and stenoses of less than 50% were not demonstrated with certainty. Collateral vessels were often difficult to observe and only the recanalized parts of the arteries were visualized.

Other Intracranial Lesions

A case of carotid-cavernous sinus fistula was clearly demonstrated with visualization of the site of the fistula and enlarged superior ophthalmic vein. Vascular anomalies such as azygous anterior cerebral artery, persistent primitive arteries, and venous sinus anomalies were also demonstrated. A large hypertensive intracerebral hemorrhage was diagnosed.

Postoperative Evaluation

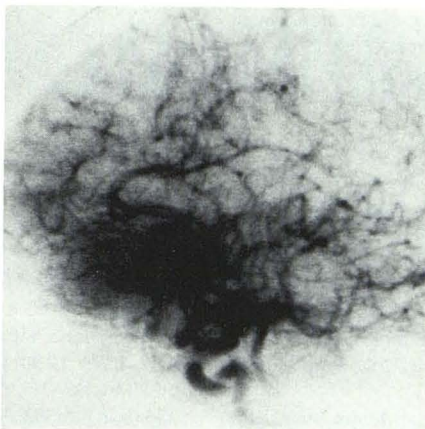Patients with brain tumors, arteriovenous malformations, and cerebral aneurysm were evaluated by postoperative DSA. The procedure was also used to evaluate anastomosis between the superficial temporal artery and middle cerebral artery. Patency or

TABLE 2: Diagnostic Usefulness of DSA in Demonstrating Intracranial Disease

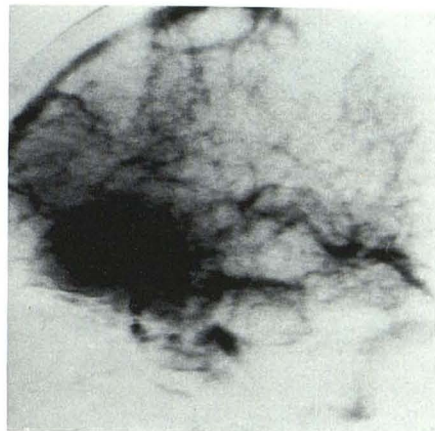
Pathology	No. (%)				
	Excellent	Good	Fair	Poor	Totals
Brain tumor	10	16	7	9	42
Cerebral aneurysm	4	2	1	...	7
Arteriovenous malformation	2	1	3
Arterial occlusive disease	2	15	11	3	31
Cerebrovascular anomaly	...	1	4	...	5
Hypertensive intracerebral hemorrhage	...	3	2	...	5
STA-MCA anastomosis	...	1	1	1	3
Other intracranial lesions	...	15	6	4	25
Totals	18 (14.9)	54 (44.4)	32 (26.4)	17 (14.0)	121

Note.—STA-MCA = superficial temporal artery to middle cerebral artery.

Fig. 1.—Subfrontal meningioma, lateral DSA. Catheter angiography demonstrated enlargement of ophthalmic and ethmoidal arteries but failed to show tumor stain. **A**, Arterial phase. Proximal part of anterior cerebral artery is displaced superoposteriorly. Ophthalmic artery is not shown. **B**, Venous phase. Dense tumor stain in anterior fossa with drainage into cavernous sinus via uncal vein.

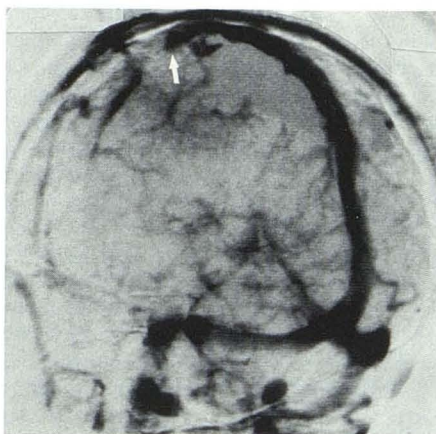

A

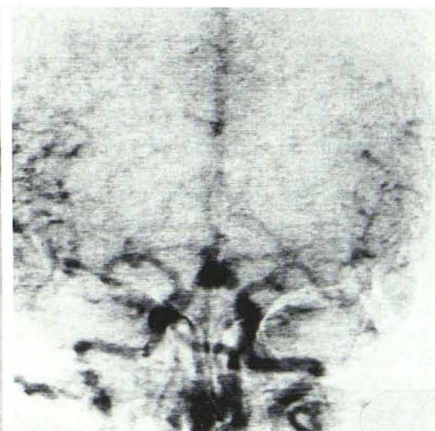


B

Fig. 2.—Small frontal meningioma, oblique lateral DSA. Catheter angiography revealed tumor in superior left frontal lobe near coronal suture, where radiating vessels were supplied by left middle meningeal artery; no definite tumor stain was noted. DSA shows occlusion of superior sagittal sinus with formation of venous collaterals inferiorly over frontal lobe (arrow).

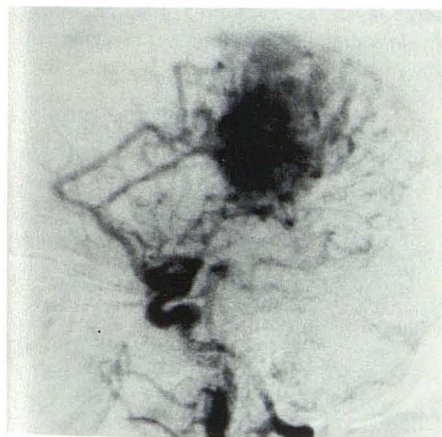

2

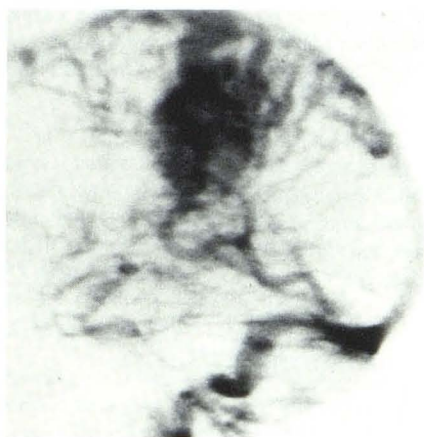

3

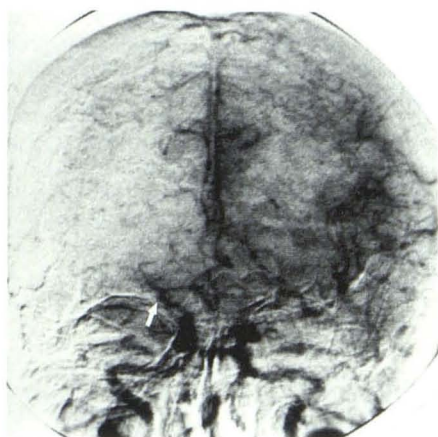
Fig. 3.—Cerebral aneurysm, anteroposterior DSA. Selective carotid angiography was successful only on left. DSA shows saccular aneurysm overlying anterior communicating artery and basilar tip. Vertebrobasilar system and right carotid artery are without aneurysms.



4A



4B



5

Fig. 4.—Arteriovenous malformation, lateral DSA. **A**, Arterial phase. Extensive arteriovenous malformation in right parietal area, fed by pericallosal and callosomarginal arteries. Middle cerebral artery also contributes to malformation. **B**, Venous phase. Drainage via veins of Trolard and Labbe toward superior sagittal and lateral sinuses.

Fig. 5.—Cerebral infarction, anteroposterior DSA. Occlusion of right middle cerebral artery from its origin (arrow). Leptomeningeal collaterals from posterior cerebral and anterior cerebral arteries.

stenosis of the anastomosis was visualized, but slight stenosis or slightly compromised flow could not be demonstrated. DSA was often useful in evaluating patients who had undergone embolization.

Discussion

The advantages of DSA have been emphasized by many authors [2-4, 7, 12]. DSA is safer and less invasive than conventional cerebral angiography since arterial catheterization or direct arterial puncture is not necessary. The procedure can be performed easily on patients who are in poor condition or of advanced age. In addition, it can be performed on an outpatient basis. The cost of DSA is lower than that of conventional cerebral angiography. Real-time images can be obtained, and repeat and/or follow-up examinations are easily performed.

Because of better low-contrast sensitivity, faint tumor stains are better demonstrated by DSA than by conventional angiography [8, 10]. Tumor stains of meningioma and metastasis were well delineated in this study. The dural sinuses are better visualized by DSA because opacified blood drains into the sinus bilaterally. For this reason, DSA may be the procedure of choice for imaging sinus occlusion or stenosis [7, 8, 10].

DSA has more physiologic potential than conventional angiography, since direct arterial injection of contrast media and catheter placement in the artery are unnecessary. Because all intracranial vessels are simultaneously opacified, more physiologic observation of cross-filling and collateral flow can be made in occlusive diseases [8].

Although DSA may not provide as much detail as conventional angiography, the information obtained may be sufficient for determining the extent and vascularity of cerebral tumors, especially when DSA data are correlated with computed tomographic (CT) findings [11]. For example, intrasellar masses can be evaluated with DSA and CT, eliminating the need for conventional angiography, since the primary role of angiography in these cases is to exclude the possibility of existing aneurysm in the parasellar area.

DSA has certain limitations [3, 4, 11]. Limited spatial resolution and misregistration artifacts may produce undiagnostic or uninterpretable images. The procedure cannot be used successfully for evaluation or detection of small lesions. With technical advancements, however, these difficulties are likely to be overcome to some extent. The overlapping or superposition of vessels on DSA images is also a disadvantage. Slightly oblique lateral projections are frequently useful in overcoming this handicap. The amount of contrast medium currently required for DSA is large, but biplane DSA may soon solve this problem.

DSA can be performed expeditiously and noninvasively. With further technical development, it will become an important diagnostic tool in the pathologic evaluation of the central nervous system.

REFERENCES

1. Chilcote WA, Modic MT, Pavlicek WA, et al. Digital subtraction angiography of the carotid arteries: a comparative study in 100 patients. *Radiology* **1981**;139:287-295
2. Christenson PC, Ovitt TW, Fisher HD, Frost MM, Nudelman S, Roehrig H. Intravenous angiography using digital video subtraction: intravenous cervicocerebrovascular angiography. *AJNR* **1980**;1:379-386, *AJR* **1980**;135:1145-1152
3. Meaney TF, Weinstein MA, Buonocore E, et al. Digital subtraction angiography of the human cardiovascular system. *AJR* **1980**;135:1153-1160
4. Ovitt TW, Christenson PC, Fisher HD III, et al. Intravenous angiography using digital video subtraction: x-ray imaging system. *AJNR* **1980**;1:387-390, *AJR* **1980**;135:1153-1160
5. Strother CM, Sackett JF, Crummy AB, et al. Clinical applications of computerized fluoroscopy: the extracranial carotid arteries. *Radiology* **1980**;136:781-783
6. Turski PA, Strother CM, Turnipseed WD, et al. Evaluation of extracranial occlusive disease by digital subtraction angiography. *Surg Neurol* **1981**;16:394-398
7. Carmody RF, Smith JRL, Seeger JF, Ovitt TW, Capp MP. Intracranial applications of digital intravenous subtraction angiography. *Radiology* **1982**;144:529-534
8. Modic MT, Weinstein MA, Chilcote WA, et al. Digital subtraction angiography of the intracranial vascular system: comparative study in 55 patients. *AJNR* **1981**;2:527-534, *AJR* **1982**;138:299-306
9. Seeger JF, Weinstein PR, Carmody RF, Ovitt TW, Fisher HD, Capp MP. Digital video subtraction angiography of the cervical and cerebral vasculature. *J Neurosurg* **1982**;56:173-179
10. Takahashi M, Bussaka H, Nonaka N, Miura Y, Hirata Y, Matsukado Y. Digital fluoroscopic angiography in central nervous system (in Japanese). *Neuro Med Chir (Tokyo)* (in press)
11. Takahashi M, Hirota Y, Tsuchigame T, et al. Clinical value of digital fluoroscopic angiography (in Japanese). *J Med Imaging* **1982**;2:660-672
12. Strother CM, Sackett JF, Crummy AB, et al. Intravenous video arteriography of the intracranial vasculature: early experience. *AJNR* **1981**;2:215-218