



Get Clarity On Generics

Cost-Effective CT & MRI Contrast Agents



FRESENIUS
KABI

WATCH VIDEO

AJNR

Monitoring of hemispheric or brainstem functions with neurophysiologic methods during interventional neuroradiology.

W Hacke, H Zeumer and E Berg-Dammer

AJNR Am J Neuroradiol 1983, 4 (3) 382-384

<http://www.ajnr.org/content/4/3/382>

This information is current as
of August 23, 2025.

Monitoring of Hemispheric or Brainstem Functions with Neurophysiologic Methods during Interventional Neuroradiology

W. Hacke,¹ H. Zeumer, and E. Berg-Dammer

Interventional neuroradiology, sometimes requiring full anesthesia, is now performed in high-risk patients. The neurologic state of an anesthetized patient cannot always be sufficiently evaluated during the neuroradiologic examination. In such cases neurophysiological methods provide information about some aspects of the patient's cerebral condition. Three useful neurophysiological methods for monitoring hemispheric or brainstem functions during the neuroradiologic procedure are on-line or Fourier-transformed electroencephalographic (EEG) analysis; the monitoring of somatosensory-evoked potentials; and the monitoring of brainstem acoustic-evoked potentials. All methods can be done in the operating room with small, mobile equipment.

Interventional neuroradiology has created new diagnostic and therapeutic approaches, including reversible or definitive occlusion of extra- or intracranial arteries by balloon catheters, therapeutic embolization, and selective local thrombolytic therapy. These procedures influence a patient's neurologic state, and are not without an element of risk. The change of the neurologic state of the patient cannot always be sufficiently controlled by clinical methods alone during these procedures, especially if anesthesia is needed or the patient is unconscious. In these cases neurophysiologic methods give objective data about changes in a patient's brain function.

We have found three neurophysiologic methods useful for the continuous monitoring of cerebral functions during interventional neuroradiology. The three methods are on-line conventional or Fourier-transformed electroencephalography (EEG), which is used to monitor hemispheric function; continuous recording of brainstem-evoked acoustic potentials, used for monitoring brainstem functions; and continuous recording of somatosensory-evoked cortical potentials, used for monitoring both hemispheric and brainstem functions.

Methods and Applications

EEG Monitoring

Serebinenko [1] discussed the possibility of electrophysiologic studies during therapeutic or diagnostic occlusion of the carotid artery with balloon catheters. Several reports of the use of EEG before and during operations on carotid arteries have recently been published [2-4]. While most of the studies have conventional EEG derivations, Chiappa et al. [4] reported the superior frequency

analysis of the intraoperative EEG compared with that of conventional EEG. But their method could not be used for on-line monitoring. They used bipolar EEG derivations recorded simultaneously on tape, and performed frequency analysis afterward.

In 1981 Hacke et al. [5] described on-line Fourier-transformed EEG analysis during reversible, diagnostic occlusion of the internal carotid artery before neurosurgical operation. They used two bipolar derivations with electrode positions P₁-O₁ and P₂-O₂ or C_z-T₅ and C_z-T₆ according to the international 10/20 system. This examination can be done in the operating room with a small, mobile "bedside" system, which records the conventional EEG signal and simultaneously performs the Fourier-transformed frequency analysis.

In figure 1 the EEG frequency analysis is demonstrated in a case of a meningioma of the left sphenoid bone before, during, and after an occlusion of the left internal carotid artery that lasted 8 min. There were no changes in the conventional EEG or in the Fourier-transformed recording during the reversible occlusion, which indicated that the definitive occlusion of the internal carotid artery would probably be a well tolerated step during the neurosurgical operation that would follow [5].

Because of the enormous influence of anesthetic agents on brain functions, the method is only suitable for patients who do not undergo full anesthesia. The other two methods reported here concern biologic potentials not very much influenced by anesthesia.

Evoked Potential Techniques

The use of sensory-evoked potentials is widely recognized in various neurologic diseases like multiple sclerosis, tumors of the cerebellopontine angle, space-occupying lesions of the posterior fossa, brainstem ischemia, and spinal lesions [6-7]. In recent years, reports have appeared on the application of evoked potential techniques in the operating room. Feinsod et al. [8] and Wilson [9] applied visual evoked potentials in monitoring intraorbital surgery or operations of pituitary adenomas. Brainstem acoustic-evoked potentials and somatosensory-evoked potentials were used in brainstem monitoring during neurosurgical operations in the posterior fossa or the spinal cord [10].

The measurement of evoked potentials is based on signal averaging techniques. Averaging leads to a signal enhancement in which the amplitude of the time-locked (stimulus-correlated) activity is enhanced relative to the random background activity of the

¹All authors: Department of Neurology, Neurophysiological and Neuroradiological Services, Klinikum der RWTH, Goethestrasse 27-29, D-5100 Aachen, West Germany. Address reprint requests to W. Hacke.

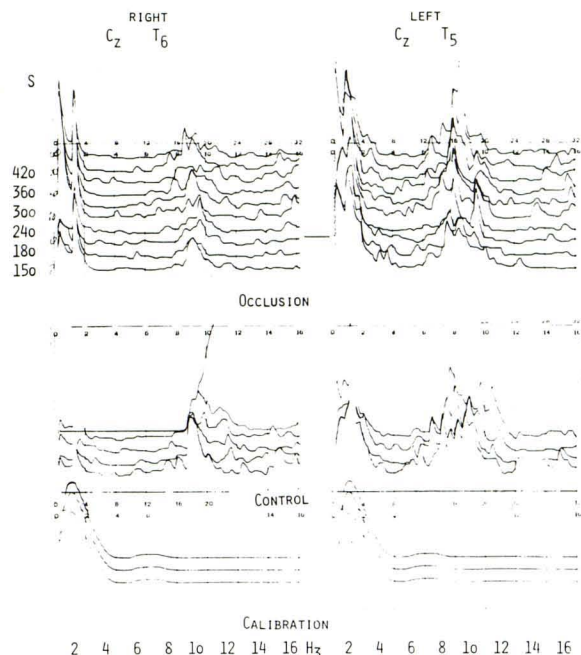


Fig. 1.—On-line Fourier-transformed EEG frequency analysis during reversible occlusion of left internal carotid artery.

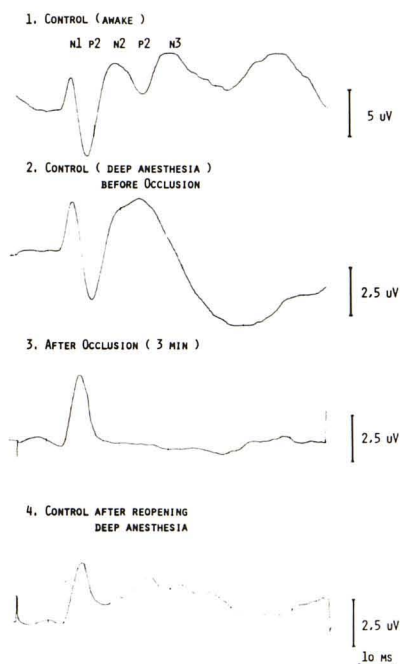


Fig. 2.—Monitor record of right median nerve somatosensory-evoked potential during reversible occlusion of left carotid artery (CzP₃). Note loss of late cortical components under anesthesia, single N20 peak 3 min after occlusion, and recovery of N35 when occlusion was discontinued.

conventional EEG. The stimuli used can be visual, sensory, or acoustic.

Somatosensory-evoked potentials consist of submicrovolt components of short latency that reflect activity in spinal cord and brainstem pathways, and of high amplitude, long-latency components that reflect activity in thalamic and cortical structures. For

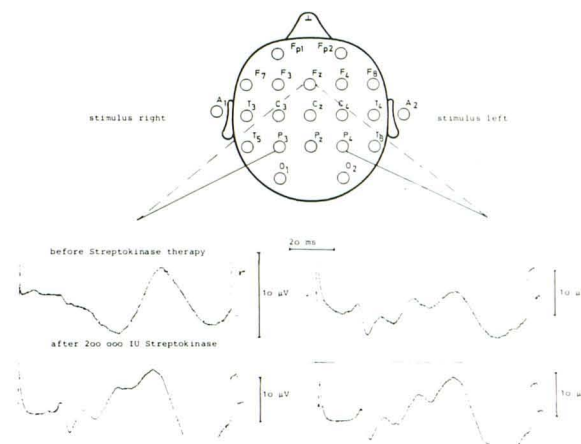


Fig. 3.—Median nerve somatosensory potential during intraarterial streptokinase therapy for basilar thrombosis.

example, stimulation of the median nerve typically elicits a negative component at 20 msec, a positive component at 25–30 msec, and subsequent negative and positive waves at 35 and 45 msec, respectively. The N20 element represents the thalamocortical bundle and the arrival of the afferent volley at the sensory cortex.

Figure 2 shows the somatosensory-evoked potential monitoring of the median nerve during reversible occlusion of the internal carotid artery in a patient with a fistula of the cavernous sinus. The somatosensory-evoked potential of the contralateral median nerve was recorded before anesthesia. The patient was then fully anesthetized and a control conducted before occlusion. This control showed that the waves N20 and P25 remained stable, while the other cortical components slowed. The continuous monitoring of the somatosensory-evoked potentials during the occlusion showed the P25 component (representing the primary cortical response to the stimulus) vanished after 3 min. At this point occlusion was immediately halted. The somatosensory-evoked potentials recovered within seconds.

The median nerve somatosensory-evoked potential can also be used in monitoring brainstem functions. With minor changes in electrode positions and filters, it is possible to record subcortical components of the evoked potentials, the so-called short latency somatosensory-evoked potentials. Because these potentials are more vulnerable and influenced by biologic and technical artifacts, we use the three early elements of the conventional cortical somatosensory-evoked potentials for brainstem monitoring, too.

Figure 3 shows the changes of the initially pathologic median nerve somatosensory-evoked potential in a patient with thrombosis of the basilar artery before and after successful selective thrombolytic therapy [11]. At the time therapy was started no early elements of the right potentials could be detected. After the reopening of the thrombosis a normal somatosensory-evoked potential was recorded.

Brainstem acoustic-evoked potentials consist of a series of five to seven components of less than 1 μ V amplitude, thought to originate from sequential activation of the elements of the auditory pathway in the brainstem. The brainstem acoustic-evoked potentials are elicited by monaural clicks and recorded with needle electrodes (Cz–Mst). In order to receive technically satisfactory potentials we use 2,500 trials for averaging (filters 100–3,000 Hz). By using a certain "overlapping" technique a new acoustic potential is realized every 4 min. All potentials are registered. The interpeak latency between element II and element V represents brainstem transmission time, which can also be measured continuously.

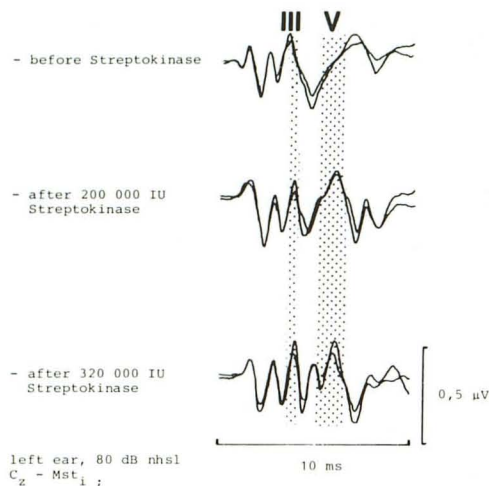


Fig. 4.—Brainstem acoustic-evoked potential monitor record during local, intraarterial streptokinase therapy for basilar thrombosis.

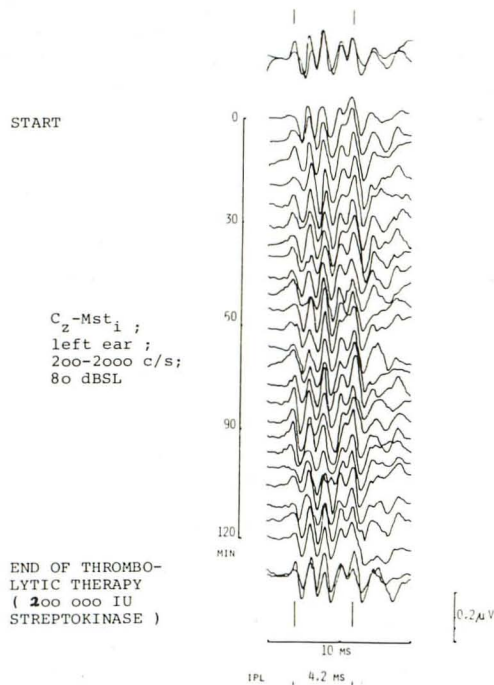


Fig. 5.—Brainstem acoustic-evoked potential monitor record during streptokinase therapy of thrombosis of vertebral artery.

Figure 4 shows six average recordings during thrombolysis of a patient suffering from thrombosis of the basilar artery. The potential initially indicated a mild desynchronization of the impulse transmission in the central acoustic pathways. During the therapy the recovery of the acoustic brainstem potentials was demonstrated. The monitoring of the brainstem acoustic-evoked potentials during the thrombolysis provided continuous information about the increasing synchronization of the propagation of impulses in the acoustic pathways. It also would have permitted an early recognition of a

possible deterioration during the neuroradiologic treatment (e.g., brainstem hemorrhage).

In two other patients we monitored brainstem acoustic- and somatosensory-evoked potentials during a selective thrombolysis of the vertebrobasilar system. In the first case no alterations of the acoustic potential were recorded at the beginning of the therapy, and there were no changes in the brainstem acoustic-evoked potential during the effective thrombolysis of a large thrombus located in the intradural part of the right vertebral artery (fig. 5). In the other patient (who presented with an old bilateral vertebral occlusion) at the beginning of the therapy we found only a very small wave I, indicating a severe diffuse brainstem dysfunction. No cortical somatosensory-evoked potentials could be recorded. No changes occurred in the evoked potentials during the therapy, nor was there any reopening of the vertebral artery.

Conclusions

Neurophysiologic monitoring can serve as a control function during interventional neuroradiology because the almost instant information it provides about a patient's condition can indicate when a diagnostic or therapeutic procedure should be interrupted. It also gives early indications of the success of the therapy, and reliable information about the stability of a patient's hemispheric or brainstem functions while interventional neuroradiology is still going on.

REFERENCES

1. Serebrenko FA. Balloon catheterization and occlusion of major cerebral vessels. *J Neurosurg* 1974;41:125-145
2. Wise BL, Boldrey E, Aird RB. The value of electroencephalography in studying the effect of ligation of the carotid arteries. *Electroencephalogr Clin Neurophysiol* 1974;40:261-268
3. Miller JD, Jawad K, Janner B. Safety of carotid ligation and its role in the management of intracranial aneurysms. *J Neurol Neurosurg Psychiatry* 1977;40:64-72
4. Chiappa KH, Burke SR, Young RR. Results of electroencephalographic monitoring during 367 carotid endarterectomies. *Stroke* 1979;10:381-388
5. Hacke W, Zeumer H, Ringelstein EB. EEG controlled occlusion of the internal carotid artery. *Neuroradiology* 1981;22:19-22
6. Stockard JJ, Stockard JE, Sharbrough HF. Brainstem auditory evoked potentials in neurology: methodology, interpretation, clinical application. In: Aminoff MJ, ed. *Electrodiagnosis in clinical neurology*. New York: Churchill-Livingstone, 1980:370-414
7. Giblin DR. Scalp recorded somatosensory evoked potential. In: Aminoff MJ, ed. *Electrodiagnosis in clinical neurology*. New York: Churchill-Livingstone, 1980:414-451
8. Feinsod M, Selhorst JB, Hoyt WF, Wilson CB. Monitoring optic nerve function during craniotomy. *J Neurosurg* 1976;44:29-31
9. Wilson WB, Kirsch WM, Neville H, Stears SJ, Feinsod M, Lehmann RAW. Monitoring of visual function during parasellar surgery. *Surg Neurol* 1976;5:323-329
10. Grundy B, Bosten R, Procopio P, Doyle E, Nelson R, Agnes L. Evoked potential monitoring during neurosurgical operations. Presented at the annual meeting of the American Society of Anesthesiology, St. Louis, 1980
11. Zeumer H, Hacke W, Kolmann HL, Poeck K. Lokale Fibrinolysetherapie bei Basilarthrombose. *Dtsch Med Wochenschr* 1982;107:728-731