



Get Clarity On Generics

Cost-Effective CT & MRI Contrast Agents



FRESENIUS
KABI

WATCH VIDEO

AJNR

Cranial computed tomography in disorders of complex carbohydrate metabolism and related storage diseases.

B Ludwig, T Kishikawa, S Wende, M Rochel and J Gehler

AJNR Am J Neuroradiol 1983, 4 (3) 431-433

<http://www.ajnr.org/content/4/3/431>

This information is current as
of August 17, 2025.

Cranial Computed Tomography in Disorders of Complex Carbohydrate Metabolism and Related Storage Diseases

B. Ludwig,¹ T. Kishikawa,¹ S. Wende,¹ M. Rochel,² and J. Gehler²

Computed tomography (CT) was performed on 34 children with different disorders of complex carbohydrate metabolism and related storage diseases to obtain data on the degree of cerebral involvement. The main findings on CT were cerebral atrophy and hypodensity of the white matter. There was a great variability in these CT findings, even in siblings. Among the patients there were several in whom CT was normal, so a negative study does not exclude one of these disorders. These findings show that CT features such as cerebral atrophy or hypodensity are helpful in the evaluation of these disorders, though a diagnosis cannot be made on the basis of CT alone.

Patients with inborn errors of metabolism have a great variation in phenotype and symptomatology, which often makes diagnosis difficult. Recent computed tomographic (CT) reports have shown inconsistent results with different CT findings in such patients [1–9]. To test the diagnostic, differential diagnostic, and prognostic significance of the CT findings, and to obtain data of the degree of cerebral involvement in metabolic disorders, we investigated children with disorders of complex carbohydrate metabolism and related storage diseases.

Subjects and Methods

We examined 34 children with definite inborn errors by CT. Included in the series were 17 cases of mucopolysaccharidosis, two cases of oligosaccharidosis, three of mucopolipidosis, nine of sphingolipidosis, and three of neuronal ceroid lipofuscinosis. In patients with defined enzyme defects the diagnoses were established biochemically. In patients suffering from neuronal ceroid lipofuscinosis, the diagnoses were verified histologically.

Clinical Description and Results

Mucopolysaccharidoses

The mucopolysaccharidoses are divided into six distinct entities and several subtypes based on biochemical, clinical, and genetic aspects [10]. The clinical symptomatology is due to the intralysosomal storage of glycosaminoglycans caused by the deficiency of a single lysosomal enzyme. Typical clinical features are dwarfism, organomegaly, joint contractures, thickened skin, skeletal abnormalities, and moderate to severe mental retardation. The involve-

ment of neuronal tissue leads to progressive intellectual damage in most types. Recent investigations have shown a remarkable phenotypic variation even in those types that result from the same enzyme defect. On the other hand, clinically indistinguishable phenotypes originate from different enzyme defects, as seen in mucopolysaccharidosis III. Except for mucopolysaccharidosis II, the mode of inheritance is autosomal recessive [10–12].

There are other significant differences among the mucopolysaccharidoses that are obvious on CT [9]. These CT findings are partly (but not in every case) caused by the different ages of the patients or by different manifestations of the disease. Dilatation of the ventricles and of the subarachnoid spaces can occur. These findings become more distinct with increasing age. A density decrease of the white matter is possible in types IH, IIB, and VI. No disturbance of the blood-brain barrier is present. Therefore, no circumscribed enhancement after contrast injection is obvious on CT. Watts et al. [9] confirmed a normal blood-brain barrier with the aid of xenon investigations.

The variability of CT findings in mucopolysaccharidoses was shown in two sisters with mucopolysaccharidosis VI (fig. 1). CT findings of other types of mucopolysaccharidosis are represented in figures 2 and 3.

Oligosaccharidoses and Mucopolipidoses

Some lysosomal storage disorders clinically resemble the sphingolipidoses and mucopolysaccharidoses. They formerly were designated as mucopolipidoses [13]. After better understanding of the underlying biochemical defects they have been classified as the oligosaccharidoses (or glycoproteinoses), and as the mucopolipidoses. In oligosaccharidoses one finds an elevated excretion of oligosaccharides in urine and a disturbance of glycoprotein catabolism; in mucopolipidoses the catabolism of glycosaminoglycans, glycoproteins, and glycolipids is impaired [14]. The clinical picture of oligosaccharidoses and mucopolipidoses results from the excessive and progressive intracellular accumulation of undegraded metabolites. Besides the typical symptoms like organomegaly, osteodysplasia, and dysmorphism, patients show a less or more pronounced mental deterioration. The inheritance is autosomal recessive.

Different CT changes can also be found in patients with oligosaccharidoses (mannosidosis, fucosidosis, aspartylglycosaminuria, sialidosis). In mannosidosis normal CT findings as well as dilatation of the subarachnoid spaces or density decrease of the white matter can occur. In fucosidosis, findings of a cortical and cerebellar

¹ Abteilung für Neuroradiologie, Universitäts-Kliniken, Langenbeckstrasse 1, D-6500 Mainz, West Germany. Address reprint requests to B. Ludwig.

² Kinderklinik der Universität, D-6500 Mainz, West Germany.

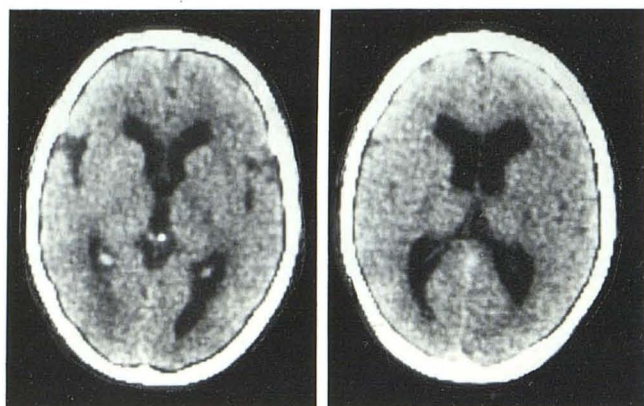


Fig. 1.—Mucopolysaccharidosis VI in 14-year-old girl. Enlargement of ventricles and sylvian fissures. Normal density of white matter. (Her 15-year-old sister had normal CT.)

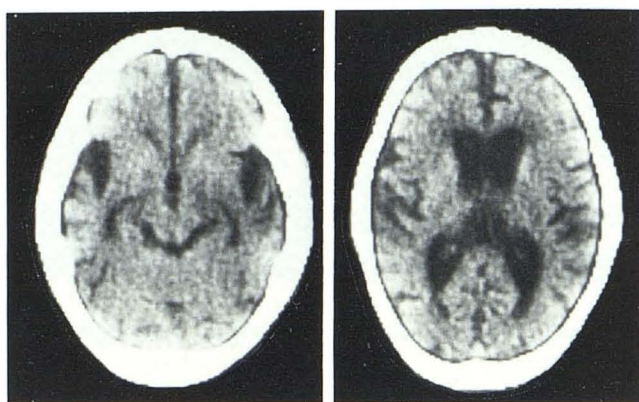


Fig. 3.—Mucopolysaccharidosis IIA in 8-year-old boy. Dilatation of ventricles, cisterns, and sylvian fissures. Normal density of white matter.

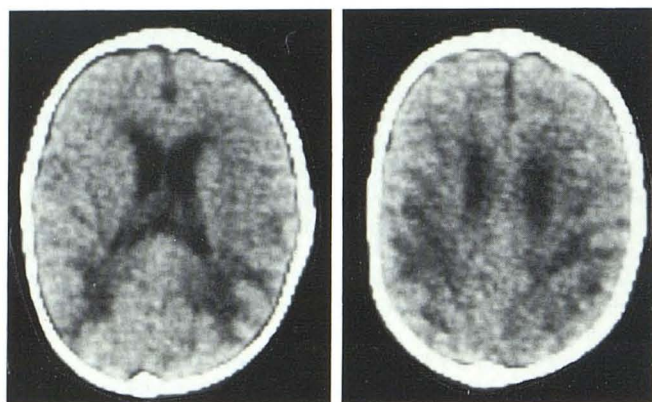


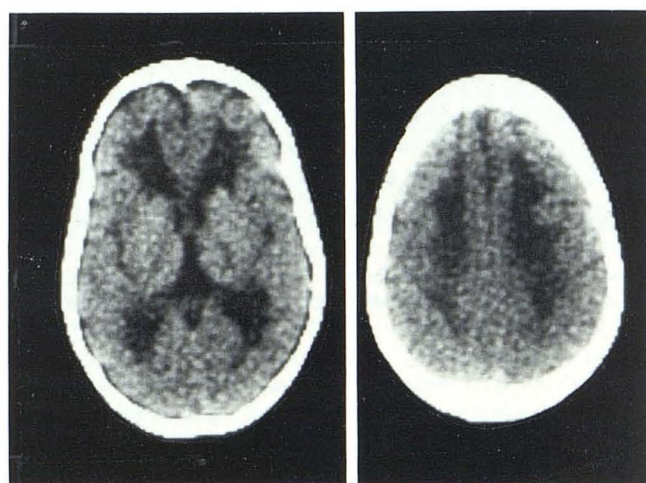
Fig. 2.—Mucopolysaccharidosis IH in 1-year-old boy. Dilatation of ventricles. Low density in parietal and occipital white matter.

atrophy with hypodense areas have been reported [6]. CT of patients suffering from aspartylglycosaminuria may be normal. In mucopolidoses, a moderate dilatation of the ventricles and subarachnoid spaces as well as a mild density decrease of the white matter were occasional findings on CT.

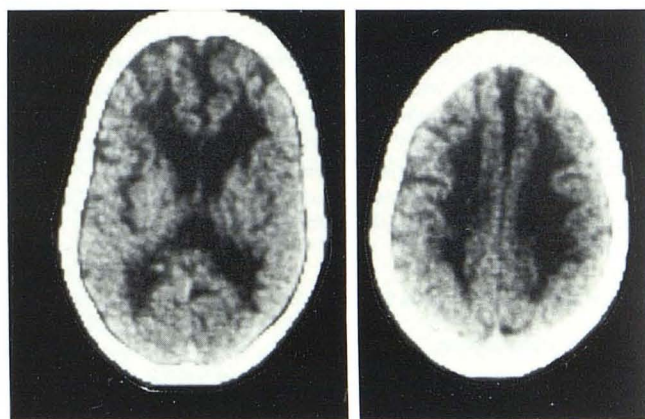Sphingolipidoses

Sphingolipidoses are inborn errors of lipid metabolism based on a lysosomal enzyme defect. In this group of disorders there is an abnormal intracellular accumulation of glycolipids, although the catabolism of glycosaminoglycans and glycolipids may be disturbed as well. Since glycolipids are essential in neuronal tissues, most of the patients develop a neurodegenerative symptomatology. Other leading symptoms are hepatosplenomegaly, ophthalmologic signs, and skeletal changes. There is a great clinical variability even within the same type of disorder. Except for the X-linked inherited Fabry disease (glycolipid lipidosis), the mode of inheritance is autosomal recessive [15].

In the group of sphingolipidoses, various CT findings are seen in metachromatic leukodystrophy. In this disease the ventricular system and the subarachnoid spaces may be quite normal, or there may be a significant dilatation of the ventricles and a distinct symmetrical density decrease of the white matter, especially in the



A



B

Fig. 4.—Metachromatic leukodystrophy in a girl. **A**, At age 10 years. Enlargement of ventricles. Low density in frontal and parietal white matter. **B**, At age 15 years. Distinct increase of changes.

frontal region. The CT changes are typical but not specific. Contrast enhancement does not occur [4].

In one of our female patients with metachromatic leukodystrophy, CT was performed at 10 and 15 years of age (fig. 4). Dilatation of

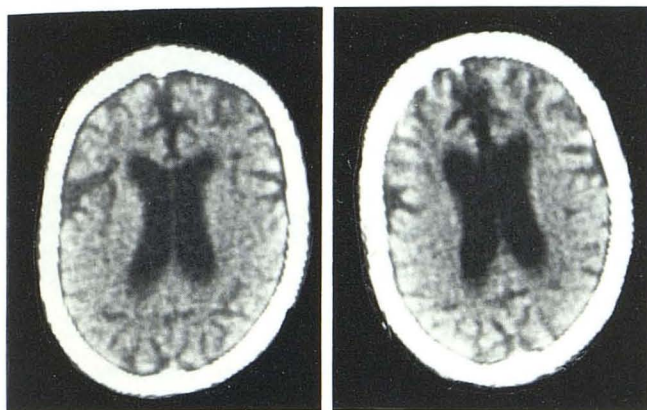

Fig. 5.— G_{M1} -gangliosidosis in a girl. A, At age 12 years. Dilatation of ventricles and subarachnoid spaces. No density changes of white matter. B, At 14 years. Increase of changes.

the cerebrospinal fluid spaces and an increasing white-matter hypodensity occurred as the child aged.

In G_{M1} -gangliosidosis, dilatation of the ventricles and subarachnoid spaces may be observed (fig. 5). In G_{M2} -gangliosidosis CT showed an atrophy of the brainstem and cortex, and also a hypodensity of the white matter. CT findings were normal for patients afflicted with Gaucher disease.

Neuronal Ceroid Lipofuscinoses

Neuronal ceroid lipofuscinoses represent a group of neurodegenerative disorders in which four subtypes are differentiated by the age of onset. All patients except those with the adult type develop seizures, myoclonic jerks, dementia, and visual failure. In the infantile types the course is rapidly progressive; in the juvenile and adult type the course is slower. The mode of inheritance is autosomal recessive, although a dominant inheritance is described in some adult patients. The basic biochemical defect is unknown. Diagnosis is proven by analysis of electron microscopy of rectal or sural nerve biopsy. The leading histopathologic features are accumulation of typical ceroid lipofuscin in neuronal cells. The analysis of other tissues such as lymphocytes or fibroblasts seems to be as valid.

CT findings in neuronal ceroid lipofuscinosis vary [5, 8]. The ventricular system and the subarachnoid spaces may be normal or dilated. In general, cerebral atrophy is obvious without any correlation between the grade and the age of the process. The white matter has a normal density.

Discussion

CT findings must be considered in light of the clinical context. The different CT findings overlap considerably, restricting the dif-

ferential diagnosis. The following conclusions can be made: (1) CT is an important diagnostic procedure in patients with suspected neurodegenerative diseases; (2) CT may alter the diagnostic workup of these patients, though a diagnosis cannot be made by CT alone; (3) CT follow-up may allow objective assessment of progression of the disease; and (4) if a definite biochemical diagnosis is not possible and a brain biopsy not available, CT may be contributory to the diagnosis.

REFERENCES

- Robertson WC Jr, Gomez MR, Reese DF, Okazaki H. Computerized tomography in demyelinating diseases of the young. *Neurology* (NY) 1977;27:838-842
- Boltshauser E, Spiess H, Isler W. Computer tomography in neurodegenerative disorders in childhood. *Neuroradiology* 1978;16:41-44
- Lane B, Carrol BA, Pedley TA. Computerized cranial tomography in cerebral diseases of white matter. *Neurology* (NY) 1978;28:534-544
- Heinz ER, Drayer BP, Haenggeli CA, Painter MJ, Grumrine P. Computed tomography in white matter disease. *Radiology* 1979;130:371-378
- Valavanis A, Friede RI, Schubiger O, Hayek J. Computed tomography in neuronal ceroid lipofuscinosis. *Neuroradiology* 1980;19:35-38
- Kessler RM, Altmann DH, Martin-Jimenez R. Cranial CT in fucosidosis. *AJNR* 1981;2:591-592
- Kingsley DPE, Kendall BE. Demyelinating and neuro-degenerative disease in childhood. CT appearances and their differential diagnosis. *J Neuroradiol* 1981;8:243-255
- Lagenstein I, Schwendemann G, Kuehne D, et al. Neuronal ceroid lipofuscinosis: CCT findings in fourteen patients. *Acta Paediatr Scand* 1981;70:857-860
- Watts RWE, Spellacy E, Kendall BE, Du Boulay G, Gibbs DA. Computed tomography studies on patients with mucopolysaccharidoses. *Neuroradiology* 1981;21:9-23
- McKusick VA. Genetic heterogeneity and allelic variation in the mucopolysaccharidoses. *Johns Hopkins Med J* 1980;146:71-79
- Spranger J. The systemic mucopolysaccharidoses. *Ergebn Inn Med Kinderheilkd* 1972;32:165-265
- Cantz M, Gehler J. The mucopolysaccharidoses: inborn errors of glycosaminoglycan catabolism. *Hum Genet* 1976;32:233-255
- Spranger JW, Wiedemann HR. The genetic mucopolipidosis: diagnosis and differential-diagnosis. *Hum Genet* 1970;9:113-139
- Galjaard H. Diagnosis of mucopolipidoses. In: Galjaard H, ed. *Genetic metabolic diseases*. Amsterdam: Elsevier/North Holland Biochemical, 1980:132-165
- Galjaard H. Inborn errors of lipid metabolism. In: Galjaard H, ed. *Genetic metabolic diseases*. Amsterdam: Elsevier/North Holland Biochemical, 1980:166-302