



Get Clarity On Generics

Cost-Effective CT & MRI Contrast Agents

 FRESENIUS
KABI

WATCH VIDEO

AJNR

Single-photon tomographic determination of regional cerebral blood flow in epilepsy.

F J Bonte, M D Devous, Sr, E M Stokely and R W Homan

AJNR Am J Neuroradiol 1983, 4 (3) 544-546

<http://www.ajnr.org/content/4/3/544>

This information is current as
of August 13, 2025.

Single-Photon Tomographic Determination of Regional Cerebral Blood Flow in Epilepsy

Frederick J. Bonte,¹ Michael D. Devous, Sr.,¹ Ernest M. Stokely,¹ and Richard W. Homan²

Using a single-photon emission computed tomographic scanner (SPECT) the authors determined regional cerebral blood flow (rCBF) with inhaled xenon-133, a noninvasive procedure. Studies were performed in 40 normal individuals, and these were compared with rCBF determinations in 51 patients with seizure disorders. Although positive results were obtained in 15 of 16 patients with mass lesions, the group of principal interest comprised 25 patients suffering from "temporal lobe" epilepsy. Only one of these had a positive x-ray computed tomogram, but 16 had positive findings on rCBF study. These findings included increased local blood flow in the ictal state and reduced flow interictally.

The diffusible indicator method of Kety and Schmidt [1] for measuring cerebral blood flow was rapidly adapted to the use of radioisotopes of the noble gases. Ingvar [2] and Lassen et al. [3, 4] developed increasingly sophisticated scintillation detectors for the measurement of regional cerebral blood flow (rCBF), but they realized that observations made with single-plane detectors were necessarily limited to brain surface flow values. Therefore, Lassen and colleagues decided to construct a device that would provide three-dimensional representation of rCBF, and, working with Stokely et al. [5], they designed a single-photon emission computed tomograph (SPECT) capable of deriving and displaying rCBF. They began clinical studies, which have been reported in part by Lassen et al. [6]. Using a similar instrument (Medimatic A/S, Copenhagen) we also began a program of evaluation of SPECT determination of rCBF in various brain diseases [7]. The following is a preliminary report on our use of this procedure in the seizure disorders.

Materials and Methods

The SPECT detector was described in detail by Stokely et al. [5]. Briefly, it consists of four scintillation detectors in a square configuration mounted on a wheel that rotates about the subject's head at 6 rpm. Special collimators define three transverse tomographic sections on 4 cm centers. The subject rebreathes ¹³³Xe in air for 1 min, and air alone during a 3 min washout period. A small laboratory computer is used to translate detected events into cross-sectional images by a filtered back-projection method, and rCBF is then calculated within each pixel by the method of Kanno and Lassen [8]. Blood flow is displayed quantitatively in a 16 shade color scale (see figs. 1-4).

Control studies have been carried out on 40 normal volunteer subjects (ages 18-59 years) who were examined in the resting state. An illustrative cross-section at 6 cm above, and parallel to the canthomeatal line, from a 40-year-old normal volunteer is seen in figure 1.

We also studied 51 patients (ages 18-65) who were known to have seizure disorders. Their rCBF test results are summarized in table 1. All patients and all normal volunteer subjects gave informed consent to the procedure. We will illustrate our experience with the following examples.

Figure 2 represents a section 6 cm above the canthomeatal line in a 24-year-old man who had suffered an increasing number of complex partial seizures. Electroencephalography (EEG) had demonstrated a seizure focus in his anterior right temporal region. CT was negative. During his first examination (fig. 2, left), the patient had a seizure of 1 min duration, followed by amnesia for the entire 4 min examination. He returned 5 months later and an interictal study (fig. 2, right) was performed.

Figure 3 represents sections 6 cm above the CML from two studies of a 36-year-old man with a history of complex partial seizures, which were only moderately well controlled by medication. EEG had demonstrated a seizure focus in the anterior left temporal region. CT was negative. Figure 3A, left, was made during a brief complex partial seizure, while figure 3B, right, had been made at an earlier time when the patient's seizures were under relatively good control with medication.

Figure 4 is the rCBF study of a 24-year-old woman who had suffered seizures intermittently since the age of 2 years.

Results

Figure 1 shows the SPECT rCBF study of a normal volunteer subject. Patient data and an orientation symbol are seen at the left. Note that the presentation of the rCBF studies (subject's left to reader's left) is the reverse of x-ray CT scans, and is inherent in the software of SPECT.

On the right is a 16 color quantitative scale in which low flow values are rendered in blue and the highest in red and white. In the periphery of the section low flows are seen in the skin, scalp, and skull. Highest values are seen in the cortical gray matter ring, in which the highest flow is often seen in the visual cortex, as in figure 1. Immediately within the gray matter ring is a ring of lower flows in white matter. In some subjects relatively high flow may also be seen in central gray matter.

This work was supported in part by National Institutes of Health grant HL 29577 and grants from the Southwestern Medical Foundation and Biological Humanities Foundation.

¹Department of Radiology, and Nuclear Medicine Center, University of Texas Health Science Center, 5323 Harry Hines Blvd., Dallas, TX 75235. Address reprint requests to F. J. Bonte.

²Department of Neurology, University of Texas Health Science Center, Dallas, TX 75235.

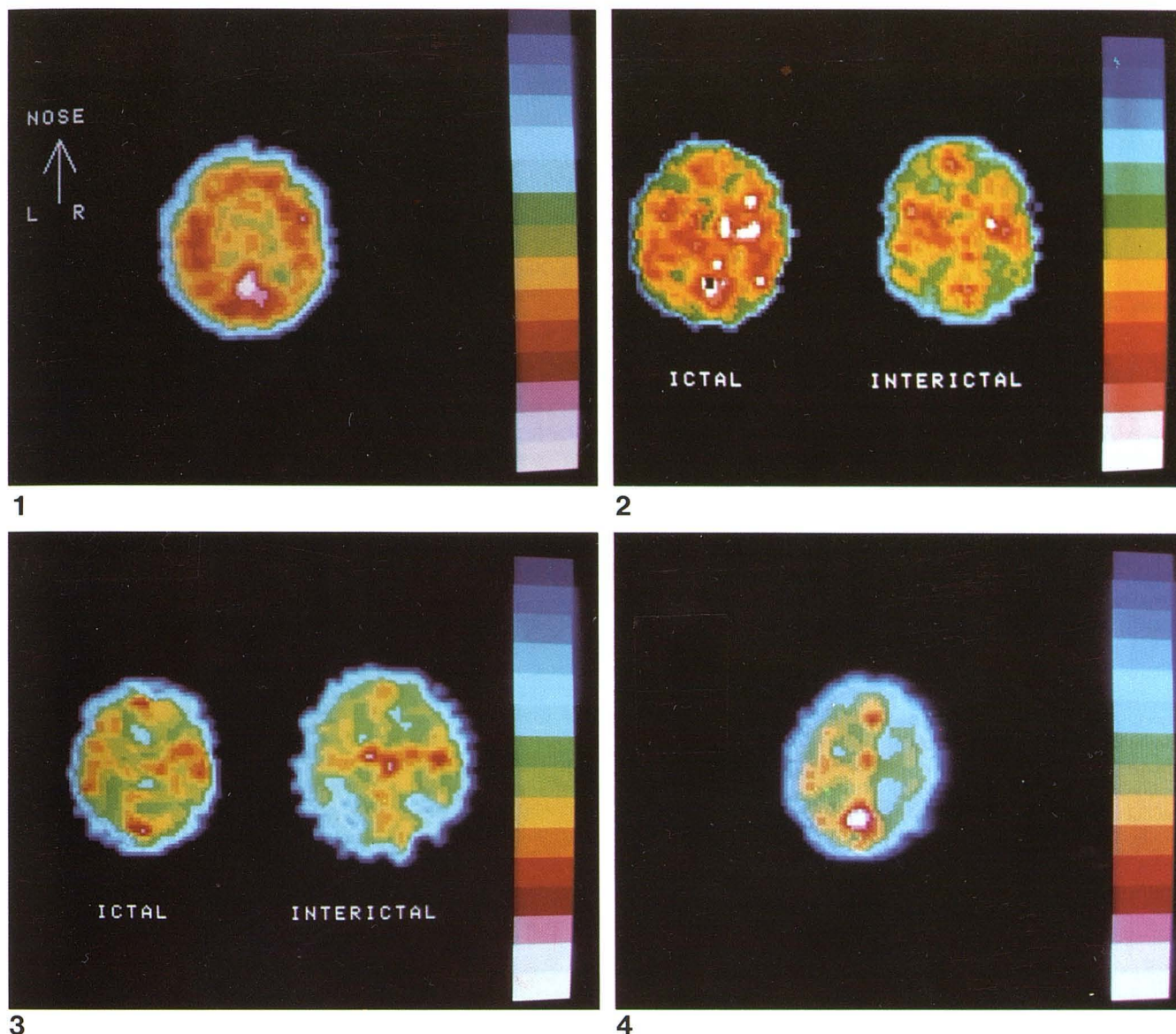


Fig. 1.—SPECT rCBF study of normal, 40-year-old volunteer. (Orientation on left applies to figs. 2–4 also.)
 Fig. 2.—SPECT rCBF study of 24-year-old patient. *Left*, during complex partial seizure. *Right*, 4 months later during interictal state.
 Fig. 3.—36-year-old patient. *Left*, during complex partial seizure. *Right*, interictal study at an earlier time.
 Fig. 4.—Interictal study of 24-year-old woman with history of seizure disorder since age 2 years.

TABLE 1: Results in Patients with Seizure Disorders

Seizure Etiology	No. Patients (n = 51)		
	Positive Scan	Negative Scan	Totals
Organic lesion	15	1	16
Trauma	2	8	10
"Temporal lobe" epilepsy	16	9	25

Studies in 51 patients with seizure disorders of various kinds are summarized in table 1. Note that in 16 of the 51 patients an organic cause was identified for the patient's seizure disorder. In 15 of these 16, abnormal rCBF studies and CT scans were obtained. Ten

of the 51 patients had a history of head injuries of sufficient severity to have caused loss of consciousness. Neither SPECT rCBF studies (two of 10 positive) nor CT scans (three of 10 positive) made a significant contribution in this group. Of principal interest are the 25 patients with "temporal lobe" epilepsy, of whom 16 had positive rCBF studies and nine had negative studies. Of this group only one patient had a positive CT scan. Findings in the temporal lobe epilepsy group are illustrated by the cases in figures 2–4.

Figure 2, left, shows a cluster of elevated flows in the anterior right temporal region at the site of EEG seizure focus localization. High flows are also seen in the right posterior temporal lobe and in the visual cortex, although the subject's eyes were closed during and after his seizure. An interictal study (fig. 2, right) shows a residual of the previously noted high flows in the right anterior

temporal region, but rCBF values are reduced in the posterior temporal region and in the principal seizure focus. Flow in the visual cortex is at a more normal level.

Figure 3, left, is a study made during a brief complex partial seizure and shows a pattern essentially normal in its distribution. In figure 3, right, a study made while the patient was in the interictal state, large areas of reduced flow are seen in both temporal and the right frontal regions. Flow has decreased in the left anterior temporal region, the site of EEG localization of this patient's seizure focus.

Figure 4 is the interictal study of a young woman with a life-long history of epilepsy. It shows reduction of flow throughout almost the entirety of the right hemisphere.

Discussion

It has been shown by investigators such as Ingvar [2], Plum et al. [9], and others that cerebral blood flow abnormalities are present in the seizure disorders. Localized high flow has been observed in the ictal seizure center, while in the interictal state less than normal regional blood flows have been identified in volumes as small as the seizure center and as large as a whole hemisphere. Using noninvasive ^{133}Xe inhalation SPECT study of rCBF we have demonstrated all of these various findings in a three-dimensional mode.

The enhanced flow to an ictal brain focus is shown in the case in figure 2, and probably in the case in figure 3 as well. Interictal locally reduced rCBF is illustrated by the case in figure 3, in which not only the presumed anterior left temporal seizure focus shows reduced flows, but additional volumes of each of the hemispheres as well. The case in figure 4 illustrates reduced flow throughout almost the entirety of a hemisphere.

Similar findings have been identified by Kuhl et al. [10] using positron tomographic evaluation of not only regional brain blood flow but regional brain glucose metabolism as well. Their findings have been of considerable value in assisting surgeons in the management of intractable epilepsy, and it is hoped that SPECT study of rCBF may in time become similarly effective. The next generation of SPECT instruments should see improved sensitivity and resolu-

tion, and radiopharmaceutical research should yield single-photon tracers capable of imaging not only blood flow but other physiologic functions as well.

REFERENCES

1. Kety SS, Schmidt CF. The nitrous oxide method for quantitative determination of cerebral blood flow in man: theory, procedure and normal values. *J Clin Invest* 1948;27:476-483
2. Ingvar DH. Regional cerebral blood flow in focal cortical epilepsy. *Stroke* 1973;4:359-360
3. Lassen NA, Ingvar D, Skinhoj E. Brain function and blood flow. *Sci Am* 1978;239:62-71
4. Sveinsdottir E, Larsen B, Rommer P, Lassen NA. A multidetector scintillation camera with 254 channels. *J Nucl Med* 1977;18:168-174
5. Stokely EM, Sveinsdottir E, Lassen NA, Rommer P. A single photon dynamic computer assisted tomograph (DCAT) for imaging brain function in multiple cross-sections. *J Comput Assist Tomogr* 1980;4:230-240
6. Lassen NA, Henriksen L, Paulson O. Regional cerebral blood flow in stroke by ^{133}Xe inhalation and emission tomography. *Stroke* 1981;12:284-288
7. Bonte FJ, Stokely EM. Single-photon tomographic study of regional cerebral blood flow in stroke. *J Nucl Med* 1981;22:1049-1053
8. Kanno I, Lassen NA. Two methods for calculating regional cerebral blood flow from emission computed tomography of inert gas concentrations. *J Comput Assist Tomogr* 1979;3:71-76
9. Plum F, Posner JB, Troy B. Cerebral metabolic and circulation responses to induced convulsions in animals. *Arch Neurol* 1968;18:1-13
10. Kuhl DE, Engel J, Phelps ME, et al. Epileptic patterns of local cerebral metabolism and perfusion in humans determined by emission computed tomography of ^{18}F FDG and $^{13}\text{NH}_3$. *Ann Neurol* 1980;8:348-360