



## Get Clarity On Generics

Cost-Effective CT & MRI Contrast Agents



FRESENIUS  
KABI

WATCH VIDEO

# AJNR

### **The use of $^{123}\text{I}$ -iodoamphetamine and single-photon emission computed tomography to assess local cerebral blood flow.**

D H O'Leary, T C Hill, R G Lee, M E Clouse and B L Holman

*AJNR Am J Neuroradiol* 1983, 4 (3) 547-549

<http://www.ajnr.org/content/4/3/547>

This information is current as  
of August 14, 2025.

# The Use of $^{123}\text{I}$ -Iodoamphetamine and Single-Photon Emission Computed Tomography to Assess Local Cerebral Blood Flow

Daniel H. O'Leary,<sup>1</sup> Thomas C. Hill,<sup>1</sup> Robert G. L. Lee,<sup>1</sup> Melvin E. Clouse,<sup>1</sup> and B. Leonard Holman<sup>2</sup>

N-Isopropyl  $^{123}\text{I}$  P-iodoamphetamine (IMP) is a radiopharmaceutical that is lipid-soluble, penetrates the normal blood-brain barrier, and has a high first-pass extraction efficiency in brain. Initial IMP distribution is proportional to local cerebral blood flow and is stable for at least 1 hr after administration. When combined with single-photon emission computed tomography (SPECT), regional activity can be quantified. Eighty-three studies were performed to aid in understanding the clinical utility of this radiotracer. In control subjects, brain activity followed expected regional perfusion patterns. Physiologic maneuvers produced altered perfusion patterns corresponding to those demonstrated by positron tomography. Perfusion abnormalities in stroke patients were visualized earlier than structural changes detected by transmission computed tomography (CT), and the area of altered IMP activity generally exceeded that suggested by standard CT examination. Seizure foci were identified by local abnormalities of cerebral blood flow. Primary brain tumors failed to demonstrate IMP activity even when shown by angiography to be highly vascular.

The ability to routinely measure local blood flow (LCBF) and cerebral metabolism should have an impact on the diagnosis and treatment of neurologic disorders. Quantitative physiologic measurements of cerebral blood flow, glucose metabolism, and oxygen utilization have already been achieved with techniques that employ positron isotopes [1-3]. While the employment of positron emission tomography has contributed markedly to our understanding of regional cerebral function, the high cost and difficulties associated with the production of the cyclotron-based isotopes have severely limited their clinical application and stimulated the search for other methods that would yield comparable information [4, 5].

In order to measure regional cerebral physiology using a single-photon isotope such as technetium-99m or iodine-123, the isotope would have to be attached to a carrier that can easily cross the normal as well as the abnormal blood-brain barrier, would have to have a high first-pass extraction fraction, and would have to remain trapped in the brain until imaging is completed. The ability of radiotracers to penetrate the normal blood-brain barrier appears to be directly related to their lipid solubility [6]. In 1980 Winchell et al. [7] first proposed that N-isopropyl  $^{123}\text{I}$  P-iodoamphetamine (IMP) could be used to evaluate regional cerebral perfusion in humans. Studies demonstrated that this lipid-soluble radiopharmaceutical

had a high first-pass extraction fraction in rat brain [6]. It was thought that IMP attached to high-capacity nonspecific central nervous system amine-binding sites. Kuhl et al. [8], employing arterial input measurements and tissue-sample counting, demonstrated good correlation between LCBF based on IMP and that based on microsphere injections in dog brains. In an attempt to understand the potential clinical utility of this radiotracer, we performed 83 clinical studies. Our published results suggest that regional activity of IMP can be quantified in normal and diseased brains using single-photon emission computed tomography (SPECT) to obtain information similar to that available with positron imaging [9].

## Materials and Methods

The instrument used in this study was the Harvard Scanning Multidetector Brain System, a single-photon machine that uses 12 sodium iodide detector units, all scanning in a rectilinear fashion within the same tomographic plane to obtain a single brain slice. Each detector consists of a focus collimator with the detectors moving in pairs, with the focal point of each detector set to scan half the field of view. The data generated from these detectors are processed by a Data General Eclipse computer and reconstructed by a back projection method to obtain a single image made up of a matrix of  $128 \times 128$  picture elements. Scanning time is 5 min for each slice, and slices at the same level may be summated to improve image quality. The sensitivity of the unit is 14,000 counts/ $\text{mCi}/\text{cm}^3$  and the spatial resolution is 10 mm full width at half maximum for  $^{99\text{m}}\text{Tc}$  [10]. This multidetector scanning system was originally designed by Stoddard and manufactured by Union Carbide as Cleon 710 prior to undergoing further modification at the Harvard Medical School [11].

The  $^{123}\text{I}$  radiolabel was produced by the  $\text{TE-124 (P, 2N)} \text{ }^{23}\text{MeV } ^{123}\text{I}$  reaction. This results in contamination with  $^{124}\text{I}$  of 2.1%–4.6% of the injected dose. Employing a technique described by Winchell et al. [7], the radiolabel was attached to IMP in California (Medipysics Laboratory). Patients received about 5 mCi (185 MBq) of IMP intravenously. Scanning was carried out during a period of 1–120 min after injection. In general, each patient was scanned at a point 2 cm above the canthomeatal line; however, this protocol was varied depending on the clinical area of interest.

In order to determine regional cerebral blood flow, specific re-

<sup>1</sup>Department of Radiology, Harvard Medical School, and New England Deaconess Hospital, 185 Pilgrim Road, Boston, MA 02215. Address reprint requests to D. H. O'Leary.

<sup>2</sup>Department of Radiology, Harvard Medical School, and Brigham and Women's Hospital, Boston, MA 02115.



gions of interest were identified and counts/min/mCi injected dose/100 g of brain ( $100 \text{ cm}^3$ ) were calculated and adjusted for such variables as number of slices obtained, dosage of  $^{123}\text{I}$ , and differences in the size of the region of interest. The mean slice count rate/mCi/100 g of brain tissue in nine normal patients was equated to normal cerebral blood flow of  $54 \text{ ml/min/100 g}$  [12]. Assuming linearity, this factor was used to calculate LCBF from regional count rates obtained from the tomographic images in the other patient studies.

A total of 72 patients was studied. Seven patients had two examinations and two had three, for a total of 83 studies. Clinical groupings included controls (21); stroke (19); transient ischemic episode (TIA) (seven); preendarterectomy (three); seizure (eight); brain tumor (five); hematoma (two); and other (seven). All patients had transmission computed tomographic (CT) scans near the time of their IMP studies.

## Results

In our 21 normal control patients, activity was greatest in the strip of cortex along the convexities of the frontal, temporal, and occipital

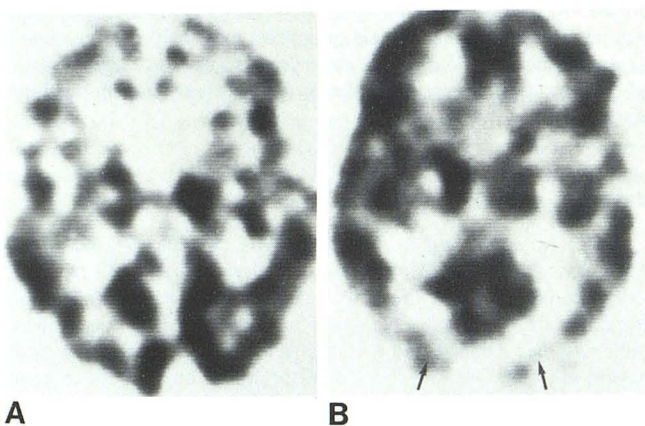


Fig. 1.—Control patient. **A**, Single-photon tomographic image 2 cm above canthomeatal line demonstrates high level of activity in cortical gray matter as well as basal ganglia and thalamus. Central white matter and ventricles show less activity, reflecting decreased flow. Resolution is high enough to demonstrate interhemispheric fissure and sulci. **B**, At 2 cm above canthomeatal line in patient with eyes closed. Decreased activity in occipital lobe corresponding to associative visual cortex (arrows).

lobes corresponding anatomically to the cortical gray matter. Infoldings corresponding to some surface sulci were identified, as were the interhemispheric and sylvian fissures. Activity was high in regions corresponding to the gray matter of the basal ganglia and thalamus, with lesser activity being present in the central white matter. Obvious alterations in regional blood flow with physiologic maneuvers were demonstrated after the intravenous injection of IMP. Patients injected with eyes closed showed a dramatic decrease in activity in their associated visual cortex when compared with patients injected with eyes open (fig. 1).

Of 19 stroke patients, 16 had positive and three negative IMP studies. In five of the positive studies, there was good correspondence between the extent of brain injury depicted by IMP and CT scans. Seven patients had abnormal IMP scans demonstrating areas of decreased perfusion and normal CT scans (fig. 2). Four patients had IMP studies that showed perfusion deficits larger than the abnormality seen on CT scans. Both studies were normal in two patients. One patient, studied 3 weeks after a presumed lacunar stroke, had a positive CT scan and a normal IMP study.

No distinct abnormalities were visualized on the IMP studies of those 10 patients studied after TIA or before carotid endarterectomy. One of the three preoperative patients was restudied shortly after endarterectomy and diminished perfusion was detected on the operative side. The patient was stable, and a third study done 4 weeks later showed normal perfusion.

Of the five patients with brain tumor, three demonstrated diminished IMP activity in the area of the tumor. All five had abnormal CT scans.

Only one of our seizure patients, studied at the time of actual seizure, had a positive scan with focally increased activity in a region corresponding to the area of electroencephalographic (EEG) abnormality (fig. 3). The other seven patients were studied interictally. Five had normal scans, and two demonstrated diminished focal activity in the region of the suspected brain abnormality. Two patients, one with hemiballismus and one with tremor, had increased activity in the appropriate motor regions.

## Discussion

Our clinical studies indicate that SPECT of IMP may have widespread clinical utility in the study of neurologic disease. The relatively long half-life of  $^{123}\text{I}$  (13 hr) removes one of the major constraints associated with the use of positron isotopes. This, combined with the fact that the equipment required for imaging is less costly than that associated with positron emission tomography, suggests that these studies will be feasible in the general hospital.

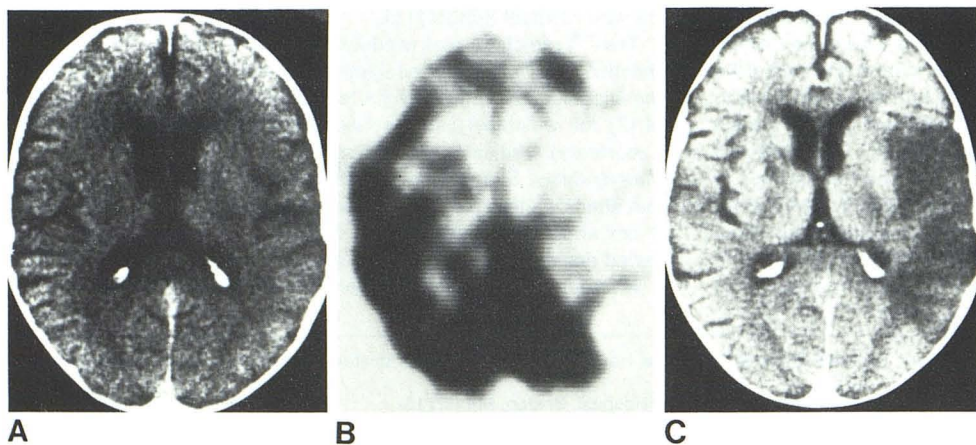


Fig. 2.—Stroke patient. **A**, Initial CT scan on day of acute onset of right hemiparesis shows no abnormality. **B**, SPECT-IMP scan at same level. Large area of decreased activity in left hemisphere in region of distribution of middle cerebral artery corresponds to clinical findings. **C**, CT scan 1 week later. Area of edema in left hemisphere in region of previously noted perfusion deficit on SPECT-IMP.



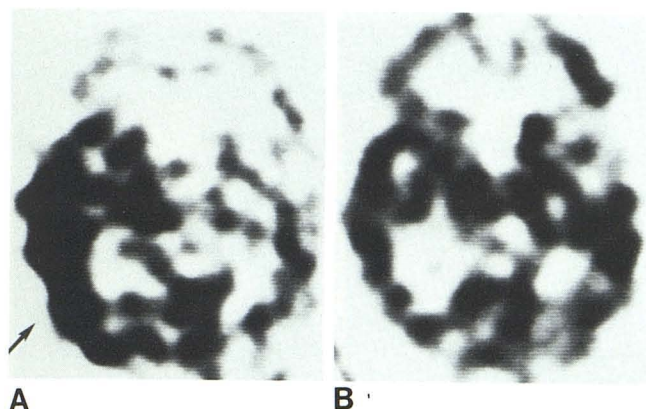


Fig. 3.—Seizure patient. **A**, SPECT-IMP at 2 cm above canthomeatal line. Increased activity in right temporal lobe (arrow) corresponds to temporal lobe seizure and abnormal EEG activity. **B**, After adequate medical therapy with Dilantin with cessation of seizure, SPECT-IMP scan is normal.

In normal brain, there is good correlation between regional metabolism and regional cerebral blood flow. The distribution of IMP reflects the flow of blood within brain tissue during the first few minutes after injection. An individual injected with eyes closed will demonstrate a reduced pattern of activity in the associated visual cortex even if he or she is later scanned while viewing a complex visual scene. This initial activity seems to be maintained for at least 1 hr.

The exact behavior of the radiotracer is incompletely understood. Perfusion abnormalities in stroke patients were visualized earlier than structural changes detected by transmission CT, and the area of altered IMP activity generally exceeded that suggested by standard CT examination. Ackerman et al. [13, 14] have demonstrated with positron tomography that oxygen metabolism and cerebral blood flow may be uncoupled after a stroke, and that the values of LCBF may not be as important as  $O_2$  metabolism as an indicator of tissue viability. We did not visualize either the luxury perfusion syndrome of Lassen [15] or delayed reactive hyperemia in any of our stroke cases, phenomena thought to represent nonnutritional blood flow. This may suggest that in damaged brain we are measuring the availability of binding sites in addition to cerebral blood flow, and thus possibly distinguishing between viable and nonviable tissue. Further studies will be needed to determine whether we are able to distinguish between varying degrees of tissue injury.

While tomography provides three-dimensional resolution and permits quantification of LCBF, this is not an absolute requirement for IMP studies. In all our abnormal stroke studies, the area of brain injury was clearly visualized on standard images with a scintillation camera, so this information would be readily available to assist in therapeutic decisions in the acute stroke patient [16].

IMP would also appear to play a role in the study of epilepsy, particularly in those patients being considered for surgery, where seizure activity is poorly controlled by medication. Because IMP studies are simple to perform and do not require much patient cooperation or complex external breathing or injection devices, it is relatively easy to study patients in an attempt to localize seizure foci. We have shown that IMP can identify a seizure focus by demonstrating increased regional blood flow in a specific portion of the brain by injecting material during a seizure or at a time when the patient's EEG is abnormal.

Thus we have demonstrated that SPECT of IMP permits early delineation of tissue injury in stroke patients, may identify the location and extent of seizure foci, provides quantitative data to

permit assessment of LCBF, and has the potential for widespread use in the study of neurologic disease.

## REFERENCES

1. Phelps ME, Mazziotta JC, Huang SC. Study of cerebral function with positron computed tomography. *J Cerebral Blood Flow Metab* **1982**;2:113-162
2. Ackerman RH, Alpert NM, Correa JA, et al. Clinical aspects of positron emission tomography (PET). *Radiol Clin North Am* **1982**;20:9-14
3. Mazziotta JC, Phelps ME, Miller J, Kuhl DE. Tomographic mapping of human cerebral metabolism: normal unstimulated state. *Neurology (NY)* **1982**;31:503-516
4. Lassen NA, Henriksen L, Paulson O. Regional cerebral blood flow in stroke by  $^{133}\text{Xe}$  inhalation and emission tomography. *Stroke* **1981**;12:284-288
5. Fazio F, Fieschi C, Collice M, et al. Tomographic assessment of cerebral perfusion using a single-photon emitter (krypton-81 mm) and a rotating gamma camera. *J Nucl Med* **1980**;21:1139-1145
6. Winchell HS, Baldwin RM, Lin TH. Development of  $I^{123}$  labeled amines for brain studies: localization of  $I^{123}$  iodoamphetamine in rat brain. *J Nucl Med* **1980**;21:940-946
7. Winchell HS, Horst WD, Braun L, Oldeudoof WH, Hattner R, Parker H. N-isopropyl  $I^{123}$ -p-iodoamphetamine: single-pass brain uptake and washout; binding to brain synaptosomes; and localization in dog and monkey brain. *J Nucl Med* **1980**;21:947-952
8. Kuhl DE, Barrio JR, Huang SC, et al. Quantifying local cerebral blood flow by N-isopropyl-p- $I^{123}$ -iodoamphetamine (IMP) tomography. *J Nucl Med* **1982**;23:196-203
9. Hill TC, Holman BL, Lovett R, et al. Initial experience with SPECT (single-photon computerized tomography) of the brain using N-isopropyl  $I^{123}$  p-iodoamphetamine. *J Nucl Med* **1982**;23:191-195
10. Zimmerman RE, Kirsch CM, Lovett R. Single photon emission computed tomography with short focal length detectors. Single photon emission computed tomography and other selected computer topics. In: *Proceedings of the 10th annual symposium, Society of Nuclear Medicine Computer Council, January 1980, Miami Beach, Florida*. New York: Society of Nuclear Medicine, **1980**;1:47-157
11. Stoddart HF, Stoddart HA. A new development in single gamma transaxial tomography: union carbide focused collimator scanner. *IEEE Trans Nucl Sci* **1979**;26:2710-2712
12. Patterson JL. Circulation through the brain. In: Ruchand TC, Patton HD, eds. *Physiology and biophysics*. Philadelphia: Saunders, **1966**:951
13. Ackerman RH, Alpert NM, Correa JA, et al. Importance of monitoring metabolic function in assessing the severity of a stroke insult (CBF: an epiphenomenon?). *J Cerebral Blood Flow Metab* **1981**;1:S502-S503
14. Ackerman RH. Positron imaging in stroke disease. In: Moosey J, Reinmuth OM, eds. *Cerebrovascular disease*. New York: Raven, **1981**:67-72
15. Lassen NA. The luxury perfusion syndrome and its possible relation to acute metabolic acidosis localized within the brain. *Lancet* **1966**;2:1113-1115
16. Lee RGL, Hill TC, Holman BL, Uren RF, Clouse ME. Comparison of N-isopropyl (1-123) p-iodoamphetamine brain scans using anger camera scintigraphy and single-photon emission tomography. *Radiology* **1982**;145:789-793