



Discover Generics

Cost-Effective CT & MRI Contrast Agents



[VIEW CATALOG](#)

AJNR

Double-blind study of effects of enkephalinase inhibitor on adverse reactions to myelography.

P Floras, A M Bidabé, J M Caillé, G Simonnet, J M Lecomte and M Sabathié

AJNR Am J Neuroradiol 1983, 4 (3) 653-655
<http://www.ajnr.org/content/4/3/653>

This information is current as of September 8, 2025.

Double-Blind Study of Effects of Enkephalinase Inhibitor on Adverse Reactions to Myelography

Pierre Floras,¹ Anne-Marie Bidabé,¹ Jean-Marie Caillé,¹ Guy Simonnet,² Jeanne-Marie Lecomte,³ and Michel Sabathié⁴

The side effects in myelography are well known and frequently observed. The most common are headache, nausea, and vomiting. In this study, a rather new compound, Thiorphan, was examined, which displays an antinociceptive activity by inhibiting enkephalinase activity. Forty-two patients received intravenous infusions of Thiorphan before myelography. Another 42 patients were in a control group, and Thiorphan was not administered. In the treated group, postmyelographic headache was found in 24% (versus 52% in the control group). Nausea and vomiting were never seen. Low back pain or sciatica was diminished in 33% of cases. Enkephalin levels in cerebrospinal fluid were measured by a radioreceptor-assay method in both groups without any correlation.

Side effects in myelography are well known and occur in about 50% of patients [1–5]. The most common are headache, nausea, and vomiting. Generally, analgesics have been ineffective in alleviating or preventing side effects. The major morphinomimetic analgesics are difficult to use because of possible respiratory depression or exacerbation of nausea and vomiting. In this study we used a new compound, Thiorphan (fig. 1), which has analgesic properties due to specific inhibition of enkephalinase activity, recently identified and responsible for the rapid destruction of enkephalins [6, 7]. In fact, since the discovery of enkephalins, the powerful activity of these endogenous morphines has been demonstrated [8–10]. However, because of their transient activity, they have never been applicable to therapy. Thiorphan, by its specificity, can take advantage of enkephalin activity to some extent.

Subjects and Methods

In our double-blind study, 84 patients requiring myelography were divided randomly into two groups of 42. There were 57 men and 27 women aged 18–77 years. Most were 25–51 years. Concurrent disease was not considered an eliminating factor. However, to make the groups somewhat homogenous, only patients over 18 years with normal psychoaffective behavior and not receiving any analgesic, antiinflammatory, or psychotropic drug were included. All patients were hospitalized under the same conditions. In 29 patients in the control group and in 31 treated patients, an algogenic lesion of variable intensity was identified in the sciatic or crural territory before myelography.

Before the study the patients were given a scale for evaluating the spontaneous pain they felt (table 1). The descriptions were simple and unambiguous. The observations related to headache, evolution of pain, nausea, and vomiting, and were noted every 15 min during the first hour, then every 30 min until the end of the second hour. The patients were rechecked at 4 and 8 hr as well as the next morning. Thus, the first 24 hr was covered.

During the 30 min before the study, 42 patients received an intravenous perfusion of 150 mg of Thiorphan diluted in 250 ml of isotonic glucose. In the 42 control patients, Thiorphan was not administered. In every patient in both groups, 10 ml of metrizamide, a water-soluble iodinated contrast medium, was injected by means of a lumbar puncture with a concentration of 170 mg I/ml, creating a solution that is isotonic with cerebrospinal fluid (CSF). The same type of small caliber (22 gauge) needle was used for all of the patients. Before injection of the contrast medium, a small quantity of CSF was withdrawn for the determination of enkephalin levels [11]. The position of the patient during and after the examination was carefully noted. During the study the head was kept raised and hyperextended to avoid diffusion of the product toward the brain. Likewise after the study patients remained in the sitting position for 8 hr. Statistical analysis was performed with analysis of variance and the Student *t* test.

Results

Postmyelographic Symptoms

Headache occurred in 22 patients (52%) in the control group versus 10 (24%) in the treated group. This finding is significant ($p < 0.02$). However, the headaches described were of an intensity equal or superior to level 2. Level 1 corresponds to annoyance more than true pain and was considered to be a more subjective symptom than a headache. The average delay of onset of headache was 3 hr (± 1.3) after lumbar puncture for the control group against 5 hr (± 3) for the treated group. The average duration of headache was 12 hr (± 6) for the control group versus 8 hr (± 3) for the treated group. These results are not significant. Nausea and vomiting were absent in the treated patients and present in 12% of the control group.

Evolution of Pain

After myelography only one diminution of pain was found in the control group versus 16 in the treated group ($p < 0.01$). In the

¹Department of Neuroradiology, Hôpital Pellegrin-Tripode, 33076 Bordeaux, France. Address reprint requests to P. Floras.

²National Institute of Health and Medical Research (INSERM U. 176), 33076 Bordeaux, France.

³Bio-Project, 30, rue des Francs Bourgeois, 75003 Paris, France.

⁴Department of Anesthesiology, Hôpital Pellegrin-Tripode, 33076 Bordeaux, France.

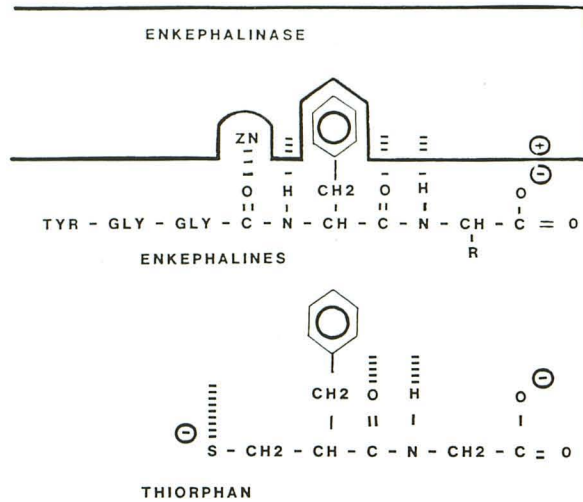


Fig. 1.—Hypothetic model of active site of enkephalinase and binding of enkephalins and Thiorphan.

TABLE 1: Postmyelographic Pain Scores

Grade: Type of Pain	Manifestation
5: Intolerable	Shouting, crying, moaning, psychomotor agitation
4: Significant	Immediate relief requested
3: Tolerable	Constant symptoms
2: Mild	Intermittent symptoms
1: Very mild	Annoyance
0: None	No annoyance

treated group, among the patients who had pain before the study, 16 of 31 were improved after an average delay of 3 hr (± 2.5) and improvement lasted about 16 hr (± 5). Recurrence of lumbar or sciatic pain was found in 16 patients in the control group and in three patients in the Thiorphan group. This aggravation lasted an average of 12 hr (± 6.1). A more detailed analysis of the 16 patients improved by Thiorphan shows that pain disappeared totally in only nine whose preceding pain level was 1 or 2. The other seven went from a high pain level of 3 or 4 to level 2. The three patients in the Thiorphan series who showed aggravation had radicular pain due to irritation of the nerve root by the lumbar puncture. In summary, in the Thiorphan series, only three patients attributed their pain to the study, 23 showed no change, and 16 were improved.

Side Effects of Thiorphan

Action on respiration, studied during the first 30 min of perfusion using an average dose of 2 mg/kg, proved to be insignificant on respiratory frequency and on tidal volume (table 2). Hemodynamic tolerance, as measured by arterial blood pressure and cardiac frequency, was excellent.

Determination of Enkephalin Levels in CSF

The determination of enkephalinlike substances in CSF, withdrawn at the time of the examination, proved to be very variable among patients; it was 18–487 ng/ml (mean, 254) in the control

group and 120–602 ng/ml (mean, 340) in the Thiorphan group. We noticed that even if the results were not significant, the lowest level was found in the control group and the highest level was found in the Thiorphan group. However, three lumbar punctures were done 3 hr after Thiorphan infusion and showed high endorphin levels: 430, 569, and 861 ng/ml.

Discussion

Among the most common complications observed in myelography, two categories of side effects can be distinguished: those directly related to lumbar puncture (headache, nausea, vomiting) and those related to the contrast medium (neurologic complications). Actually, it seems that postmyelographic headaches originate from three mechanisms: hydrodynamic disturbances of CSF caused by leakage at the puncture site; direct irritation by the contrast medium; and indirect vascular types [1, 12]. The contrast medium is detected in the blood as soon as 15 min after injection [13]. Nevertheless, in our series we observed no neurologic complications such as meningeal irritation, epileptic seizure, confusional episodes, or aphasia [2, 5], probably because of the precautions taken during and after the study [14]. As for headaches, the percentage in our control group coincides with those mentioned in literature [1, 3, 4]. The decrease of headache in the treated group is significant and seems to confirm the action of enkephalins in the pathogenesis of headaches. In fact, our current study (unpublished) demonstrates a therapeutic effect in migraines with corresponding low levels of MET-enkephalin in migraine patients (six cases) as compared with a control population (10 cases). The absence of nausea, vomiting, and respiratory depression seems to suggest, even though this is not yet established with certitude, that the morphinelike substances react essentially, if not exclusively, with the opiate receptor μ (μ), which is believed to be responsible for analgesic effects as well as typical side effects of morphinomimetics such as physical dependence, respiratory depression, and vomiting [15]. Enkephalins and related peptides react with delta receptors, of which little is known except that they intervene in the behavioral processes of pleasure [7]. The effects of Thiorphan on pain were predictable following the results of animal experimentation [6, 7]. However, it is perhaps better to speak of "hypalgesia" rather than analgesia since only nine patients experienced complete regression of initial pain from a preceding moderate pain level of 1 or 2. The seven patients who did not experience complete regression of pain belonged to a higher pain level (3 or 4). The improvement, however, was appreciated by the patients. All the patients clearly felt the pain of the lumbar puncture, which suggests that the enkephalins do not participate in the control of response to this type of stimulus. In fact, in the mouse tail withdrawal test, Thiorphan did not display an antinociceptive effect, while naloxone did not produce a pronociceptive effect. In contrast, in the hot-plate test (at 55°C) where naloxone produces hyperalgesia, Thiorphan clearly displayed an

TABLE 2: Respiratory and Hemodynamics Effect of Thiorphan during Intravenous Infusion

	Mean Time (\pm SEM)		
	0	15 min	30 min
Respiratory frequency (min)	16 (1.9)	16 (1.9)	18 (1.7)
Tidal volume (ml/min)	480 (112)	396 (130)	491 (185)
Mean arterial blood pressure (kPa)	18.1 (2.8)	17.8 (1.6)	18 (2.4)
Heart rate (beats/min)	68 (8.6)	72 (9.2)	67 (81)

antinociceptive activity [6]. This is reversed by naloxone, indicating that the opiate receptors are involved in this type of analgesia. Thus, by a modification of behavior, there is a modulating effect of enkephalins on pain perception.

Because of the absence of precise results in the literature, we are unable to draw any firm conclusions. The variability of levels of enkephalinlike substances in CSF of patients in the two series can be explained in different ways. There could be a response to each stimulus provoking secretion of enkephalins in certain situations: nociceptive stimuli, anxiety, stress as with neuromediators [9]. Enkephalin secretion probably varies with the time of day and with the individual, as do neurohormones [16]. Our method of determination by radioreceptor-assay which is less specific than radioimmunologic techniques in relation to one substance as MET-enkephalin, includes, on the other hand, global biologic activity of other enkephalinlike peptides [9, 17]. We also believe that the CSF sample was drawn too early in relation to the Thiorphan perfusion for the biologic effect to occur. It was the high frequency of side effects in myelography and their repercussions on the patients that led us to test this enkephalinase inhibitor. The potentials and limitations of Thiorphan still need to be determined.

REFERENCES

- Gelmers HJ. Adverse side effects of metrizamide in myelography. *Neuroradiology* **1979**;18:119-123
- Hauge O, Falkenberg H. Neuropsychologic reactions and other side effects after metrizamide myelography. *AJNR* **1982**;3:229-232
- Baker RA, Hilman BJ, McLennan JE, Strand RD, Kaufman SM. Sequelae of metrizamide myelography in 200 examinations. *AJR* **1978**;130:499-502
- Nogaki H, Fujiwara K, Tamaki N, Matsumoto S. Diagnostic values and adverse reactions of metrizamide in neuroradiology. *Neuroradiology* **1981**;22:52
- Carella A, Federico F, Di Cuonzo F, Vinjau E, Lamberti P. Adverse side effects of metrizamide and iopamidolo in myelography. *Neuroradiology* **1982**;22:247-249
- Roques BP, Fournie-Zaluski MC, Soroça E, Lecomte JM, Malfroy B, Llorens C. The enkephalinase inhibitor Thiorphan shows antinociceptive activity in mice. *Nature* **1980**;288:286-288
- Schwartz JC, Malfroy B, de la Baume S. Minireview: biological inactivation of enkephalins and the role of enkephalin-dipeptidyl-carboxy peptidase (enkephalinase) as neuropeptidase. *Life Sci* **1981**;29:1715-1732
- Hughes J, Smith TW, Kosterlitz HW, Fothergill A, Morgan BA, Morris HR. Identification of two related pentapeptides from the brain with potent opiate agonist activity. *Nature* **1975**;258:577-579
- Akil H, Richardson DE, Hughes J, et al. Enkephalin-like material elevated in ventricular cerebrospinal fluid of pain patients after analgetic focal stimulation. *Science* **1978**;201:463-465
- Frederickson RCA. Minireview—enkephalin pentapeptides: a review of current evidence for a physiological role in vertebrate neurotransmission. *Life Sci* **1977**;21:23-42
- Akil H, Watson SJ, Sullivan S, Barchas JD. Enkephalin-like material in human CSF: measurement and levels. *Life Sci* **1978**;23:121-126
- Picard L, Vespignani H, Vieux-Rochat P, et al. Complications neurologiques graves des myélographies au métrizamide. A propos de huit observations. *J Neuroradiol* **1979**;6:3-14
- Cherazi B, Virapongse C. Transient encephalopathy and asterix following metrizamide myelography. *J Neurosurg* **1981**;55:826-829
- Grainger RG, Kindall BE, Wylie IG. Lumbar myelography with metrizamide: a new non-ionic contrast medium. *Br J Radiol* **1976**;49:996-1003
- Wood PL. Multiple opiate receptors: support for unique mu, delta and kappa sites. *Neuropharmacology* **1982**;21:487-497
- Joyce EM, Koob GF, Strecker R, Iversen SD, Bloom FE. The behavioural effects of enkephalin analogues injected into the ventral tegmental area and globus pallidus. *Brain Research* **1981**;221:359-370
- Rossier J, Bayon A, Vargo TM, et al. Radio immunoassay of brain peptides: evaluation of a methodology for the assay of β -endorphin and enkephalin. *Life Sci* **1977**;21:847-852