



Get Clarity On Generics

Cost-Effective CT & MRI Contrast Agents



FRESENIUS
KABI

WATCH VIDEO

AJNR

Duplex sonography in the evaluation of carotid artery disease.

J N Dreisbach, C E Seibert, S F Smazal, A T Stavros and R J Daigle

AJNR Am J Neuroradiol 1983, 4 (3) 678-680

<http://www.ajnr.org/content/4/3/678>

This information is current as
of August 23, 2025.

Duplex Sonography in the Evaluation of Carotid Artery Disease

James N. Dreisbach,¹ Charles E. Seibert, Stanley F. Smazal, A. Thomas Stavros, and Robert J. Daigle

High-resolution duplex sonography was compared with biplane magnified carotid angiography in a prospective evaluation of 161 carotid arteries in 86 patients. The duplex scanner combined real-time B-mode imaging (7.5 MHz) with simultaneous range-gated pulsed Doppler frequency analysis (3 MHz). The degree of stenosis was usually determined by the true and residual lumen of the carotid artery at the atherosclerotic plaque on the transverse image. The Doppler frequency signals were automatically converted to velocity data by a minicomputer. The accuracy of the duplex system in detecting and assessing stenoses graded in 20% increments is demonstrated according to specificity, sensitivity, and positive and negative predictive value by both cumulative and subgroup analyses. A 93.7% sensitivity was shown for minimal (0–20%) stenosis and 100% sensitivity for severe (>60%) stenosis. An apparent limitation of duplex sonography is the differentiation of a high-grade stenosis from occlusion (sensitivity, 82.6%; positive predictive value, 90.4%).

Traditionally, a series of direct and indirect noninvasive tests including ocular plethysmography, carotid phonoangiography, periorbital bidirectional Doppler sonography, and bidirectional direct Doppler sonography have been used to evaluate extracranial carotid artery disease. These techniques are sensitive to severely stenotic lesions (>60% stenosis) but insensitive to lesser degrees of stenosis [1–3]. Duplex sonography was developed in the 1970s to improve the detection and assessment of atherosclerotic disease and to distinguish between minimal, moderate, and severe stenosis. The rapid development of real-time high-resolution B-mode scanning (7.5–10 MHz) has provided the technical basis for the demonstration of all stages of atherosclerotic disease. When combined with Doppler spectral analysis, it permits grading of the various degrees of stenosis at or near the carotid artery bifurcation [4, 5]. The purpose of this study was to prospectively compare the accuracy of a new duplex scanner (Diasonics Peripheral Vascular System) with biplane magnified carotid angiography.

Subjects and Methods

The duplex scanner used for this study combines a 7.5 or 10 MHz real-time B-mode transducer with a 3 MHz pulsed range-gated Doppler transducer. The imaging field was 4–7 cm and the maximum Doppler depth of penetration was 5.5 cm. The Doppler range for accurate blood flow measurement is 11–300 cm/sec at a 45° angle. Our system uses a 16 bit microcomputer (LSI 11) with a digital scan converter having an image memory of 512 × 512 × 6

bits. Software capabilities include the calculation of degree (%) of stenosis, linear measurement, real-time spectral analysis of the velocity waveform by fast Fourier transformation, average velocity measurement at any point in the cardiac cycle, and velocity ratio calculation.

The duplex scanner was used over an 8 month period to evaluate 86 of 87 patients who also underwent biplane magnified carotid angiography. One patient studied by angiography could not be scanned with the duplex system because of body habitus. Fifteen percent of the 87 patients had definitive carotid-distribution transient ischemic accidents. The other patients had equivocal symptoms for carotid-distribution neurologic dysfunction, asymptomatic bruit, or were in a high-risk category undergoing major noncerebrovascular surgery.

The scan protocol comprised B-mode imaging in the transverse and sagittal planes. The diameters as determined by the true and residual lumen of the carotid artery at the point of maximum stenosis were measured on the transverse image (fig. 1). Sagittal B-mode images were examined and simultaneous Doppler spectral analysis was performed in this orientation. Data were recorded from the common carotid artery, the point of maximum stenosis, and the internal carotid artery (fig. 2). The degree of stenosis was categorized into subgroups: 0–20%, 21–40%, 41–60%, 61–99%, and occlusion. In about 20% of cases, reliable transverse measurements could not be obtained at the stenosis. In these cases, the degree of stenosis was graded on the basis of the Doppler spectral data and sagittal images. Mean velocities at peak systole were obtained from the common carotid artery (\bar{V}_{cca}) and from the point of maximum stenosis (\bar{V}_{st}) or the internal carotid artery immediately distal to the maximum stenosis (\bar{V}_{ica}). Ratios of $\bar{V}_{st}/\bar{V}_{cca}$ or $\bar{V}_{ica}/\bar{V}_{cca}$ were then calculated. Small plaques (less than one-third the diameter of the vessel) imaged on the sagittal view with $\bar{V}_{st}/\bar{V}_{cca}$ or $\bar{V}_{ica}/\bar{V}_{cca}$ ratios <1.8 were classified as 21–40% stenosis. Plaques with about 50% stenosis in the sagittal plane with a velocity ratio ($\bar{V}_{st}/\bar{V}_{cca}$) <1.8 were defined as 41–60% stenosis. Plaques with 50% or greater stenosis in the sagittal plane with a velocity ratio >1.8 were classified as greater than 60% stenosis. The velocity ratio concepts were based on the clinical report of Blackshear et al. [6]. Sagittal measurement criteria for stenosis were used only when adequate transverse measurements could not be obtained.

Results

Table 1 illustrates the accuracy of the duplex system according to specificity, sensitivity, and positive and negative predictive value

¹All authors: Department of Radiology, Swedish Medical Center, 501 E. Hampden Ave., Englewood, CO 80110. Address reprint requests to J. N. Dreisbach.

Fig. 1.—Transverse B-mode sonograms at bulb of left internal carotid artery. Linear measurements of (A) true lumen (0.91 cm) and (B) residual lumen (0.55 cm) at atherosclerotic plaque (arrow) determine degree of stenosis (45%–50%).

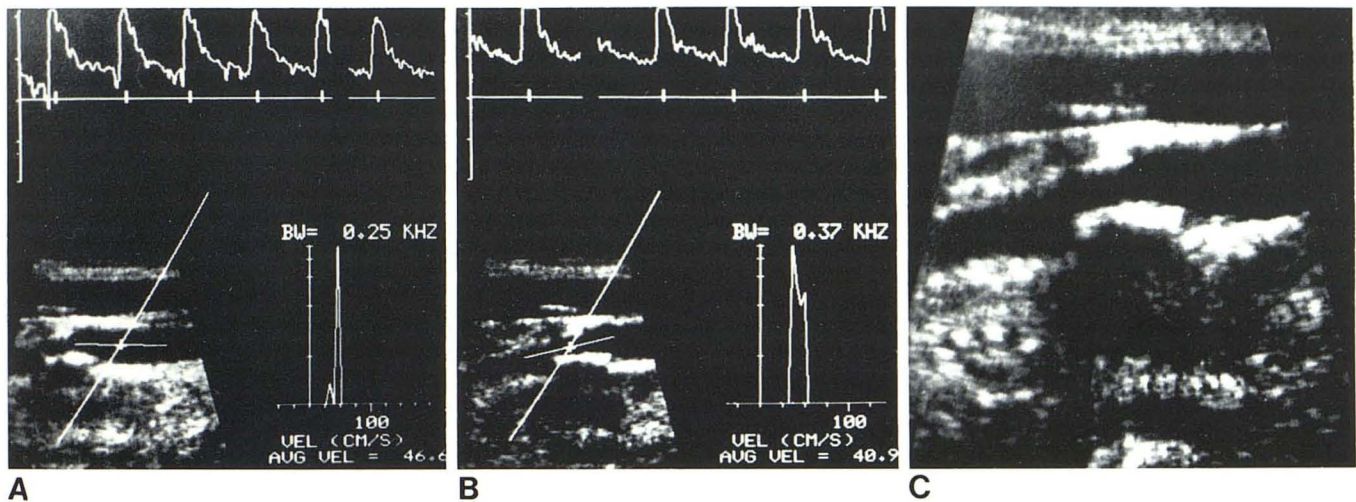
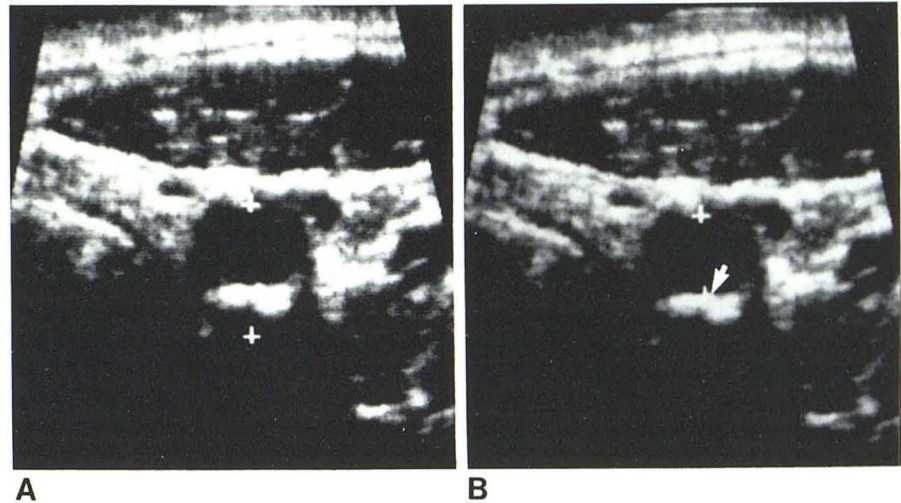


Fig. 2.—A and B, Sagittal mixed-mode display with real-time B-mode sonogram and simultaneous Doppler spectral analysis. Average velocity proximal to atherosclerotic plaque (A) is 46.6 cm/sec; velocity at point of

maximum stenosis (B) is 40.9 cm/sec, yielding $\bar{V}_{st}/\bar{V}_{cca}$ of 0.88. C, Sagittal B-mode image of atherosclerotic plaque and resulting stenosis.

TABLE 1: Accuracy of Duplex Sonography in the Detection and Assessment of Carotid Artery Disease

Type of Analysis: Degree of Stenosis (%)	Specificity (%)	Sensitivity (%)	Negative Predictive Value (%)	Positive Predictive Value (%)
Cumulative:				
>20	93.8	96.9	95.2	95.9
>40	98.0	93.1	96.2	96.4
>60	98.3	100.0	100.0	95.3
Occlusion	96.5	94.4	99.2	77.2
Subgroup:				
0–20	...	93.7	...	95.2
21–40	...	83.8	...	76.4
41–60	...	76.0	...	90.4
61–99	...	82.6	...	90.4
Occlusion	...	94.4	...	77.2

Note.—Analyses are based on a comparison of findings in 86 patients (161 carotid arteries) who underwent both duplex sonography and biplane magnified carotid angiography.

as determined by cumulative and subgroup analyses of the data [3, 7]. Duplex sonography was least sensitive for 21%–40% and 41%–60% stenotic lesions (83.8% and 76.0%, respectively). The examination had 93.7% sensitivity and 95.2% positive predictive value for 0–20% stenosis. The lowest sensitivity was obtained in the discrimination of high-grade stenosis from occlusion (sensitivity, 82.6%; positive predictive value, 90.4%). The duplex examination has 100% sensitivity and 95.3% positive predictive value for defining lesions with greater than a 60% stenosis.

Discussion

This duplex system proved to be highly sensitive with a high positive predictive value in patients with minimal or severe atherosclerotic disease at the carotid artery bifurcation. If the incidence of ulceration is truly low in normal-appearing vessels or vessels with small plaques, as reported by Eisenberg et al. [8], duplex sonog-

raphy alone could obviate more invasive studies of the carotid artery bifurcation in asymptomatic patients with carotid bruit, patients with equivocal carotid-distribution neurologic dysfunction, and patients with multiple risk factors [8, 9]. In addition, our study shows that patients with significant carotid artery disease (greater than 60% stenosis) can be identified with 100% sensitivity by duplex sonography. Further testing with either carotid angiography or digital subtraction angiography (DSA) can be performed if clinically indicated.

A major limitation of the duplex technique and possibly all sonographic systems is the inability to distinguish high-grade stenosis from occlusion. This limitation, which has also been reported by other investigators [5], is not solely instrument-dependent, but is related to the technologist's operative skill and the experience of the interpreter. In our study, three out of five false-positive diagnoses for occlusion were attributable to interpretive error. Another limitation was the decreased sensitivity of the system in the 21%–40% and 41%–60% stenosis groups. This may be explained in part by intraobserver error in measuring the degree of stenosis on angiography in the moderate stenosis range [5].

DSA may provide a new standard for noninvasive testing. In the future, a noninvasive testing method must offer a high sensitivity and specificity in grading various degrees of stenosis and a lower cost than either DSA or carotid angiography if it is to be effective and competitive. At our institution, noninvasive carotid testing costs are 40% of those for DSA and 25% of those for carotid biplane angiography. The duplex scanner can be used on patients with asymptomatic carotid artery bruit, patients with equivocal symptoms of carotid-distribution neurologic dysfunction, high-risk patients undergoing major surgery, and patients with transient ischemic accidents who are reluctant to submit to an invasive procedure [1]. Our data indicate that severe atherosclerotic lesions will be detected by duplex sonography and that patients with minimal disease will be accurately diagnosed with a high positive predictive value. At our institution, DSA and biplane carotid angiography are reserved for patients with transient ischemic accidents, reversible

ischemic neurologic deficits, and positive duplex sonographic scans (>60% stenosis), cases in which the intracranial vessels as well as the carotid bifurcations must be imaged in order to formulate definitive therapy.

Editor's Note: Interested readers are referred to another article on the same topic in a recent issue of *AJNR* [Blasberg DJ. Duplex sonography for carotid artery disease: an accurate technique. *AJNR* 1982;3:609–614].

REFERENCES

1. Ackerman RH. Noninvasive carotid evaluation. *Stroke* 1980;11:675–678
2. Ackerman RH. Perspective on noninvasive diagnosis of carotid disease. *Neurology* (NY) 1979;29:615–622
3. Sumner DS. Noninvasive methods for preoperative assessment of carotid occlusive disease. *Vasc Diagn Ther* 1981;2:41–56
4. Katz ML, Comerota AJ, Cranley JJ. Characterization of atherosclerotic plaques by real-time carotid imaging. *Bruit* 1982;6:17–22
5. Fells G, Phillips DJ, Chikos PM, Harley JD, Thiele BL, Strandness DE. Ultrasound duplex scanning for disease of the carotid artery. *Circulation* 1981;64:1191–1195
6. Blackshear WM, Phillips DJ, Chikos PM, Harley JD, Thiele BL, Strandness DE. Carotid artery velocity patterns in normal and stenotic vessels. *Stroke* 1980;11:67–71
7. McNeil B, Keeler E, Adelstein SJ. Primer on certain elements of medical decision making. *N Engl J Med* 1975;293:211–215
8. Eisenberg RL, Nemzek WR, Moore WS, Mani RL. Relationship of transient ischemic attacks of angiographically demonstrable lesions of carotid artery. *Stroke* 1977;8:483–486
9. Edwards JH, Kricheff II, Riles T, Imparato A. Angiographically undetected ulceration of the carotid bifurcation as a cause of embolic stroke. *Radiology* 1979;132:369–373