



Get Clarity On Generics

Cost-Effective CT & MRI Contrast Agents

**FRESENIUS
KABI**

[WATCH VIDEO](#)

AJNR

Stereotaxic lesion as a model of brain edema.

S E Cronqvist and G Kullberg

AJNR Am J Neuroradiol 1983, 4 (3) 722-724

<http://www.ajnr.org/content/4/3/722>

This information is current as
of August 24, 2025.

Stereotaxic Lesion as a Model of Brain Edema

Sten E. Cronqvist¹ and Gunvor Kullberg²

Repeated computed tomographic (CT) examinations after thalamotomy showed a lesion varying in size over time. This variation was interpreted as indicating presence of an edema. The effect of steroid treatment upon such an edema was tested in a pilot study of 28 patients, 16 of whom were given betamethasone. The diameter of the lesion as observed on CT was used as a measure of the amount of edema. The mean diameter was significantly lower in the steroid-treated group as compared with controls ($p < 0.01$, Mann-Whitney U test). The groups were comparable with respect to other variables that might influence lesion size. It is concluded that steroid treatment has an edema-preventing effect.

Computed tomographic (CT) changes in the appearance of a lesion after stereotactically performed radiofrequency coagulation vary according to the location of the lesion. After amygdalotomy, capsulotomy, or cingulotomy the lesion is often difficult to define, especially when CT scans in only the axial projection are available. Visualization is hindered somewhat by interference from neighboring anatomic structures, but the primary difficulty is that such lesions, when located in white matter, tend to be large, irregular, and poorly differentiated from the surrounding tissue. When the lesion is located in gray matter, as after thalamotomy, it is more easily observed and is generally well demarcated [1–5]. The characteristic thalamic lesion appears as a rounded area of decreased attenuation with a central core of higher density. However, as evidenced by repeated postoperative CT examinations [3], the lesion varies over time, both in appearance and in size (figs. 1 and 2). During the first few days up to a week after surgery, the rounded area increases in size; thereafter it slowly decreases in size and the central core gradually resolves. This change in size appears to reflect the development and resolution of an edema in and around the site of tissue destruction resulting from the operative procedure.

The regular existence of an edema and the fact that it changed according to a predictable pattern suggested that stereotaxic lesions in the thalamus could be used as a model for testing the effects of steroid treatment. The effect of glucocorticosteroids on edema secondary to acute brain damage has been subjected to many studies, both clinical and experimental. The results, however, have been contradictory. Since stereotaxic thalamotomy is performed with little technical variation in the procedure, differences in the appearance of the edema between patients who received steroid treatment and those who did not might be expected to provide further information.

Subjects and Methods

Thirty-one patients had one or more CT examinations within 12 days after thalamotomy. Three patients were excluded from the

study because CT showed an intracerebral hemorrhage in the vicinity of the lesion. None of these three had undergone steroid treatment. Of the other 28 patients, 16 were treated with steroids. The steroid-treated patients were 37–70 years of age (mean, 57 years). All were given betamethasone in doses of 16 mg/day for 5 days beginning on the day before surgery. Twelve patients had no steroid treatment and formed a control group. The untreated patients were 27–74 years of age (mean, 59 years). CT was performed one to four times after surgery. Thirty-five CT scans were available in the steroid-treated group and 25 in the control group. The time intervals between surgery and successive CT examinations were similarly distributed in the two groups.

The CT studies were performed on an EMI 1010 scanner using a slice thickness of 10 mm, high resolution, and an overlapping scanning technique. The amount of edema was expressed as the diameter of the area of decreased attenuation measured on the slice where this area was largest.

Results

Figure 3 shows a plot of the diameter of the low-density area against the time elapsed since surgery. The values are scattered over a wide range and there is considerable overlap of the two groups, although a tendency toward higher values in the control group could be discerned. However, when the data were averaged over consecutive time periods (fig. 4) a clear difference between the two groups emerged, the values from the control group being consistently somewhat higher than the values from the steroid group. The overall mean diameter in the control group was 11.8 mm (range, 7.9–18.0 mm); in the steroid group, 10.0 mm (range, 5.4–16.2 mm). Statistical analysis of the total set of data by the nonparametric Mann-Whitney U test revealed a significant difference between the two groups ($p < 0.01$).

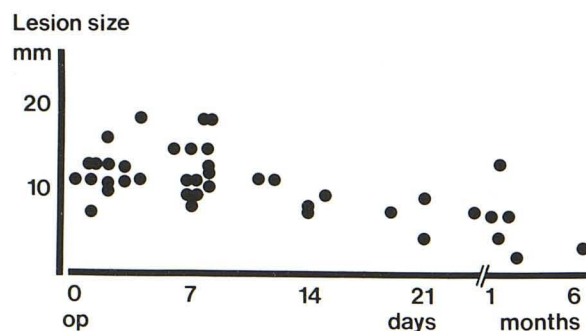


Fig. 1.—Size of thalamic lesion related to time elapsed since surgery.

¹Department of Neuroradiology, University Hospital, S-221 85 Lund, Sweden. Address reprint requests to S. E. Cronqvist.

²Department of Neurosurgery, University Hospital, S-221 85 Lund, Sweden.

Fig. 2.—Variation in size and CT appearance of thalamic lesion (arrow) over time. Top, left to right: 1, 3, and 7 days after surgery; bottom, left to right: 15, 24, and 50 days after surgery.

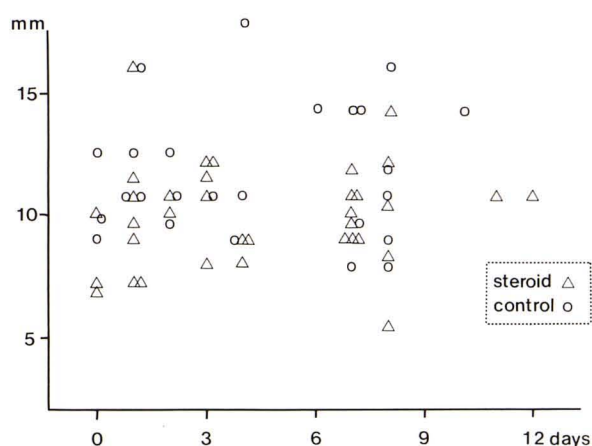
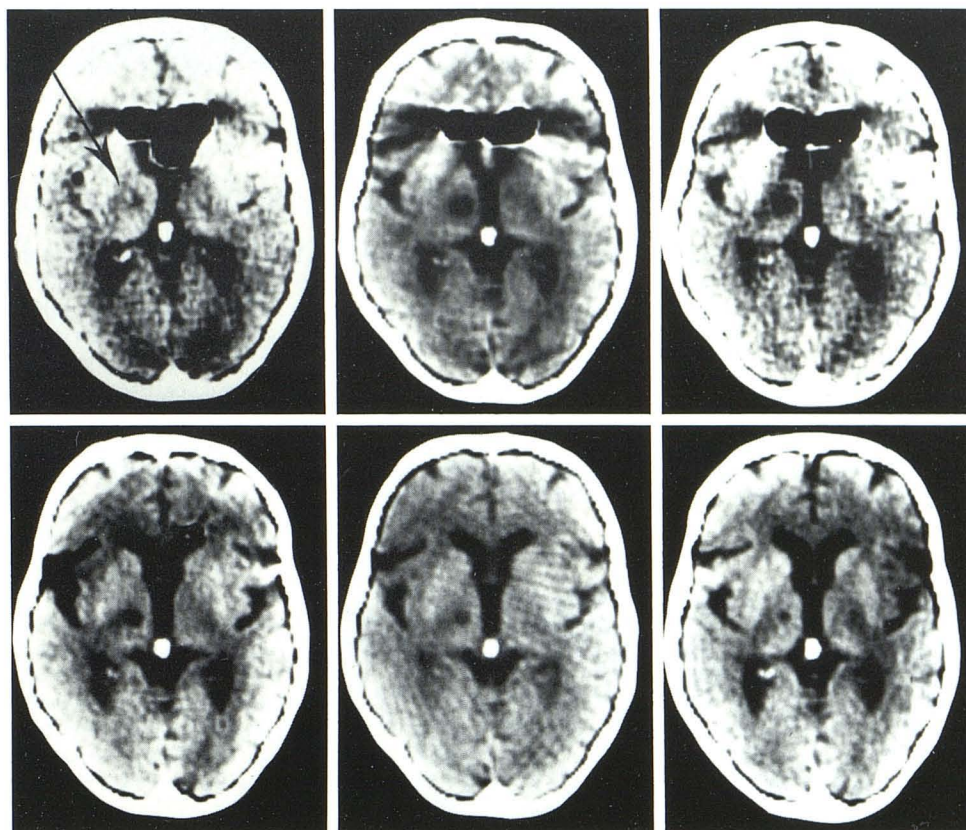


Fig. 3.—Diameter of thalamic lesion on CT scans ($n = 35$) of patients treated with steroids ($n = 16$) and on CT scans ($n = 25$) of untreated controls ($n = 12$) examined within 12 days after thalamotomy.

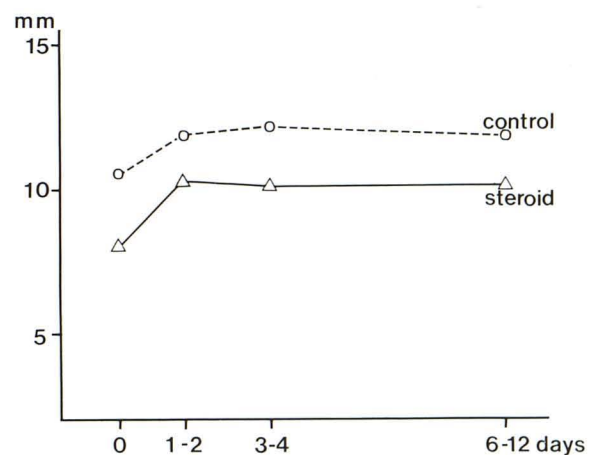


Fig. 4.—Diameter of thalamic lesion in two treatment groups (data from fig. 3 averaged over consecutive time periods).

Discussion

The considerable scatter of the measurement values in this study is an unfavorable feature of an edema model, related to the fact that the size of the lesion depends on the coagulation parameter. Such variations cannot be eliminated, however, since the procedure must be guided by the clinical requirements in the individual case. In the present study the coagulation variable (mA) did not vary significantly; it was 120–150 (mean, 139) in the steroid-treated group and 100–150 (mean, 138) in the control group.

Variations in the time interval must also be considered, but even in this respect there was no significant difference between the two groups. It is therefore reasonable to conclude that the steroid treatment was the differentiating factor.

Whether the observed decrease in CT attenuation related to the stereotaxic lesion does in fact represent edema cannot be conclusively established in a clinical study. However, there is experimental evidence that this is true. In a study of the progression and regression of edema in a cold lesion model using the specific gravity method and serial measurements of CT attenuation values, good

correspondence between these two parameters was reported, with maximum edema noted on the fifth day [6].

It has also been reported that radiofrequency lesions caused blood-brain barrier damage and edema developing along a time scale similar to that of the CT changes in the present study, and that these effects were diminished by pretreatment with steroids [7, 8]. These observations support the assumption that edema was at least partly responsible for the attenuation changes seen after thalamic coagulation and, conversely, that the size of the low-density area could be used as a relative measure of the amount of edema present. Thus, the results of the present study strongly indicate that the steroid treatment had an edema-preventing effect.

REFERENCES

1. Amano K, Iseki H, Kawabatake H, Notani M, Kawamura H, Kitamura K. Role of computerized transverse axial tomography on stereotactic surgery of the diencephalon. *Appl Neurophysiol* **1977**;39:202-211
2. Colombo F, Dettori P, Pinna V, Benedetti A. Stereotactic thalamic lesions studied by CT scanner. *Acta Neurochir* **1981**;57:205-212
3. Kullberg G, Cronqvist S, Brismar J. Stereotactic lesions studied by computer tomography. *Acta Neurochir [Suppl]* (Wien) **1980**;30:395-400
4. Murayama Y, Tsuda T, Sogabe K, Matsumoto K. CT appearances of thalamic lesions in stereotactic surgery. *Appl Neurophysiol* **1979**;42:307
5. Passerini A, Broggi G, Giorgi C, Savoiardo M. CT studies in patients operated with stereotaxic thalamotomies. *Neuroradiology* **1978**;16:561-563
6. Rieth KG, Fujiwara K, Di Chiro G, et al. Serial measurements of CT attenuation and specific gravity in experimental cerebral edema. *Radiology* **1980**;135:343-348
7. Pappius HM, Wolfe LS. Some further studies on vasogenic oedema. In: Pappius HM, Feindel W, eds. *Dynamics of brain edema*. Berlin: Springer-Verlag, **1976**:138-143
8. Rovit R, Hagan R. Steroids and cerebral edema: the effects of glucocorticoids on abnormal capillary permeability following cerebral injury in cats. *J Neuropathol Exp Neurol* **1968**;27:277-299