



Get Clarity On Generics

Cost-Effective CT & MRI Contrast Agents



FRESENIUS
KABI

WATCH VIDEO

AJNR

Extracerebral collections: recognition by NMR imaging.

I R Young, G M Bydder, A S Hall, R E Steiner, B S Worthington, R C Hawkes, G N Holland and W S Moore

AJNR Am J Neuroradiol 1983, 4 (3) 833-834

<http://www.ajnr.org/content/4/3/833>

This information is current as
of August 17, 2025.

Extracerebral Collections: Recognition by NMR Imaging

I. R. Young,¹ G. M. Bydder,² A. S. Hall,¹ R. E. Steiner,² B. S. Worthington,³ R. C. Hawkes,^{4,5} G. N. Holland,⁴ and W. S. Moore⁴

After head injury, nuclear magnetic resonance (NMR) scanning is, like computed tomography (CT), an effective method of distinguishing between intracerebral and extracerebral lesions. The location and shape of extracerebral collections are excellently displayed using the multiplanar facility of NMR. There are good grounds for believing that the problem of the isodense subdural hematoma encountered in CT scanning can almost certainly be overcome by the use of NMR imaging.

Cranial trauma accounts for as many as 10% of all patients seen in British accident and emergency departments. In the acute phase, deterioration in the level of consciousness with or without focal neurologic signs is the chief indication for radiologic investigation, and for this computed tomography (CT) has completely superseded angiography [1]. Extracerebral collections are the most common treatable lesions that can be demonstrated. Scans will also show the compression of the underlying brain and the presence of associated contusion or hematoma, the greater the degree of which the less favorable the prognosis [2]. Although there is no strict correlation between the age of a hematoma and its density, there is a general decrease with time such that hematomas pass through a stage (typically 2–4 weeks after injury) when they are isodense with brain [3]. Diagnosis then may be very difficult and often depends on the observation of indirect signs in unilateral collections. These include midline shift, flattening of the ipsilateral ventricle, effacement of cortical sulci, and medial displacement of the gray-/white-matter interface [4]. In bilateral collections there are compression of the ventricles and effacement of the basal cisterns and cortical sulci. Care must be taken here not to confuse hypodense collections with cerebral atrophy.

Methods and Results

In the University Hospital, Nottingham, and the Hammersmith Hospital, London, we have had the opportunity to study several patients with extracerebral collections using a variety of different nuclear magnetic resonance (NMR) scanning sequences. Whether intracerebral or extracerebral, an acute hematoma appears white on both inversion-recovery, T_1 -dominated images, and T_2 spin-echo images. This is because it displays a short T_1 value while showing an increased T_2 value relative to normal brain. On T_1 -dominated images contusion and edema are associated with a long T_1 value

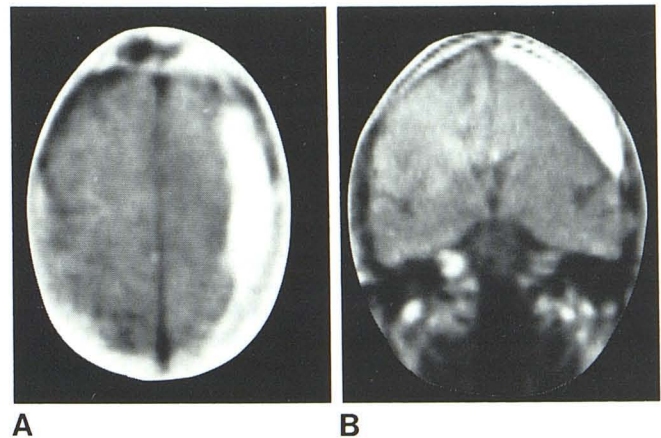


Fig. 1.—Axial transverse (A) and coronal (B) (SSFP) NMR scans showing high-convexity subdural hematoma.

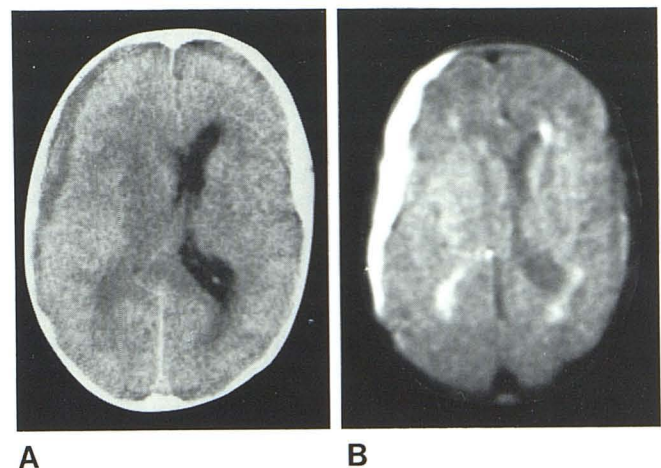


Fig. 2.—CT scan (A) and spin-echo NMR scan (B) of subdural hematoma. Collection is hypodense on CT and is better seen on NMR scan, reflecting long T_2 time of clotted blood. Periventricular edema is also known.

¹Pickering International, Wembley, London, England.

²Department of Diagnostic Radiology, Royal Postgraduate Medical School, Hammersmith Hospital, London, England.

³Department of Academic Radiology, Queen's Medical Centre, University of Nottingham, Nottingham NG7 2UH, England. Address reprint requests to B. S. Worthington.

⁴Department of Physics, University of Nottingham, Nottingham, England.

⁵Present address: Pickering International, Highland Heights, OH 44143.

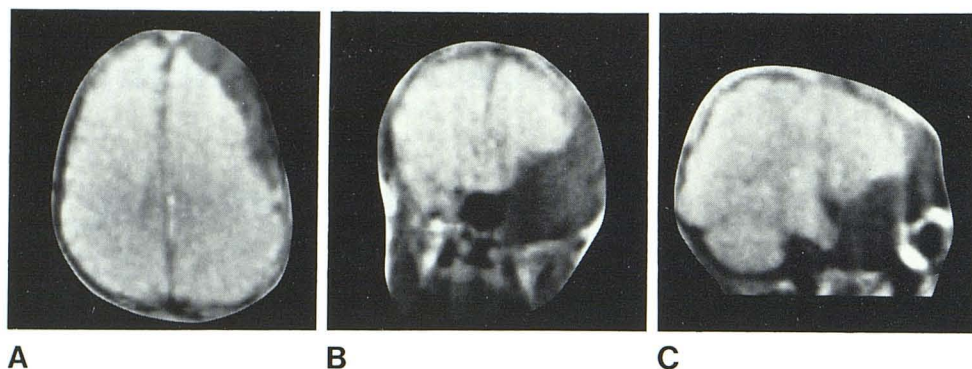


Fig. 3.—Axial transverse (A), coronal (B), and parasagittal (C) (SSFP) NMR scans showing hygroma surrounding temporal lobe and extending to high convexity. Coronal section also shows expanded middle cranial fossa.

and thus appear black, allowing a clear distinction to be made from hematoma. On T_2 -dominated images both hematoma and contusion lead to a lengthening of T_2 and so cannot be distinguished. In the transverse CT scan shown in figure 1A a hypodense subdural collection is seen over the high convexity and is associated with ventricular compression and medial displacement of the gray-/white-matter interface, a feature that will be more clearly seen on T_1 -dominated images. The hematoma is very well seen on the T_2 -dominated image together with periventricular edema (fig. 2B). Both in acute extracerebral collections (which have a higher CT attenuation value than brain) and in hypodense collections (with a lower attenuation value than brain), there is a high signal on the T_2 -dominated image. We may therefore infer that even during the transitional period, when the attenuation value of a collection changes and it becomes isodense, it will nevertheless give a higher signal than brain on the NMR scan.

Discussion

Because the changes in the spin relaxation times associated with clotted blood are in the opposite sense—that is, a short T_1 and long T_2 —the ratio T_2/T_1 greatly increased. This makes steady-state free-precession sequences (SSFP), which reflect this ratio, exquisitely sensitive to the presence of hematoma. The transverse and coronal sections (fig. 1) of a convex hematoma that was isodense on CT illustrate this, and also show the value of the multiplanar facility of NMR for defining the full extent of a collection. This will be particularly valuable in extensions beneath the temporal lobe

and in collections situated under the tentorium. Arachnoid malformations occur in many sites but they are most common in the middle cranial fossa [5] (fig. 3). The SSFP NMR scans show a low-density area within the expanded middle cranial fossa. The density corresponds to the long T_1 value of its contents, which approaches that of cerebrospinal fluid.

It appears that NMR will be more sensitive than CT in the detection of extracerebral collections because the isodense lesion will not be a problem. Its ability to demonstrate parenchymal damage and hematoma also commend its sequential use in patients who fail to improve or who deteriorate after a head injury. Repeated examination can be valuable in monitoring the effects of treatment.

REFERENCES

1. Ambrose J, Gooding MR, Uttley D. EMI scan in the management of head injuries. *Lancet* 1976;1:847
2. Merino-de-Villasante J, Taveras JM. Computerized tomography in acute head trauma. *AJR* 1976;126:765-778
3. Scotti G, Terbrugge K, Melancon D, Belanger G. Evaluation of the age of subdural hematomas by computerized tomography. *J Neurosurg* 1977;47:311-315
4. Barmier E, Dubowitz B. Grey-white matter interface (G-WMI) displacement: a new sign in the computed tomographic diagnosis of subtle subdural haematomas. *Clin Radiol* 1981;32:393-396
5. Smith RJ, Zacks DJ. CT scanning in middle fossa arachnoid malformations. *Clin Radiol* 1978;29:161-169