



Get Clarity On Generics

Cost-Effective CT & MRI Contrast Agents



FRESENIUS
KABI

WATCH VIDEO

AJNR

Fatty Replacement of Lower Paraspinal Muscles: Normal and Neuromuscular Disorders

Herzlia Hadar, Natan Gadoth and Marina Heifetz

AJNR Am J Neuroradiol 1983, 4 (5) 1087-1090

<http://www.ajnr.org/content/4/5/1087>

This information is current as
of August 12, 2025.

Fatty Replacement of Lower Paraspinal Muscles: Normal and Neuromuscular Disorders

Herzlia Hadar¹
Natan Gadoth²
Marina Heifetz¹

The physiologic replacement of the lower paraspinal muscles by fat was evaluated in 157 patients undergoing computed tomography for reasons unrelated to abnormalities of the locomotor system. Five patients with neuromuscular disorders were similarly evaluated. The changes were graded according to severity at three spinal levels: lower thoracic-upper lumbar, midlumbar, and lumbosacral. The results were analyzed in relation to age and gender. It was found that fatty replacement of paraspinal muscles is a normal age-progressive phenomenon most prominent in females. It progresses down the spine, being most advanced in the lumbosacral region. The severest changes in the five patients with neuromuscular disorders (three with poliomyelitis and two with progressive muscular dystrophy) consisted of complete muscle group replacement by fat. In postpoliomyelitis atrophy, the distribution was typically asymmetric and sometimes lacked clinical correlation. In muscular dystrophy, fatty replacement was symmetric, showing relative sparing of the psoas and multifidus muscles. In patients with neuromuscular diseases, computed tomography of muscles may be helpful in planning a better rehabilitation regimen.

The replacement of muscle tissue by fat as seen with advanced age or with various neuromuscular disorders has been well documented by conventional radiology [1, 2] and recently by computed tomography (CT) [3-6]. The muscles studied have been mainly those of the extremities, while the paraspinal muscles of the lower spine have been relatively neglected. However, during routine CT scanning of the abdomen these muscles are displayed clearly. We describe fat replacement of the lower paraspinal muscles in normal individuals as related to age and gender. The comparative appearance of these muscles in three patients with postpoliomyelitis atrophy and two with progressive muscular dystrophy is described.

Materials and Methods

We reviewed the CT scans of 80 men and 77 women who were examined at outpatient clinics. All the patients were in general good health, were active, and led normal lives for their ages. They had neither neuromuscular complaints nor neuromuscular disability. The CT scans were obtained to search for a neoplastic process, stage a known neoplastic process, or evaluate response to therapy.

Among these so-called normal controls, only three individuals were on long-term treatment with low doses of steroids. Seven males and 23 females were obese. The patients were divided into four age groups. The youngest age group (up to 19 years) comprised 20 males and 17 females. The other three groups (20-39; 40-59; and over 60 years) consisted of 20 men and 20 women each. Three adults with long-standing poliomyelitis and two children with progressive muscular dystrophy were studied separately.

The three adults with poliomyelitis comprised case 1, a 71-year-old woman affected since age 4 who had moderate weakness of the right leg and walked with a cane; case 2, a 33-year-old man affected since age 3 who had flaccid asymmetric paraparesis, severe scoliosis, and walked freely; and case 3, a 33-year-old man affected since age 3 who had

This article appears in the September/October 1983 issue of *AJNR* and the November 1983 issue of *AJR*.

Received July 28, 1982; accepted after revision February 8, 1983.

¹Department of Radiology, Beilinson Medical Center and Tel Aviv University Sackler School of Medicine, Petah Tiqva 49100, Israel. Address reprint requests to H. Hadar.

²Department of Neurology, Beilinson Medical Center and Tel Aviv University Sackler School of Medicine, Petah Tiqva 49100, Israel.

AJNR 4:1087-1090, September/October 1983
0195-6108/83/0405-1087 \$00.00
© American Roentgen Ray Society

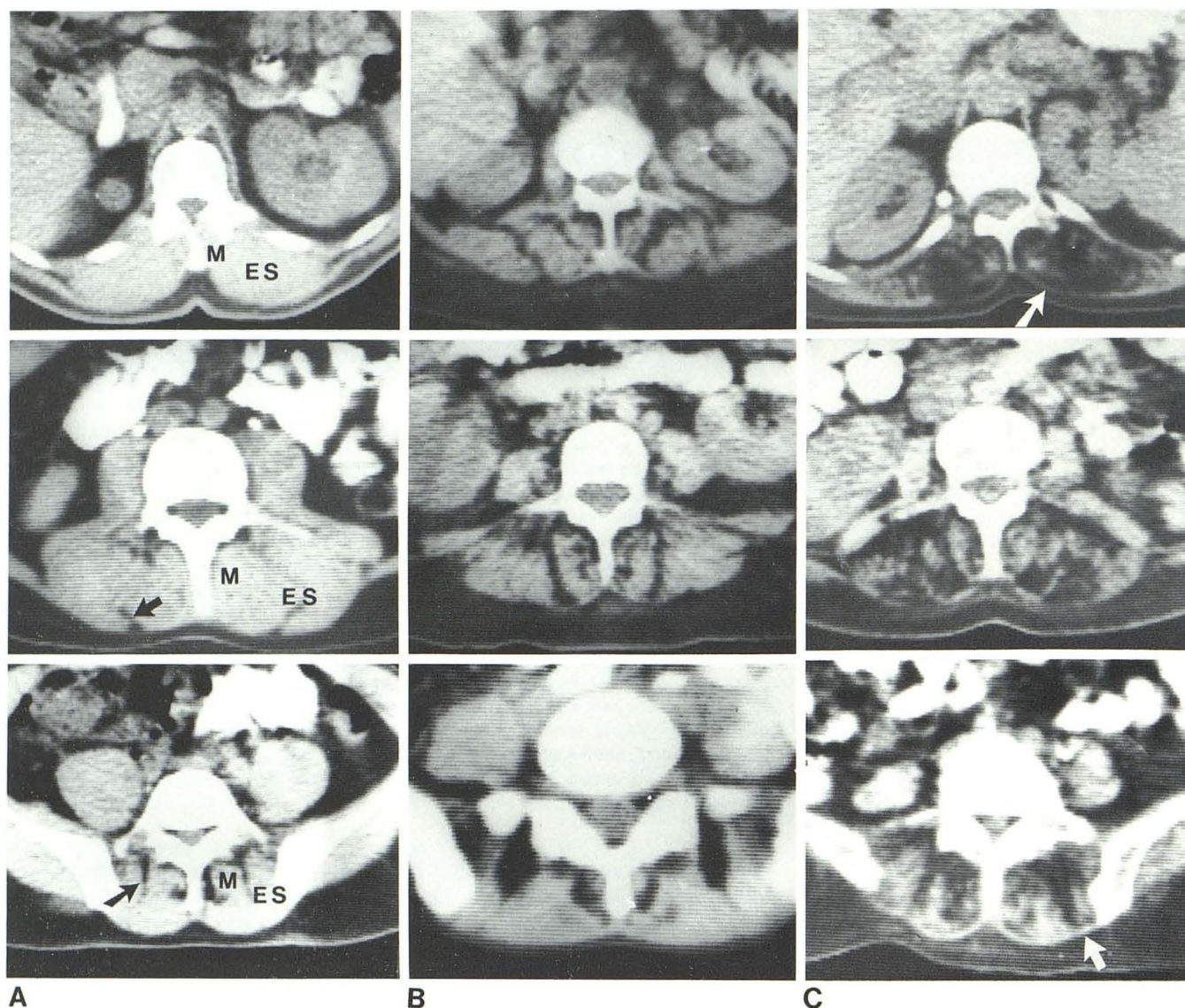


Fig. 1.—CT scans at three levels. Level 1 (top row); levels 2 and 3 (middle and bottom rows, respectively). A, Grade 0 fatty changes. Paraspinal muscles appear dense and homogeneous; fine, low-density striae separate muscle bundles (arrows). B, Grade 1 changes. Slight decrease of paraspinal mass

with coarse, low-density striae representing fat at all three levels. C, Grade 2 changes. Marked decrease in muscle mass with prominent fatty replacement. Thoracolumbar fascia (arrows) easily recognized due to shrinkage of wasted muscle. M = multifidus; ES = erector spinae.

monoparesis of left upper extremity.

The two children with progressive muscular dystrophy included case 4, a 13-year-old girl with a 7 year history of progressive weakness and wasting of limb-girdle musculature causing severe lordosis, and case 5, an 11-year-old boy with a 5 year history of progressive limb girdle weakness and clinical genetic and biochemical evidence indicating Duchenne muscular dystrophy.

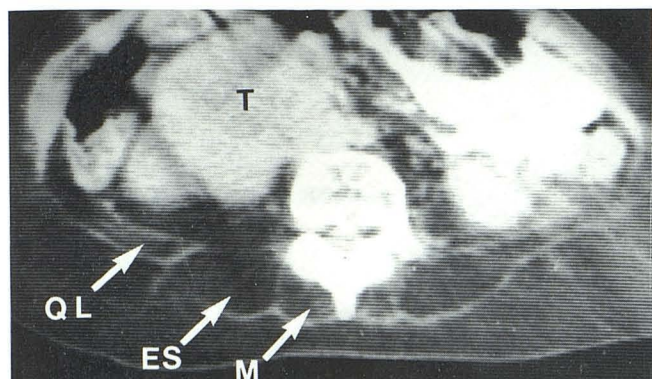
CT scans were obtained using the Elscint RLM 710 scanner. The slice thickness was 12 mm and photography was obtained at soft-tissue window settings. The paraspinal musculature was studied at three levels: *level 1*, T11–L1, covered the area of the lower back, provided that the lower ribs were visible; at *level 2*, L2–L4, the ribs were always absent and the iliac crests were not seen; *level 3* encompassed L5–S1.

The CT appearance of the paraspinal mass was judged according to its density, homogeneity, and presence of low-density areas,

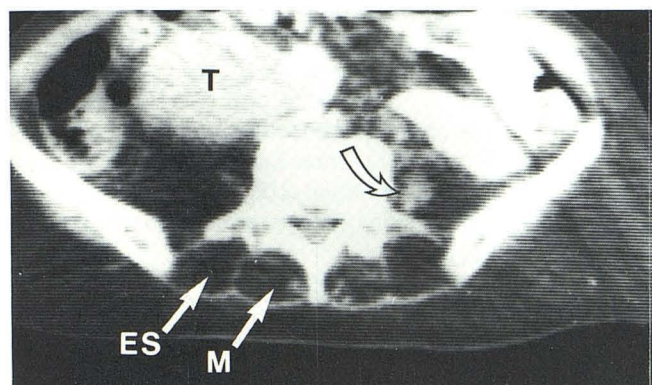
presumably fat tissue. The CT appearance of the muscle was graded as follows: *grade 0*, homogeneous muscle density sometimes containing low-density, fine striae outlining muscle bundles (fig. 1); *grade 1*, slight decrease of muscle mass with coarse fat striae (fig. 1); *grade 2*, marked decrease of muscle mass and prominent amount of fat (fig. 1); and *grade 3*, total replacement of muscle by fat (figs. 2–4).

Results

Fatty replacement of paraspinal muscles was present in 130 of the 157 controls. The severity of the changes was clearly related to age and gender. Females showed more prominent changes; however, the degree of fatty infiltration did not exceed grade 2. No correlation was found between



A



B

Fig. 2.—Case 1. Long-standing poliomyelitis and right-sided kidney tumor, representing grade 3 changes. **A**, Midlumbar level. Total “washout” of erector spinae (ES), multifidus (M), and quadratus lumborum (QL) with preservation of their intact fascia. Both psoas muscles are absent. Renal tumor (T) is seen clearly. **B**, Lumbosacral region. Total fatty replacement is similar to **A**. Asymmetric involvement of psoas evident by its partial presence on left (arrow).

fatty infiltration of paraspinal muscles and obesity, chemotherapy, or steroid treatment. The fatty infiltration was also related to the spinal level, being most prominent at level 3. Data showing the percentage of fatty changes according to age, gender, and level are given in figure 5.

At level 1 the youngest age group showed no changes, while, with increasing age, fatty infiltration increased concomitantly, being maximal in people over 60 years (45% of women and 15% of men showed grade 1 changes while 10% of women showed grade 2 changes).

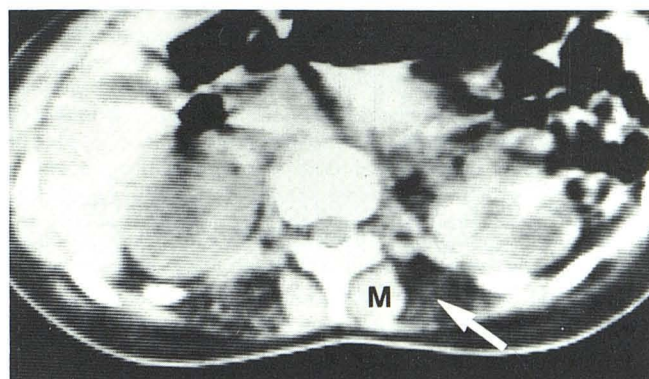
At level 2, 5.9% of the youngest females showed grade 1 changes. This increased with age, and, in the oldest age group, 70% of women and 45% of men had grade 1 changes while 15% of both genders showed grade 2 changes.

At level 3, changes were frequent even in the youngest age group but were evident only in children over 10 years of age. These changes were maximal in the oldest (50% of men and 10% of women were grade 1, while 90% of women and 50% of men were grade 2.)

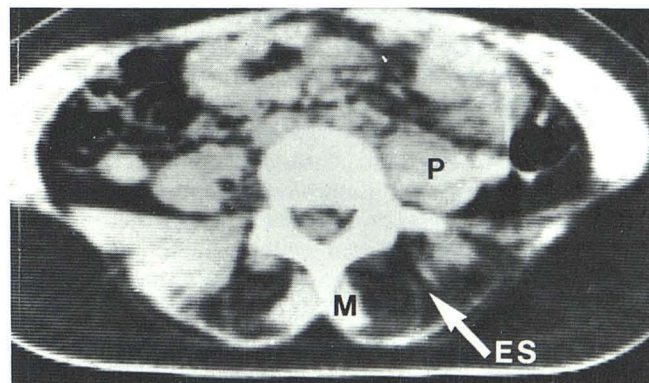
In the patients with neuromuscular disorders muscle involvement was asymmetric in the three adults with old

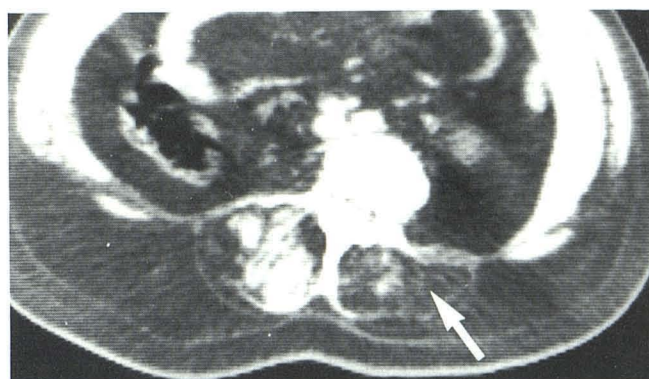

Fig. 3.—Case 2. Long-standing poliomyelitis showing grade 3 changes of left paraspinal muscles (arrow). Note asymmetric involvement typical for poliomyelitis and absence of both psoas muscles.



A



B

Fig. 4.—Case 4. Progressive muscular dystrophy. **A**, Level 1. Symmetric grade 3 changes of both erector muscles of spine (arrow), with sparing of both multifidus (M) muscles. **B**, Level 2. Almost symmetric involvement of the erector muscles of spine (ES) with sparing of both multifidus (M) and both psoas (P) muscles.

poliomyelitis (figs. 2 and 3), while distribution was symmetric in the two children with muscular dystrophy (figs. 4 and 6). Fatty infiltration was present in all five patients but reached grade 3 in four only. The changes found in case 5 with Duchenne-type muscular dystrophy at level 2 (fig. 6) resem-

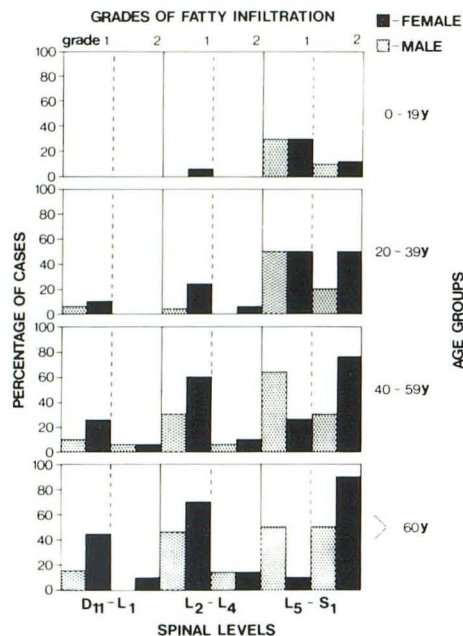


Fig. 5.—Distribution of fatty replacement of paraspinal muscles in 157 controls according to age, gender, and spinal level.

bled those found in the oldest group of controls. In the patients with neurogenic atrophy, there was a wide range of muscular involvement, while the dystrophy cases showed relative sparing of the psoas and multifidus muscles (figs. 4 and 6).

Discussion

It is well known that muscles wasted due to aging, disuse, or disease are replaced by fatty tissue. This fat can be differentiated easily from remaining muscle fibers on CT by its low-density appearance.

Conventional radiologic observations have shown that fatty replacement of the muscles of the extremities is related to age and gender, being more prominent in aged women [1]. Our survey, which dealt with the paraspinal group of muscles, has shown a similar pattern. It is of interest that not all the parts of the paraspinal group appeared to be affected equally. The severity of changes is related to the spinal level, being minimal in the lower thoracic region and maximal in the lumbosacral region. This is evident from the appearance of these muscles at the lumbosacral level in our normal adolescents. Among children older than 10 years this area contained fat in about 70% of the patients, suggesting that this region is normally more vulnerable to fatty replacement.

As it is unreasonable to perform CT on normal individuals for the evaluation of paraspinal musculature, the control group was selected from our outpatient population. Naturally, some of these patients were on chemotherapy for various malignancies; however, in a number of controls in whom repeated scans were obtained, no change in the appearance of the paraspinal muscles was present during the course of prolonged chemotherapy. It can be assumed that our so-called control group represents the normal pop-

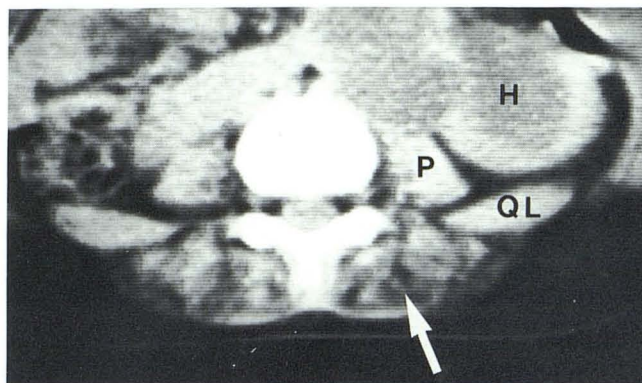


Fig. 6.—Case 5. Progressive muscular dystrophy. Changes of paraspinal muscles (arrow) could not be differentiated from grade 2 changes of controls. Note symmetrical sparing of psoas (P) and quadratus lumborum (QL) muscles. Incidental finding was left hydronephrosis (H).

ulation as regards paraspinal musculature. This assumption is based on the normal neuromuscular condition of these patients and the small number of individuals who showed only minimal fatty changes despite prolonged steroid therapy (grade 1 at level 3).

Fatty replacement was marked in our five patients suffering from primary muscle disease or neurogenic muscle atrophy. Although the diagnosis of a specific disease entity could not be reached by the CT appearance, the neurogenic atrophy of poliomyelitis could easily be distinguished due to its clear-cut asymmetric distribution.

Scanning the superficial paraspinal group and deep-seated pelvic muscles in neuromuscular disorders may be valuable because single muscles that are not accessible to individual manual muscle testing or electromyography can be demonstrated. This is documented in our case 3, who suffered only from flaccid monoparesis of the left arm. CT revealed atrophic changes of the left psoas and moderate atrophy with fatty replacement of the right gluteal muscles. As these muscles play an essential role in locomotion, their proper assessment with the aid of CT might determine successful rehabilitation and appreciation of the value of various therapeutic and physiotherapeutic regimens.

REFERENCES

1. Di Chiro G, Nelson KB. Soft tissue radiography of extremities in neuromuscular disease with histological correlations. *Acta Radiol [Diagn]* (Stockh) **1965**;3:65-88
2. Gwinn JL, Lee FA. Radiological case of the month: pseudohypertrophic muscular dystrophy (Duchenne's muscular dystrophy). *Am J Dis Child* **1973**;125:831-832
3. O'Doherty DS, Schellinger D, Raptopoulos V. Computed tomographic patterns of pseudohypertrophic muscular dystrophy: preliminary results. *J Comput Assist Tomogr* **1977**;1:482-486
4. Bulcke JA, Termote JL, Palmers Y, Crolla D. Computed tomography of the human skeletal muscular system. *Neuroradiology* **1979**;17:127-136
5. Termote JL, Baert A, Crolla D, Palmers Y, Bulcke JA. Computed tomography of the normal and pathologic muscular system. *Radiology* **1980**;137:439-444
6. Riddlesberger MM. Computed tomography of the musculoskeletal system. *Radiol Clin North Am* **1981**;19:463-477