



Get Clarity On Generics

Cost-Effective CT & MRI Contrast Agents



WATCH VIDEO

AJNR

Real-time digital subtraction angiography for therapeutic neuroradiologic procedures.

R G Sherry, R E Anderson, R A Kruger and J A Nelson

AJNR Am J Neuroradiol 1983, 4 (6) 1171-1173

<http://www.ajnr.org/content/4/6/1171>

This information is current as
of August 26, 2025.

Real-Time Digital Subtraction Angiography for Therapeutic Neuroradiologic Procedures

Richard G. Sherry¹
Robert E. Anderson
Robert A. Kruger
James A. Nelson

Procedural control during therapeutic neuroradiologic procedures is generally based on repeated angiograms to assess the degree to which embolization has reduced abnormal blood flow. Due to the complex craniofacial skeletal anatomy that is superimposed over lesions in this area, subtraction studies are usually required to see the vessels and visualize a tumor stain satisfactorily. We have used a device incorporating continuous recursive digital video filtration, which allows the operator to view a subtracted fluoroscopic image of each control angiographic sequence in real time. The advantages of this technique for therapeutic procedures are described.

Digital subtraction angiography (DSA) has found wide application in neuroradiology [1-3]. With refinements in equipment, greater use of this technique is being made for interventional procedures. The speed with which an electronically subtracted image may be viewed compared with making a darkroom subtraction film substantially decreases the overall time required for therapeutic neuroradiologic procedures. Patient comfort and safety are improved because of the diminished catheter time and the lower doses and concentrations of contrast material used. We describe the use of a prototype real-time DSA subtraction device and emphasize the advantages for its use in therapeutic procedures.

Materials and Methods

A dual-memory digital recursive video filtration device has been interfaced to a General Electric RFX/Fluoricon L300 system. Details of this processor and its properties relative to DSA have been reported [4, 5]. Initial clinical results have shown that temporal filtration of fluoroscopic video using this device is effective both for intravenous and intraarterial DSA [6, 7]. Rather than periodic x-ray pulsing, continuous fluoroscopic exposure is used. For the case reported, a field size up to 15 cm was used, resulting in a maximum x-ray dose rate of 300 μ R/sec [0.077 C/(kg-sec)] incident to the image-intensifier surface. These factors yield two line pairs/mm resolution. A noise-reduced subtraction image sequence was available in real time at 30 frames/sec. The image matrix size was 400 \times 792. Filtered DSA sequences were stored simultaneously on analog videodisk and videotape. An automatic mode of reprocessing from videodisk was available, but was not needed for this case study.

Case Report

A 19-year-old man was referred for radiologic evaluation and subsequent embolization of a juvenile angiofibroma. The patient had a 6 month history of nasal stuffiness, but no epistaxis. Computed tomography (CT) showed a 3 cm mass arising in the right pterygo-maxillary fossa. Higher cuts showed extension across the midline, suggesting some blood supply might be drawn from the left.

Intraarterial DSA showed intense vascular staining of the tumor with the predominant blood supply from distal branches of the right internal maxillary artery (figs. 1A and 1B).

Received December 10, 1982; accepted after revision May 9, 1983.

¹All authors: Department of Radiology, University of Utah School of Medicine, 50 N. Medical Dr., Salt Lake City, UT 84132. Address reprint requests to R. G. Sherry.

AJNR 4:1171-1173, Nov/Dec 1983
0195-6108/83/0406-1171 \$00.00
© American Roentgen Ray Society

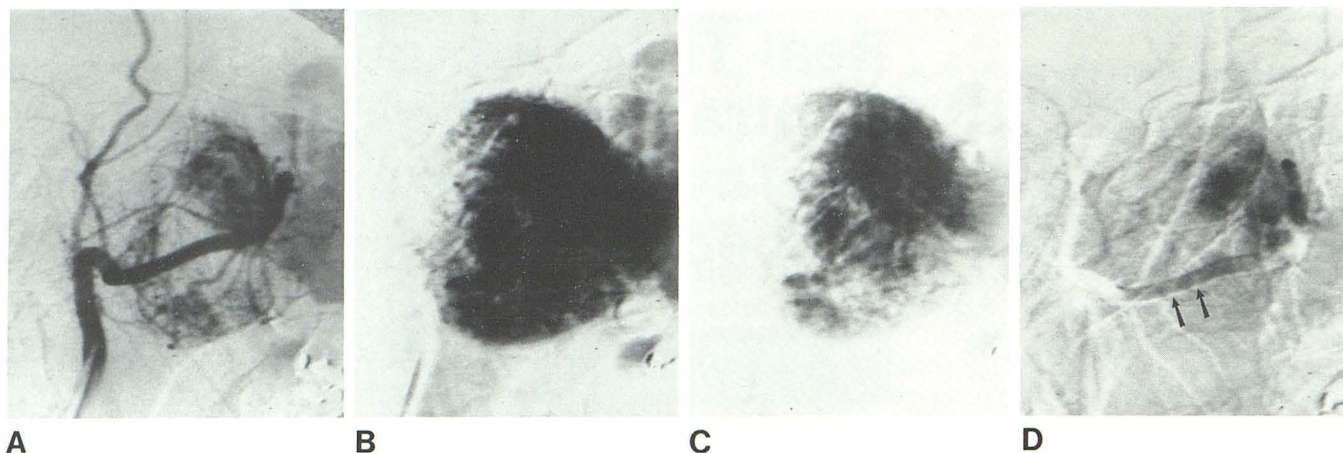


Fig. 1.—A, Single frame from real-time subtracted DSA series after selective injection in right internal maxillary artery. Excellent definition of numerous arterial branches enveloping tumor. B, Venous phase. Intense homogeneous stain characteristic of juvenile angiofibroma. C, Venous phase of injection of 3 ml of 43% contrast after partial embolization demonstrates new avascular areas in periphery of the tumor. Immediate display of real-time

series of subtracted images facilitates determination of progress of procedure. D, Single frame from late venous phase injection at termination of procedure shows markedly diminished tumor blush. Small residual nidus of tumor still enhances quite avidly. Persistence of contrast in internal maxillary artery and several Gelfoam particles in vessels (arrows).

Only a small amount of opacification occurred via the left internal maxillary artery.

The right internal maxillary artery was selectively catheterized to a point beyond the origin of the middle meningeal artery and embolized with 2–3 mm Gelfoam particles injected in small aliquots. Embolization was monitored fluoroscopically and with several real-time subtraction studies (fig. 1C). The procedure was terminated when only a small stain could be seen on the DSA images, and significant reduction of blood flow to the tumor was observed (fig. 1D). Total procedure time was about 45 min.

Discussion

Real-time DSA offers many advantages over conventional film angiographic methods for monitoring interventional vascular procedures [8]. Viewing of the subtracted angiographic sequences in real time before and during embolization facilitates decision making during the procedure by eliminating the need to process film and make subtractions, as well as permitting rapid comparison of multiple studies from the videodisk. With our equipment, the entire serial angiographic sequence is visualized in subtracted form, and false impressions that might have resulted in the past when only selected angiogram films could be subtracted are eliminated.

In addition to decreasing procedure time, patient comfort is enhanced because smaller volumes of lower-concentration contrast material can be used. In our case reported, imaging was performed with a rapid hand injection of 3–5 ml of Conray-43 in the internal maxillary artery. The volume of contrast material was decreased as embolization progressed. The slightly larger volume of contrast material (5 ml) was necessary initially to assure opacification of small distal branches of the internal maxillary artery.

Early in the procedure the patient felt only mild warmth. Late in the procedure, as the tumor bed became obliterated and flow through the tumor diminished, the patient de-

scribed only a mild aching sensation with contrast injection. This minimal morbidity is a dramatic improvement compared with the way in which control angiograms were obtained with conventional angiographic techniques and higher concentrations of contrast material in the past. Despite lower concentrations of contrast material, the overall quality of the subtracted images compares very favorably with conventional film techniques.

Although the DSA images appear to be of high quality, one difficulty in using this technique with therapeutic procedures is lower spatial resolution compared with conventional film magnification angiography. A potential hazard exists in that extracranial-intracranial anastomotic channels below the limits of resolution of the DSA system may be present. The practical significance of this needs further investigation. We have not yet had the opportunity to make direct comparison of DSA and conventional magnification film angiograms in a patient with visible extracranial-intracranial anastomoses. In part, the lower spatial resolution is compensated for by the greater contrast resolution and improved conspicuity of transiently filled vessels offered by real-time DSA. Injection of 2–3 mm particles also diminishes the risk of inadvertent embolization of any small extracranial-intracranial anastomoses that could be below the lower limits of resolution of the video system [9].

Compared with conventional pulsed DSA equipment, the reported device and procedure have several advantages for intraarterial arteriography:

Processing occurs in real time and results in a 30 frame/sec display that can be viewed as a virtually continuous subtraction imaging sequence. Therefore, all the subtleties of vascular opacification are preserved.

Videodisk storage is adjustable up to 30 frames/sec, but for this type of study is set at five frames/sec. Since playback can be adjusted from freeze frame to 30 frames/sec, an accelerated display (up to six times real time) is possible. This type of accelerated display often makes it easier to

assess alterations in blood flow through a vascular bed and to document efficacy of embolization. Videotape storage and display are maintained at 30 frames/sec.

X-ray dose to the patient is significantly reduced with this type of processing. It has been shown that x-ray dose can be reduced by a factor of 1.6 for equivalent images compared with DSA pulsed at once per second [7]. For intraarterial studies such as the type performed here, pulsing rates in excess of two per second are necessary. Therefore, less than one third of the x-ray dose is necessary with our equipment compared with a pulsed DSA method. If higher pulsing rates are used, the dose reduction is even greater.

Further advantages of the DSA technique described here are the minimal film cost and improved use of special procedure personnel. Also, work is progressing on software refinements to allow on-line quantification of blood flow through arterial feeders to tumors and arteriovenous malformations [10]. This may permit more accurate determination and standardization of embolization endpoints.

REFERENCES

1. Strother CM, Sackett JF, Crummy AB, et al. Clinical applications of computerized fluoroscopy. The extracranial carotid arteries. *Radiology* **1980**;136:781-783
2. Ovitt TW, Christenson PC, Fischer HD III, et al. Intravenous angiography using digital video subtraction: x-ray imaging system. *AJNR* **1980**;1:387-390, *AJR* **1980**;135:1141-1144
3. Meaney JF, Weinstein MA, Buonocore E, et al. Digital subtraction angiography of the human cardiovascular system. *Proc SPIE* **1980**;233:272-278
4. Kruger RA. A method for time domain filtering using computerized fluoroscopy. *Med Phys* **1981**;8:466-470
5. Kruger RA, Liu PY, Bateman W, Nelson J. Time domain filtering using computerized fluoroscopy—intravenous angiography applications. *Proc SPIE* **1981**;314:319-326
6. Kruger RA, Miller FJ, Nelson JA, et al. Digital subtraction angiography using a temporal bandpass filter: associated patient motion properties. *Radiology* **1982**;145:309-313
7. Nelson JA, Miller FJ, Kruger RA, et al. Digital subtraction angiography using a temporal bandpass filter: initial clinical results. *Radiology* **1982**;145:309-313
8. Forbes GS, Earnest F, Kismet DB, Folger WN, Sundt TM. Digital angiography. *Mayo Clin Proc* **1982**;57:683-693
9. Lasjaunias P. Nasopharyngeal angiofibromas: hazards of embolization. *Radiology* **1980**;136:119-123
10. Kruger RA, Bateman W, Liu PY, Nelson JA. Parametric imaging using a digital recursive process. *Radiology* (in press)