



**Get Clarity On Generics**

Cost-Effective CT & MRI Contrast Agents

**FRESENIUS  
KABI**

**WATCH VIDEO**

**AJNR**

**Computed Tomography of the Asymptomatic  
Postsurgical Lumbar Spine: Analysis of the  
Physiologic Scar**

Ira F. Braun, Joseph P. Lin, M. Vallo Benjamin and Irvin I.  
Kricheff

This information is current as  
of August 17, 2025.

*AJNR Am J Neuroradiol* 1983, 4 (6) 1213-1216  
<http://www.ajnr.org/content/4/6/1213>

# Computed Tomography of the Asymptomatic Postsurgical Lumbar Spine: Analysis of the Physiologic Scar

Ira F. Braun<sup>1,2</sup>  
Joseph P. Lin<sup>1</sup>  
M. Vallo Benjamin<sup>3</sup>  
Irvin I. Kricheff<sup>1</sup>

Computed tomography (CT) has been shown to be an effective noninvasive means of imaging the lumbar spine in patients with suspected disk disease. The clinical and radiographic evaluation, however, of patients with new or recurrent symptoms after surgery for disk disease is fraught with difficulty. This report describes CT changes seen in seven asymptomatic volunteers scanned at various intervals after disk surgery and discusses the implications of these findings.

A most difficult diagnostic problem from both clinical and radiographic standpoints is the evaluation of patients with recurrent symptoms after lumbar disk surgery. The causative factors may include recurrent disk herniation at the operative level, postoperative scarring or arachnoiditis, disk herniation at a remote level, infection, spinal stenosis, cyst and meningocele formation, and mechanical instability [1]. The most common causes are recurrent herniation and postoperative scarring; the myelographic differentiation between them is at best difficult and considered by many to be impossible [2-9]. High-resolution computed tomography (CT) has been shown to be effective in evaluating preoperative patients with suspected disk disease [10], and it has also been used extensively in the evaluation of the postoperative patient with recurrent symptoms. It requires some knowledge of CT findings of normal physiologic healing and fibrosis after disk surgery. Such information is lacking in the literature. To provide a "baseline" for the CT evaluation of symptomatic postoperative patients, we scanned a series of seven asymptomatic volunteers at intervals ranging from 4 weeks to 7 months after surgery for lumbar disk disease.

## Subjects and Methods

Seven volunteers were scanned using a General Electric CT/T 8800 scanner equipped with a digital radiographic image capability (ScoutView) for identifying scanning planes. A slice thickness of 5 mm was used to decrease partial-volume effects that occur with thicker cuts. Scanning features included 120 kVp, 760 mAs, and 0.75 mm pixel size.

Only the level of surgery was studied. Four to five scans were obtained routinely; two to three scans through the surgically violated disk space, one 5 mm below the space, and one 5 mm above the space. All scans were obtained parallel to the disk plane and adjacent vertebral body end-plates with the patient supine. Intravenous contrast material was not used.

The asymptomatic volunteers were scanned from as early as 4 weeks to as late as 7 months into the postoperative period. Several volunteers had had preoperative CT scans as part of their initial workup. The surgical procedure performed on all volunteers included in this report was the same. It consisted of a hemilaminectomy, partial medial facetectomy, and radical disk removal done by a single neurosurgeon (M. V. B.).

This article appears in the November/December 1983 issue of *AJNR* and the January 1984 issue of *AJR*.

<sup>1</sup> Department of Radiology, New York University Medical Center, New York, NY 10016.

<sup>2</sup> Present address: Department of Radiology, Section of Neuroradiology, Emory University School of Medicine, 1365 Clifton Rd., N.E., Atlanta, GA 30322. Address reprint requests to I. F. Braun.

<sup>3</sup> Department of Neurosurgery, New York University Medical Center, New York, NY 10016.

*AJNR* 4:1213-1216, Nov/Dec 1983  
0195-6108/83/0406-1213 \$00.00  
© American Roentgen Ray Society



## Results

Several features were seen consistently (table 1). Four subjects had an eccentric "vacuum" phenomenon (figs. 1–3), a finding seen as early as 5 weeks and as late as 7 months postoperatively. One patient scanned 5 weeks after surgery had vacuum gas within the spinal canal in addition to gas at the disk space (fig. 2).

The four subjects with a nonstenotic canal displayed retraction of the dural tube toward the side of surgery (figs. 3 and 4). These individuals also displayed intraspinal soft tissue of relative hyperdensity to the dural tube on the side of surgery blending anteriorly with the disk coursing around the lateral aspect of the dural tube, and extending posteriorly to the laminectomy defect (figs. 1, 3, and 4). Concomitant findings included effacement of normal epidural fat (figs. 1–4), loss of distinction of the ipsilateral nerve root

(fig. 3), and extension of the soft tissue into the neural foramina in both cases in which a foraminal disk had previously been removed (figs. 1 and 4).

The three subjects with a stenotic spinal canal had loss of definition of intraspinal contents (fig. 5). In addition, all seven cases had a decrease in the height of the surgically violated disk space as seen on the digital radiograph.

## Discussion

In our routine clinical practice only symptomatic patients undergo postoperative radiography. In these symptomatic patients we consistently find vacuum changes, increased density obliterating nerve root and dural tube landmarks on the side of surgery, effacement of epidural fat, and retraction of the dural tube. While our series of asymptomatic volunteers is admittedly small, every one of these asymptomatic postoperative patients had several or all findings commonly seen in the symptomatic postoperative patient.

The vacuum phenomenon was a consistent feature in the asymptomatic volunteers. It is commonly seen in patients without a history of previous surgery and is thought to result from liberation of gas, usually nitrogen, into fissures within the degenerated disk material [11]. A vacuum formation may also be seen when the disk is injured [12] secondary to either metabolic disease, which interferes with nutrition of the disk, or to simple mechanical trauma, such as occurs during disk removal. The gas in the region of the disk shortly after surgery probably represents sequelae of the recent surgical manipulation, while that seen 6 or 7 months after

TABLE 1: CT Features of Postoperative Spine in Asymptomatic Subjects

Feature	No. (n = 7)
Eccentric vacuum phenomenon	4
Gas within spinal canal	1
Dural tube retraction toward surgical side (in non-stenotic canal)	4
Intra- and extraspinal tissue accumulation	5
Effacement of epidural fat	4
Loss of distinction of ipsilateral nerve root	2
Decrease in height of surgically violated disk space	7
Loss of definition of intraspinal contents	3

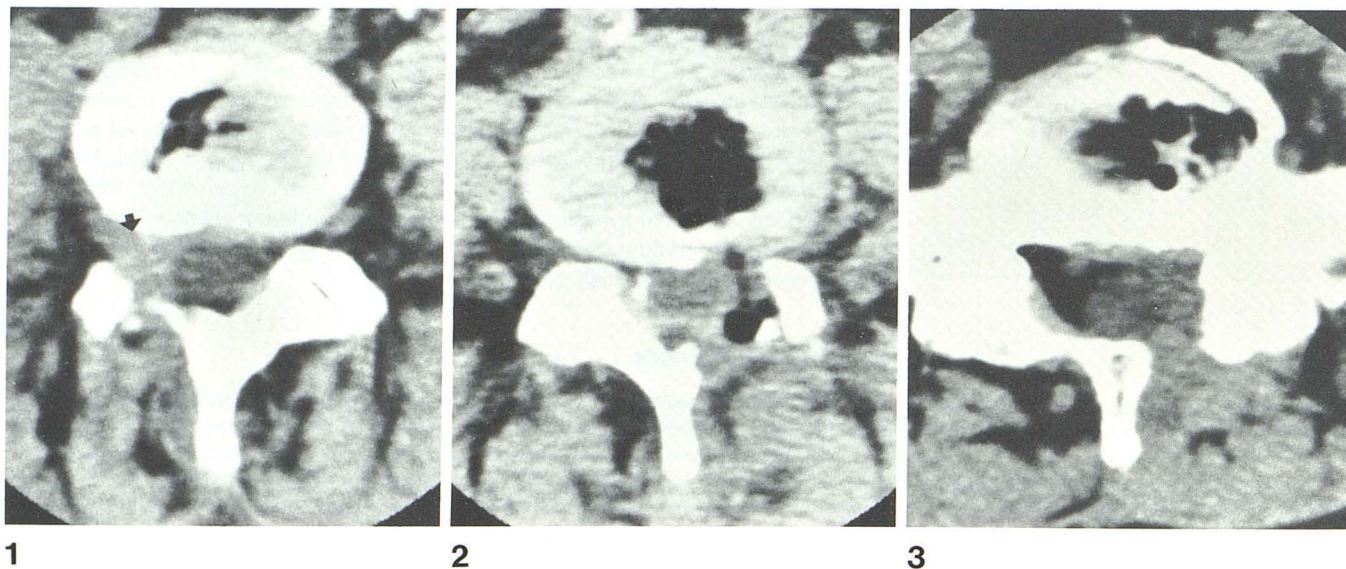


Fig. 1.—L4–L5 disk space 6 months after surgery for extruded right foraminal disk. Eccentric vacuum phenomenon is apparent. Band of hyperdense soft tissue courses around anterolateral aspect of dural tube on right extending from disk margin out through right intervertebral foramen and posteriorly to laminectomy defect (arrow). Moderate hypertrophy of facet joints and postoperative changes in right paraspinal musculature are also apparent.

Fig. 2.—L4–L5 interspace 4 weeks after surgery. Gas extends from disk margin around left lateral aspect of dural tube to laminectomy defect. Post-

operative changes in left paraspinal musculature as well as moderate amount of facet joint hypertrophy on right are seen.

Fig. 3.—L5–S1 interspace 7 months after surgery for central disk herniation. Vacuum phenomenon in eccentric location. Band of hyperdense soft tissue extends anteriorly from disk margin around lateral aspect of dural tube to laminectomy defect on left. Nerve root on right is seen distinctly while no definitive nerve root is appreciated on left. Retraction of dural tube toward side of surgery on left. Postoperative changes in left paraspinal musculature are apparent.



Fig. 4.—Pre- and postoperative L4–L5 interspace in patient with severe right lower extremity pain and radiculopathy. **A**, Soft-tissue density protruding through right intervertebral foramen (arrow) was proven surgically to represent herniated disk material. **B**, 7 months after surgery. No symptoms. Marked retraction of dural tube toward side of surgery. Band of soft-tissue density extends around lateral aspect of dural tube from hemilaminectomy defect posteriorly to disk margin anteriorly and through foramen laterally adjacent to vertebral body. Postoperative changes in right paraspinal musculature are appreciated.

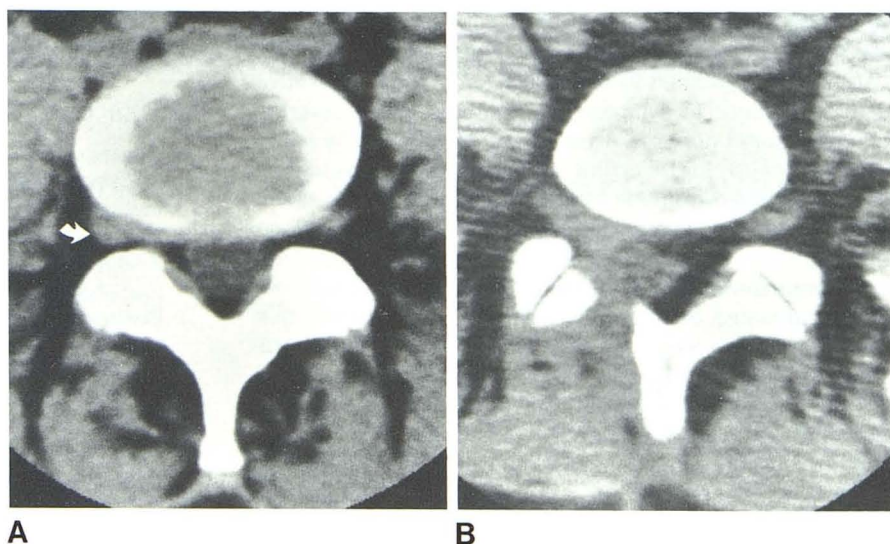
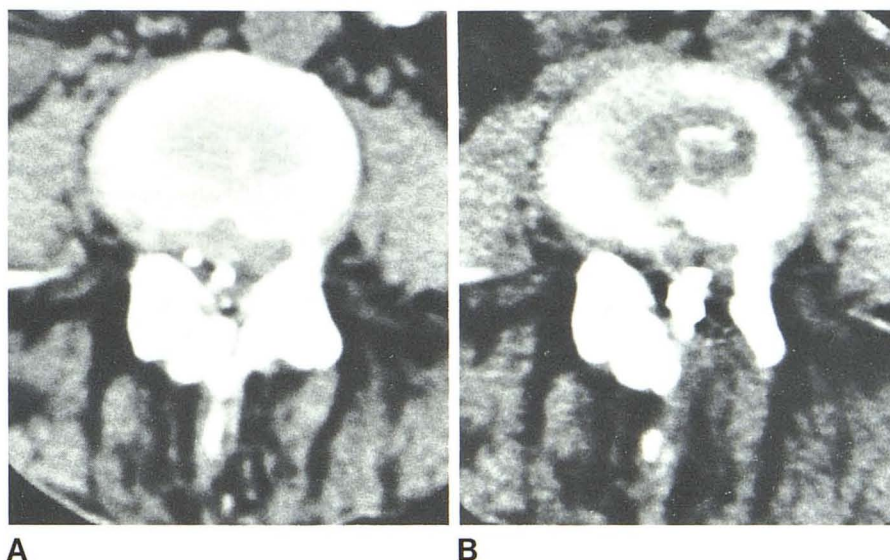


Fig. 5.—Pre- and postoperative L4–L5 interspace in patient with severe spinal stenosis and facet joint hypertrophy bilaterally. **A**, Soft tissue extending to left lateral aspect of canal was proven surgically to represent herniated disk material. Residual droplets of Pantopaque within canal. Dural tube is not seen distinctly. **B**, 5 months after surgery; no symptoms. Band of slightly hyperdense soft tissue anteriorly and along left anterolateral aspect of spinal canal. Exact boundaries of dural tube remain poorly defined. Postoperative changes in left paraspinal musculature are noted.



surgery is a reflection of postoperative degenerative disk phenomenon.

Dural tube retraction toward the side of surgery is consistent with postoperative healing and scar formation with subsequent cicatrization and adhesions of the thecal sac. While we would expect to see this change in all patients as a result of normal physiologic healing, the only asymptomatic volunteers who did not demonstrate this change were those with a stenotic canal. Lack of space for movement of the dural tube precludes this displacement.

A band of hyperdense soft tissue (relative to the dural tube) on the side of surgery coursing from the disk margin around the lateral aspect of the dural tube and extending to the laminectomy defect was seen in all subjects with a canal capacious enough to demonstrate intraspinal contents. This presumed fibrous tissue extended laterally through the

neural foramina, simulating recurrent lateral herniation in those symptomatic volunteers operated on for a laterally herniated disk (figs. 1 and 4). Effacement of epidural fat and loss of distinction and displacement of nerve roots occurred in four of the volunteers secondary to healing and scar formation.

Early in our experience with symptomatic postoperative patients, scans were obtained both before and after intravenous contrast administration. We found intravenous contrast enhancement to be of no value in differential diagnosis, and indeed no significant changes other than some enhancement of epidural venous structures could be seen. For this reason and for ethical considerations, contrast material was not administered to our group of asymptomatic volunteers. Measurements of attenuation coefficients for known herniated disk material were compared with those of



areas of postoperative fibrosis in these asymptomatic volunteers, and no significant differences were found.

All the findings seen in our asymptomatic postoperative volunteers occur in symptomatic patients. While scarring and subsequent nerve root retraction are commonly implicated as a cause for recurring symptoms, they were seen in all asymptomatic patients with a sufficiently large spinal canal and were indistinguishable from those in symptomatic patients. Hasso (Hasso AN, personal communication) has seen contralateral displacement of the dural tube with recurrent herniated disk, but we have not yet observed this finding. Therefore, we agree with Williams et al. [10], Carrera et al. [13], and Haughton et al. [14] that the CT differentiation of symptomatic scarring from asymptomatic fibrosis and from small clinically significant recurrent disk herniation is usually extremely difficult. Larger recurrent herniations may be easier to discern against a background of fibrosis on plain CT. Similarly, the finding of a vacuum in the postoperative period provides no diagnostic information.

The postoperative appearance of the spine will necessarily depend on the type of surgery performed. Two basic surgical procedures are used for the treatment of herniated lumbar disks. The less radical technique is an interlaminar approach with laminotomy and limited removal of disk fragments. The more radical approach, and the one we use in our subjects, consists of a hemilaminectomy with partial medial facetectomy and radical disk removal. The former method of treatment involves sectioning of the ligamentum flavum with disk fragment removal and preservation of epidural fat, while the latter involves removal of bone and ligamentum flavum as well as epidural fat. Radical disk removal implies that the surgeon has attempted complete disk removal. Up to 50% removal of disk is usually accomplished.

Our observations in postoperative subjects without symptoms indicate herniated disk material, especially small fragments, may be difficult if not impossible to discern. Because of the partial-volume phenomenon it is necessary to have a relatively large mass of nuclear material for unequivocal demonstration. CT myelography with water-soluble contrast material might be helpful in differentiating between the two entities by the subtle changes in the contour of the dural

tube caused by herniated disk material [15]. That is currently under investigation.

#### REFERENCES

1. Quencer RM, Murtagh RF, Post MJD, Rosomoff HL, Stokes NA. Postoperative bony stenosis of the lumbar spinal canal: evaluation of 164 symptomatic patients with axial radiography. *AJR* 1978;131:1059-1064
2. Knutsson F. The myelogram following operation for herniated disc. *Acta Radiol* (Stockh) 1949;32:60-65
3. Cronquist S. The postoperative myelogram. *Acta Radiol* (Stockh) 1959;52:45-51
4. Maltby GL, Prendergrass RL. Pantopaque myelography: diagnostic errors and review of cases. *Radiology* 1946;47:35-46
5. Leader SA, Russel MJ. The value of Pantopaque myelography in the diagnosis of herniation of the nucleus pulposus in the lumbosacral spine. *AJR* 1953;69:231-241
6. Borelli FJ, Maglione AA. The importance of myelography in spinal pathology. Analytic study of 150 cases. *AJR* 1956;76:273-289
7. Wright FW, Sanders RC, Steel WM, O'Connor BT. Some observations on the value and techniques of myelography in lumbar disc lesions. *Clin Radiol* 1971;22:33-43
8. Shapiro R. *Myelography*, 3d ed. Chicago: Year Book Medical, 1975:203
9. Moseley I. The oil myelogram after operation for lumbar disc lesions. *Clin Radiol* 1977;28:267-276
10. Williams AL, Haughton WM, Syvertsen A. Computed tomography in the diagnosis of herniated nucleus pulposus. *Radiology* 1980;135:95-99
11. Ford LT, Gilula LA, Murphy WA, et al. Analysis of gas in vacuum lumbar disc. *AJR* 1977;128:1056-1057
12. Resnick D, Niwayama G, Guerra J Jr, Vint V, Usselman J. Spinal vacuum phenomena: anatomical study and review. *Radiology* 1981;139:341-348
13. Carrera GF, Williams AK, Haughton VM. Computed tomography in sciatica. *Radiology* 1980;137:433-437
14. Haughton VM, Eldevik OP, Magnaes B, Amundsen P. Prospective comparison of computed tomography and myelography in the diagnosis of herniated lumbar discs. *Radiology* 1982;142:103-110
15. Meyer JD, Latchaw RE, Roppolo HM. CT myelography of the postoperative spine. Presented at the annual meeting of the Radiological Society of North America, Chicago, November 1981