



Get Clarity On Generics

Cost-Effective CT & MRI Contrast Agents



FRESENIUS
KABI

WATCH VIDEO

AJNR

Radiologic evaluation of *E. coli* meningitis after a ventriculoperitoneal shunt.

M S Levine

AJNR Am J Neuroradiol 1983, 4 (6) 1247-1248

<http://www.ajnr.org/content/4/6/1247.citation>

This information is current as
of August 25, 2025.

Radiologic Evaluation of *E. coli* Meningitis after a Ventriculoperitoneal Shunt

Marc S. Levine¹

A case of *E. coli* meningitis in a patient with a ventriculoperitoneal shunt was encountered recently at our institution. A shunt-induced bowel perforation was demonstrated by injecting contrast material percutaneously into the proximal end of the shunt. Apparently, retrograde spread of normal bowel flora via the shunt was responsible for his unusual Gram-negative meningitis. Because of the disastrous consequences of persistent bacterial seeding of his cerebrospinal fluid (CSF), the shunt was removed surgically. This unusual but potentially fatal complication of ventriculoperitoneal shunts has been reported in the nonradiologic literature. However, the radiologist's role in documenting this condition has received little attention. A complete description of this case is provided.

Case Report

A 24-year-old man had a ventriculjugular shunt placed in 1973 for treatment of hydrocephalus due to a congenital cyst of the third ventricle. In 1979, the shunt was subsequently revised to a ventriculoperitoneal shunt with a Raimondi peritoneal catheter. On this admission, he presented to the emergency room with recent onset of severe headache, neck pain, nausea, vomiting, loss of appetite, and high fever. Physical examination revealed a young man in acute distress with a stiff neck, positive Brudzinski and Kernig signs, and a temperature of 39.7°C. A lumbar puncture revealed cloudy fluid with a white blood cell count of 19,400/mm³. A Gram stain revealed Gram-negative rods and *E. coli* was subsequently cultured from his CSF.

The patient was started on antibiotic therapy with ampicillin and gentamicin. Because of the unusual nature of his Gram-negative meningitis, the possibility of a bowel perforation by the ventriculoperitoneal shunt with subsequent retrograde spread of infection via the shunt was suspected. With the aid of a neurosurgeon, a shunt contrast study was performed by injecting 20 ml of metrizamide (Amipaque) through the scalp into the proximal end of the shunt. Under fluoroscopic guidance, contrast material was shown to enter the proximal ascending colon from the distal tip of the catheter, confirming the presence of a bowel perforation (fig. 1). As a result, the ventriculoperitoneal shunt was surgically removed. Postoperatively, the patient became afebrile and a repeat lumbar puncture demonstrated clearing of his CSF. However, he subsequently developed signs and symptoms of increased intracranial pressure, necessitating placement of another ventriculoperitoneal shunt. The

patient was discharged from the hospital in good condition with further follow-up planned by his neurosurgeons to carefully monitor the status of his shunt.

Discussion

Ventriculoperitoneal shunts are often used to treat hydrocephalus by diverting CSF from an obstructed ventricular system into the peritoneal cavity for reabsorption. Intestinal perforation by the peritoneal tip of the catheter is an unusual but dangerous complication of this procedure. In 1966, Wilson and Bertran [1] first described this problem in two patients with ventriculoperitoneal shunts. One developed generalized peritonitis and died. However, the other was asymptomatic and the only sign of a bowel perforation was the passage of a separated distal catheter fragment per rectum.

Intestinal perforation by a ventriculoperitoneal shunt has subsequently become a well recognized entity. In the two largest series, Schulhof et al. [2] reported colonic perforation in seven patients and Grosfield et al. [3] in five patients with ventriculoperitoneal shunts. While the colon was usually the site of involvement, perforation of the small intestine has also been described [4]. Patient ages have ranged from 3 months to 18 years, and the interval between placement of the shunt and detection of a bowel perforation has ranged from 1 month to 8 years.

In about one-half the reported cases, the presence of a bowel perforation was recognized only by passage of the peritoneal end of the shunt per rectum with the catheter tip seen extruding from the anus of an otherwise asymptomatic patient [1-6]. In other cases, however, an unusual Gram-negative ventriculitis or meningitis resulted from retrograde spread of normal bowel flora (usually *E. coli*) via the shunt [2-5, 7, 8]. Because of persistent ventricular seeding, the infection usually could not be controlled with antibiotics and revision or removal of the shunt was required. Despite aggressive therapy, nearly half the patients with *E. coli* meningitis secondary to a shunt-induced bowel perforation have not survived.

Plain abdominal radiographs may be of value in detecting certain intraabdominal complications of ventriculoperitoneal

Received July 19, 1982; accepted October 6, 1982.

¹ Department of Radiology, Hospital of the University of Pennsylvania, 3400 Spruce St., Philadelphia, PA 19104.

AJNR 4:1247-1248, November/December 1983 0195-6108/83/0406-1247 \$00.00 © American Roentgen Ray Society

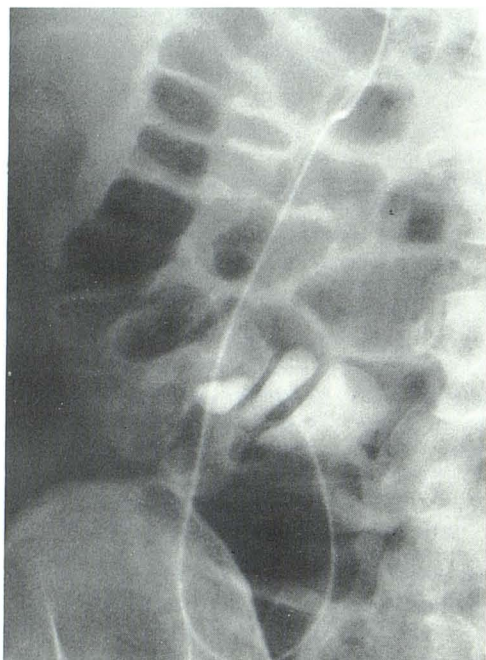


Fig. 1.—Contrast injected into proximal end of shunt enters proximal ascending colon, confirming shunt-induced colonic perforation.

shunts such as loculated collections of CSF [9]. However, a shunt-induced bowel perforation can only be diagnosed by a shunt contrast study [10]. With assistance from the neurosurgeon, percutaneous injection of water-soluble contrast material into the proximal end of the shunt under fluoroscopic guidance may document a perforation by demonstrating passage of contrast material from the shunt into the bowel lumen (fig. 1) [3, 4]. Alternatively, the radiologist himself may directly puncture and opacify the shunt as it courses subcutaneously over the thoracic cage. The feasibility of direct puncture of LeVeen-type peritoneovenous shunts has already been demonstrated [11]. The same procedure could be used for determining the cause of a malfunctioning ventriculoperitoneal shunt. In any event, documentation of a shunt-induced bowel perforation in the presence of a Gram-negative ventriculitis or meningitis should lead to immediate revision or removal of the shunt as a potentially life-saving procedure.

The etiology of intestinal perforation by ventriculoperitoneal shunts is uncertain. It has been postulated that fibrous encasement of the peritoneal end of the catheter may cause sustained pressure erosion by its tip at a fixed point on the bowel surface with eventual perforation at this site [5]. This concept is supported by a case in which autopsy findings demonstrated marked fibrotic reaction around the margins of an ileal perforation [5]. The usual absence of associated

peritonitis may also be attributed to this extensive fibrosis, which apparently prevents spillage of intestinal contents into the peritoneal cavity.

Of interest, a particular peritoneal catheter called the Raimondi catheter was used in some cases, including our own, in which a shunt-induced bowel perforation occurred [2, 6, 8]. Because of the apparently increased risk of intestinal perforation with this catheter, the neurosurgeons at our institution now use other catheters for this procedure.

In summary, intestinal perforation with subsequent *E. coli* meningitis is an unusual but frequently fatal complication of ventriculoperitoneal shunts. Clinicians and radiologists should be aware of the role of a shunt contrast study to document this entity, so that its potentially disastrous consequences may be avoided.

ACKNOWLEDGMENT

I thank Luis Schut, Department of Neurosurgery, Children's Hospital of Philadelphia, for referring this case to our department.

REFERENCES

1. Wilson CB, Bertan V. Perforation of the bowel complicating peritoneal shunt for hydrocephalus. Report of two cases. *Am Surg* 1966;32:601-603
2. Schulhof LA, Worth RM, Kalsbeck JE. Bowel perforation due to peritoneal shunt: a report of seven cases and a review of the literature. *Surg Neurol* 1975;3:265-269
3. Grosfeld JL, Cooney DR, Smith J, Campbell RL. Intra-abdominal complications following ventriculoperitoneal shunt procedures. *Pediatrics* 1974;54:791-796
4. Davidson RI. Peritoneal bypass in the treatment of hydrocephalus: historical review and abdominal complications. *J Neurol Neurosurg Psychiatry* 1976;39:640-646
5. Rubin RC, Ghatak NR, Visudhipan PA. Asymptomatic perforated viscus and Gram-negative ventriculitis as a complication of valve-regulated ventriculoperitoneal shunts. *J Neurosurg* 1972;37:616-618
6. Murtagh FR, Quencer RM, Poole CA. Extracranial complications of cerebrospinal fluid shunt function in childhood hydrocephalus. *AJR* 1980;135:763-766
7. Pierce KR, Loeser JD. Perforation of the intestine by a Raimondi peritoneal catheter. *J Neurosurg* 1975;43:112-113
8. Sells CJ, Loeser JD. Peritonitis following perforation of the bowel: a rare complication of a ventriculoperitoneal shunt. *J Pediatrics* 1973;83:823-824
9. Goldfine SL, Turetz F, Beck AR, Eiger M. Cerebrospinal fluid intraperitoneal cyst: an unusual abdominal mass. *AJR* 1978;130:568-569
10. Azimi F, Dinn WM, Naumann RA. Intestinal perforation: an infrequent complication of ventriculoperitoneal shunts. *Radiology* 1976;121:701-702
11. Freiman DB, Ring EJ, Oleaga JA, Rosato EF. Radiography of LeVeen type peritoneovenous shunts. *AJR* 1978;131:916-917