



Get Clarity On Generics

Cost-Effective CT & MRI Contrast Agents



FRESENIUS
KABI

WATCH VIDEO

AJNR

Pneumatization of the occipital bone as a cause of radiolucent skull lesions.

W W Lo and E Zapanta

AJNR Am J Neuroradiol 1983, 4 (6) 1249-1250

<http://www.ajnr.org/content/4/6/1249.citation>

This information is current as
of August 14, 2025.

Pneumatization of the Occipital Bone as a Cause of Radiolucent Skull Lesions

William W. M. Lo¹ and Edward Zapanta²

Radiolucent calvarial lesions evoke a long list of differential diagnostic possibilities. Reeder and Felson [1] listed 13 common and 20 rare causes. Extensive as that list may be, we recently encountered yet another cause, and we report our findings.

Case Report

A 67-year-old man was admitted to the St. Vincent Medical Center (SVMC) for biopsy of an occipital bone lesion. Several months before, following a coughing spell, he noticed a small mass and some discomfort in the occipital region. There was no drainage or redness. More recently he felt discomfort involving the left side of the head and the left ear.

A few weeks before admission, while under the care of a different physician, the patient had the small mass in the occipital region excised. This was reported to be consistent with a lipoma. Subsequent outside skull radiographs were reported to show a large defect in the occipital bone; a computed tomographic (CT) scan was reported to show a low-density occipital bone lesion, but the radionuclide bone scan was normal.

After admission to SVMC, skull radiographs (fig. 1A) and complex motion tomograms (figs. 1B and 1C) were obtained, pneumatization of the occipital bone was recognized, and the scheduled bone biopsy cancelled. The air density was confirmed by CT (fig. 1D).

The patient was discharged with the assurance of a benign process. On follow-up 9 months later he continued to experience fullness in the left ear on pressing the occiput and discomfort in the occiput on blowing his nose.

Discussion

Air cells of the temporal bone develop as out-pouchings from the tympanum, epitympanum, antrum, and eustachian tube [2]. Pneumatization begins late in fetal life, accelerates at birth, and continues through infancy, early childhood, and occasionally early adult life. The extent and pattern of pneumatization vary greatly between individuals, with a tendency toward symmetry in a given individual. Pneumatization is generally confined to the mastoid process, the base of the petrosa, the base of the squama, and around

the eustachian tube, but occasionally extends into the zygoma and petrous apex and behind the sigmoid sinus. The pneumatization process may be arrested by childhood mastoiditis [2].

On the basis of anatomic landmarks and patterns of air cell development, pneumatization of the temporal bone may be classified by region as follows: (1) mastoid, (2) perilabyrinthine, (3) petrous apex, or (4) accessory [3]. Included in the accessory group are the zygomatic, squamous, occipital, and styloid cell areas. It has been noted that occipital pneumatization is a posterior extension from perisinus air cells [3].

Our case shows extensive extratemporal pneumatization involving the occipital bone and the clivus of the sphenoid, presumably by extension of the temporal pneumatization across temporooccipital and temporosphenoidal sutures. Such a connection between the occipital cells and the middle ear is at least suggested by the patient's symptoms. The cause for such an unusual extent of pneumatization is unknown. In addition, there is pneumatization of the lateral masses of the atlas, even though polytomography did not reveal fusion between the occipital condyles and the lateral masses. The mechanism of pneumatization of the atlas is thus open to further speculation. It is also open to question whether the extraordinary extent of pneumatization developed early and stabilized after the patient's formative years or whether it is still progressive. Will fractures occur from minor trauma or serious complications occur from infection? It is not apparent whether common causative factors exist between profuse pneumatization originating from the temporal bone and that from the paranasal sinuses—pneumosis dilatans [4, 5].

From a practical standpoint, the prime significance of extratemporal pneumatization appears to lie in the potential of its being unrecognized and subjected to unwarranted surgical intervention and possible complications. The diagnosis can be made by careful analysis of the radiographs of the skull and can be supported by conventional tomography and confirmed by CT.

Received July 20, 1982; accepted after revision December 15, 1982.

¹ Department of Radiology, St. Vincent Medical Center, 2131 W. Third St., Los Angeles, CA 90057. Address reprint requests to W. W. M. Lo.

² Section of Neurosurgery, St. Vincent Medical Center, Los Angeles, CA 90057.

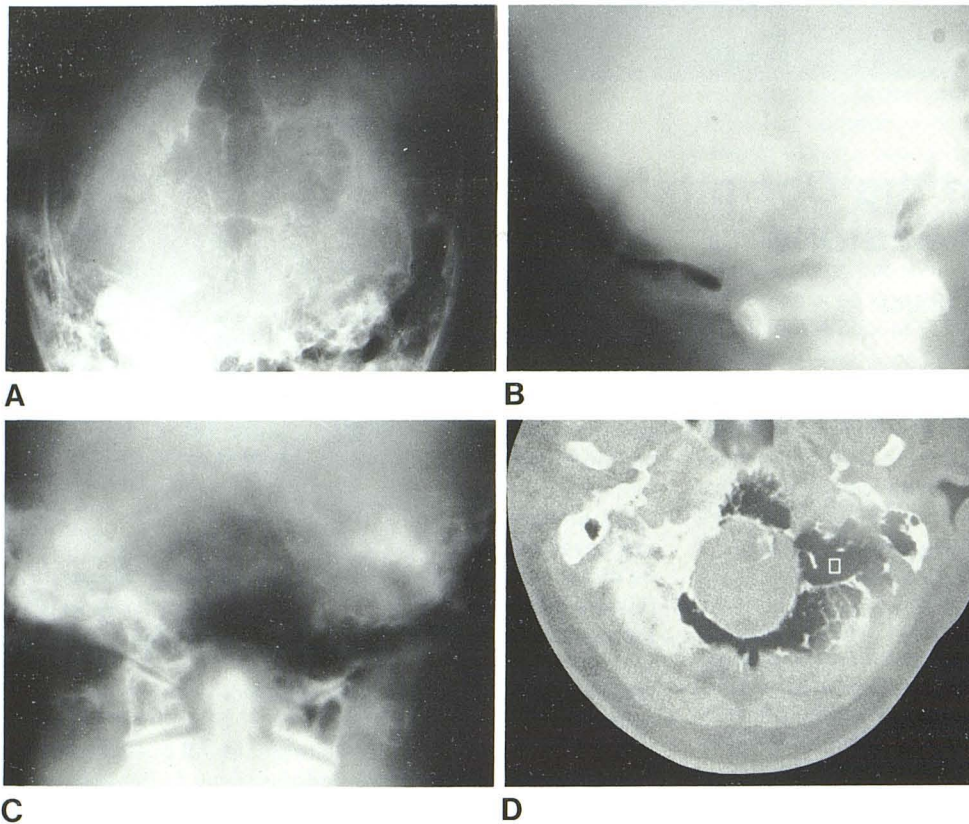


Fig. 1.—A, Towne view of skull shows 6 cm midline occipital radiolucency bordered by fine radiopaque rim and divided by several septa. Radiolucency borders foramen magnum and extends toward mastoids. Air density is difficult to appreciate on this view. B, Lateral polytomogram shows occipital air confined between inner and outer tables of skull and similar pneumatization of clivus. C, Frontal polytomogram shows pneumatization of occipital condyles and of lateral masses of atlas without occipitalization of atlas. D, Axial CT of base of skull shows continuation of pneumatization around foramen magnum. Mean density of -232 Hounsfield units lies clearly below range of fat, such as might be seen in dermoids.

ACKNOWLEDGMENTS

We thank Richard M. Witten for supervising the CT scan, Connie J. Etchie for manuscript preparation, and Sook Wha Lee for photography.

REFERENCES

1. Reeder MM, Felson B. *Gamuts in radiology: comprehensive lists of differential diagnosis*. Cincinnati: Audiovisual Radiology of Cincinnati, 1975
2. Shambaugh GE Jr. *Surgery of the ear*, 2d ed. Philadelphia: Saunders, 1967
3. Allam AF. Pneumatization of the temporal bone. *Ann Otol Rhinol Laryngol* 1969;78:49-64
4. Shapiro R, Schorr S. A consideration of the systemic factors that influence frontal sinus pneumatization. *Invest Radiol* 1980;15:191-202
5. Lombardi G. *Radiology in neuro-ophthalmology*. Baltimore: Williams & Wilkins, 1967