



**Get Clarity On Generics**

Cost-Effective CT & MRI Contrast Agents

**FRESENIUS  
KABI**

**WATCH VIDEO**

**AJNR**

## **Qualitative Assessment and Reporting Quality of Intracranial Vessel Wall MR Imaging Studies: A Systematic Review**

J.W. Song, S.C. Guiry, H. Shou, S. Wang, W.R. Witschey,  
S.R. Messé, S.E. Kasner and L.A. Loevner

This information is current as  
of August 14, 2025.

*AJNR Am J Neuroradiol* 2019, 40 (12) 2025-2032

doi: <https://doi.org/10.3174/ajnr.A6317>

<http://www.ajnr.org/content/40/12/2025>

# Qualitative Assessment and Reporting Quality of Intracranial Vessel Wall MR Imaging Studies: A Systematic Review

J.W. Song, S.C. Guiry, H. Shou, S. Wang, W.R. Witschey, S.R. Messé, S.E. Kasner, and L.A. Loevner



## ABSTRACT

**BACKGROUND:** Over the last quarter-century, the number of publications using vessel wall MR imaging has increased. Although many narrative reviews offer insight into technique and diagnostic applications, a systematic review of publication trends and reporting quality has not been conducted to identify unmet needs and future directions.

**PURPOSE:** We aimed to identify which intracranial vasculopathies need more data and to highlight areas of strengths and weaknesses in reporting.

**DATA SOURCES:** PubMed, EMBASE, and MEDLINE databases were searched up to September 2018 in accordance with the Preferred Reporting Items for Systematic Reviews and Meta-Analyses guidelines.

**DATA ANALYSIS:** Two independent reviewers screened and extracted data from 128 articles. The Strengthening the Reporting of Observational Studies in Epidemiology guidelines were used to assess the reporting quality of analytic observational studies.

**DATA SYNTHESIS:** There has been an exponentially increasing trend in the number of vessel wall MR imaging publications during the past 24 years ( $P < .0001$ ). Intracranial atherosclerosis is the most commonly studied intracranial vasculopathy (49%), followed by dissections (13%), aneurysms (8%), and vasculitis (5%). Analytic observational study designs composed 48% of the studies. Transcontinental collaborations showed nonsignificantly higher reporting quality compared with work originating from single continents ( $P = .20$ ).

**LIMITATIONS:** A limitation is the heterogeneity in study designs.

**CONCLUSIONS:** Investigations on the diagnostic utility of vessel wall MR imaging in less commonly studied intracranial vasculopathies such as dissections, aneurysms, and vasculitis are warranted. More consistent adherence to the Strengthening the Reporting of Observational Studies in Epidemiology guidelines should improve transparency and maximize effective synthesis for clinical translation. Diverse collaborative teams are encouraged to advance the understanding of intracranial vasculopathies using vessel wall MR imaging.

**ABBREVIATIONS:** CRS = complete reporting score; ICAD = intracranial atherosclerotic disease; STROBE = Strengthening the Reporting of Observational Studies in Epidemiology; VWI = vessel wall MR imaging

Vessel wall MR imaging (VWI) is being increasingly used worldwide to evaluate intracranial vasculopathies.<sup>1</sup> This increased utilization has paralleled a rise in the number of publications using VWI. Many narrative reviews report the application and utility of VWI for different types of vasculopathies.<sup>2,3</sup> However, no study has systematically assessed the frequency or

trends of VWI publications for all intracranial vasculopathies or the reporting quality.

Interpretation of data and secondary analyses from observational studies is often limited by the methodology and completeness of reporting. Reporting quality is important to critically

Received July 15, 2019; accepted after revision September 24.

From the Departments of Radiology (J.W.S., S.C.G., S.W., W.R.W., L.A.L.), Neurology (S.R.M., S.E.K.), Otolaryngology (L.A.L.), and Neurosurgery (L.A.L.), Hospital of the University of Pennsylvania, Philadelphia, Pennsylvania; and Department of Biostatistics, Epidemiology and Informatics (H.S.), University of Pennsylvania, Philadelphia, Pennsylvania.

This work was supported by the Radiological Society of North America Research and Education Foundation, through grant No. RSCH1929; the Institute for Translational Medicine and Therapeutics/Thomas B. McCabe and Jeannette E. Laws McCabe Fund for Junior Faculty (J.W.S.); and National Institutes of Health National Heart, Lung, and Blood Institute, R01 HL137984 (W.R.W.).

The content is solely the responsibility of the authors and does not necessarily represent the official views of the Radiological Society of North America Research and Education Foundation.

Please address correspondence to Jae W. Song, MD, MS, Department of Radiology, Division of Neuroradiology, Hospital of the University of Pennsylvania, 3400 Spruce St, Philadelphia, PA 19104; e-mail: jae.song@penmedicine.upenn.edu; @jsongmd

Indicates open access to non-subscribers at [www.ajnr.org](http://www.ajnr.org)

Indicates article with supplemental on-line tables.

<http://dx.doi.org/10.3174/ajnr.A6317>

assess the strengths of studies, weaknesses, and generalizability as well as for investigators who want to assess the reproducibility of a study. The clinical and scientific utility of research data may be lost in poorly reported studies. The Strengthening the Reporting of Observational Studies in Epidemiology (STROBE) guidelines were developed to improve the quality of reporting of observational studies in medical research.<sup>4,5</sup> We set out to systematically survey VWI publications by examining the types of vasculopathies studied as well as assessing the quality of reporting of analytic observational studies using the STROBE checklist. The aims of this study were to identify which intracranial vasculopathies may need more data and to highlight areas of reporting that could be improved.

## MATERIALS AND METHODS

### Search Strategy

The systematic review was conducted in accordance with the Preferred Reporting Items for Systematic Reviews and Meta-Analyses guidelines. PubMed, EMBASE, and MEDLINE were searched on September 12, 2018. To identify eligible studies, we searched keywords using the Boolean operators “OR” and “AND.” Keywords covered imaging, vessel wall imaging, intracranial circulation, vasculopathy, and vascular disease terms (On-line Table 1). A manual review of the citations of each included article was also performed. All foreign language articles were translated.

### Study Selection

Two researchers independently reviewed all publications for inclusion. Inclusion criteria were the following: 1) case series or observational studies, 2) imaging humans, 3) intracranial arteries, 4) intracranial vasculopathies, 5) imaging of the arterial wall, and 6) MR imaging. Single case reports, conference abstracts, animal studies, and studies of the pediatric population were excluded.

### Data Extraction

Two reviewers independently screened and extracted data from each study that fulfilled the inclusion and exclusion criteria. Disagreements were resolved by consensus. We collected the following data: publication characteristics (year of publication, countries of publication, funding sources), type of vasculopathy studied, study design (case series or analytic observational study), and subject enrollment design (prospective or retrospective). Analytic observational studies were identified using a published study design classification algorithm<sup>6</sup> and included studies with comparator groups or that were designed as prevalence/cross-sectional or diagnostic accuracy studies.<sup>7–9</sup> Studies that reported obtaining informed consent or explicitly reported prospective enrollment by the authors were categorized as prospective. Transcontinental collaborative publications were identified by author affiliations. Reporting quality was assessed using the STROBE checklist.<sup>4</sup> Each STROBE item was assessed as 1 = reported, 0.5 = partly reported, or 0 = not reported. A complete reporting score (CRS) per publication was calculated by summing the total number of items divided by 22 (the total number of STROBE criteria). Scores by article section (introduction, methods, results, and conclusions) were also calculated.

### Statistical and Sensitivity Analysis

Categorical variables are expressed in counts and percentages. Distributions of continuous variables are summarized with means and SDs or medians and interquartile ranges. Agreement was calculated with an unweighted Cohen  $\kappa$ . Based on the goodness of fit, exponential and linear regression analyses were fit to test trends across time in the total number of VWI studies and analytic observational studies by year, respectively. The Shapiro-Wilks test was used to test normal distributions of CRS measures. CRS measures were calculated by a summary statistic (mean or median) based on the test for a normal distribution. The Kruskal-Wallis test assessed differences among CRS scores by continent. Two sensitivity analyses assessed the robustness of the results. The first sensitivity analysis considered fulfillment of STROBE items reported in footnotes, bylines, and different sections of the article. A second analysis was conducted by considering fulfillment of STROBE items that were “partly reported” in any part of the article, including footnotes and bylines. Publication bias was assessed using the likelihood ratio  $\chi^2$  test to compare the distributions of the intracranial vasculopathies of the included studies versus the excluded conference abstracts. SPSS Version 19 (IBM, Armonk, New York) was used for statistical analysis.

## RESULTS

### Search

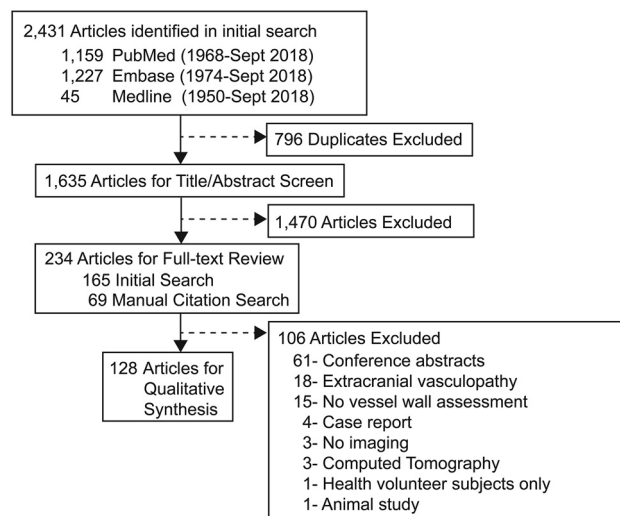
The search strategy identified 2431 publications, among which 1635 were screened by title/abstract ( $\kappa = 0.77$ ; 95% CI, 0.71–0.83;  $P < .01$ ). Of those, 234 articles were selected for full-text review ( $\kappa = 0.89$ ; 95% CI 0.82–0.96;  $P < .01$ ). Manual review of the citations of the included articles yielded 807 citations, which were further screened by title/abstract ( $\kappa = 0.73$ ; 95% CI, 0.52–0.93;  $P < .01$ ). Full data extraction for qualitative synthesis was performed on 128 articles identified from the initial and manual citation review (Fig 1; references in the On-line Appendix).

### Publication Trends

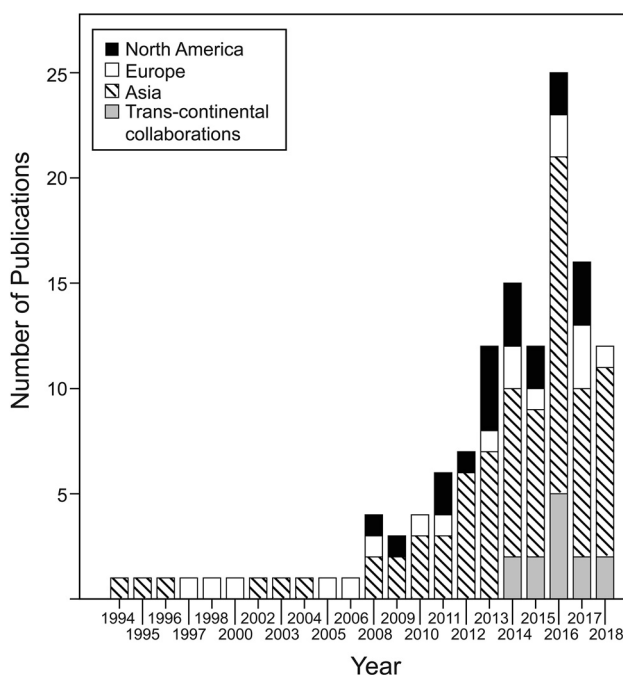
The first article evaluating intracranial vessel wall characteristics from this systematic review was reported in 1994 evaluating intramural hematomas in dissections.<sup>10</sup> The second publication was in 1995 and evaluated vessel walls for cerebral atherosclerosis.<sup>11</sup> An exponentially increasing trend in the number of VWI publications during the past 24 years was seen (Fig 2) ( $\beta = 0.14$ ; 95% CI, 0.11–0.17;  $P < .0001$ ). Asia published the highest number of publications (61%) during the 24 years, followed by North America ( $n = 19$ ) and Europe ( $n = 18$ ). In 2014, transcontinental collaborative publications emerged, composing 10% of the included publications. Asia was part of 92% of the transcontinental collaborations (Fig 3A), and 46% of the transcontinental collaborations were between Asia and North America.

Most investigations were solely federally funded (39%). Publications with mixed types of funding sources accounted for 21%, with the most common combination being federal and medical society sources (54%). No funding source was reported for 30% of all publications (Fig 3B).

Survey of studies focused on 1 vasculopathy revealed intracranial atherosclerotic disease (ICAD) to be the most commonly studied vasculopathy (49%,  $n = 62$ , references in the On-line



**FIG 1.** Systematic review of the data bases. From the initial data base search, 165 articles were identified for full-text review. Manual review of the citations of those 165 articles identified 807 citations that were further screened by title and abstract. This resulted in 69 articles for full-text review from the manual citation search. A total of 234 articles underwent full-text review, from which 128 articles met the predetermined inclusion and exclusion criteria.



**FIG 2.** Annual number of publications using vessel wall MR imaging.

Appendix), followed by arterial dissection (13%,  $n = 16$ ),<sup>10,12-26</sup> aneurysm (8%,  $n = 10$ ),<sup>27-36</sup> vasculitis (5%,  $n = 6$ ),<sup>37-42</sup> Moyamoya disease (3%,  $n = 4$ ),<sup>43-46</sup> postendovascular changes (2%,  $n = 3$ ),<sup>47-49</sup> and reversible cerebral vasoconstriction syndrome (1%,  $n = 1$ )<sup>50</sup> (Fig 3C). Among the 16 publications investigating arterial dissections, 11 used VWI<sup>12,14-18,22-26</sup> and the other 5 publications<sup>10,13,19-21</sup> assessed intramural hematoma signal characteristics on conventional MR imaging. Note that 21% of the studies examined  $\geq 2$  types of vasculopathies; a breakdown of the types of vasculopathies

studied among these publications is further illustrated in the pie-in-pie chart.

Publication bias was assessed by comparing the number of intracranial vasculopathy types that were included in this study with excluded conference abstracts; the comparison showed no significant difference (On-line Table 2,  $P = .95$ ).

### Study Designs

Case series composed 52% of the publications, and 48% were analytic observational study designs. There was a significant yearly increase in analytic observational studies since 2000 ( $\beta = 0.39$ ; 95% CI, 0.26–0.51;  $P < .0001$ ). Most studies were conducted with prospective subject enrollment (50%) compared with retrospective subject identification (44%). Examples of prospective case series include studies that obtained written informed consent to study circle of Willis cadaveric specimens and characterize intracranial atherosclerotic plaque components,<sup>51</sup> recruited 3 subjects to describe atherosclerosis enhancement characteristics by VWI,<sup>52</sup> and methodologic articles reporting interrater/intrater reliability<sup>53</sup> and scan-rescan reproducibility.<sup>54</sup>

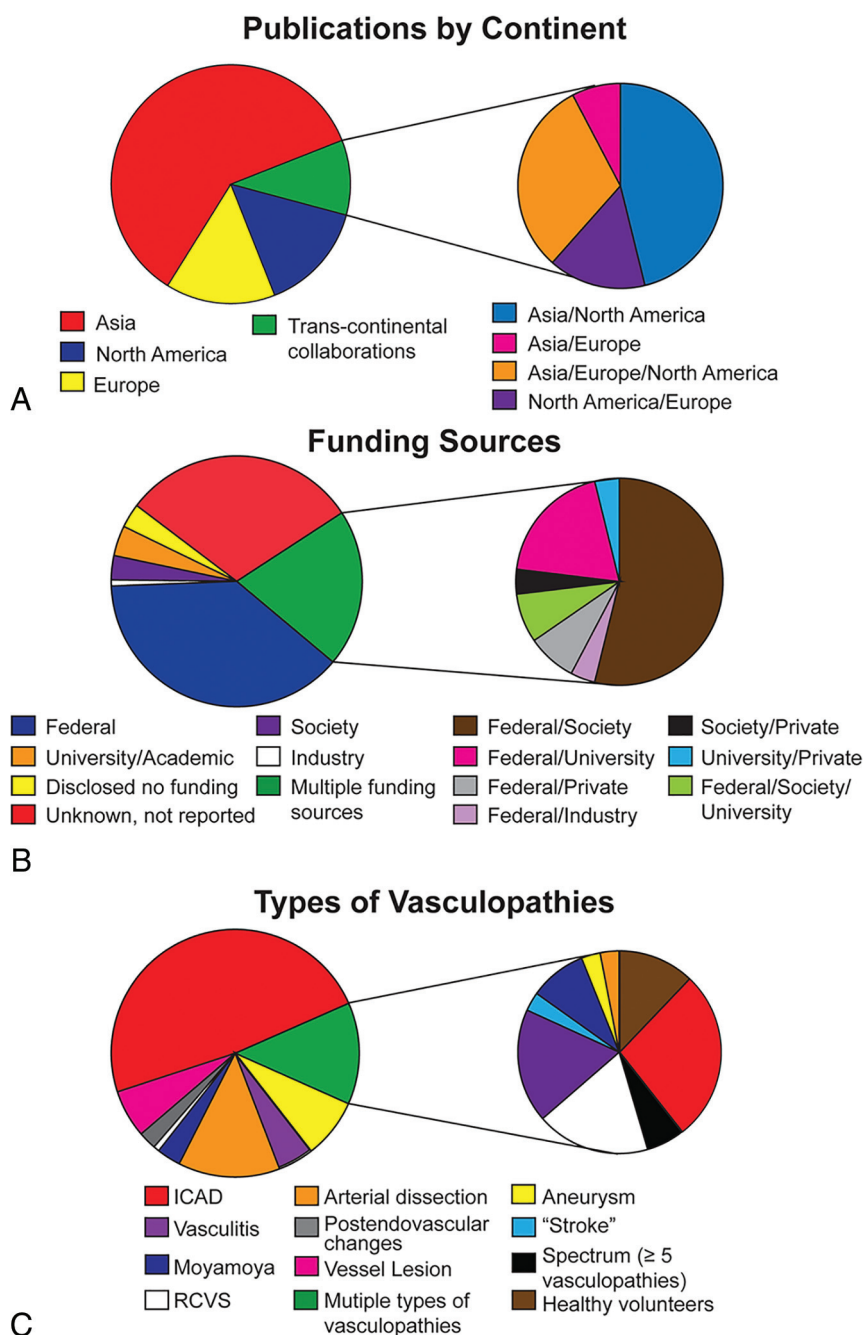
### STROBE Reporting Assessment

The 62 analytic observational studies were evaluated for reporting quality using the STROBE checklist (Table) ( $\kappa = 0.76$ ; 95% CI, 0.72–0.79;  $P < .001$ ). The mean CRS for all studies was  $0.64 \pm 0.10$ . The introduction section had the highest and the methods had the lowest scores. Transcontinental collaborative publications showed higher scores ( $\text{CRS}_{\text{all}} = 0.67 \pm 0.05$ ) compared with single-continent studies (Table) and multisite/single-continent collaborations ( $\text{CRS}_{\text{all}} = 0.63 \pm 0.12$ ), though these results did not reach statistical significance ( $P = .20$ ).

Two sensitivity analyses were performed that showed the same direction of the results but notably did not reach statistical significance. First, a sensitivity analysis evaluating each study for items reported in any part of the article, including footnotes and bylines, showed higher scores from transcontinental collaborations compared with single-continent studies ( $P = .30$ ). A second sensitivity analysis considered all partially reported criteria as fulfilling reporting and also showed higher CRS measures by transcontinental collaborations than North American and European studies. The studies from Asia had only marginally higher CRS measures ( $P = .27$ ) (On-line Table 3).

On-line Table 4 reports the mean score per STROBE item for the 62 articles and checklist descriptions. Items 1 and 22 were scored separately because they reflect title/abstract and funding reporting, respectively. Most studies provided an informative abstract but did not indicate the study design in the title (item 1) to fully meet the STROBE criterion, resulting in a score of  $0.52 \pm 0.13$ . Also, 70% of the studies did not disclose whether there was a funding source (item 22), resulting in a score of  $0.71 \pm 0.46$ . The 2 introduction section criteria, evaluating the reporting of the scientific background and rationale (item 2) and specific objectives or hypothesis (item 3), scored the highest among all sections.

The methods section included 9 criteria. No publication reported a sample size determination (item 10). Explicitly presenting key elements of the study (item 4) also scored low



**FIG 3.** Distribution of publications by funding source, continent and intracranial vasculopathy. A, Distribution of publications by continent is shown. Distribution of transcontinental collaborations is further elaborated to show 4 different groups of collaborating partners. B, Distribution of different funding sources and the combination of funding sources are shown. C, Distribution of studied intracranial vasculopathies are shown. RCVS indicates reversible cerebral vasoconstriction syndrome.

( $0.08 \pm 0.24$ ). Although 73% of the studies reported a prospective or retrospective subject enrollment method, few studies named the study design type.<sup>5</sup> Clearly defining outcomes, exposures, predictors, confounders, and diagnostic criteria (item 7) also had a low score ( $0.34 \pm 0.32$ ); for example, only 14% of the 43 publications studying ICAD reported diagnostic criteria for cardiovascular risk factors such as hypertension. The importance of reporting diagnostic criteria for hypertension is emphasized in light of the new 2017 American Heart Association classifications of hypertension and evolving definitions.<sup>55</sup>

Five criteria were included in the results section. Reporting of the study participants and information on exposures and potential confounders (item 14) was suboptimal ( $0.45 \pm 0.19$ ). Publications lacking information on confounders such as race/ethnicity were scored as partial reporting. Only 8 studies<sup>18,56-62</sup> reported race/ethnicity, among which 5 studies<sup>18,56-59</sup> reported the information in the discussion section as a limitation of generalizability. Twenty-four publications originated from Asia, were single-center studies, and did not report a description of ethnicity; in these studies, one could assume that all enrolled subjects were Asian but clarity in reporting could be strengthened.

In the discussion section, generalizability (item 21) scored the lowest ( $0.26 \pm 0.44$ ). Most studies were single-center studies (74.2%), but this was not commonly addressed as a limitation for external validity. A discussion on limitations and reporting direction/magnitude of potential bias (item 19) also scored

#### STROBE complete reporting scores<sup>a</sup>

	CRS <sub>All</sub>	CRS <sub>Introduction</sub>	CRS <sub>Methods</sub>	CRS <sub>Results</sub>	CRS <sub>Discussion</sub>
All ( $n = 62$ )	0.64 (0.10)	1.00 (0)	0.56 (0.22)	0.60 (0.20)	0.63 (0.25)
North America ( $n = 11$ )	0.62 (0.10)	1.00 (0)	0.52 (0.11)	0.56 (0.22)	0.69 (0.28)
Asia ( $n = 40$ )	0.65 (0.11)	1.00 (0)	0.61 (0.17)	0.65 (0.20)	0.63 (0.25)
Europe ( $n = 6$ )	0.58 (0.14)	1.00 (0)	0.42 (0.15)	0.60 (0.15)	0.63 (0.19)
Trans-continental collaborations ( $n = 5$ )	0.67 (0.05)	1.00 (0)	0.60 (0.07)	0.64 (0.11)	0.73 (0.10)

<sup>a</sup> CRS measures reported in means (SDs) or medians (interquartile range). Summary statistics were chosen on the basis of the test for normality.



poorly ( $0.55 \pm 0.24$ ), with most studies partially fulfilling this item due to an absence of a discussion on the direction and magnitude of the bias.

## DISCUSSION

The increasing trend in the number of VWI publications and more transcontinental collaborations during the past 24 years suggest the widespread interest in the diagnostic utility of VWI. Evaluation of the reporting quality of analytic observational studies using the STROBE checklist highlighted strengths and weaknesses in the current literature. Subgroup analyses showed that transcontinental collaborations yielded higher CRS measures compared with single-center/single-continent and multicenter/single-continent publications, suggesting an advantage for multicultural, diverse collaborative teams. Notably, the results did not reach significance, potentially due to the relatively small number of transcontinental publications.

A survey of the literature to date shows Asia as the leading contributor of VWI publications and ICAD to be the most commonly studied vasculopathy. Fewer VWI studies were identified evaluating arterial dissections, aneurysms, vasculitis, and Moyamoya disease. More effort is warranted to further understand the diagnostic utility of VWI in these less commonly studied intracranial vasculopathies.

Given that stroke is one of the leading causes of morbidity and mortality worldwide and a widespread public health problem, it is not surprising to see federal funding supporting many of the VWI investigations across all continents. Medical societies such as the Dutch Heart Foundation, American Society of Neuroradiology, Radiological Society of North America, and American Heart Association also emerged as common funding sources, showing societal missions to improve stroke outcomes. Nearly one-third of the studies did not disclose a funding source, reflecting either no funding source or funding that was not disclosed.

The availability of the STROBE guidelines has encouraged many research domains and medical specialties to improve reporting quality<sup>63,64</sup> and ultimately improve research reproducibility. Assessment of reporting quality of VWI publications has not yet been evaluated. Our results show a CRS of 0.64 for the 62 analytic observational VWI studies. The results of this study highlight areas where reporting of analytic observational studies are good, along with other areas where improvements are needed. In particular, there is a need for studies to improve the clear reporting of definitions of exposures, predictors, and potential confounders (item 7). The lack of clearly defined diagnostic criteria becomes important when, for example, guidelines are updated; in 2017, the American Heart Association changed the blood pressure guidelines, with some secondary analyses suggesting that the new classification correlates with different prevalence rates and outcomes.<sup>65,66</sup>

Study size calculations (item 10) were not reported in any study. Sample size estimates are informative because they indicate the magnitude of the aimed effect and address whether there were challenges with recruitment due to drop-out or attrition bias.<sup>5</sup>

Additional areas of weakness in reporting included the description of study design (item 4) and settings and locations (item 5). Reporting a prospective or retrospective enrollment design only is insufficient. For example, a cross sectional study could assess imaging findings on a subject at 1 time point using a prospective enrollment design or the subject could be identified retrospectively from a registry.

In the discussion, reporting the generalizability or external validity (item 21) of the results was also noted to be a weakness. Generalizability is evaluating the extent to which the results of the publication can be applied to other settings and populations and is important for the reader to see whether the results are applicable to his or her own practice setting.

Analysis of reporting quality by continent showed that transcontinental collaborations had higher CRS measures (Table). Collaborations are encouraged for the cross-pollination of ideas, to increase recruitment, or to enhance generalizability by coordinating a multisite study, among other advantages.<sup>67</sup> Our findings suggest an additional advantage of higher reporting quality. Multilingual authors and increased diversity within teams from different continents may be possible explanations for this finding.

This systematic review has some limitations. First, neuro-radiology research often reports innovative techniques and drives cutting-edge methods that are not tested as part of larger epidemiologic studies. These technologic-advancement publications are typically of smaller scale and are “proof of concept” studies that are designed differently but may have larger impact. The STROBE guidelines do not always fit this radiology research framework. However, as an assessment for completeness of reporting with consistency in evaluation by 2 independent raters, the results provide at least a basis of reporting quality among VWI publications. Second, classifying studies as case series or analytic observational studies was often challenging due to the heterogeneity in study designs. Many of the included studies did not fit traditional epidemiologic study designs. This challenge has been addressed in other systematic review methodologies, and an algorithm has been tested to appropriately classify study designs for systematic reviews. We based our classification as descriptive (case series) or analytic observational studies following a simplified version of this algorithm.<sup>6</sup> Third, methodologic quality was not assessed because the aim was to identify trends in VWI publications rather than conduct a quantitative meta-analysis. Instead, an assessment of reporting quality was conducted to highlight areas for improvement.

Fourth, use of the STROBE checklist is inconsistently recommended in author guidelines among journals, which could be a confounder in our analysis. Notably, some journals have their own checklists requiring a statement on data-sharing and open-source availability, which also improve transparency of the conducted research. As a future direction, an assessment of the journals can be conducted to assess CRS measures by journal Impact Factor as well as explicit author instructions to follow the STROBE checklist. Finally, the CRS was calculated using the STROBE guidelines, and items were scored by section as determined by the STROBE checklist. Studies that did not report items

in the correct section per the STROBE guidelines were not considered as fulfilling the criteria. This method may underestimate CRS measures. To account for this issue, we performed a sensitivity analysis with items scored as reported if present in any part of the article, including footnotes and author bylines. This sensitivity analysis yielded similar conclusions. A second sensitivity analysis considering partially reported items as completely reported showed a similar direction of the results.

## CONCLUSIONS

We systematically assess VWI publications to identify trends and assess reporting quality. Our results show that ICAD is the most common intracranial vasculopathy studied. The utility of VWI for ICAD, and for other types of intracranial vasculopathies will likely benefit from additional rigorous studies. We also highlight deficiencies in the reporting of analytic observational VWI studies. Transcontinental collaborative effort yielded a higher reporting quality, though this result did not reach statistical significance. Nonetheless, there may be advantages to diverse and multilingual cross-cultural teams. More consistent adherence to STROBE guidelines should improve transparency and maximize effective synthesis and clinical translation of findings for future studies.

Disclosures: Jae W. Song—RELATED: Grant: Radiological Society of North America, Comments: Radiological Society of North America Scholar Grant.\* Walter R. Witschey—RELATED: Grant: National Institutes of Health.\* Scott E. Kasner—UNRELATED: Consultancy: Bristol Myers Squibb, Bayer, Boehringer Ingelheim, Medtronic; Expert testimony: Janssen; Grants/Grants Pending: BMS, Bayer, Medtronic, WL Gore\*; Royalties: UpToDate. Laurie A. Loevner—UNRELATED: Board Membership: American Society of Neuroradiology, Foundation of the American Society of Neuroradiology, Comments: Co-Chair of the Foundation of the American Society of Neuroradiology, Board of Trustees, Board of Directors. \*Money paid to the institution.

## REFERENCES

1. Arenillas JF, Dieleman N, Bos D. Intracranial arterial wall imaging: techniques, clinical applicability, and future perspectives. *Int J Stroke* 2019;14:564–73 [CrossRef Medline](#)
2. Lindenholtz A, van der Kolk AG, Zwanenburg JJM, et al. The use and pitfalls of intracranial vessel wall imaging: how we do it. *Radiology* 2018;286:12–28 [CrossRef Medline](#)
3. Mandell DM, Mossa-Basha M, Qiao Y, et al. Intracranial vessel wall MRI: principles and expert consensus recommendations of the American Society of Neuroradiology. *AJNR Am J Neuroradiol* 2017;38:218–29 [CrossRef Medline](#)
4. von Elm E, Altman DG, Egger M, et al. The strengthening the reporting of observational studies in epidemiology (STROBE) statement: guidelines for reporting observational studies. *Lancet* 2007;370:1453–57 [CrossRef Medline](#)
5. Vandenbroucke JP, von Elm E, Altman DG, et al. Strengthening the reporting of observational studies (STROBE): explanation and elaboration. *Epidemiology* 2007;18:805–35 [CrossRef Medline](#)
6. Seo HJ, Kim SY, Lee YJ, et al. A newly developed tool for classifying study designs in systematic reviews of interventions and exposures showed substantial reliability and validity. *J Clin Epidemiol* 2016;70:200–25 [CrossRef Medline](#)
7. Song JW, Chung KC. Observational studies: cohort and case-control studies. *Plast Reconstr Surg* 2010;126:2234–42 [CrossRef Medline](#)
8. Grimes DA, Schulz KF. An overview of clinical research: the lay of the land. *Lancet* 2002;359:57–61 [CrossRef Medline](#)

9. Rutjes AW, Reitsma JB, Vandenbroucke JP, et al. Case-control and two-gate designs in diagnostic accuracy studies. *Clin Chem* 2005;51:1335–41 [CrossRef Medline](#)
10. Kitanaka C, Tanaka J, Kuwahara M, et al. Magnetic resonance imaging study of intracranial vertebrobasilar artery dissections. *Stroke* 1994;25:571–75 [CrossRef Medline](#)
11. Aoki S, Shirouzu I, Sasaki Y, et al. Enhancement of the intracranial arterial wall at MR imaging: relationship to cerebral atherosclerosis. *Radiology* 1995;194:477–81 [CrossRef Medline](#)
12. Natori T, Sasaki M, Miyoshi M, et al. Detection of vessel wall lesions in spontaneous symptomatic vertebrobasilar artery dissection using T1-weighted 3-dimensional imaging. *J Stroke Cerebrovasc Dis* 2014;23:2419–24 [CrossRef Medline](#)
13. Urbach H, Meyer-Lindenberg A, Bendszus M, et al. Dissections of the basilar artery [in German]. *Rofa* 1998;169:170–74 [CrossRef Medline](#)
14. Ishitsuka K, Sakaki Y, Sakai S, et al. Diagnosis and follow-up of posterior inferior cerebellar artery dissection complicated with ischemic stroke assisted by T1-VISTA: a report of two cases. *BMC Neurol* 2016;16:121 [CrossRef Medline](#)
15. Sakurai K, Miura T, Sagisaka T, et al. Evaluation of luminal and vessel wall abnormalities in subacute and other stages of intracranial vertebrobasilar artery dissections using the volume isotropic turbo-spin-echo acquisition (VISTA) sequence: a preliminary study. *J Neuroradiol* 2013;40:19–28 [CrossRef Medline](#)
16. Choi JW, Han M, Hong JM, et al. Feasibility of improved motion-sensitized driven-equilibrium (iMSDE) prepared 3D T1-weighted imaging in the diagnosis of vertebrobasilar artery dissection. *J Neuroradiol* 2018;45:186–91 [CrossRef Medline](#)
17. Wang Y, Lou X, Li Y, et al. Imaging investigation of intracranial arterial dissecting aneurysms by using 3 T high-resolution MRI and DSA: from the interventional neuroradiologists' view. *Acta Neurochir (Wien)* 2014;156:515–25 [CrossRef Medline](#)
18. Kwon JY, Kim N, Suh DC, et al. Intracranial and extracranial arterial dissection presenting with ischemic stroke: lesion location and stroke mechanism. *J Neurol Sci* 2015;358:371–76 [CrossRef Medline](#)
19. Hirai T, Korogi Y, Murata Y, et al. Intracranial artery dissections: serial evaluation with MR imaging, MR angiography, and source images of MR angiography. *Radiat Med* 2003;21:86–93 [Medline](#)
20. Kim T, Choi HS, Koo J, et al. Intramural hematoma detection by susceptibility-weighted imaging in intracranial vertebral artery dissection. *Cerebrovasc Dis* 2013;36:292–98 [CrossRef Medline](#)
21. Mascalchi M, Bianchi MC, Mangiafico S, et al. MRI and MR angiography of vertebral artery dissection. *Neuroradiology* 1997;39:329–40 [CrossRef Medline](#)
22. Takano K, Yamashita S, Takemoto K, et al. MRI of intracranial vertebral artery dissection: evaluation of intramural haematoma using a black blood, variable-flip-angle 3D turbo spin-echo sequence. *Neuroradiology* 2013;55:845–51 [CrossRef Medline](#)
23. Park KJ, Jung SC, Kim HS, et al. Multi-contrast high-resolution magnetic resonance findings of spontaneous and unruptured intracranial vertebral artery dissection: qualitative and quantitative analysis according to stages. *Cerebrovasc Dis* 2016;42:23–31 [CrossRef Medline](#)
24. Jung SC, Kim HS, Choi C, et al. Spontaneous and unruptured chronic intracranial artery dissection: high-resolution magnetic resonance imaging findings. *Clin Neuroradiol* 2018;28:171–81 [CrossRef Medline](#)
25. Yun SY, Heo YJ, Jeong HW, et al. Spontaneous intracranial vertebral artery dissection with acute ischemic stroke: high-resolution magnetic resonance imaging findings. *Neuroradiol J* 2018;31:262–69 [CrossRef Medline](#)
26. Madokoro Y, Sakurai K, Kato D, et al. Utility of T1- and T2-weighted high-resolution vessel wall imaging for the diagnosis and follow up of isolated posterior inferior cerebellar artery dissection with ischemic stroke: report of 4 cases and review of the

- literature. *J Stroke Cerebrovasc Dis* 2017;26:2645–51 [CrossRef Medline](#)
27. Mizutani T. A fatal, chronically growing basilar artery: a new type of dissecting aneurysm. *J Neurosurg* 1996;84:962–71 [CrossRef Medline](#)
  28. Edjlali M, Gentric J, Régent-Rodriguez C, et al. Does aneurysmal wall enhancement on vessel wall MRI help to distinguish stable from unstable intracranial aneurysms? *Stroke* 2014;45:3704–06 [CrossRef Medline](#)
  29. Park JK, Lee CS, Sim KB, et al. Imaging of the walls of saccular cerebral aneurysms with double inversion recovery black-blood sequence. *J Magn Reson Imaging* 2009;30:1179–83 [CrossRef Medline](#)
  30. Boussel L, Wintermark M, Martin A, et al. Monitoring serial change in the lumen and outer wall of vertebrobasilar aneurysms. *AJNR Am J Neuroradiol* 2008;29:259–64 [CrossRef Medline](#)
  31. Martin AJ, Hettis SW, Dillon WP, et al. MR imaging of partially thrombosed cerebral aneurysms: characteristics and evolution. *AJNR Am J Neuroradiol* 2011;32:346–51 [CrossRef Medline](#)
  32. Omodaka S, Endo H, Niizuma K, et al. Quantitative assessment of circumferential enhancement along the wall of cerebral aneurysms using MR imaging. *AJNR Am J Neuroradiol* 2016;37:1262–66 [CrossRef Medline](#)
  33. Blankena R, Kleinloog R, Verweij BH, et al. Thinner regions of intracranial aneurysm wall correlate with regions of higher wall shear stress: a 7T MRI study. *AJNR Am J Neuroradiol* 2016;37:1310–17 [CrossRef Medline](#)
  34. Matouk CC, Mandell DM, Günel M, et al. Vessel wall magnetic resonance imaging identifies the site of rupture in patients with multiple intracranial aneurysms: proof of principle. *Neurosurgery* 2013;72:492–96 [CrossRef Medline](#)
  35. Kleinloog R, Korkmaz E, Zwanenburg JJM, et al. Visualization of the aneurysm wall: a 7.0-Tesla magnetic resonance imaging study. *Neurosurgery* 2014;75:614–22 [CrossRef Medline](#)
  36. Nagahata S, Nagahata M, Obara M, et al. Wall enhancement of the intracranial aneurysms revealed by magnetic resonance vessel wall imaging using three-dimensional turbo spin-echo sequence with motion-sensitized driven-equilibrium: a sign of ruptured aneurysm? *Clin Neuroradiol* 2016;26:277–83 [CrossRef Medline](#)
  37. Cheng-Ching E, Jones S, Hui FK, et al. High-resolution MRI vessel wall imaging in varicella zoster virus vasculopathy. *J Neurol Sci* 2015;351:168–73 [CrossRef Medline](#)
  38. Ide S, Kakeda S, Miyata M, et al. Intracranial vessel wall lesions in patients with systemic lupus erythematosus: vessel wall lesions in SLE patients. *J Magn Reson Imaging* 2018;48:1237–46 [CrossRef Medline](#)
  39. Berkefeld J, Enzensberger W, Lanfermann H. MRI in human immunodeficiency virus-associated cerebral vasculitis. *Neuroradiology* 2000;42:526–28 [CrossRef Medline](#)
  40. Thaler C, Kaufmann-Bühler A, Gansukh T, et al. Neuroradiologic characteristics of primary angiitis of the central nervous system according to the affected vessel size. *Clin Neuroradiol* 2019;29:37–44 [CrossRef Medline](#)
  41. Schuster S, Bachmann H, Thom V, et al. Subtypes of primary angiitis of the CNS identified by MRI patterns reflect the size of affected vessels. *J Neurol Neurosurg Psychiatry* 2017;88:749–55 [CrossRef Medline](#)
  42. Küker W, Gaertner S, Nagele T, et al. Vessel wall contrast enhancement: a diagnostic sign of cerebral vasculitis. *Cerebrovasc Dis* 2008;26:23–29 [CrossRef Medline](#)
  43. Han C, Li M, Xu Y, et al. Adult Moyamoya-atherosclerosis syndrome: clinical and vessel wall imaging features. *J Neurol Sci* 2016;369:181–84 [CrossRef Medline](#)
  44. Muraoka S, Araki Y, Taoka T, et al. Prediction of intracranial arterial stenosis progression in patients with Moyamoya vasculopathy: contrast-enhanced high-resolution magnetic resonance vessel wall imaging. *World Neurosurg* 2018;116:e1114–21 [CrossRef Medline](#)
  45. Yu L, He H, Zhao J, et al. More precise imaging analysis and diagnosis of Moyamoya disease and Moyamoya syndrome using high-resolution magnetic resonance imaging. *World Neurosurg* 2016; 96:252–60 [CrossRef Medline](#)
  46. Wang M, Yang Y, Zhou F, et al. The contrast enhancement of intracranial arterial wall on high-resolution MRI and its clinical relevance in patients with Moyamoya vasculopathy. *Sci Rep* 2017;7:44264 [CrossRef Medline](#)
  47. Seo W, Oh K, Suh S, et al. Clinical significance of wall changes after recanalization therapy in acute stroke: high-resolution vessel wall imaging. *Stroke* 2017;48:1077–80 [CrossRef Medline](#)
  48. Power S, Matouk C, Casaubon LK, et al. Vessel wall magnetic resonance imaging in acute ischemic stroke: effects of embolism and mechanical thrombectomy on the arterial wall. *Stroke* 2014;45: 2330–34 [CrossRef Medline](#)
  49. Abraham P, Scott Pannell J, Santiago-Dieppa D, et al. Vessel wall signal enhancement on 3-T MRI in acute stroke patients after stent retriever thrombectomy. *Neurosurg Focus* 2017;42:E20 [CrossRef Medline](#)
  50. Chen C, Chen S, Fuh J, et al. Vascular wall imaging in reversible cerebral vasoconstriction syndrome: a 3-T contrast-enhanced MRI study. *J Headache Pain* 2018;19:74 [CrossRef Medline](#)
  51. Jiang Y, Zhu C, Peng W, et al. Ex-vivo imaging and plaque type classification of intracranial atherosclerotic plaque using high resolution MRI. *Atherosclerosis* 2016;249:10–16 [CrossRef Medline](#)
  52. Jiang W, Yu W, Ma N, et al. High resolution MRI guided endovascular intervention of basilar artery disease. *J Neurointerv Surg* 2011;3:375–78 [CrossRef Medline](#)
  53. Ma N, Jiang WJ, Lou X, et al. Arterial remodeling of advanced basilar atherosclerosis: a 3-Tesla MRI study. *Neurology* 2010;75:253–58 [CrossRef Medline](#)
  54. Zhang X, Zhu C, Peng W, et al. Scan-rescan reproducibility of high-resolution magnetic resonance imaging of atherosclerotic plaque in the middle cerebral artery. *PLoS One* 2015;10:e0134913 [CrossRef Medline](#)
  55. Whelton PK, Carey RM, Aronow WS, et al. 2017 ACC/AHA/AAPA/ABC/ACPM/AGS/APhA/ASH/ASPC/NMA/PCNA guideline for the prevention, detection, evaluation, and management of high blood pressure in adults: executive summary—a Report of the American College of Cardiology/American Heart Association Task Force on Clinical Practice Guidelines. *Hypertension* 2018;71: 1269–324 [CrossRef Medline](#)
  56. Xu W, Li M, Niu J, et al. Intracranial artery atherosclerosis and lumen dilation in cerebral small-vessel diseases: a high-resolution MRI study. *CNS Neurosci Ther* 2014;20:364–67 [CrossRef Medline](#)
  57. Kim J, Jung K, Sohn C, et al. Intracranial plaque enhancement from high resolution vessel wall magnetic resonance imaging predicts stroke recurrence. *Int J Stroke* 2016;11:171–79 [CrossRef Medline](#)
  58. Kim YS, Lim S, Oh K, et al. The advantage of high-resolution MRI in evaluating basilar plaques: a comparison study with MRA. *Atherosclerosis* 2012;224:411–16 [CrossRef Medline](#)
  59. Ahn S, Lee J, Kim Y, et al. Isolated MCA disease in patients without significant atherosclerotic risk factors: a high-resolution magnetic resonance imaging study. *Stroke* 2015;46:697–703 [CrossRef Medline](#)
  60. Niu P, Yu Y, Zhou H, et al. Vessel wall differences between middle cerebral artery and basilar artery plaques on magnetic resonance imaging. *Sci Rep* 2016;6:38534 [CrossRef Medline](#)
  61. Dieleman N, Yang W, Abrigo JM, et al. Magnetic resonance imaging of plaque morphology, burden, and distribution in patients with symptomatic middle cerebral artery stenosis. *Stroke* 2016; 47:1797–802 [CrossRef Medline](#)
  62. Qiao Y, Anwar Z, Intrapromkul J, et al. Patterns and implications of intracranial arterial remodeling in stroke patients. *Stroke* 2016;47:434–40 [CrossRef Medline](#)



63. Langan S, Schmitt J, Coenraads PJ, et al. **The reporting of observational research studies in dermatology journals: a literature-based study.** *Arch Dermatol* 2010;146:534–41 [CrossRef Medline](#)
64. Fung AE, Palanki R, Bakri SJ, et al. **Applying the CONSORT and STROBE statements to evaluate the reporting quality of neovascular age-related macular degeneration studies.** *Ophthalmology* 2009;116:286–96 [CrossRef Medline](#)
65. Papaioannou TG, Soulis D, Tousoulis D. **Reversibility of hypertension-induced subclinical vascular changes: do the new ACC/AHA 2017 blood pressure guidelines and heart rate changes make a difference?** *J Clin Hypertens (Greenwich)* 2019; 21:1242 [CrossRef](#)
66. Muntner P, Carey RM, Gidding S, et al. **Potential US population impact of the 2017 ACC/AHA high blood pressure guideline.** *Circulation* 2018;137:109–18 [CrossRef Medline](#)
67. Hall KL, Vogel AL, Huang GC, et al. **The science of team science: a review of the empirical evidence and research gaps on collaboration in science.** *Am Psychol* 2018;73:532–48 [CrossRef Medline](#)