

Generic Contrast Agents

Our portfolio is growing to serve you better. Now you have a *choice*.



[VIEW CATALOG](#)

AJNR

Prognostic Accuracy of Fetal MRI in Predicting Postnatal Neurodevelopmental Outcome

M. Wilson, K. Muir, D. Reddy, R. Webster, C. Kapoor and E. Miller

This information is current as of May 23, 2025.

AJNR Am J Neuroradiol 2020, 41 (11) 2146-2154

doi: <https://doi.org/10.3174/ajnr.A6770>

<http://www.ajnr.org/content/41/11/2146>

Prognostic Accuracy of Fetal MRI in Predicting Postnatal Neurodevelopmental Outcome

 M. Wilson,  K. Muir,  D. Reddy,  R. Webster,  C. Kapoor, and  E. Miller



ABSTRACT

BACKGROUND AND PURPOSE: The superior diagnostic accuracy of fetal MR imaging in detecting fetal brain abnormalities has been previously demonstrated; however, the ability of fetal MR imaging to prognosticate postnatal outcome is not well-studied. We performed a retrospective analysis to determine the prognostic accuracy of fetal MR imaging in predicting postnatal neurodevelopmental outcome.

MATERIALS AND METHODS: We identified all fetal MR imaging performed at the Children's Hospital of Eastern Ontario during a 10-year period and assessed agreement between prenatal prognosis and postnatal outcome. Prenatal prognosis was determined by a pediatric neurologist who reviewed the fetal MR imaging report and categorized each pregnancy as having a favorable, indeterminate, or poor prognosis. Assessment of postnatal neurodevelopmental outcome was made solely on the basis of the child's Gross Motor Function Classification System score and whether the child developed epilepsy. Postnatal outcome was categorized as favorable, intermediate, or poor. We also assessed the diagnostic accuracy of fetal MR imaging by comparing prenatal and postnatal imaging diagnoses.

RESULTS: We reviewed 145 fetal MR images: 114 were included in the assessment of diagnostic accuracy, and 104 were included in the assessment of prognostic accuracy. There was 93.0% agreement between prenatal and postnatal imaging diagnoses. Prognosis was favorable in 44.2%, indeterminate in 50.0%, and poor in 5.8% of pregnancies. There was 93.5% agreement between a favorable prenatal prognosis and a favorable postnatal outcome.

CONCLUSIONS: A favorable prenatal prognosis is highly predictive of a favorable postnatal outcome. Further studies are required to better understand the role of fetal MR imaging in prognosticating postnatal development, particularly in pregnancies with indeterminate and poor prognoses.

ABBREVIATIONS: FeMRI = fetal MRI; GA = gestational age; GMFCS = Gross Motor Function Classification System; VM = ventriculomegaly

Fetal MR imaging (feMRI) is emerging as an important supplement to ultrasound in pregnancy. Many studies have demonstrated that feMRI provides superior diagnostic accuracy to antenatal ultrasound, with postnatal imaging findings used as the outcome reference diagnosis.¹⁻⁴ The role of feMRI in prognosticating the neurodevelopmental outcome of the child, however, has not been thoroughly investigated. Until recently, there have been only scattered studies, limited to mostly studies of cases of

isolated ventriculomegaly (VM) and posterior fossa abnormalities, which have assessed the role of feMRI in predicting postnatal outcome.⁵⁻⁸ The Magnetic Resonance Imaging to Enhance the Diagnosis of Fetal Developmental Brain Abnormalities in Utero (MERIDIAN) study is a large multicenter prospective study that assessed the utility of feMRI in diagnosing fetal brain abnormalities.⁹ One component of this study, published in 2019, assessed the prognostic accuracy of feMRI versus ultrasound in predicting postnatal neurodevelopment.¹⁰ The authors concluded that neither feMRI nor ultrasound was able to accurately predict abnormal development, but they did report that feMRI was better than ultrasound at ruling out abnormal development. While the MERIDIAN study is very robust, it is currently the only study to date to assess concordance between feMRI-based prognosis and postnatal outcome; thus, further studies are required. We therefore retrospectively assessed concordance between the prognosis

Received April 30, 2020; accepted after revision July 6.

From the Departments of Medical Imaging (M.W., C.K., E.M.) and Pediatric Neurology (K.M.) and Research Institute (D.R., R.W.), Children's Hospital of Eastern Ontario, University of Ottawa, Ottawa, Ontario, Canada; and Department of Neurology (M.W.), Beth Israel Deaconess Medical Center, Harvard Medical School, Boston, Massachusetts.

Please address correspondence to Elka Miller, MD, FRCPC, Department of Medical Imaging, CHEO, University of Ottawa, 401 Smyth Rd, Ottawa, ON, Canada, K1H 8L1; e-mail: EMiller@cheo.on.ca

<http://dx.doi.org/10.3174/ajnr.A6770>

of the fetal brain based on prenatal MR imaging and the neurodevelopmental outcome of the child. Additionally, we measured the diagnostic accuracy of feMRI with an assessment of concordance between prenatal diagnosis by feMRI and the postnatal imaging diagnosis.

MATERIALS AND METHODS

Demographic Data

This retrospective study was approved by the institutional review board of Children's Hospital of Eastern Ontario, Canada. All referrals for feMRI followed a dedicated fetal neurosonographic study. No written informed consent was obtained at the Medical Imaging Department, but feMRI requisitions were discussed with a multidisciplinary team before booking the MR imaging, as per departmental practice. A search of the Medical Imaging Department data base was performed to identify feMRI studies performed with a 3T system (Magnetom Skyra; Siemens) and a 1.5T MR imaging system (Signa HD; GE Healthcare) from January 1, 2008, to November 30, 2018. We examined the final radiology report of all the feMRIs identified during this time and included only those that had dedicated imaging of the fetal brain. A total of 145 pregnancies with at least 1 feMRI scan were found. In the assessment of diagnostic accuracy, we excluded cases that did not have postnatal imaging ($n = 31$).

In cases of termination of pregnancy or fetal death, we reviewed postmortem imaging, if available. In the assessment of prognostic accuracy, patients were excluded if they lacked sufficient documented postnatal clinical follow-up to assess the postnatal neurodevelopmental outcome (ie, there was no postnatal clinical follow-up or there was follow-up but the Gross Motor Function Classification System [GMFCS; <https://cerebralpalsy.org.au/our-research/about-cerebral-palsy/what-is-cerebral-palsy/severity-of-cerebral-palsy/gross-motor-function-classification-system/>]) score and epilepsy status could not be determined ($n = 36$) or if there was termination of pregnancy ($n = 5$) because the clinical postnatal assessment could not be performed. In pregnancies with multiple feMRIs, we included only the feMRI performed at the latest gestational age (GA). For assessments of both diagnostic and prognostic accuracy of feMRI, we repeated our analyses after dividing patients into 2 groups, $GA < 25$ weeks and $GA \geq 25$ weeks, because decisions regarding termination of pregnancy in our institution are preferable earlier during the second trimester.

Image Analysis

For assessment of the diagnostic accuracy between feMRI and postnatal imaging, each of the fetal MR imaging report impressions was reviewed by a medical student (M.W.) and compared with the final radiology impression from the postnatal MR imaging brain report or, alternatively, if a postnatal MR imaging was not performed, the postnatal ultrasound brain report. For each pregnancy, concordance was reported as the following: 1) agreement (comparable results) between prenatal and postnatal final diagnosis, or 2) disagreement between the prenatal and postnatal final diagnosis.

Cases that were initially deemed to have disagreement between prenatal and postnatal diagnoses underwent further review by a

pediatric neuroradiologist (E.M., 19 years of experience in fetal imaging), which included an examination of both the prenatal MR imaging and postnatal images and associated reports. The initial assessment of discordance of the case was amended if the radiologist determined that there was actually agreement between the prenatal and postnatal diagnoses.

The fetal MR imaging reports were reviewed (M.W.) to determine the predominant type of brain abnormality of each fetus. Each fetal MR imaging of the brain was classified as one of the following: VM (mild, moderate, or severe), corpus callosum abnormalities, posterior fossa abnormalities, sulcation/migration, space-occupying lesion, vascular anomaly, hemorrhage, or normal brain. When there was >1 brain abnormality identified, we reported the most severe abnormality.

Assessment of Prenatal Prognosis

Prenatal prognosis was determined by a pediatric neurologist (K.M., with 1 year of experience as an attending pediatric neurologist) who reviewed all feMRI reports and categorized each pregnancy as having either a favorable, indeterminate, or poor prognosis based on her clinical experience, to replicate what would occur in clinical practice. The neurologist was blinded to postnatal outcome. For a small number of cases in which the feMRI findings were difficult to interpret, the neurologist received input from the radiologist, again replicating what would occur in clinical practice. When available ($n = 36$), prenatal consult notes produced by fetal-maternal medicine, genetics, and neurology were examined to verify that the prognosis provided by our neurologist was concordant with the prognosis provided by experts at the time of pregnancy.

Assessment of Postnatal Outcome

Postnatal neurodevelopmental status was assessed by reviewing the clinical notes of the children corresponding to the pregnancies included in the study. This assessment was performed by a pediatric neurologist (K.M.) and a medical student (M.W.) who were blinded to the prenatal prognosis of the child. The most recent report in the child's medical history to document gross motor function and seizure status was reviewed. Reports produced before 12 months of age were not reviewed. Reports produced by neurologists and geneticists were prioritized. If the reports produced by these specialists did not provide sufficient information to assess neurodevelopmental status or were non-existent, we then reviewed reports produced by other allied health professionals. If after review of all available medical reports, there was insufficient information to grade the neurodevelopmental outcome, then the patient was excluded.

For each child, the postnatal neurodevelopmental outcome was categorized as either favorable, intermediate, or poor. The postnatal outcome was determined by a combination of the following: gross motor function measured using the GMFCS score¹¹ of the child and the presence or absence of epilepsy. For GMFCS, a score of either 0 or I was considered favorable, a score of either II or III was considered intermediate, and a score of IV or V was considered poor. For epilepsy, having no diagnosis of epilepsy was considered favorable, a diagnosis of epilepsy controlled by medication was considered intermediate, and a diagnosis of intractable epilepsy (failing to respond to 2 antiepileptic drugs) was considered

Table 1: Characteristics of participants included in image analysis

Characteristic	All GA (n = 114)	GA <25 Weeks (n = 56)	GA ≥25 Weeks (n = 58)
GA at fetal MR imaging (range) (median) (IQR) (wk)	19.00–39.43 (25.9 [21.9–32.3])	19.00–24.43 (21.8 [21.0–23.1])	25.86–39.43 (32.2 [29.1–34.1])
Maternal age at fetal MR imaging (range) (median) (IQR) (yr)	16.00–41.00 (31.0 [28.0–34.0])	16.00–41.00 (31.0 [28.8–35.0])	17.00–41.00 (31.0 [27.2–34.0])
Brain region (No.) (%)			
Ventriculomegaly	39 (34.2%)	20 (35.7%)	19 (32.8%)
Mild	23 (21.9%)	14 (25.0%)	9 (15.5%)
Moderate	7 (4.4%)	4 (3.6%)	3 (5.1%)
Severe	9 (7.9%)	2 (3.6%)	7 (12.1%)
Posterior fossa	26 (22.8%)	12 (21.4%)	14 (24.1%)
Corpus callosum	13 (11.4%)	3 (5.4%)	10 (17.2%)
Sulcation/migration	15 (13.2%)	9 (16.1%)	6 (10.3%)
Normal brain	15 (13.2%)	11 (19.6%)	4 (6.9%)
Space-occupying lesion	4 (3.5%)	1 (1.8%)	3 (5.2%)
Vascular anomaly	1 (0.9%)	0 (0.0%)	1 (1.7%)
Hemorrhage	1 (0.9%)	0 (0.0%)	1 (1.7%)

Note:—IQR indicates interquartile range.

Table 2: Image analysis—concordance between fetal MR imaging and postnatal imaging

	No. (%)	GA <25 Weeks (No.) (%)	GA ≥25 Weeks (No.) (%)
Agreement	106 (93.0%)	50 (89.3%)	56 (96.6%)
Disagreement	8 (7.0%)	6 (10.7%)	2 (3.4%)

poor. The overall neurodevelopmental outcome of the child was reported as the least favorable outcome between the GMFCS and epilepsy scores. Death due to a brain abnormality in the postnatal period and stillbirth were also considered a poor outcome. Researchers were blinded to the prenatal prognosis.

An overall assessment of concordance was made by comparing the prenatal prognosis with the neurodevelopmental outcome of the child. Additionally, we specifically tested concordance between the prenatal prognosis and the postnatal development of epilepsy in all children who survived to at least 1 year of age.

RESULTS

Image Analysis

Of 145 patients in the study sample who underwent fMRI, 31 were removed from the image analysis because they did not have any documented postnatal imaging. For the group of 114 patients included in this analysis, the gestational age range was 19.0–39.4 weeks (median, 25.9 weeks; interquartile range, 21.9–32.3 weeks). The maternal age range was 16–41 years (median, 31 years; interquartile range, 28–34 years). In 15.8% (18/114) of pregnancies, there were multiple brain abnormalities noted on fMRI. Table 1 summarizes the participants' characteristics and abnormalities found on fMRI. There was agreement between the prenatal diagnosis by fMRI and the postnatal imaging diagnosis in 93% (106/114) of cases (Table 2). After the prenatal and postnatal imaging reports were reviewed by the medical student, there were 9 cases of disagreement between prenatal and postnatal imaging; however, after these 9 cases were reviewed by the radiologist, it was determined that there was disagreement in only 8 cases. A list of the 8 cases in which there was disagreement between prenatal and postnatal imaging is provided in Table 3.

Concordance between Prenatal Prognosis and Postnatal Neurodevelopmental Outcome

A total of 104 patients with fMRI met the study criteria and were included in the final study group for analysis. The gestational age range was 19–39.4 weeks (median, 26.1 weeks; interquartile range, 21.8–31.9 weeks). The maternal age range was 16–41 years (median, 31 years; interquartile range, 28–33 years). In 11.5% (12/104) of pregnancies, there were multiple brain abnormalities noted on the fMRI. The range of ages for postnatal follow-up was 1.0–10.4 years (median, 3 years; interquartile range, 1.9–5.9 years). For the assessment of postnatal outcome, clinic notes from neurologists or geneticists were available in 69.2% (72/104) of cases. Table 4 summarizes the participants' characteristics and abnormalities found on fMRI. There were 36 pregnancies in which prenatal consult notes were available. In all 36 of these pregnancies, the prognosis generated by the neurologist was the same as the prognosis provided in the prenatal consult notes.

Of all pregnancies with a prenatal and postnatal assessment, the prenatal prognosis was favorable in 44.2% (46/104), indeterminate in 50.0% (52/104), and poor in 5.8% (6/104); the postnatal outcome was favorable in 74.0% (77/104), intermediate in 11.5% (12/104), and poor in 14.4% (15/104) (Table 5). Of the 15 with a poor postnatal outcome, 7 died in the postnatal period and 1 was stillborn.

Of the pregnancies with a favorable prenatal prognosis, 93.5% (43/46) had a favorable postnatal outcome, while 2.2% (1/46) had a poor postnatal outcome. Of the pregnancies with a poor prenatal prognosis, 16.7% (1/6) had a favorable postnatal outcome. For pregnancies with an indeterminate prognosis, 46% (24/52) had a prenatal diagnosis of VM, 19.2% (10/52) had corpus callosum abnormalities, 13.5% (7/52) had posterior fossa abnormalities, and 13.5% (7/52) had sulcation/migration abnormalities.

There were 96 pregnancies with children surviving to at least 1 year of age. Of those with a favorable prognosis, 97.8% (45/46) did not develop epilepsy in the postnatal period, while 2.2% (1/46) developed intractable seizures (Table 6). There were 47 pregnancies with an indeterminate prognosis, of which 3 developed intractable seizures. Fetal and postnatal imaging is provided for 1 of these cases in Fig 1C. There were 3 pregnancies with a poor prognosis, 2 of which did not develop seizures while 1 developed intractable seizures.

Table 3: List of prenatal and postnatal imaging diagnoses in cases of disagreement

GA (wk)	Prenatal Diagnosis	Postnatal Diagnosis
24	Macrocephaly with moderate asymmetric VM	Healthy
22	Vermis and cerebellum slightly small for GA	Healthy
27	Moderate VM (Fig 2A)	Mild VM and 3 subependymal heterotopias
20	Mild VM and moderate pericardial effusion	Cystic encephalomalacia
24	Mild VM (Fig 2B)	Microcephaly with severe VM
24	Flattening of inferior surface of cerebellum (Fig 2C)	Extensive lissencephaly with band heterotopia
19	Twin A, healthy	Congenital CMV
19	Twin B, healthy	Congenital CMV

Note:—CMV indicates cytomegalovirus.

Table 4: Characteristics of participants included in the assessment of concordance between prenatal prognosis and postnatal neurodevelopmental outcome

Characteristic	(n = 104)	GA <25 Weeks (n = 50)	GA ≥25 Weeks (n = 54)
GA at fetal MR imaging (range) (median) (IQR) (wk)	19.00–39.43 (26.1 [21.8, 31.9])	19.00–24.43 (21.7 [21.0, 23.0])	25.00–39.43 (31.9 [29.6–34.0])
Maternal age at fetal MR imaging (range) (median) (IQR) (yr)	16.00–41.00 (31.0 [28.0–33.0])	16.00–41.00 (30.0 [28.0–32.0])	17.00–41.00 (31.0 [28.0–34.0])
Age at postnatal visit (range) (median) (IQR) (yr)	1.00–10.42 (3.0 [1.9–5.9])	1.00–8.92 (2.8 [1.7–5.1])	1.00–10.42 (3.8 [2.0–6.0])
Brain region (No.) (%)			
Ventriculomegaly	32 (30.8%)	17 (34.0%)	15 (27.8%)
Mild	20 (19.2%)	12 (24.0%)	8 (14.8%)
Moderate	5 (4.8%)	3 (6.0%)	2 (3.7%)
Severe	7 (6.7%)	2 (4.0%)	5 (9.3%)
Posterior fossa	19 (18.3%)	7 (14.0%)	12 (22.2%)
Corpus callosum	11 (10.6%)	2 (4.0%)	9 (16.7%)
Sulcation/migration	8 (7.7%)	5 (10.0%)	3 (5.6%)
Normal	28 (26.9%)	18 (36.0%)	10 (18.5%)
Space	4 (3.8%)	1 (2.0%)	3 (5.6%)
Vascular anomaly	1 (1.0%)	0 (0.0%)	1 (1.9%)
Hemorrhage	1 (1.0%)	0 (0.0%)	1 (1.9%)

Table 5: Prenatal prognosis and postnatal outcome for all gestational ages (n = 104)

Prenatal Prognosis (No.) (%)	Postnatal Outcome, Favorable (n = 77)	Postnatal Outcome, Intermediate (n = 12)	Postnatal Outcome, Poor (n = 15)
Favorable (n = 46)	43 (93.5%)	2 (4.3%)	1 (2.2%)
Indeterminate (n = 52)	33 (63.5%)	10 (19.2%)	9 (17.3%)
Poor (n = 6)	1 (16.7%)	0 (0.0%)	5 (83.3%)

Table 6: Prenatal prognosis and postnatal development of epilepsy (n = 96)

Prenatal Prognosis (No.) (%)	Absence of Epilepsy (n = 84)	Medically Controlled Epilepsy (n = 7)	Intractable Epilepsy (n = 5)
Favorable (n = 46)	45 (97.8%)	0 (0.0%)	1 (2.2%)
Indeterminate (n = 47)	37 (78.7%)	7 (14.9%)	3 (6.4%)
Poor (n = 3)	2 (66.7%)	0 (0.0%)	1 (33.3%)

FeMRI Prognostication by GA

The distribution of prenatal prognosis and postnatal outcome for GA <25 weeks and GA ≥25 weeks is presented in Tables 7 and 8. The proportion of pregnancies given a favorable prognosis that resulted in favorable development was similar between groups (92.0% GA <25 weeks versus 95.2% GA ≥25 weeks).

DISCUSSION

Our study demonstrated a high level of agreement between prenatal diagnosis by feMRI and postnatal imaging diagnosis, with agreement observed in 93% (106/114) of cases. Our findings are comparable with prior diagnostic-accuracy studies of feMRI^{1–4} and further highlight the strength of feMRI in accurately diagnosing fetal brain abnormalities. In 7% (8/114) of cases, there was disagreement between prenatal and postnatal imaging. The prenatal and postnatal imaging diagnoses for each of these 8 cases are listed in Table 3, with representative images provided for 3 of these cases in Fig 2.

An example of discordant imaging diagnoses is that of the fetus whose feMRI was reported as having slight flattening of the inferior surface of the cerebellum with no note made of any lissencephaly (Table 3). The postnatal MR imaging, however, demonstrated extensive lissencephaly with subcortical band heterotopia (Fig 2C). On retrospective review of the feMRI, there was a subtle, thin, T2-hypointense cerebral

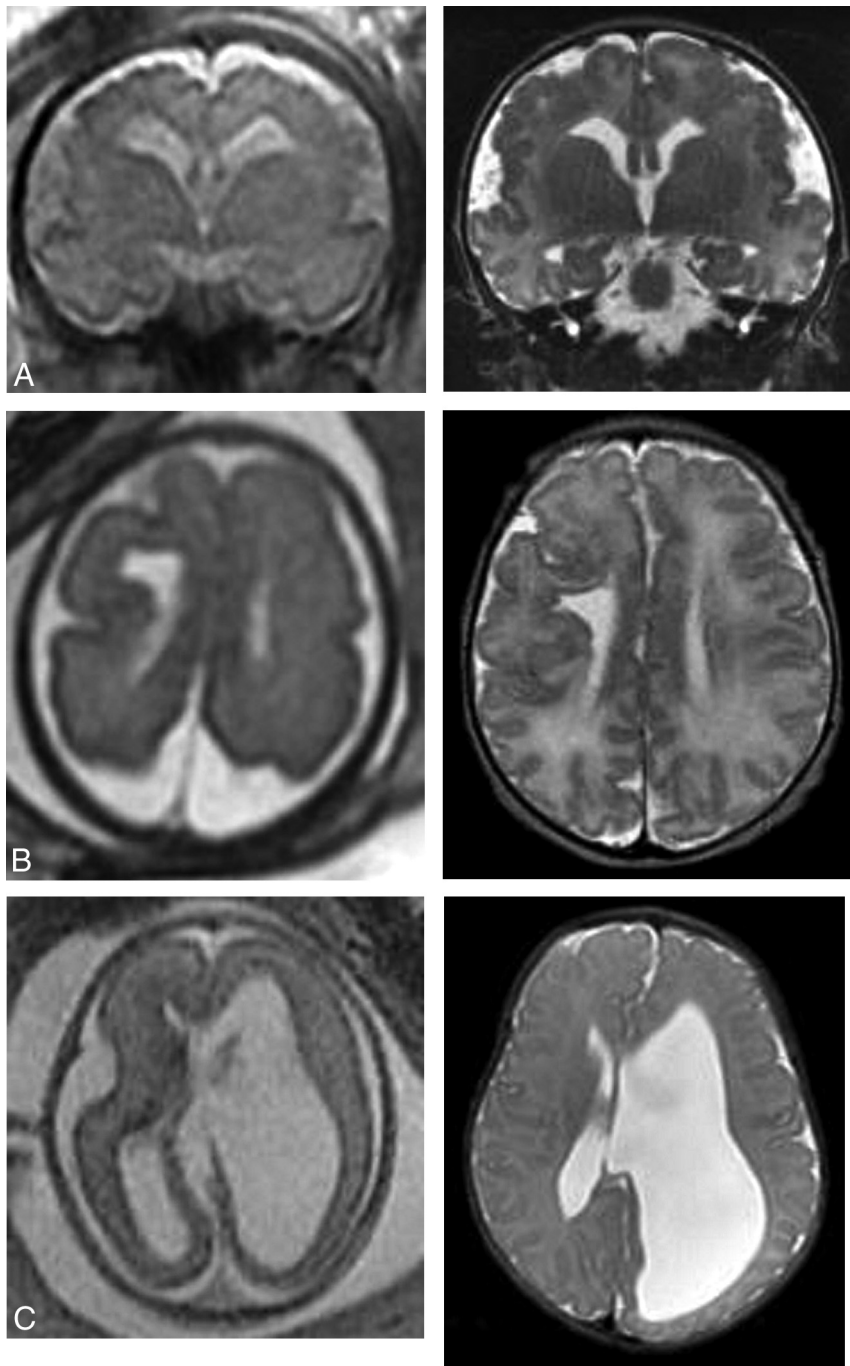


FIG 1. Prenatal and postnatal imaging examples of cases in which an indeterminate prognosis was associated with a poor outcome. A, Coronal single-shot fast spin-echo at 33 weeks with extensive bilateral polymicrogyria (peri-Sylvian, frontal, and parietal). Coronal T2 at 2 days of age confirms diffuse polymicrogyria. B, Axial single-shot fast spin-echo at 30 weeks shows a small right cerebral hemisphere with associated abnormal sulcation. There is right-sided polymicrogyria, a left subependymal nodule, and a large middle cystic structure (not shown) inferior to the corpus callosum and extending to the posterior fossa. Axial T2 at 2 days of age confirmed the fetal MR imaging findings. C, Axial FIESTA at 23 weeks demonstrates left unilateral VM. Axial T2 at 3 weeks of age confirms the left VM. The patient later required ventriculoperitoneal shunt due to complications of hydrocephalus and further disconnection surgery without resolution of seizures.

line that can be appreciated in the frontal lobes. This antenatal diagnosis, however, could only be made retrospectively in light of the available postnatal imaging data.

made.¹ Many identified brain abnormalities, however, have an unknown outcome regardless of when they are discovered or who is generating the prognosis; thus, an outcome cannot be predicted

It is often difficult to predict and explain discordant imaging diagnoses. After reviewing the images of the 8 discordant cases, we are confident that the imaging findings reported are accurate and that the changes seen on postnatal imaging would have been very difficult if not impossible to predict. In reality, there are changes in the fetal brain that can occur in the prenatal period after the fMRI and also in the brain of the child in the postnatal period. Fortunately, novel imaging techniques are emerging to facilitate more accurate and earlier prenatal imaging diagnoses.¹²⁻¹⁴ For example, the use of myo-inositol in MR spectroscopy shows promise as an early marker of congenital cytomegalovirus infection.¹⁴ This technique may have aided in the detection of congenital cytomegalovirus in the twins in our study, who had normal brains on fMRI but were both subsequently diagnosed with congenital cytomegalovirus infection postnatally (Table 3).

The principal aim of this study was to retrospectively assess the ability of fMRI to prognosticate the neurodevelopment of the child. The key finding of our study was the strong association between a favorable prognosis and favorable postnatal outcome, with 93.5% (43/46) of pregnancies assigned a favorable prognosis resulting in a favorable outcome. Similar results were observed when comparing the prognosis with the postnatal development of epilepsy, with 97.8% (45/46) of favorable pregnancies resulting in children without a postnatal diagnosis of epilepsy. Poor prognosis and poor outcome were also highly concordant, albeit in a small sample, with 83.3% (5/6) of pregnancies assigned a poor prognosis resulting in a poor outcome. Of all pregnancies with a prenatal prognosis and postnatal assessment, 50.0% (52/104) were given an indeterminate prognosis. It has previously been reported that an advantage of fMRI compared with antenatal ultrasound is that fewer indeterminate prognoses are

Table 7: Prenatal prognosis and postnatal outcome at GA <25 weeks (n = 50)

Prenatal Prognosis (No.) (%)	Postnatal Outcome, Favorable (n = 36)	Postnatal Outcome, Intermediate (n = 7)	Postnatal Outcome, Poor (n = 7)
Favorable (n = 25)	23 (92.0%)	1 (4.0%)	1 (4.0%)
Indeterminate (n = 25)	13 (52.0%)	6 (24.0%)	6 (24.0%)
Poor (n = 0)	0 (0.0%)	0 (0.0%)	0 (100.0%)

Table 8: Prenatal prognosis and postnatal outcome at GA ≥25 weeks (n = 50)

Prenatal Prognosis (No.) (%)	Postnatal Outcome, Favorable (n = 41)	Postnatal Outcome, Intermediate (n = 5)	Postnatal Outcome, Poor (n = 8)
Favorable (n = 21)	20 (95.2%)	1 (4.8%)	0 (0.0%)
Indeterminate (n = 27)	20 (74.1%)	4 (14.8%)	3 (11.1%)
Poor (n = 6)	1 (16.7%)	0 (0.0%)	5 (83.3%)

regardless of the accuracy of the imaging test. For pregnancies with an indeterminate prognosis, 63.5% (33/52) had a favorable outcome, 19.2% (10/52) had an intermediate development, and 17.3% (9/52) had a poor outcome. An indeterminate prognosis is not predicting an intermediate neurodevelopmental outcome. Rather, an indeterminate prognosis implies that a range of outcomes is possible, which could be favorable, intermediate, or poor. We have included representative imaging for 3 cases in which an indeterminate prognosis was associated with a favorable outcome (Fig 3) and 3 cases in which an indeterminate prognosis was associated with a poor outcome (Fig 1).

The most common prenatal diagnosis for pregnancies with an indeterminate prognosis was VM, which accounted for 46% (24/52) of the prenatal diagnoses. Of these 24 fetuses with VM given an indeterminate prognosis, 12 had mild VM, 5 had moderate VM, and 7 had severe VM. In our study, VM was a challenging prenatal diagnosis to prognosticate as demonstrated by the 75% (24/32) of all fetuses with VM and 100% (12/12) of fetuses with moderate (n = 5) or severe (n = 7) VM given an indeterminate prognosis. The large proportion of indeterminate prognoses given to pregnancies with a diagnosis of VM appears justified because the 24 pregnancies with VM given an indeterminate prognosis resulted in a wide range of outcomes, including 15 children with a favorable outcome, 5 with an intermediate outcome, and 4 with a poor outcome (including 3 deaths).

The MERIDIAN diagnostic accuracy study is currently the most exhaustive study of fMRI and its ability to aid in the prenatal diagnosis of fetal brain abnormalities.⁹ One component of this study compared prognostication of postnatal neurodevelopmental outcome between fMRI and antenatal ultrasound.¹⁰ Prenatal prognosis was categorized as either normal, favorable, intermediate, poor, or unknown. Postnatal neurodevelopment was assessed at 2–3 years of age and was categorized as either normal, at risk, or abnormal and was assessed using primarily the Bayley Scales of Infant and Toddler Development, Third Edition, and the Ages & Stages Questionnaire, Third Edition, as well as the Strength and Difficulties Questionnaire, GMFCS, and whether the child developed cerebral palsy. They concluded that neither fMRI nor ultrasound was able to accurately predict abnormal development, but they did report that fMRI was better than ultrasound at ruling out

abnormal development. Unlike our study, this study did not report the proportion of pregnancies with a favorable prognosis based on fMRI that resulted in a child with favorable development. However, they did report that in children who developed normally, 72% (71/99) were given a favorable or healthy prognosis based on fMRI. Furthermore, they reported that in surviving children with abnormal development, 39% (21/54) were given a favorable or normal prognosis based on fMRI, and in nonsurviving infants, 15% (11/73) were given a favorable or normal prognosis. In this respect, the study by Hart et al¹⁰ suggested that a

favorable prognosis based on fMRI is less predictive of normal development than it was in our retrospective study. This suggestion could be explained by numerous factors, including differences in the prognosis categories, outcome assessment, clinical thresholds for indicating a fMRI, and likely different practices in providing prognoses.

We also compared fMRI prognostication between 2 GA groups: <25 weeks and ≥25 weeks. We found that the ability of fMRI to predict favorable development in pregnancies with a favorable prenatal prognosis was not influenced by GA, with 92.3% (23/25) agreement for GA <25 weeks versus 95.2% (20/21) for GA ≥25 weeks. Providing accurate prognoses to patients is particularly important in the earlier stages of pregnancy because decisions regarding termination of pregnancy may be based on these fetal scans. It is, therefore, encouraging to note that fMRI performed at GA <25 weeks provides a high level of prognostic accuracy that is not inferior to fMRI performed at GA ≥25 weeks.

In our study, there was 1 pregnancy assigned a favorable prenatal prognosis that resulted in a poor postnatal outcome. This was a twin pregnancy with the fMRI for the fetus in question being unremarkable apart from a fluid-filled cavity above the tentorium believed to be an arachnoid cyst. This fetus was given a favorable prenatal prognosis; however, the child had a poor outcome with GMFCS II–III and intractable seizures. Postnatal MR imaging findings at 4 months were unremarkable. The most likely explanation is that this child had a predisposition to seizures without any associated intracranial abnormality demonstrated on fMRI. A large portion of children with seizures do not have any evidence of intracranial abnormality on postnatal imaging.¹⁵ We therefore do not believe that this poor outcome could have been predicted on the basis of findings of the fMRI.

A concerning scenario is when the prognosis of a fetus is determined to be poor and the child has a favorable postnatal outcome. There was 1 case like this in our study. The fetus had a vein of Galen aneurysmal malformation seen on fMRI. A poor prenatal prognosis was made retrospectively from the fMRI report and images; however, the child's postnatal development was favorable, with the vein of Galen malformation redemonstrated on postnatal MR imaging. Many interventional procedures were

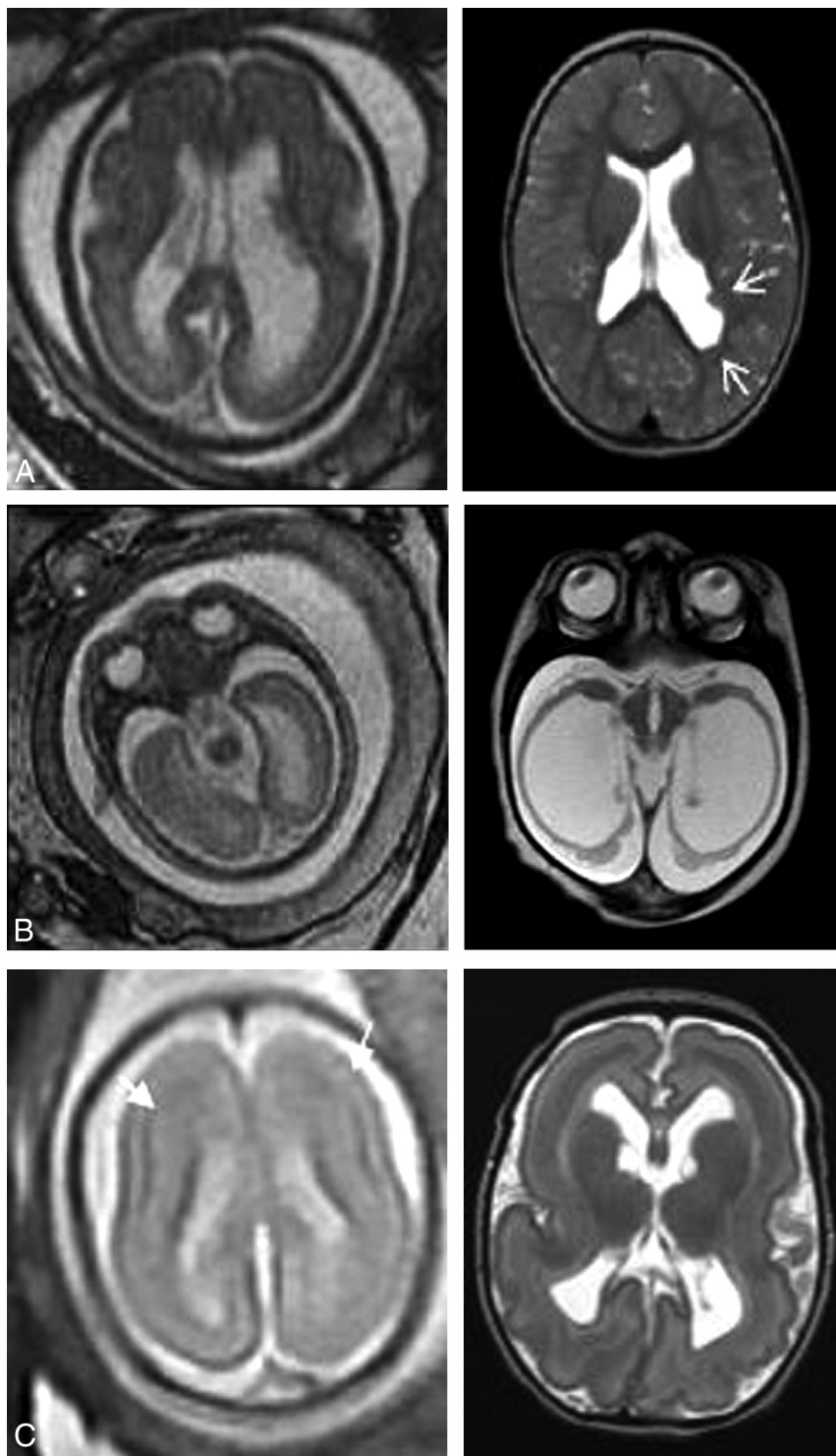


FIG 2. Prenatal and postnatal images showing examples of discordant imaging findings. A, Axial T2 feMRI at 27 weeks shows moderate VM, and postnatal axial T2 MRI shows mild VM with subependymal heterotopia (arrows). B, feMRI at 24 weeks shows mild VM and a preserved cerebral mantle, and postnatal MRI shows microcephaly and severe ventriculomegaly with thinning of the cerebral mantle. C, feMRI at 24 weeks shows a thin T2-hypointense cerebral line in the frontal lobes (arrows) that was overlooked. Postnatal MRI confirmed subcortical band heterotopia.

completed to render the malformation nonhemodynamically significant, and apart from decreased endurance and some fine motor difficulties, the child has been developing normally. Vein of Galen

did not perform any assessment of language or social or cognitive skills. Furthermore, using the GMFCS score, originally designed to evaluate children with cerebral palsy, in our cohort that was

malformations are known to have variable outcomes, which could explain why this child developed favorably despite a poor prognosis by feMRI. Furthermore, while this child did meet our criteria for a favorable postnatal outcome, he did require several embolizations in the postnatal period; thus, the postnatal outcome was not as benign as in another child with a favorable outcome who did not require such an extensive follow-up.

One of the main limitations of our study, inherent in its retrospective design, was that in most pregnancies (68/104), the prenatal prognosis was established solely on the basis of the feMRI report and imaging, without any clinical data that would otherwise be available in the real world. In the 36 pregnancies for which prenatal consult notes were available, we demonstrated that the prognosis determined by the neurologist was the same as the prognosis provided in the prenatal consult notes. We can therefore be fairly confident that the prognoses retrospectively determined by our neurologist likely represent the prognoses that would be provided by our institution for all 104 pregnancies included in the prognostic arm of the study. Nonetheless, it is difficult to distinguish whether the prognosis was established purely on the basis of feMRI or if the prognosis represents the combined efforts of feMRI coupled with the interpretation of clinical information by our pediatric neurologist. Even in the 36 cases for which a prognosis had already been established, it is entirely possible that factors beyond the findings of the feMRI influenced the prognosis that was generated at the time.

In the postnatal period, our neurodevelopmental assessments were limited to the GMFCS score and the presence/absence of seizures because these were the only outcomes that could be accurately assessed in our retrospective chart review. We therefore

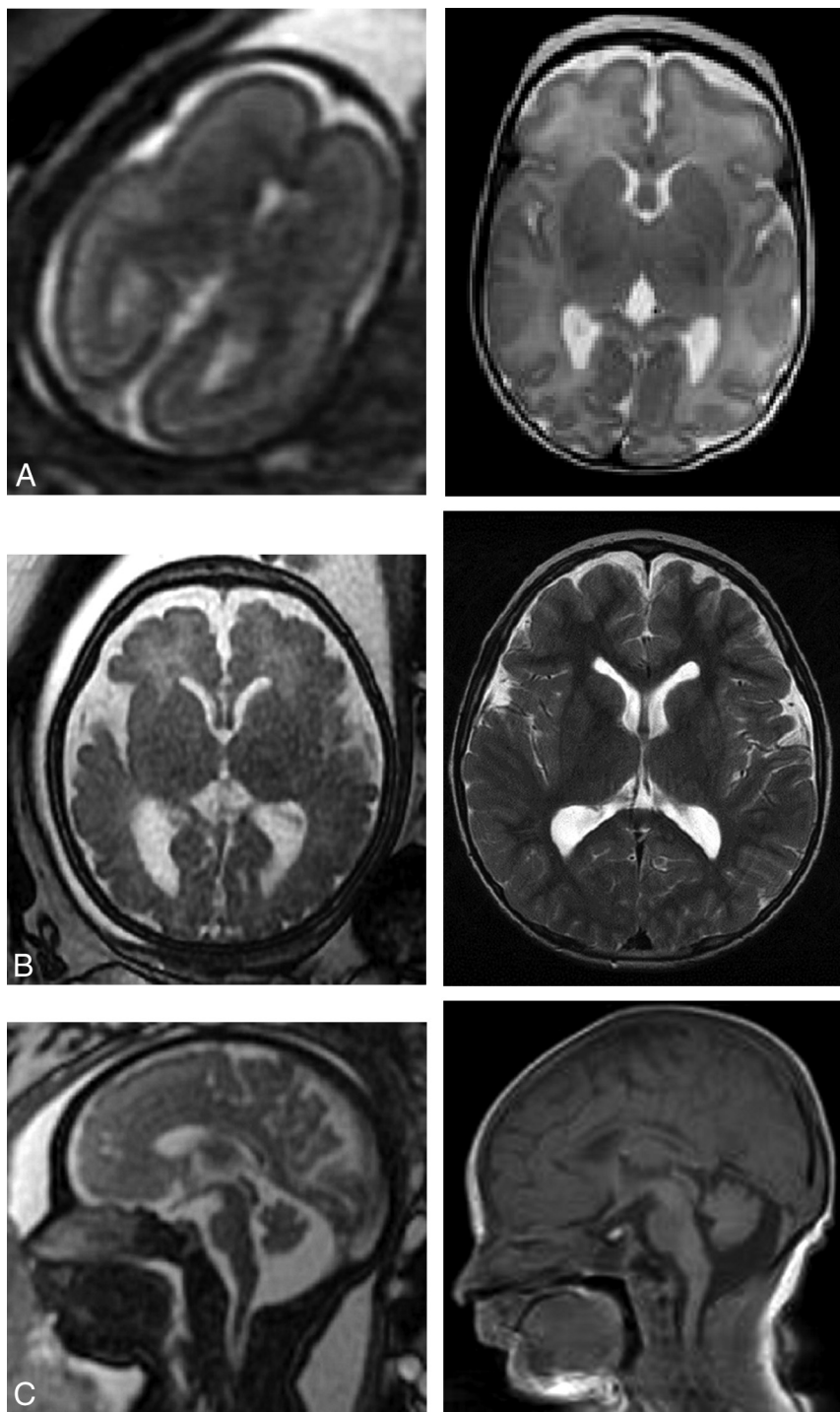


FIG 3. Prenatal and postnatal imaging examples of cases in which an indeterminate prognosis was associated with a favorable outcome. A, Axial single-shot fast spin-echo at 23 weeks with primitive sulcation and oligohydramnios. Axial T2 at 2 months of age shows normal brain MRI findings. B, Axial single-shot fast spin-echo at 35 weeks with VM (left 13 and right 12 mm). MRI at 6 years of age shows persistent prominent VM similar to findings on the ultrasound after birth (not shown). The patient has normal neurologic examination findings. C, Sagittal single-shot fast spin-echo at 35 weeks with a large cisterna magna versus vermian hypoplasia. Sagittal T1 at 3 days of life shows a prominent cisterna magna without other abnormalities.

not limited to children with cerebral palsy, has its limitations. We also assessed developmental outcomes at a wide range of ages (1–10 years of age). Our sample size was relatively small, particularly

the number of pregnancies that had a poor prognosis. This size limits our ability to provide any definitive guidance for pregnancies given a poor prognosis. Last, our retrospective study summarizes feMRI data during a 10-year period from 2008 to 2018; therefore, we may not have captured improvements in imaging techniques in terms of resolution and the applicability of advanced techniques during this time. FeMRI continues to be an evolving technology, and novel imaging methods such as FLAIR, DWI, and DTI may further increase both diagnostic and prognostic accuracy.^{12–14}

CONCLUSIONS

Our study confirmed that feMRI provides a high level of diagnostic accuracy (93.0%), which is comparable with that in previous studies of diagnostic accuracy. The principal finding of our retrospective study was that a favorable prenatal prognosis based on feMRI is highly predictive of a favorable neurodevelopmental outcome in the child (93.5% agreement). A large portion of the pregnancies in our study were given indeterminate prognoses (50%), of which a large proportion had a prenatal diagnosis of VM (46%). The pregnancies given an indeterminate prognosis resulted in a wide range of outcomes, 63.5% of which were favorable. Last, our study found no differences in prognostication between feMRI completed at GA <25 weeks and GA ≥25 weeks.

Our study adds to the growing body of literature examining the utility of feMRI, particularly the work by Hart et al,¹⁰ who were the first to publish a prospective cohort study comparing prognoses based on feMRI and postnatal neurodevelopmental outcome. Moving forward, more large, prospective studies are required to better understand the role of feMRI in prognosticating neurodevelopment, particularly in cases in which the prognosis is indeterminate. These may eventually allow clinicians to provide

prognoses for these patients with greater certainty of postnatal outcome. Future studies should also aim to recruit large numbers of pregnancies with poor prognoses on feMRI because prognostication

of outcome in these cases has only been studied in small samples to date.

Disclosures: Elka Miller—**UNRELATED: Board Membership:** I am on the Board at my hospital as a representative of the medical staff. I do not receive payment for this.

REFERENCES

1. Griffiths PD, Bradburn M, Campbell MJ, et al; MERIDIAN collaborative group. **Use of MRI in the diagnosis of fetal brain abnormalities in utero (MERIDIAN): a multicentre, prospective cohort study.** *Lancet* 2017;389:538–46 [CrossRef Medline](#)
2. Jarvis D, Mooney C, Cohen J, et al. **A systematic review and meta-analysis to determine the contribution of MR imaging to the diagnosis of foetal brain abnormalities in utero.** *Eur Radiol* 2017;27:2367–80 [CrossRef Medline](#)
3. Rossi A, Prefumo F. **Additional value of fetal magnetic resonance imaging in the prenatal diagnosis of central nervous system anomalies: a systematic review of the literature.** *Ultrasound Obstet Gynecol* 2014;44:388–93 [CrossRef Medline](#)
4. van Doorn M, Oude Rengerink K, Newsum EA, et al. **Added value of fetal MRI in fetuses with suspected brain abnormalities on neurosonography: a systematic review and meta-analysis.** *J Matern Fetal Neonatal Med* 2016;29:2949–61 [CrossRef Medline](#)
5. Winkler A, Tölle S, Natalucci G, et al. **Prognostic features and long-term outcome in patients with isolated fetal ventriculomegaly.** *Fetal Diagn Ther* 2018;44:210–20 [CrossRef Medline](#)
6. Li Z, Lv Y, He P, et al. **Clinical value of prenatal MRI for diagnosis of isolated ventriculomegaly and prediction of early postnatal developmental outcomes.** *Prenat Diagn* 2019;39:124–29 [CrossRef Medline](#)
7. Patek KJ, Kline-Fath BM, Hopkin RJ, et al. **Posterior fossa anomalies diagnosed with fetal MRI: associated anomalies and neurodevelopmental outcomes.** *Prenat Diagn* 2012;32:75–82 [CrossRef Medline](#)
8. Limperopoulos C, Robertson RL, Estroff JA, et al. **Diagnosis of inferior vermian hypoplasia by fetal magnetic resonance imaging: potential pitfalls and neurodevelopmental outcome.** *Am J Obstet Gynecol* 2006;194:1070–76 [CrossRef Medline](#)
9. Griffiths PD, Bradburn M, Campbell MJ, et al. **MRI in the diagnosis of fetal developmental brain abnormalities: the MERIDIAN diagnostic accuracy study.** *Health Technol Assess* 2019;23:1–144 [CrossRef Medline](#)
10. Hart AR, Embleton ND, Bradburn M, et al. **Accuracy of in-utero MRI to detect fetal brain abnormalities and prognosticate developmental outcome: postnatal follow-up of the MERIDIAN cohort.** *Lancet Child Adolesc Health* 2020;4:131–40 [CrossRef Medline](#)
11. Palisano R, Rosenbaum P, Walter S, et al. **Development and reliability of a system to classify gross motor function in children with cerebral palsy.** *Dev Med Child Neurol* 1997;39:214–23 [CrossRef Medline](#)
12. Diogo MC, Prayer D, Gruber GM, et al. **Echo-planar FLAIR sequence improves subplate visualization in fetal MRI of the brain.** *Radiology* 2019;292:159–69 [CrossRef Medline](#)
13. Kasprian G, Del Rio M, Prayer D. **Fetal diffusion imaging: pearls and solutions.** *Top Magn Reson Imaging* 2010;21:387–94 [CrossRef Medline](#)
14. Diogo MC, Glatter S, Binder J, et al. **The MRI spectrum of congenital cytomegalovirus infection.** *Prenat Diagn* 2020;40:110–24 [CrossRef Medline](#)
15. Dayan PS, Lillis K, Bennett J, et al. **Prevalence of and risk factors for intracranial abnormalities in unprovoked seizures.** *Pediatrics* 2015;136:e351–60 [CrossRef Medline](#)