



Discover Generics

Cost-Effective CT & MRI Contrast Agents

**FRESENIUS
KABI**

[WATCH VIDEO](#)

AJNR

**Correlation between 2D and 3D Fetal Brain
MRI Biometry and Neurodevelopmental
Outcomes in Fetuses with Suspected
Microcephaly and Macrocephaly**

S. Fried, M. Gafner, D. Jeddah, N. Goshier, D. Hoffman, R.
Ber, A. Mayer and E. Katorza

This information is current as
of June 25, 2025.

AJNR Am J Neuroradiol 2021, 42 (10) 1878-1883

doi: <https://doi.org/10.3174/ajnr.A7225>

<http://www.ajnr.org/content/42/10/1878>

Correlation between 2D and 3D Fetal Brain MRI Biometry and Neurodevelopmental Outcomes in Fetuses with Suspected Microcephaly and Macrocephaly

 S. Fried,  M. Gafner,  D. Jeddah,  N. Goshier,  D. Hoffman,  R. Ber,  A. Mayer, and  E. Katorza



ABSTRACT

BACKGROUND AND PURPOSE: Definitions of fetal microcephaly and macrocephaly are debatable. A better understanding of their long-term prognoses would help guide parental education and counseling. This study aimed to explore the correlation between 2D and 3D fetal brain MR imaging biometry results and the long-term neurodevelopmental outcomes.

MATERIALS AND METHODS: This analysis is a historical cohort study. Fetal brain biometry was measured on 2D and 3D MR imaging using a volumetric MR imaging semiautomated algorithm. We measured and assessed the following brain structures: the supratentorial brain volume and cerebellar volume and cerebellar volume/supratentorial brain volume ratio, in addition to commonly used 2D brain MR imaging biometric variables, including occipitofrontal diameter, biparietal diameter, and transcerebellar diameter. Microcephaly was defined as ≤ 3 rd percentile; and macrocephaly, as ≥ 97 th percentile, corresponding to -2 SDs and $+2$ SDs. The neurodevelopmental outcome of this study cohort was evaluated using the Vineland-II Adaptive Behavior Scales, and the measurements were correlated to the Vineland standard scores.

RESULTS: A total of 70 fetuses were included. No significant correlation was observed between the Vineland scores and either the supratentorial brain volume, cerebellar volume, or supratentorial brain volume/cerebellar volume ratio in 3D or 2D MR imaging measurements, after correction for multiple comparisons. No differences were found among fetuses with macrocephaly, normocephaly, or microcephaly regarding the median Vineland standard scores.

CONCLUSIONS: Provided there is normal brain structure on MR imaging, the developmental milestone achievements in early years are unrelated to 2D and 3D fetal brain MR imaging biometry, in the range of measurements depicted in this study.

ABBREVIATIONS: BPD = biparietal diameter; CV = cerebellar volume; HC = head circumference; IQR = interquartile range; OFD = occipitofrontal diameter; STV = supratentorial brain volume; TCD = transcerebellar diameter; US = ultrasound

Measurement of head circumference (HC) is a key element in the routine prenatal ultrasonographic screening of the fetus. Fetal macrocephaly and microcephaly are defined as an ultrasonographic occipitofrontal circumference of >2 SDs above the mean and 3 SDs below the mean, respectively.^{1,2} There is a lack of published data regarding the correlation between brain MR imaging biometry and neurodevelopmental outcome.

When macrocephaly appears prenatally, its diagnosis is usually made during the third trimester, especially when no other anomalies are found.³ There is no consensus with respect to the neurodevelopmental outcomes of macrocephaly. Some studies describe this condition as benign, while others associate it with lower intelligence and motor function.³⁻⁶ Similar results are often observed regarding isolated fetal microcephaly, while definitions of this condition are debatable.⁷ Leibovitz et al⁸ described the tendency toward overdiagnosis of microcephaly in prenatal ultrasound (US).⁸ Stoler-Poria et al⁷ showed that prenatal diagnosis of a head circumference between 2 and 3 SDs below the mean does not portend an abnormal neuropsychological development.

When suspicion of an abnormal head circumference arises, in many medical centers, it is a common practice to refer for fetal brain MR imaging to obtain additional information regarding brain development. Detailed anatomic US screening, neurosonography, and genetic counseling are also frequently obtained.^{9,10}

Received January 10, 2021; accepted after revision May 3.

From the Sackler School of Medicine (S.F., M.G., D.J., D.H., R.B., A.M., E.K.), Tel-Aviv University, Tel-Aviv, Israel; Departments of Obstetrics and Gynecology (S.F., E.K.) and Diagnostic Radiology (A.M.), Sheba Medical Center, Tel-Hashomer, Israel; Department of Pediatrics B (M.G.), Schneider Children's Medical Center of Israel, Petach Tikva, Israel; and Hadassah Medical School (N.G.), The Hebrew University of Jerusalem, Jerusalem, Israel.

S. Fried and M. Gafner contributed equally to this work.

Please address correspondence to Shalev Fried, BMedSci, Tel Aviv University, Israel, Mailbox 39040, 6997801 Tel Aviv, Israel; e-mail: Shalev.Fried@mail.tau.ac.il



Indicates article with online supplemental data.

<http://dx.doi.org/10.3174/ajnr.A7225>

A previous study from our group demonstrated significant agreement among US, 2D MR imaging, 3D MR imaging, and the head circumference at birth in the classification of suspected microcephaly and macrocephaly. It raised the question of the additional value of fetal brain MR imaging in the evaluation of isolated fetal microcephaly and macrocephaly.¹¹ We expand on this previous study and aim to explore this question with the same cohort of fetuses by examining the neurodevelopmental outcomes of fetuses according to their measured brain biometry on 2D and 3D MR imaging.

MATERIALS AND METHODS

This historical cohort study was approved by the Chaim Sheba Medical Center institutional review board (0256-13-SMC). Informed consent was obtained from all women who participated in this study.

Subjects

The subjects of this study were all women with singleton pregnancies who underwent fetal brain MR imaging at our tertiary medical center between 2011 and 2018 during their third trimester. Given the study aims, we recruited the subjects in clusters according to the indication of their MR imaging examinations. These included individuals with either US-suspected microcephaly or macrocephaly and those with non-neurologic reasons such as a sibling with a neurologic abnormality for the normocephaly group.

The inclusion criteria for this study were MR imaging scans that were clear and unambiguous enabling easy assessment of measures, a full neurosonogram examination performed by an obstetrician/gynecologist expert in fetal sonography, and delivery at our medical center. Exclusion criteria were suspicion of intrauterine growth retardation, women with a multiple pregnancy, an associated major brain anomaly, termination of pregnancy, and unwillingness of parents to participate in the interview. We included fetuses with the following findings that are considered a normal or minor variant:¹² a narrow cavum septum pellucidum, dolichocephaly, minor dilation of the subarachnoid space, mega cisterna magna, and short intact corpus callosum, as has been acceptable in similar studies.¹³⁻¹⁵

Information regarding the pregnancy, fetal sex, genetic testing, and US findings was obtained from the medical records.

MR Imaging. This study was based on our routine fetal MR imaging procedure. We used a 1.5T system. Single-shot fast spin-echo T2-weighted sequences in 3 orthogonal planes were performed using a half-Fourier technique (number of excitations = 0.53) with the following parameters: section thickness = 3 or 4 mm, no gap, flexible coil (8-channel cardiac coil). FOV was determined by the size of the fetal head with a range of 24 × 24 cm to 30 × 30 cm, acquisition time = 40–45 seconds, matrix = 320/224, TE = 90 ms, TR = 1298 ms, pixel bandwidth = 122 Hz/pixel. Specific absorption rate values were between 1.1 and 1.7 W/kg.¹⁶

Semiautomated Algorithm of Volumetric MR Imaging Measurements

We used a semiautomated algorithm developed by our group.¹³ The algorithm is based on the initial manually outlined contour of the ROI in the brain parenchyma of the midcoronal section. On the basis of the signal intensity, the contour is then automatically propagated into a more accurate one. The algorithm then proceeds to propagate forward and backward, drawing contours automatically for all the slices. Later, manual adjustments are made to attain maximal precision. The total volume is calculated, summing up the volume of voxels enclosed by each contour.

Measurements

The measurements were performed on the coronal plane. We measured and assessed 2 brain structures, the supratentorial brain volume (STV) and the cerebellar volume (CV), and calculated the ratio between the cerebellar volume and the supratentorial brain volume (CV/STV). These volumes were converted to percentiles according to percentile tables derived from healthy fetuses, obtained from a previous publication from our group.¹³ The anatomic boundaries of the brain structures are as follows:¹⁷

Supratentorial Brain. The supratentorial brain included the parenchyma of the frontal, parietal, occipital, and temporal lobes, including the third ventricle. The lateral ventricles, cerebellum, brain stem, and fourth ventricle were excluded. The boundaries of the parenchyma were defined as the outer edge of the cerebral cortex. The inferior border matched the cortex and the “imagined” line crossing the brain stem between the edges of the tentorium cerebelli.

Cerebellum. The cerebellum included the cerebellar peduncles and vermis and excluded the brain stem and the fourth ventricle.

In addition, 2D MR imaging measurements, performed for clinical purposes by an expert neuroradiologist (E.K.), were obtained from the original MR imaging evaluation, namely, the occipitofrontal diameter (OFD), biparietal diameter (BPD), and transcerebellar diameter (TCD). They were then converted to percentiles according to reference ranges of Tilea et al.¹⁸

Microcephaly was defined as equal or less than the 3rd percentile, and macrocephaly, as equal or more than the 97th percentile, corresponding the threshold of -2 SDs and $+2$ SDs.

Neurodevelopmental Outcome

The fetuses were evaluated at least 6 months after birth using the Vineland-II Adaptive Behavior Scales.¹⁹ This is a commonly used interview-based questionnaire that evaluates 4 domains of development of the child from birth to adulthood. These include communication skills, motor skills, socialization skills, and daily living skills.

Because the expression of adaptive behavior changes throughout life, the scores are age-normalized and then added to an adaptive behavior composite,²⁰ which is characterized by a mean score of 100 and an SD of 15.²¹ This study used the published Israeli version of the questionnaire. Because Israeli norms for the full age ranges are not available and because there was no reason to believe that children in the United States and Israel will develop motor and mental skills differently, we used the American

Table 1: Descriptive statistics of the study population

Statistics	
Maternal age at birth (median) (IQR) (yr)	34 (29.8–36.0)
Fetal sex	
Male (No.) (%)	34 (48.6%)
Female (No.) (%)	36 (51.4%)
Abnormal triple test findings (No.) (%)	3 (4.3%)
Abnormal nuchal translucency findings (No.) (%)	3 (4.3%)
Karyotype (No.) (%)	
Not performed	31 (44.3%)
Normal findings	39 (55.7%)
Abnormal findings	0 (0%)
Chromosomal microarray (No.) (%)	
Not performed	48 (68.6%)
Normal findings	21 (30%)
Abnormal findings	1 (1.4%)
Length of pregnancy (mean) (SD) (wk)	38.8 (1.3)

Table 2: 2D and 3D fetal brain MR imaging biometric parameters

Characteristics	Median	IQR
OFD (mm)	98.5	93.0–102.3
OFD (centile)	57.5	28.8–90.0
BPD (mm)	77.0	72.8–80.0
BPD (centile)	40.0	10.0–75.0
TCD (mm)	45.0	41.9–48.0
TCD (centile)	50.0	40.0–75.0
STV (mm ³)	220.294	192,195–248,017
STV (centile)	28.0	4.0–84.3
CV (mm ³)	12.683	10,604–15,114
CV (centile)	48.5	12.8–77.5
CV/STV	0.058	0.052–0.065
CV/STV (centile)	58.5	32.0–88.5

norms. An abnormal Vineland score was defined as a standard score of a subdomain or as an adaptive-level composite standard score of <86 (low or moderately low adaptive level).²²

Statistical Analysis

Categorical variables were presented as frequency and percentage. Continuous variables were summarized as mean and SD or median and interquartile range (IQR). The Spearman rank correlation coefficient was used to study the association between the Vineland scores and brain parameters. In further analysis, the brain parameters (percentiles) were categorized using the 3rd and 97th percentiles as threshold values for microcephaly and macrocephaly, respectively. The median Vineland scores were compared between healthy fetuses and those with microcephaly and between healthy fetuses and those with macrocephaly using the Mann-Whitney *U* test. The Benjamini-Hochberg procedure (false discovery rate) was used to adjust the *P* values to avoid errors due to multiple comparisons. Differences between our cohort and the fetuses that were lost to follow up were studied using the Mann-Whitney *U* or χ^2 test. All statistical tests were 2-sided, and *P* < .05 was considered statistically significant. SPSS software was used for all statistical analyses (IBM, 2017).

Intraclass Correlation Coefficient

Interobserver and intraobserver variability were evaluated by comparing measurements of 10 fetuses from this cohort made by 2

independent observers with 10 other measurements measured twice by the same observer, respectively. We calculated the intraclass correlation coefficient and its 95% confidence intervals. We defined good agreement as $0.6 \leq$ intraclass correlation coefficient ≤ 0.74 and excellent agreement as intraclass correlation coefficient ≥ 0.75 .²³

RESULTS

A total of 88 fetuses were recruited for the study. Eighteen (20%) fetuses were excluded from the study. Sixteen (18%) fetuses were either lost to follow-up or lost due to parental refusal for an interview. These fetuses were found to be similar to the rest of the cohort (Online Supplemental Data). The other 2 fetuses (2%) were excluded due to termination of pregnancy. The demographic details of the mothers and fetuses are shown in Table 1. Obstetric data of the cohort are presented in the Online Supplemental Data.

MR Imaging Biometrics

The median gestational age at time of MR imaging was 34.3 weeks (IQR, 32.5–36.6 weeks). The 2D and 3D measurements are presented in Table 2. A total of 16 (23%) and 11 (16%) fetuses had STV s of ≤ 3 rd and ≥ 97 th percentiles, respectively. This was achieved by recruiting the fetuses in clusters according to the indication for the MR imaging, to have enough data points at the margins of the curve. Of these fetuses, 10 (14%) were ≤ 1 st percentile and 8 (11%) were ≥ 99 th percentile.

Neurodevelopmental Outcomes

The Vineland-II Adaptive Behavior scores of our cohort are presented in the Online Supplemental Data. The median age of the children at time of the interview was 55.5 months (IQR, 26.8–75.0 months). The correlations between the biometric parameters and the Vineland composite scores are presented in Figs 1 and 2 for macrocephaly and microcephaly, respectively, as well as in the Online Supplemental Data. We initially found negative correlations between the 2D MR imaging BPD and the daily living skills subdomain score, 3D MR imaging STV and the daily living skills subdomain score, and the 3D MR imaging CV/STV ratio and the motor and daily living skills subdomains scores. However, after we used the Benjamini-Hochberg procedure to adjust the *P* values for multiple comparisons, all the above correlations were found to be statistically insignificant. Furthermore, no significant differences were found when comparing the median Vineland scores between fetuses with microcephaly and healthy fetuses and fetuses with macrocephaly and healthy fetuses, using the 3rd and 97th percentiles as thresholds, respectively (Tables 3 and 4; Online Supplemental Data).

The only child who had a low adaptive behavior composite score in the cohort had a diagnosis of Soto syndrome, a rare autosomal dominant overgrowth syndrome that is associated with cognitive impairment, which was made at 4 months of age. This fetus did not have extreme biometry, with measurements of the 90th percentile for the OFD and BPD, 10th percentile for the TCD, 98th percentile for STV, 52nd percentile for CV, and 5th percentile for the CV/STV ratio. The 8 children who had moderately low composite scores had quite variable brain volumes: Two had an STV ≤ 3 rd percentile, 2 had an STV ≥ 97 th percentile, and 4 had a normal STV. Regarding genetics, only 1 fetus had

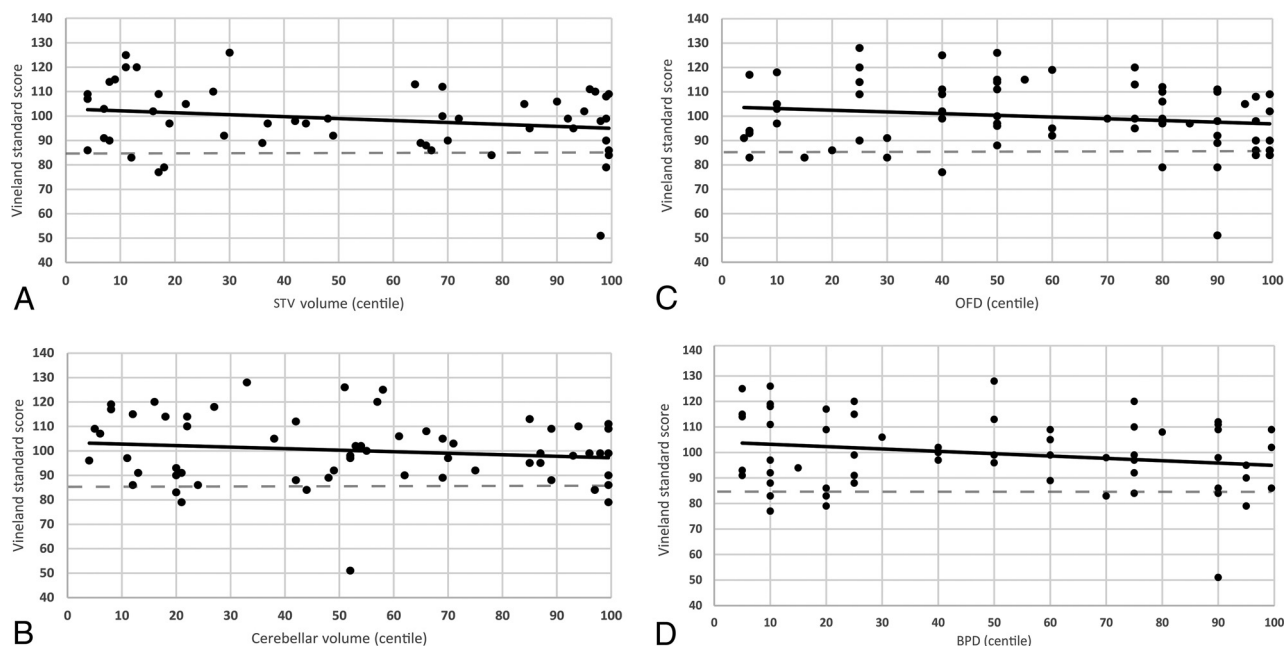


FIG 1. Scatterplots of the Vineland II Adaptive Behavior standard score according to STV (A), CV (B), OFD (C), and BPD (D). Macrocephalic and normocephalic biometry.

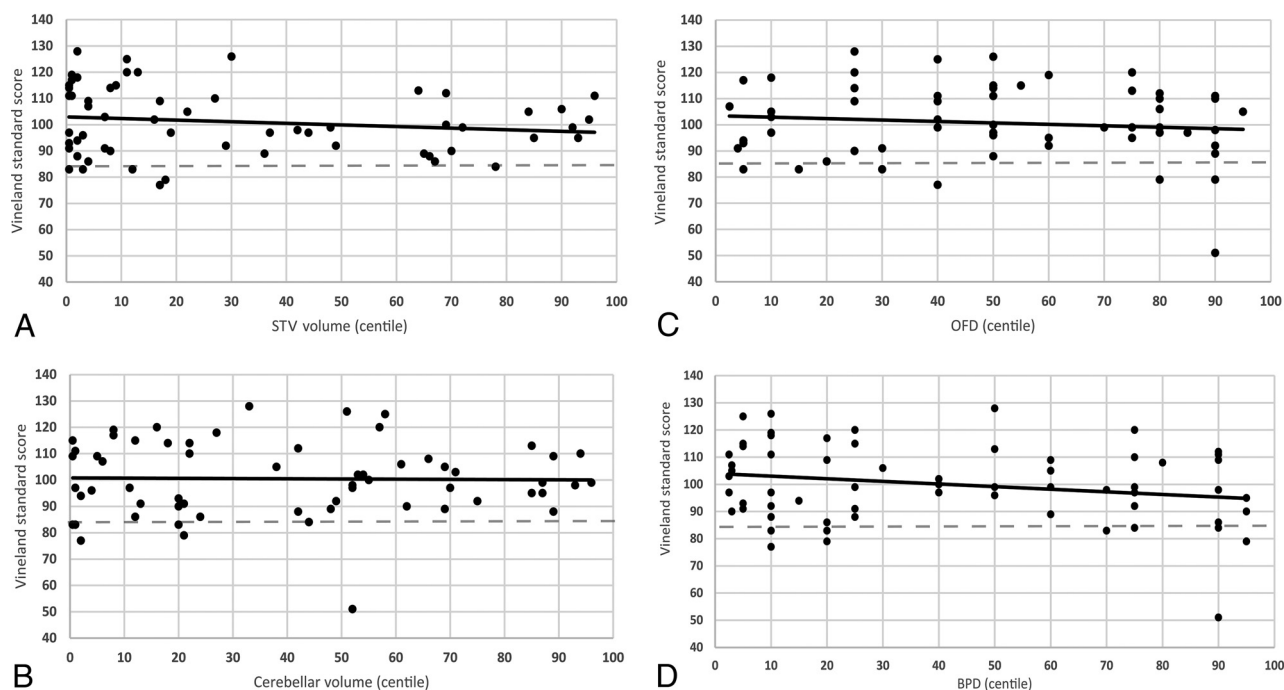


FIG 2. Scatterplots of the Vineland II Adaptive Behavior standard score according to STV (A), CV (B), OFD (C), and BPD (D). Microcephalic and normocephalic biometry.

abnormal findings on a chromosomal microarray test. This fetus did not have an abnormal Vineland score.

Interobserver and Intraobserver Variability

All volumetric intraclass correlation coefficients for both interobserver and intraobserver results were excellent (Online Supplemental Data).

DISCUSSION

In this study, we aimed to find correlations between 2D and 3D fetal brain MR imaging biometry and long-term neurodevelopmental outcomes using the Vineland-II Adaptive Behavior Scales. The results of this study show no correlation among MR imaging STV, CV, the STV/CV ratio, OFD, BPD, or TCD and the neurodevelopmental outcomes when tested as

Table 3: Comparison of Vineland-II Adaptive Behavior standard scores between fetuses with microcephaly and healthy fetuses according to 2D and 3D fetal brain MR imaging biometry^a

Percentile of biometric value	4–96	≤3	P Value
MR imaging 3D STV (No. of fetuses)	43	16	
Adaptive behavior composite score	99 (109–90)	104 (116–91)	.44
MR imaging 3D CV (No. of fetuses)	53	9	
Adaptive behavior composite score	99 (111–91)	97 (111–83)	.51
MR imaging 2D OFD (No. of fetuses)	58	1	
Adaptive behavior composite score	99 (111–71)	107	NA
MR imaging 2D BPD (No. of fetuses)	61	6	
Adaptive behavior composite score	98 (111–89)	104 (108–95)	.68

Note:—NA indicates not applicable.

^a Continuous variables are presented as median (IQR). P value refers to the Mann-Whitney U test.

Table 4: Comparison of Vineland-II Adaptive Behavior standard scores between fetuses with macrocephaly and healthy fetuses according to 2D and 3D fetal brain MR imaging biometry^a

Percentile of biometric value	4–96	≥97	P Value
MR imaging 3D STV (No. of fetuses)	43	11	
Adaptive behavior composite standard score	99 (109–90)	98 (109–84)	.31
MR imaging 3D CV (No. of fetuses)	53	8	
Adaptive behavior composite standard score	99 (111–91)	94 (106–84)	.19
MR imaging 2D OFD (No. of fetuses)	58	11	
Adaptive behavior composite standard score	99 (111–71)	90 (108–86)	.13
MR imaging 2D BPD (No. of fetuses)	61	3	
Adaptive behavior composite standard score	98 (111–89)	102	.93

^a Continuous variables are presented as median (IQR). P value refers to the Mann-Whitney U test.

continuous variables or when categorized into normal versus abnormal biometry.

When microcephaly or macrocephaly is suspected in a fetus, it is often a challenge to counsel parents, especially when fetuses lack extreme head biometry or additional malformations. Accurate detection of those conditions is important to avoid overdiagnosis that might result in unjustified termination of pregnancy and underdiagnosis that might result in the birth of a child carrying an unfavorable prognosis.

There is no consensus in the literature regarding the neurodevelopmental outcome of infants with macrocephaly. An association between macrocephaly and low intelligence or cognitive or motor function is often reported,^{6,24,25} yet other publications describe healthy or even better functioning children.^{3,26,27} Information regarding the neurodevelopmental outcome of fetuses diagnosed in utero with macrocephaly is scarce. Biran-Gol et al⁵ found that an in utero sonographic finding of a head circumference between 2 and 3 SDs above the mean for gestational age, when no associated brain malformations are present, does not necessarily portend long-term abnormal neuropsychological development. They also acknowledged the low specificity of a fetal US-measured enlarged head circumference, raising the question of whether fetal sonography can accurately predict macrocephaly at birth. Here, we present similar results, because no correlation was found between a large supratentorial brain or cerebellum and neurodevelopmental outcomes of fetuses, meaning that even the finding of a large brain parenchymal volume on MR imaging does not indicate a poor neurologic prognosis.

The definition of fetal microcephaly is also a matter of controversy.^{7,28,29} MR imaging evaluation of the fetal brain is usually performed following the sonographic suspicion of microcephaly, allowing the assessment of the brain parenchyma directly and the gathering of more information regarding the development of the fetus's brain.⁹

The neurodevelopmental outcome of fetal microcephaly has been examined in different studies. Kurtz et al³⁰ argued that the measurement of fetal HC 1–3 SDs below the mean on a US examination carries a reasonable hope that the fetuses will develop normally. Stoler-Poria et al⁷ found a negative linear correlation between a smaller HC in utero and later cognitive function but no adverse neuropsychological outcomes in children with fetal HCs 2–3 SDs below the norm. According to the Society of Obstetricians and Gynecologists of Canada, when the HC measurement is lower than 3 SDs below the norm, it should be considered an anomaly.³¹ Deloison et al³² showed, in a relatively large population of fetuses with

US-measured HC lower than the 5th percentile, that those with poorer outcomes had other associated findings rather than isolated microcephaly. Our results were similar; we did not find any difference in the neurodevelopmental outcome of fetuses with brain biometry ≤ 3rd percentile, compared with the 4th to 96th percentiles.

A limitation of our study is that MR imaging examinations were performed in a relatively advanced week of gestation compared with those at other centers worldwide. This might be because suspicion of microcephaly and macrocephaly usually does not appear on US before the third trimester.^{5,33} This feature might also reflect the local policy that allows termination of pregnancy in the second and third trimesters in cases of suspected severe fetal disabilities including brain pathologies.³⁴ Furthermore, although the Vineland-II Adaptive Behavior scores are commonly applied in children of birth to toddler age, subtle developmental delays may not be apparent until an older age and might have been missed in this study.³⁵

This study is unique in that it focuses on microcephaly and macrocephaly, defined as abnormal head circumference findings, through the prism of measurements obtained on MR imaging. This feature is important because to our knowledge, no definitions of these pathologic conditions, when detected on MR imaging, are available. The strengths of this study are a relatively large cohort of fetuses and a long period of follow-up.

CONCLUSIONS

This study shows that developmental milestone achievements are unrelated to the MR imaging biometry of the fetal brain. This

information can be useful for physicians when counseling parents of fetuses with suspected microcephaly and macrocephaly detected on MR imaging. Further studies with additional data are needed to better reassure parents of fetuses with large and small brain biometry when MR imaging findings are normal.

REFERENCES

- DeRosa R, Lenke RR, Kurczynski TW, et al. **In utero diagnosis of benign fetal macrocephaly.** *Am J Obstet Gynecol* 1989;161:690–92 [CrossRef Medline](#)
- Chervenak FA, Jeanty P, Cantraine F, et al. **The diagnosis of fetal microcephaly.** *Am J Obstet Gynecol* 1984;149:512–57 [CrossRef Medline](#)
- Day RE, Schutt WH. **Normal children with large heads: benign familial megalencephaly.** *Arch Dis Child* 1979;54:512–17 [CrossRef Medline](#)
- Lewis BA, Aram DM, Horwitz SJ. **Language and motor findings in benign megalencephaly.** *Percept Mot Skills* 1989;68:1051–54 [CrossRef Medline](#)
- Biran-Gol Y, Malinge G, Cohen H, et al. **Developmental outcome of isolated fetal microcephaly.** *Ultrasound Obstet Gynecol* 2010;36:147–53 [CrossRef Medline](#)
- Petersson S, Pedersen NL, Schalling M, et al. **Primary megalencephaly at birth and low intelligence level.** *Neurology* 1999;53:1254–59 [CrossRef Medline](#)
- Stoler-Poria S, Lev D, Schweiger A, et al. **Developmental outcome of isolated fetal microcephaly.** *Ultrasound Obstet Gynecol* 2010;36:154–58 [CrossRef Medline](#)
- Leibovitz Z, Daniel-Spiegel E, Malinge G, et al. **Prediction of microcephaly at birth using three reference ranges for fetal head circumference: can we improve prenatal diagnosis?** *Ultrasound Obstet Gynecol* 2016;47:586–92 [CrossRef Medline](#)
- Nawathe A, Doherty J, Pandya P. **Fetal microcephaly.** *BMJ* 2018;361:k2232 [CrossRef Medline](#)
- Malinge G, Lev D, Ben-Sira L, et al. **Can syndromic macrocephaly be diagnosed in utero?** *Ultrasound Obstet Gynecol* 2011;37:72–81 [CrossRef Medline](#)
- Gafner M, Fried S, Goshier N, et al. **Fetal brain biometry: is there an agreement among ultrasound, MRI and the measurements at birth?** *Eur J Radiol* 2020;133:109369 [CrossRef Medline](#)
- Barzilay E, Bar-Yosef O, Dorembus S, et al. **Fetal brain anomalies associated with ventriculomegaly or asymmetry: an MRI-based study.** *AJNR Am J Neuroradiol* 2017;38:371–75 [CrossRef Medline](#)
- Ber R, Hoffman D, Hoffman C, et al. **Volume of structures in the fetal brain measured with a new semiautomated method.** *AJNR Am J Neuroradiol* 2017;38:2193–98 [CrossRef Medline](#)
- Ber R, Bar-Yosef O, Hoffmann C, et al. **Normal fetal posterior fossa in MR imaging: new biometric data and possible clinical significance.** *AJNR Am J Neuroradiol* 2015;36:795–802 [CrossRef Medline](#)
- Gafner M, Yagel I, Fried S, et al. **Fetal brain biometry in isolated mega cisterna magna: MRI and US study.** *J Matern Neonatal Med* 2020;1–9 [CrossRef Medline](#)
- Polat A, Barlow S, Ber R, et al. **Volumetric MRI study of the intrauterine growth restriction fetal brain.** *Eur Radiol* 2017;27:2110–18 [CrossRef Medline](#)
- Olshaker H, Ber R, Hoffman D, et al. **Volumetric brain MRI study in fetuses with congenital heart disease.** *AJNR Am J Neuroradiol* 2018;39:1164–69 [CrossRef Medline](#)
- Tilea B, Alberti C, Adamsbaum C, et al. **Cerebral biometry in fetal magnetic resonance imaging: new reference data.** *Ultrasound Obstet Gynecol* 2009;33:173–81 [CrossRef Medline](#)
- Sparrow SS, Cicchetti DV, Balla DA. **The Vineland Adaptive Behavior Scales, 2nd ed.** In: *Newmark CS. Major Psychological Assessment Instruments.* Allyn & Bacon 2005
- Chatham CH, Taylor KI, Charman T, et al. **Adaptive behavior in autism: minimal clinically important differences on the Vineland-II.** *Autism Res* 2018;11:270–83 [CrossRef Medline](#)
- Sparrow SS, Cicchetti DV. **Diagnostic uses of the Vineland adaptive behavior scales.** *J Pediatr Psychol* 1985;10:215–25 [CrossRef Medline](#)
- Grinberg A, Katorza E, Hoffman D, et al. **Volumetric MRI study of the brain in fetuses with intrauterine cytomegalovirus infection and its correlation to neurodevelopmental outcome.** *AJNR Am J Neuroradiol* 2019;40:353–58 [CrossRef Medline](#)
- Cicchetti DV. **Guidelines, criteria, and rules of thumb for evaluating normed and standardized assessment instruments in psychology.** *Psychol Assess* 1994;6:284–90 [CrossRef](#)
- DeMyer W. **Megalencephaly: types, clinical syndromes, and management.** *Pediatr Neurol* 1986;2:321–28 [CrossRef Medline](#)
- Muenchberger H, Assaad N, Joy P, et al. **Idiopathic macrocephaly in the infant: Long-term neurological and neuropsychological outcome.** *Childs Nerv Syst* 2006;22:1242–48 [CrossRef Medline](#)
- Lorber J, Priestley BL. **Children with large heads: a practical approach to diagnosis in 557 children, with special reference to 109 children with megalencephaly.** *Dev Med Child Neurol* 1981;23:494–504 [CrossRef Medline](#)
- Gooskens RH, Willemse J, Faber JA, et al. **Macrocephalies: a differentiated approach.** *Neuropediatrics* 1989;20:164–69 [CrossRef Medline](#)
- Berger I. **Prenatal microcephaly: can we be more accurate?** *J Child Neurol* 2009;24:97–100 [CrossRef Medline](#)
- Gelber SE, Grünebaum A, Chervenak FA. **Prenatal screening for microcephaly: an update after three decades.** *J Perinat Med* 2017;45:167–70 [CrossRef Medline](#)
- Kurtz AB, Wapner RJ, Rubin CS, et al. **Ultrasound criteria for in utero diagnosis of microcephaly.** *J Clin Ultrasound* 1980;8:11–16 [CrossRef Medline](#)
- De Bie I, Boucoiran I. **No. 380: investigation and management of prenatally identified microcephaly.** *J Obstet Gynaecol Canada* 2019;41:855–61 [CrossRef Medline](#)
- Deloison B, Chalouhi GE, Bernard JP, et al. **Outcomes of fetuses with small head circumference on second-trimester ultrasonography.** *Prenat Diagn* 2012;32:869–74 [CrossRef Medline](#)
- Malinge G, Lerman-Sagie T, Waternberg N, et al. **A normal second-trimester ultrasound does not exclude intracranial structural pathology.** *Ultrasound Obstet Gynecol* 2002;20:51–56 [CrossRef Medline](#)
- Gat I, Hoffmann C, Shashar D, et al. **Fetal brain MRI: novel classification and contribution to sonography.** *Ultraschall Med* 2016;37:176–84 [CrossRef Medline](#)
- Salomon-Estebanez M, Mohamed Z, Michaelidou M, et al. **Vineland adaptive behavior scales to identify neurodevelopmental problems in children with congenital hyperinsulinism (CHI).** *Orphanet J Rare Dis* 2017;12:96 [CrossRef Medline](#)