



Discover Generics

Cost-Effective CT & MRI Contrast Agents

**FRESENIUS
KABI**

[VIEW CATALOG](#)

AJNR

This information is current as
of September 7, 2025.

Dandy-Walker Phenotype with Brainstem Involvement: 2 Distinct Subgroups with Different Prognosis
























C.A.P.F. Alves, J. Sidpra, A. Manteghinejad, S. Sudhakar, F.V. Massey, K.A. Aldinger, P. Haldipur, L.T. Lucato, S.F. Ferracioli, S.R. Teixeira, Ö. Öztekin, D. Bhattacharya, A. Taranath, S.P. Prabhu, D.M. Mirsky, S. Andronikou, K.J. Millen, A.J. Barkovich, E. Boltshauser, W.B. Dobyns, M.J. Barkovich, M.T. Whitehead and K. Mankad

AJNR Am J Neuroradiol 2023, 44 (10) 1201-1207

doi: <https://doi.org/10.3174/ajnr.A7967>

<http://www.ajnr.org/content/44/10/1201>

Dandy-Walker Phenotype with Brainstem Involvement: 2 Distinct Subgroups with Different Prognosis

 C.A.P.F. Alves,  J. Sidpra,  A. Manteghinejad,  S. Sudhakar,  F.V. Massey,  K.A. Aldinger,  P. Haldipur,  L.T. Lucato,  S.F. Ferracioli,  S.R. Teixeira,  Ö. Öztekin,  D. Bhattacharya,  A. Taranath,  S.P. Prabhu,  D.M. Mirsky,  S. Andronikou,  K.J. Millen,  A.J. Barkovich,  E. Boltshauser,  W.B. Dobyns,  M.J. Barkovich,  M.T. Whitehead, and  K. Mankad



ABSTRACT

BACKGROUND AND PURPOSE: Although cardinal imaging features for the diagnostic criteria of the Dandy-Walker phenotype have been recently defined, there is a large range of unreported malformations among these patients. The brainstem, in particular, deserves careful attention because malformations in this region have potentially important implications for clinical outcomes. In this article, we offer detailed information on the association of brainstem dysgenesis in a large, multicentric cohort of patients with the Dandy-Walker phenotype, defining different subtypes of involvement and their potential clinical impact.

MATERIALS AND METHODS: In this established multicenter cohort of 329 patients with the Dandy-Walker phenotype, we include and retrospectively review the MR imaging studies and clinical records of 73 subjects with additional brainstem malformations. Detailed evaluation of the different patterns of brainstem involvement and their potential clinical implications, along with comparisons between posterior fossa measurements for the diagnosis of the Dandy-Walker phenotype, was performed among the different subgroups of patients with brainstem involvement.

RESULTS: There were 2 major forms of brainstem involvement in patients with Dandy-Walker phenotype including the following: 1) the mild form with anteroposterior disproportions of the brainstem structures “only” (57/73; 78%), most frequently with pontine hypoplasia (44/57; 77%), and 2) the severe form with patients with tegmental dysplasia with folding, bumps, and/or clefts (16/73; 22%). Patients with severe forms of brainstem malformation had significantly increased rates of massive ventriculomegaly, additional malformations involving the corpus callosum and gray matter, and interhemispheric cysts. Clinically, patients with the severe form had significantly increased rates of bulbar dysfunction, seizures, and mortality.

CONCLUSIONS: Additional brainstem malformations in patients with the Dandy-Walker phenotype can be divided into 2 major subgroups: mild and severe. The severe form, though less prevalent, has characteristic imaging features, including tegmental folding, bumps, and clefts, and is directly associated with a more severe clinical presentation and increased mortality.

ABBREVIATION: DW = Dandy-Walker phenotype

Cystic malformations of the posterior fossa manifest with varied imaging patterns and diagnoses and have a broad range of etiologies and clinical outcomes.¹ A classic disorder captured in this group is the historically termed Dandy-Walker malformation,

now Dandy-Walker phenotype (DW). Several causes have been implicated in the pathogenesis of DW, including chromosomal abnormalities and genetic variants,²⁻⁷ disruptive/acquired events in fetal life such as prenatal exposure to viruses, drugs, and

Received May 15, 2023; accepted after revision July 18.

From the Division of Neuroradiology (C.A.P.F.A., A.M., S.R.T., S.A., M.T.W.), Department of Radiology, Children’s Hospital of Philadelphia, Philadelphia, Pennsylvania; Unit of Neuroradiology (J.S., S.S., K.M.), Great Ormond Street Hospital for Children, National Health Service Foundation Trust, London, United Kingdom; Developmental Biology & Cancer Section (J.S., K.M.), University College London Great Ormond Street Institute of Child Health, London, United Kingdom; Unit of Functional Neurosurgery (F.V.M.), National Hospital for Neurology & Neurosurgery, London, UK; Center for Integrative Brain Research (K.A.A., P.H., K.J.M.), Seattle Children’s Research Institute, Seattle, Washington; Departments of Pediatrics and Neurology (K.A.A., P.H., K.J.M.), University of Washington, Seattle, Washington; Department of Radiology, Division of Neuroradiology (L.T.L., S.F.F.), Hospital das Clínicas da Faculdade de Medicina da Universidade de São Paulo, São Paulo, Brazil; Department of Neuroradiology (Ö.Ö.), Bakırçay University, Çi li Education and Research Hospital, İzmir, Turkey; Department of Neuroradiology (D.B.), Royal Victoria

Hospital, Belfast, UK; Department of Medical Imaging (A.T.), Women’s and Children’s Hospital, Adelaide, South Australia, Australia; Department of Radiology, Neuroradiology Division (S.P.P.), Boston Children’s Hospital, Boston, Massachusetts; Department of Radiology, Neuroradiology Division (D.M.M.), Children’s Hospital Colorado, Aurora, Colorado; Department of Neuroradiology (A.J.B., M.J.B.), University of California, San Francisco, San Francisco, California; Department of Pediatric Neurology (E.B.), University Children’s Hospital, Zürich, Switzerland; and Department of Genetics and Metabolism (W.B.D.), University of Minnesota, Minneapolis, Minnesota. Please address correspondence to Cesar Augusto Alves, MD, PhD, Division of Neuroradiology, Department of Radiology, Children’s Hospital of Philadelphia, 324 South 34th St, Philadelphia, PA 19104; e-mail: alvesc@chop.edu; @cesaralvesneuro

 Indicates article with online supplemental data.

<http://dx.doi.org/10.3174/ajnr.A7967>

maternal ill-health^{8,9} as well as fetal sporadic posthemorrhagic cerebellar events.^{10,11} However, there have also been recent modifications in formerly well-established associations. For example, the previously reported association between congenital melanocytic nevus syndrome and DW¹² has been re-evaluated in a recent case report and literature review that emphasizes a potential misleading connection between these 2 disorders.¹³ Nevertheless, it is important to note that mesenchymal-based gene action has been shown to play a role in the development of the Dandy-Walker phenotype in some circumstances.¹⁴

Although cardinal imaging features for the diagnostic criteria of DW have recently been defined by our group,¹⁵ there is a large variability of additional unreported malformations in children with DW. DW encompasses a broad range of many potential associated abnormalities, most of them recognized in the supratentorial brain, such as agenesis/dysgenesis of the corpus callosum, hydrocephalus, and abnormalities of cortical migration, among others.^{16,17}

Contrary to the frequent description of supratentorial findings, brainstem involvement in patients with DW is far less frequently cited in the literature. Nevertheless, the brainstem is frequently involved,¹⁵ and unsurprisingly so, given that its development is closely related to that of the cerebellum.¹⁸⁻²⁰ Furthermore, when affected, the brainstem is likely to have a major impact on the brainstem and cerebellar circuitry essential for normal function.²¹ Proper brainstem function is essential for autonomic nervous system functions (ie, breathing, heart rate). Thus, brainstem involvement in DW requires critical attention due to its potential role in the pathogenesis and clinical outcome of these patients.²⁰

In this article, we present detailed information on the brainstem abnormalities found in patients with DW, including the variability of imaging patterns, their potential implications for human neurodevelopment, and their clinical impact.

MATERIALS AND METHODS

This retrospective multicenter, multinational study focuses on a subset group of patients with DW with brainstem malformations. These patients were selected from a previously published cohort of 329 patients who were confirmed to have DW on the basis of the modern diagnostic radiologic criteria established by Whitehead et al.¹⁵ Among the 329 patients, 220 showed some degree of dysmorphism. Of these, 147 (67%) had extrinsic mass effect caused by the surrounding structures, which provided a better explanation for their brainstem abnormality, for example the compression of the brainstem against the clivus, most commonly due to hydrocephalus. Since no definitive signs of primary brainstem dysgenesis were observed in this particular subset of patients, these patients were excluded. For our analysis, we included and retrospectively reviewed the MR imaging studies and clinical records of a cohort of 73 patients with DW and brainstem malformations. We provide a detailed evaluation of the different brainstem malformative findings, including the following:

1. The brainstem region involved (midbrain/tectum, pons, and/or medulla oblongata)
2. Features of hypoplasia or hyperplasia of each of the brainstem segments and their ratios to categorize potential developmental anterior-posterior patterning defects²⁴

3. Malformation of the brainstem with abnormalities resulting in deformity of normal brainstem architecture (abnormal folding, bumps, and clefts) and disturbances of axonal orientation and/or guidance
4. Additional supratentorial malformations, such as abnormalities of cortical migration, commissural dysgenesis/agenesis, and the presence of cerebral interhemispheric cysts.

Qualitative analyses and quantitative measures including size and morphology of the posterior fossa and choroid plexus, taenia tela choroidea complex location, and torcular location were performed following our previous standardized approach.¹⁵ Neuroimaging evidence of prior injury (hemorrhage and/or encephalomalacia) was also reviewed, and comparisons of all variables were performed to search for potential differences and to define subgroups in our cohort.

All cases were independently reviewed by senior neuroradiologists at each participating institution, and clinical and radiologic features were recorded. Qualitative and quantitative measures and the reporting of additional brainstem malformations were reviewed via independent analysis by the first author (C.A.P.F.A.). Subsequently, all discrepancies and disagreement were solved by a third reviewer (K.J.M.), a pediatric neuroradiologist with >15 years of experience, and a final consensus with the first author (C.A.P.F.A.) was determined for those discrepant cases. The minimum requirements for the inclusion of postnatal MR imaging were having at least 2 series of T1-weighted imaging and T2-weighted imaging with section thicknesses of ≤ 5 mm. Additional sequences were reviewed in most cases (when available). All MR imaging was performed at 1.5T or 3T.

Continuous variables are presented as the mean (SD), while categorical variables are presented as the percentage frequency. The Kolmogorov-Smirnov test was used to examine the normality of continuous variables, and the Mann-Whitney *U* test was used to assess differences among continuous variables. The Pearson χ^2 test and Fisher exact test were used to evaluate the associative significance between 2 categorical variables. Statistical analyses were performed using the Statistical Package for the Social Sciences (SPSS, Version 26; IBM).

The study was conducted after site-specific institutional review board approval with informed consent waived due to its retrospective nature.

RESULTS

Seventy-three patients (44 female, 60.3%; 29 male, 39.7%) were eligible for inclusion (age range, 1 day to 24 years of age). Fifty-seven MR images (78.1%) were obtained using 1.5T scanners, and 16 (21.9%) were obtained using 3T scanners. Genetic abnormalities were present as the presumed cause of DW in 22 (30.1%) patients. Fifteen patients presented with known risk factors for DW: Eight (11%) had vascular injuries; 5 (6.8%) were associated with maternal diseases, including maternal diabetes and congenital heart disease; and 2 (2.7%) were associated with prenatal infections, including prenatal cytomegalovirus. In the remaining 36 (49.3%) patients, there were no known risk factors, and no genetic analysis was performed. The complete descriptive analysis of study subjects is available in the [Table 1](#).

Table 1: Descriptive analysis of patients with DW with brainstem involvement

Variable	
Sex (No.) (%)	
Male	29 (39.7%)
Female	44 (60.3%)
Age	
Age (mo)	25 mo (IQR = 10 days to 15.6 mo)
Birth status (No.) (%)	
Premature	20 (27.4%)
Full-term	35 (47.9%)
Unknown	18 (24.7%)
Imaging features (No.) (%)	
Severe macrocrania	24 (32.9%)
Extreme vermian hypoplasia	12 (16.4%)
Cerebellar dysplasia	27 (37%)
Anteroposterior disproportion	67 (91.8%)
Hydrocephalus	43 (58.9%)
Corpus callosum agenesis	37 (50.7%)
Interhemispheric cyst	11 (15.1%)
Gray matter migration	18 (24.7%)
Calcification or hemorrhage	12 (16.4%)
Fastigial recess angle (mean)	167.1° (SD, 46.6°)
Posterior fossa perimeter (mean) (mm)	172.4 (SD, 110.6)
Clinical features (No.) (%)	
Seizure	31 (42.5%)
Artificial airway dependency	32 (43.8%)
Enteral feeding tube dependency	40 (54.8%)
Mortality	15 (20.5%)

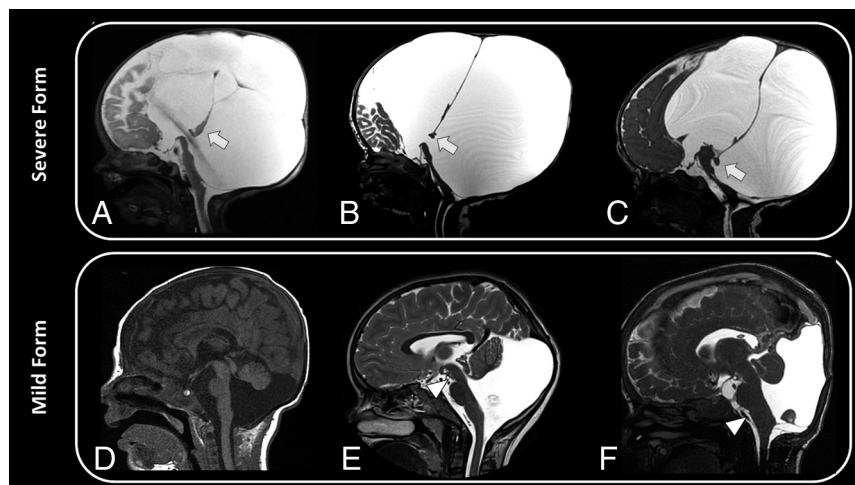


FIG 1. A severe form of brainstem malformation in 3 different patients (A–C): Sagittal T2WI demonstrates a massive enlargement of the posterior fossa with severe hypoplasia and deformity of the vermian (arrows, A–C) and elevation of the torcula. There is associated agenesis of the corpus callosum, severe hydrocephalus, and interhemispheric cysts. A mild form of brainstem malformation in 3 different patients (D–F): Sagittal T1WI (D) shows hypoplasia and rotational displacement of the inferior cerebellar vermian associated with hypoplasia of the pons. Sagittal T2WI (E and F) shows a disproportionately increased craniocaudal size of the midbrain (arrowhead, E) and diffusely increased size of the medulla (arrowhead, F).

Two subgroups of brainstem malformations were observed in our DW cohort with forms defined as the following: 1) mild, 57 (78.1%) patients with changes limited to the size and proportion of the brainstem structures, and 2) severe, 16 (21.9%) patients in whom malformation of the brainstem included posterior tegmental dysplasia with an abnormal posterior fold, bumps, and clefts in the tegmentum (Figs 1 and 2). The comparative

imaging and clinical analyses of these 2 groups are presented in the Table 2. The Kolmogorov-Smirnov test was used to evaluate the normality of the posterior fossa perimeter and fastigial recess angle, with *P* values of .001 and .019, respectively. Therefore, due to the significant difference between these 2 variable distributions from a normal distribution, the Mann-Whitney *U* test was used to compare these 2 variables between the groups.

The mild form of brainstem malformation in the DW cohort was characterized mainly by the presence of pontine hypoplasia (44/57; 77%) and, more rarely, hypoplasia or hyperplasia of other segments of the brainstem, including the medulla and midbrain/tectum (13/57; 23%) (Fig 1).

Patients in the severe brainstem DW cohort had more complex malformations: All presented with tegmental dysgenesis characterized by architectural disorganization of ≥ 1 segment of the brainstem, including evidence of a posterior folding, bumps, or clefts, with flattening of the ventral portions of the brainstem, imaging features with parallels to those of axonal guidance disturbance noted in patients with tegmental and bulbar cap dysplasia (Fig 3 and Online Supplemental Data).^{22,23} Among the significant imaging features observed in this group, the most important findings to highlight include macrocrania in 10 (62.5%), mostly secondary to severe ventriculomegaly; massive enlargement of the posterior fossa and increased rates of the extreme vermian hypoplasia in 9 (56.3%); increased rates of additional malformative features involving the corpus callosum in 12 (75.0%) patients, cerebral interhemispheric cysts in 9 (56.3%) subjects (Fig 4), and gray matter abnormalities in 10 (62.5%) patients compared with the mild group. Clinical differences were also observed between groups, including increased rates of bulbar dysfunction in 12 (75%) patients and seizures in 11 (68.8%) patients from the severe group, findings indicative of a more severe clinical presentation, revealed by increased mortality in 7 (46.7%) patients, all with bulbar dysfunction.

Among the 73 patients, genetic causes were noted in 22 (30.1%), 5 of 16 (31.2%) had severe brainstem involvement, while 17 of 57 (29.8%) had mild brainstem involvement. No statistical

differences were noted between subgroups. The most common results included 3 patients with trisomy 13, 2 patients with tetrasomy 9p, 2 patients with chromosome 6 deletion involving the *FOXC1* gene, 2 patients with *KMT2D* mutation (Kabuki syndrome), and 2 patients unbalanced X:3 translocations: arr[hg19] Xp22.33p21.2(168,547–29,318,254) x3.

DISCUSSION

Neurologic development is variable in patients with DW,¹ with the clinical course depending not only on the degree of cerebellar hypoplasia but also on the extent and severity of associated CNS malformations. In this study, patients with DW with associated brainstem involvement were evaluated to understand the potential imaging variability of malformations in this structure, their potential associations, and its clinical impact on the DW population. Although all patients with DW and brainstem

involvement shared characteristic posterior fossa cystic malformation with the required features for the current diagnostic criteria,¹⁵ there were 2 different imaging groups of patients with brainstem involvement: 1) those with the mild form: considered a less severe phenotype in which changes were related only to the size and proportion of the brainstem structures (anterior-posterior embryologic defect);²⁴ and 2) those with the severe form in which an additional dysgenetic appearance of the brainstem was noted, with a peculiar posterior tegmentum fold, bump, and cleft. In line with our concept of the critical role of the brainstem in neurologic functions, these patients with extensive morphologic abnormalities in the brainstem were also more severely affected clinically, including a significantly increased frequency of bulbar and other autonomic nervous system dysfunctions, seizures, and higher mortality rates, compared with the mild form. From the genetic perspective, we

noted that genetic abnormalities and associated syndromes in our DW cohort with brainstem malformation (30%) are almost 2 times higher than expected in the overall DW population (16%).³ This observed difference suggests that patients with DW with brainstem malformations may be better candidates for an extensive genetic work-up.

The mild brainstem phenotype was the most frequent form in our cohort (78%), characterized mainly by the presence of pontine hypoplasia and, more rarely, hypoplasia or hyperplasia of other segments of the brainstem, including the medulla and midbrain. Apart from the brainstem dysmorphology resulting from a presumed abnormal embryologic anteroposterior

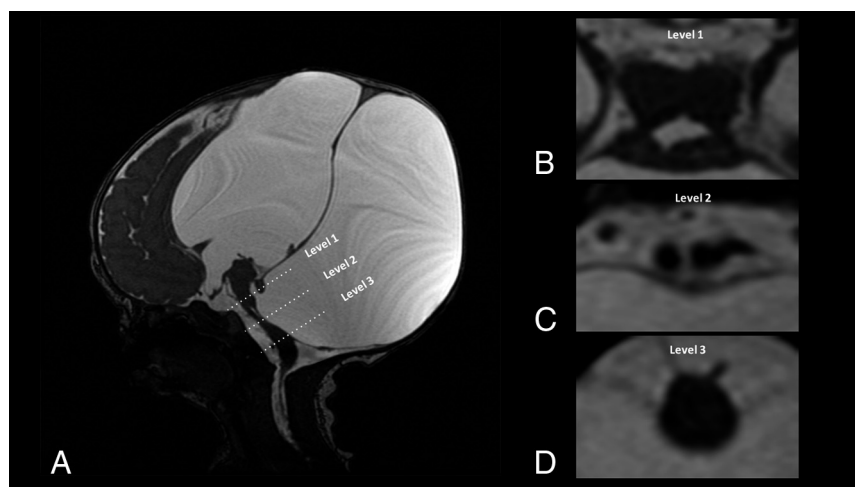


FIG 2. A severe form of brainstem malformation with tegmental dysplasia: Sagittal and axial T2WI demonstrates 3 different craniocaudal brainstem levels, including a complete cleft of the pons (C, level 2). There is associated agenesis of the corpus callosum, severe hydrocephalus, and interhemispheric cyst.

Table 2: Comparison of imaging and clinical characteristics between patient groups by the presence of a tegmental brainstem dysplasia (severe brainstem malformation)

Variable	Tegmental Brainstem Dysplasia (No.) (%)		OR (95% CI)	P Value
	Present (Severe Group)	Absent (Mild Group)		
Mortality	7 (46.7%)	8 (15.1%)	4.922 (1.392–17.399)	.01 ^a
Severe macrocrania	10 (62.5%)	14 (24.6%)	5.119 (1.576–16.629)	.004 ^b
Prematurity	6 (42.87%)	14 (34.4%)	1.446 (0.419–4.997)	.559 ^a
Genetic abnormalities	5 (31.2%)	17 (29.8%)	1.912 (0.319–11.471)	.677 ^b
Bulbar dysfunction	12 (75%)	20 (36.4%)	5.250 (1.492–18.470)	.006 ^a
Enteral feeding tube dependency	12 (75%)	28 (50.9%)	2.893 (0.830–10.087)	.087 ^a
Seizure	11 (68.%)	20 (35.7%)	3.960 (1.205–13.018)	.019 ^a
Extreme vermian hypoplasia	9 (56.25%)	3 (5.3%)	23.143 (5.034–106.401)	<.001 ^b
Cerebellar dysplasia	11 (68.8%)	16 (28.1%)	5.638 (1.690–18.805)	.003 ^a
Hydrocephalus	13 (81.3%)	30 (52.6%)	3.900 (1.002–15.177)	.04 ^a
Corpus callosum agenesis	12 (75.0%)	25 (43.9%)	3.840 (1.104–13.358)	.028 ^a
Interhemispheric cyst	9 (56.3%)	2 (3.5%)	35.357 (6.317–197.9)	<.001 ^b
Gray matter migration	10 (62.5%)	8 (14%)	10.208 (2.901–35.923)	<.001 ^b
Calcification or hemorrhage	4 (25%)	8 (14%)	2.042 (0.526–7.924)	.444 ^b
Posterior fossa perimeter (mean) (mm)	252.4 (SD, 110.3)	149.94 (SD, 100.6)	—	.002 ^c

Note:—En dash indicates not applicable.

^a Pearson χ^2 test.

^b Fisher exact test.

^c Mann-Whitney *U* test.

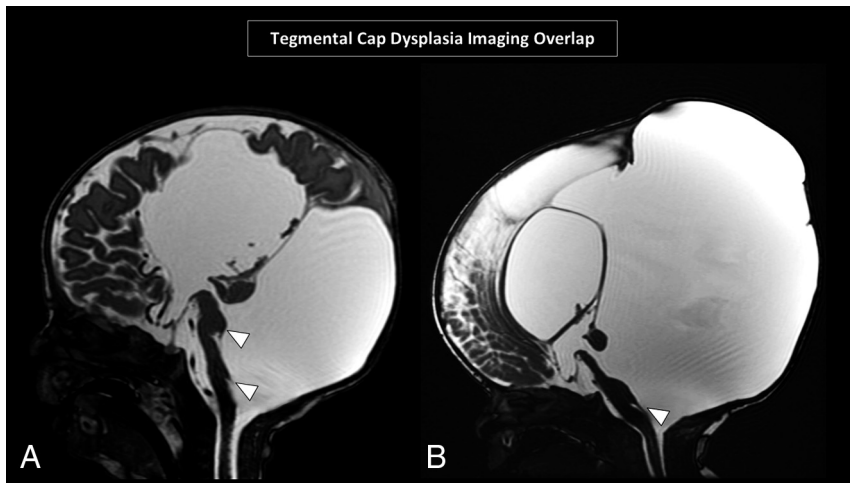


FIG 3. Two patients with severe brainstem malformations and DW. Sagittal T2WI shows severe deformity of the brainstem and flattening of the pons associated with abnormalities of the tegmentum, including a posterior cleft and white matter bump (arrowheads), overlapping features with tegmental cap dysplasia.

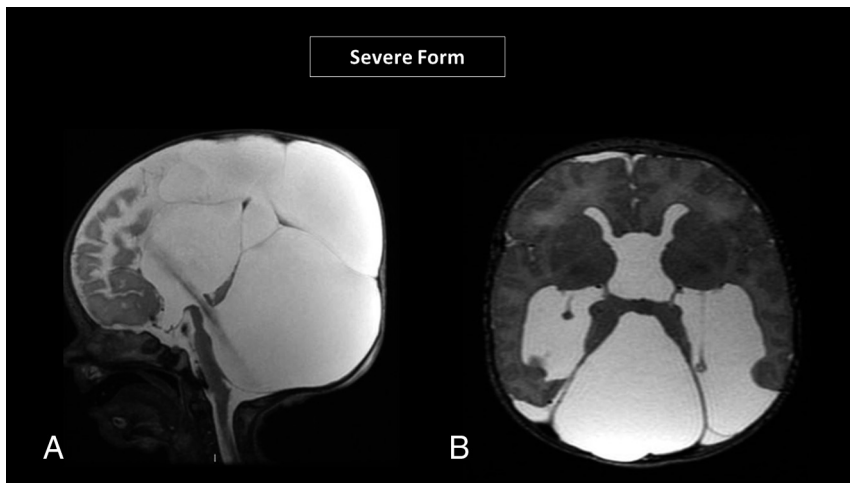


FIG 4. Sagittal (A) and axial T2WI (B) highlighting imaging features of a severe form of DW with brainstem malformation, including massive hydrocephalus and massive enlargement of the posterior fossa, along with complete agenesis of the corpus callosum and interhemispheric cysts.

defect, the measurements and appearance of the posterior fossa, including posterior fossa perimeter, fastigial angle blunting, and choroid plexus/taenia tela choroidea complex morphology, were not significantly different from those in the overall cohort already described in 2022.¹⁵ There were also no differences between the additional abnormalities of the brain or clinical features commonly noted among patients with DW.^{25,26}

Patients with severe brainstem malformation, on the other hand, had additional findings that clearly distinguish them from the mild brainstem DW cohort. In particular, we identified the presence of a posterior tegmental dysplasia as a hallmark of this group. The patients with tegmental brainstem dysplasia characterized by folding, bumps, and clefts in the tegmentum were highly associated with having more severe/extreme vermian hypoplasia, massive hydrocephalus, and larger posterior fossa perimeters compared with the mild brainstem subgroup. Additionally, dysgenesis and agenesis of the corpus callosum

and supratentorial interhemispheric cysts were significantly associated with this phenotype. Most interesting, during the retrospective imaging review and analysis, we noted that some of the patients with brainstem tegmentum dysplasia shared similar features already described in tegmental and bulbar cap dysplasias, including focal posterior protuberance of the brainstem with a small and flat pons, features related to an underlying abnormal axonal guidance pathophysiology.^{22,23} These phenotypic similarities shed light on the likely embryologic developmental intersection between both disorders.

There is substantial evidence that disruption of the rhombic lip underlies the cerebellar DW.^{27,28} The rhombic lip is a progenitor zone located along the dorsal edge of the hindbrain in the rhombomere, one of the anterior hindbrains adjacent to the roof of the fourth ventricle. It gives rise to multiple cell lines that are relevant to the phenotypes we have described in this report. Progenitors from rhombomere 1 rhombic lip develop into cerebellar granule cell progenitors, which migrate over the cerebellar anlage and then undergo massive proliferation, driving most cerebellar growth.²⁸ Earlier in development, these progenitors also give rise to the glutamatergic pontine nuclei neurons, which earlier migrate over the developing cerebellar anlage and continue ventrally to form the pontine nuclei at the brainstem.¹⁸⁻²⁰ Failure of generation and/or migration of these early-born brainstem neurons in mice

results in phenotypes similar to those seen in our patient population.²⁰ Additionally, rhombic lip progenitors from rhombomere 1 and other more posterior hindbrain regions also give rise to choroid plexus epithelial cells, which play a role in the expansion of the fourth ventricle plexus from its lateral edges. Mouse models have shown that very early misspecification of cerebellar rhombic lip progenitors toward the choroid plexus fate, at the expense of cerebellar and brainstem fates, contributes to the expansion of the fourth ventricle roof and both cerebellar and brainstem hypoplasia.^{14,29,30}

Therefore, the simultaneous association of brainstem and cerebellar malformation and even fourth ventricle expansion is anticipated in patients with DW. The severity of these abnormalities is likely related to the timing and extent of the insult during early embryologic stages. Early insults during the critical period of rhombic lip development can lead to more severe and extensive abnormalities, whereas insults occurring later in development

may result in milder phenotypes. Thus, the precise timing and extent of the disruption to the rhombic lip progenitors determine the severity of the disorder, emphasizing the importance of early embryologic events in shaping the neurologic outcomes in individuals with DW.

The variability of neuroimaging findings from mild to severe brainstem groups associated with varied severity of clinical presentations and outcomes as well as different rates of underlying genetic causes reinforce the importance of detailed imaging descriptions and neuroimaging stratification to improve the understanding of these conditions and to better support neurologists and geneticists in the clinical care and genetic counseling of these patients and their families. In patients with DW, the brainstem should be carefully scrutinized for differences in size, shape, and/or proportions. Direct comparison with aged-matched normal brain MR imaging examinations may be useful in questionable cases.

Although our study yielded notable findings, it is important to acknowledge its limitations. First, the retrospective study design and cross-sectional analysis focused primarily on postnatal studies. This approach overlooked the consideration of neurodevelopmental outcomes and prenatal imaging findings, which could have provided valuable insights. As a result, there is the possibility of selection and misclassification bias within our groups, which hinders the establishment of a stronger causal relationship. To enhance the reliability of our conclusions, future research should address these limitations by incorporating prospective designs, comprehensive assessments of prenatal factors, and animal model studies. Another limitation was the small number of severe cases in which DW and posterior dysplasia of the brainstem were noted. However, given that these cases were collected from numerous tertiary referral centers with expertise in pediatric neuroimaging, this small number may reflect the true rarity of severe brainstem dysplasia in postnatal life.

CONCLUSIONS

It is of paramount importance to recognize additional brainstem malformations in patients with DW. These malformations can be divided into 2 major subgroups, mild and severe. The severe form, though less prevalent, has characteristic imaging features, including a tegmental dysplasia, and is associated with a more severe clinical presentation that is directly related to brainstem dysfunction and increased mortality.

Disclosure forms provided by the authors are available with the full text and PDF of this article at www.ajnr.org.

REFERENCES

- Hirsch JF, Pierre-Kahn A, Renier D, et al. **The Dandy-Walker malformation: a review of 40 cases.** *J Neurosurg* 1984;61:515–22 [CrossRef Medline](#)
- Grinberg I, Northrup H, Ardinger H, et al. **Heterozygous deletion of the linked genes *ZIC1* and *ZIC4* is involved in Dandy-Walker malformation.** *Nat Genet* 2004;36:1053–55 [CrossRef Medline](#)
- Aldinger KA, Timms AE, Thomson Z, et al. **Redefining the etiologic landscape of cerebellar malformations.** *Am J Hum Genet* 2019;105:606–15 [CrossRef Medline](#)
- Aldinger KA, Lehmann OJ, Hudgins L, et al. ***FOXC1* is required for normal cerebellar development and is a major contributor to chromosome 6p25.3 Dandy-Walker malformation.** *Nat Genet* 2009;41:1037–42 [CrossRef Medline](#)
- Jalali A, Aldinger KA, Chary A, et al. **Linkage to chromosome 2q36.1 in autosomal dominant Dandy-Walker malformation with occipital cephalocele and evidence for genetic heterogeneity.** *Hum Genet* 2008;123:237–45 [CrossRef Medline](#)
- Yahyaoui R, Espinosa MG, Gómez C, et al. **Neonatal carnitine palmitoyltransferase II deficiency associated with Dandy-Walker syndrome and sudden death.** *Mol Genet Metab* 2011;104:414–16 [CrossRef Medline](#)
- Liao C, Fu F, Li R, et al. **Dandy-Walker syndrome and microdeletions on chromosome 7 [in Chinese].** *Zhonghua Yi Xue Yi Chuan Xue Za Zhi* 2012;29:48–51 [CrossRef Medline](#)
- Murray JC, Johnson JA, Bird TD. **Dandy-Walker malformation: etiologic heterogeneity and empiric recurrence risks.** *Clin Genet* 1985;28:272–83 [CrossRef Medline](#)
- Soares de Oliveira-Szejnfeld P, Levine D, de Oliveira Melo AS, et al. **Congenital brain abnormalities and Zika virus: what the radiologist can expect to see prenatally and postnatally.** *Radiology* 2016;281:203–18 [CrossRef Medline](#)
- Limperopoulos C, Folkert R, Barnewolt CE, et al. **Posthemorrhagic cerebellar disruption mimicking Dandy-Walker malformation: fetal imaging and neuropathology findings.** *Semin Pediatr Neurol* 2010;17:75–81 [CrossRef Medline](#)
- Pichiecchio A, Decio A, Di Perri C, et al. **Acquired Dandy-Walker malformation and cerebellar hemorrhage: usefulness of serial MRI.** *Eur J Paediatr Neurol* 2016;20:188–91 [CrossRef Medline](#)
- Cho YI, Hwang SK, Kim SH. **Dandy-Walker malformation associated with neurocutaneous melanosis.** *J Korean Neurosurg Soc* 2011;50:475–77 [CrossRef Medline](#)
- Di Stasi M, Mankad K, Carney O, et al. **Congenital melanocytic naevus syndrome and Dandy-Walker malformation: a mistaken association: case report and literature review.** *Neuroradiology* 2023;65:1077–86 [CrossRef Medline](#)
- Haldipur P, Gillies GS, Janson OK, et al. ***FOXC1* dependent mesenchymal signalling drives embryonic cerebellar growth.** *Elife* 2014;3:e03962 [CrossRef Medline](#)
- Whitehead MT, Barkovich MJ, Sidpra J, et al. **Refining the neuroimaging definition of the Dandy-Walker phenotype.** *AJNR Am J Neuroradiol* 2022;43:1488–93 [CrossRef Medline](#)
- Stroustrup Smith A, Levine D. **Appearance of an interhemispheric cyst associated with agenesis of the corpus callosum.** *AJNR Am J Neuroradiol* 2004;25:1037–40 [Medline](#)
- Spennato P, Mirone G, Nastro A, et al. **Hydrocephalus in Dandy-Walker malformation.** *Childs Nerv Syst* 2011;27:1665–81 [CrossRef Medline](#)
- Watson C, Bartholomaeus C, Puelles L. **Time for radical changes in brainstem nomenclature-applying the lessons from developmental gene patterns.** *Front Neuroanat* 2019;13:10 [CrossRef Medline](#)
- Leto K, Arancillo M, Becker EB, et al. **Consensus paper: cerebellar development.** *Cerebellum* 2016;15:789–828 [CrossRef Medline](#)
- Kratochwil CF, Maheshwari U, Rijli FM. **The long journey of pontine nuclei neurons: from rhombic lip to cortico-ponto-cerebellar circuitry.** *Front Neural Circuits* 2017;11:33 [CrossRef Medline](#)
- D'Angelo E. **Physiology of the cerebellum.** *Handb Clin Neurol* 2018;154:85–108 [CrossRef](#)
- Jissendi-Tchofo P, Doherty D, McGillivray G, et al. **Pontine tegmental cap dysplasia: MR imaging and diffusion tensor imaging features of impaired axonal navigation.** *AJNR Am J Neuroradiol* 2009;30:113–19 [CrossRef Medline](#)
- Gafner M, Garel C, Leibovitz Z, et al. **Medullary tegmental cap dysplasia: fetal and postnatal presentations of a unique brainstem malformation.** *AJNR Am J Neuroradiol* 2023;44:334–40 [CrossRef Medline](#)
- Barkovich AJ, Millen KJ, Dobyns WB. **A developmental classification of malformations of the brainstem.** *Ann Neurol* 2007;62:625–39 [CrossRef Medline](#)

25. Fischer EG. **Dandy-Walker syndrome: an evaluation of surgical treatment.** *J Neurosurg* 1973;39:615–21 [CrossRef Medline](#)
26. Bindal AK, Storrs BB, McLone DG. **Management of the Dandy-Walker syndrome.** *Pediatr Neurosurg* 1990;16:163–69 [CrossRef Medline](#)
27. Haldipur P, Aldinger KA, Bernardo S, et al. **Spatiotemporal expansion of primary progenitor zones in the developing human cerebellum.** *Science* 2019;366:454–60 [CrossRef Medline](#)
28. Haldipur P, Bernardo S, Aldinger KA, et al. **Evidence of disrupted rhombic lip development in the pathogenesis of Dandy-Walker malformation.** *Acta Neuropathol* 2021;142:761–76 [CrossRef Medline](#)
29. Aldinger KA, Elsen GE, Prince VE, et al. **Model organisms inform the search for the genes and developmental pathology underlying malformations of the human hindbrain.** *Semin Pediatr Neurol* 2009;16:155–63 [CrossRef Medline](#)
30. Haldipur P, Dang D, Aldinger KA, et al. **Phenotypic outcomes in mouse and human *FOXC1* dependent Dandy-Walker cerebellar malformation suggest shared mechanisms.** *Elife* 2017;6:e20898 [CrossRef Medline](#)