



Discover Generics

Cost-Effective CT & MRI Contrast Agents



FRESENIUS
KABI

WATCH VIDEO

AJNR

Skull phylogeny: an investigation using radiography and high-resolution computed tomography.

C Virapongse, M Sarwar, S Bhimani and E S Crelin

AJNR Am J Neuroradiol 1984, 5 (2) 147-154

<http://www.ajnr.org/content/5/2/147>

This information is current as
of June 24, 2025.

Skull Phylogeny: An Investigation Using Radiography and High-Resolution Computed Tomography

Chat Virapongse¹
 Mohammad Sarwar¹
 Sultan Bhimani¹
 Edmund S. Crelin²

To demonstrate the phylogenetic changes that have led to the current form of the human skull, dried skulls of various representative vertebrates were examined using plain radiography and high-resolution computed tomography. The latter was chosen rather than pluridirectional tomography in anticipation of its future role as the major method for imaging the skull base. The phylogenetic history of the human skull is reviewed by considering separately the evolution of the calvarium, zygomatic arch, palate, jaw, and skull base.

The human skull, characterized by an immensely expanded calvarium, a basiclival flexion, and a vertically directed face, is considered unique, perhaps even grotesque, when compared with that of other vertebrates. However, despite its frequent radiographic display, this phylogenetic distinction has generated little interest among practicing radiologists. The radiographic literature abounds with lengthy anatomic descriptions of various skull landmarks and ontogenetic development, but nowhere is there acknowledgment of the key evolutionary steps that produced the human skull.

In an attempt to explain and illustrate this evolutionary process, plain skull films of various representative vertebrates were compared with high-resolution computed tomographic (CT) scans. Pluridirectional tomography was not used, since it has been superseded in large measure by CT. Further, the potential of CT for investigating aberrant human skull morphology can be extrapolated from its performance in evaluating the skull morphology of other vertebrates.

Materials and Methods

The representative vertebrates whose skulls were studied were the codfish, haddock, frog, iguana, python, alligator, ostrich, dog, and baboon (fig. 1). Each was photographed, radiographed, and scanned with a GE CT/T 8800 scanner. The scanning factors were 120 kV and 100–600 mA; the scanning time was 9.6 sec. Sections were 1.5 mm thick and in the axial plane. Each specimen was "targeted" prospectively using the GE ReView software package.

Observations and Commentary

Phylogenetically, the human skull is divided into three parts: dermatocranium, viscerocranium, and chondrocranium. The dermatocranium evolved into the calvarium, the viscerocranium into the palate and jaw apparatus, and the chondrocranium into the skull base (basicranium).

Calvarium

The human calvarium evolved from what was originally scales of fishes, hence

Received May 27, 1983; accepted after revision September 22, 1983.

¹ Department of Diagnostic Imaging, Section of Neuroradiology, Yale University School of Medicine, 333 Cedar St., New Haven, CT 06510. Address reprint requests to C. Virapongse.

² Department of Surgery, Yale University School of Medicine, New Haven, CT 06510.

AJNR 5:147–154, March/April 1984
 0195–6108/84:0502–0147 \$00.00
 © American Roentgen Ray Society

the term *dermatocranium*. Sharks, one of the lowest groups in the vertebrate echelon, have only a cartilage skull base covering the sense organs and brain. Higher on the evolutionary ladder, certain fishes have developed scales for protection; in the head region these scales have sunk to cover the brain. In early bony fishes, the skull roof is composed of numerous scalelike bones, several of which are unpaired. The codfish and haddock used in this study are representative of the bony fishes that possess such a skull roof. In the haddock, the forerunners of the frontal, parietal, and occipital bones can already be recognized (fig. 2).

As creatures emerged from the sea, legs evolved from fins, providing mobility on land. The transition to four-legged (tetrapod), air-breathing, land-dwelling creatures necessitated certain adaptations. The opercular bones covering the gill slits in

fishes were lost, and the gill-slit cartilages were transformed into cartilages for conduction of sound and protection of the windpipe [1] (fig. 3). Amphibian skulls are distinguished from fish skulls also by changes in the palate. The skull base remains mostly cartilage and is largely unchanged except for development of two condyles arising from the exoccipitals. The membranous bones of the skull roof and palate have undergone an overall reduction in number.

The skull of the present-day labyrinthodont amphibian demonstrates certain characteristics of the early land-dwellers. The numerous bones of the skull roof are reduced in number and are paired (fig. 4). The orbits and parietal foramen are situated posteriorly, lengthening the face. This foramen is thought to have housed the pineal gland (the "third eye"), not to be confused with the parietal foramina in man, which lie parasagittally. The fishlike face with its clustered sense organs is no longer evident. Along each superoposterior aspect of the skull is an otic notch between the squamosal and the temporal series of bones. This is the site of a middle ear, containing an ossicle (columella). During subsequent evolution the bones of the calvarium underwent further reduction in number, and it began to have a dome-shaped appearance in birds (fig. 5), reflecting expansion of the brain.

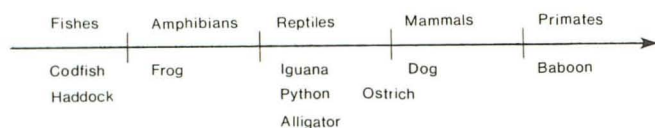


Fig. 1.—Classification of nine selected vertebrates and their respective locations on evolutionary scale.

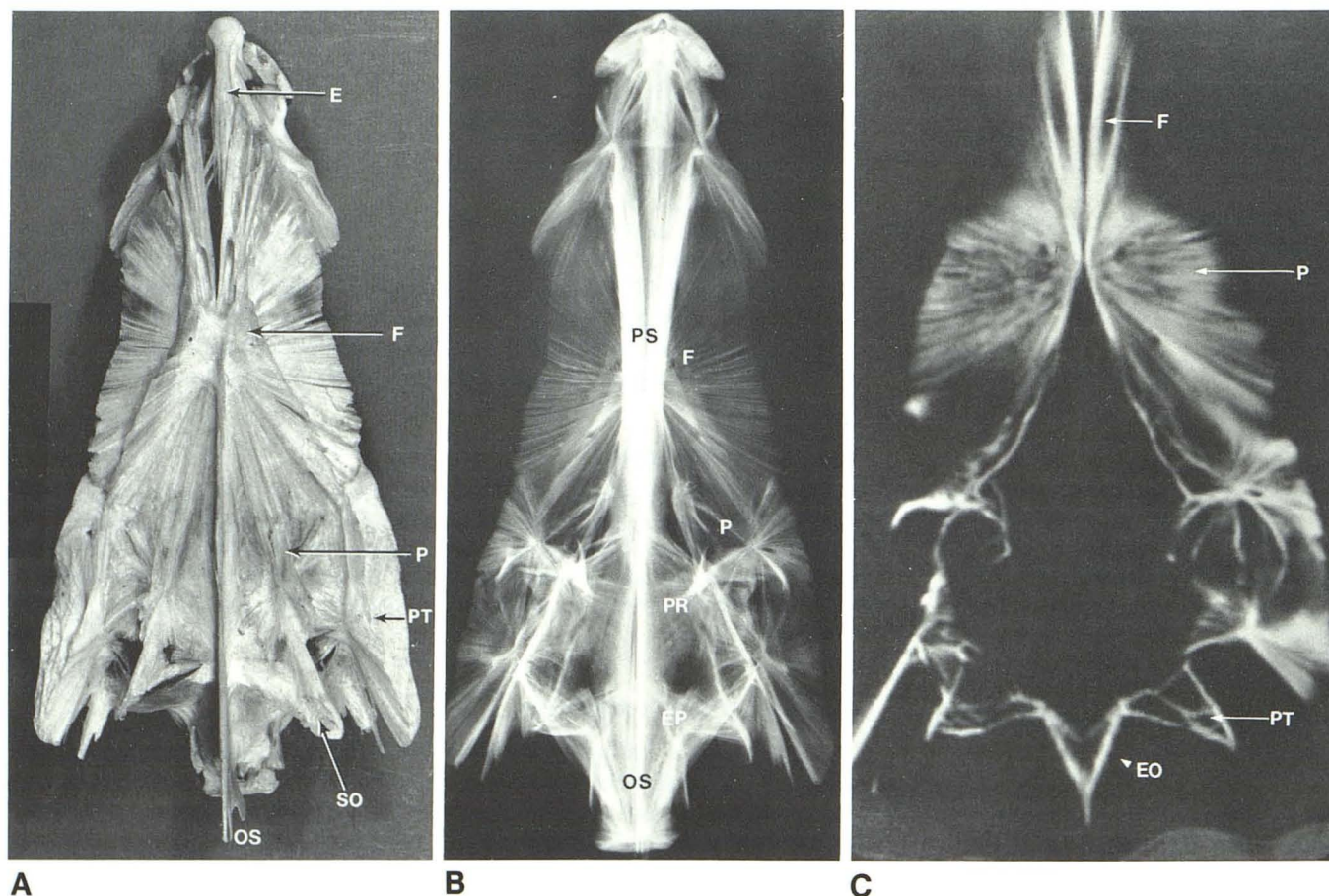


Fig. 2.—Dermatocranium of haddock: dorsal photograph (A); basal radiograph (B); axial CT scan (C). Note radiating trabeculation of flattened skull roof. E = median ethmoid; EO = exoccipital; EP = epiotic; F = frontal; OS = occipital spine; P = parietal; PR = prootic; PS = parasphenoid; PT = pterotic; SO = supraoccipital.

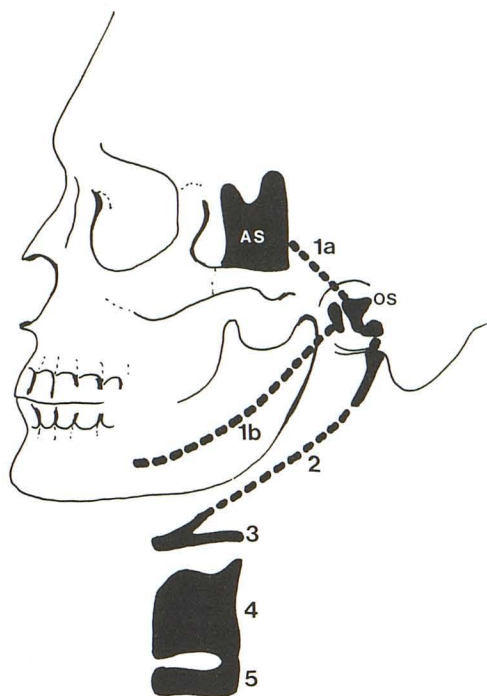


Fig. 3.—Incorporation of brachial arch cartilages into skull and windpipe. 1a and 1b = pterygoquadrate and Meckel cartilages, respectively; the former formed the alisphenoid and incus, the latter the mandible and malleus. Second brachial arch (2) gave rise to stapes and hyoid; arches 3, 4, and 5 provided other cartilages of upper respiratory tract. AS = alisphenoid; OS = middle ear ossicles.

Zygomatic Arch

The zygomatic arch and the subtemporal fossa developed in man as a sequel to the expansion of mastication muscles that appeared in reptiles. In the forerunners of reptiles, the stem reptiles, these muscles, which operate the lower jaw, were trapped within the bony calvarium so that their lateral expansion during contraction was impeded. Consequently, one (figs. 6 and 7) or two (fig. 8) fenestrations appeared along the lateral aspect of the calvarium, allowing this expansion [2, 3]. Reptiles can be classified according to the number of fenestrations (synapsid or diapsid) [4, 5]. In the alligator, a diapsid, two temporal fenestrations have developed on each side, a superior and an inferior (fig. 9); the python represents the synapsid variety (single fenestration).

Man seems to have descended from synapsid reptiles. With greater enlargement of the temporal fenestration, the inferior bar of bone gradually was displaced downward, becoming the zygomatic arch (fig. 7C). Meanwhile, the gap separating it and the brain was covered by downgrowth of bone from the sides [2]. Therefore, the bone underlying the temporal muscle in man represents the "new" calvarium whereas that above it, including the zygomatic arch, represents the "old" calvarium (fig. 7C) [2]. With continued brain development in mammallike reptiles and mammals, further additions to the skull bones, such as the temporal and occipital squamae, were incorporated along the sides of the calvarium.

Palatal Complex

The shark has seven pairs of branchial cartilages. The first of these evolved into the palatal complex. The first pair of

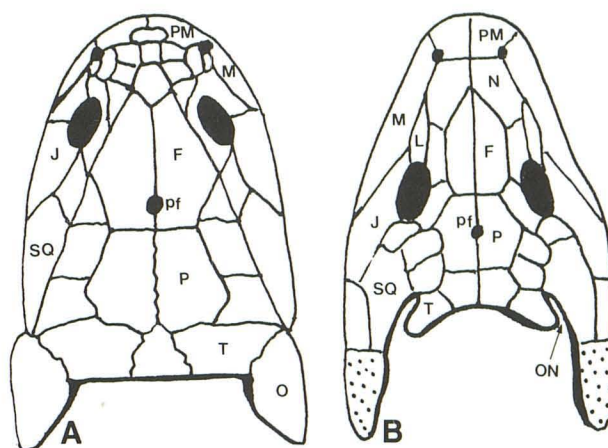


Fig. 4.—Changes in skull during conversion to land-dweller. Crossopterygian fish (A); labyrinthodont amphibian (B). Note posterior movement of orbits to enlarge facial skeleton; otic notch (ON) between temporal (T) and squamosal (SQ) series appears with shedding of opercular bones (O). F = frontal; J = jugal; L = lacrimal; M = maxilla; N = nasal; P = parietal; pf = parietal foramen; PM = premaxilla; stippled area = site of previous opercular bones.

branchial cartilages is specialized by being divided into the ventral pterygoquadrate and dorsal Meckel cartilages. The former evolved into the upper jaw, the latter into the lower jaw. Huxley [6] classified the palatal complex in fishes into hyostyly, autostyly, and amphistly, depending on the nature of the articulation. In the elasmobranch shark, the pterygoquadrate and Meckel cartilages are attached to the hyomandibular (second) cartilage, which in turn is attached to the braincase at the otic capsule. Fishes have only a primary upper palate, which is formed by the pterygoid centrally and flanked by smaller bones, the vomers, palatines, and epipterygoids. These bones converge anteriorly, while posteriorly the palatal shelf is open, exposing the parasphenoid, which forms the floor of the skull in the lower vertebrates. In reptiles this palate is mobile (kinetic) by virtue of its loose articulation with the skull base.

The secondary palate in man and mammals evolved from the need to breathe during feeding. It first appeared in the higher reptiles by a backward growth of the palatal processes of the premaxilla and maxilla (figs. 10 and 11). The internal nares moved posteriad in conjunction with the posterior growth of the maxilla [2]. The paired vomers, palatines, and pterygoids also moved backward, becoming diminutive bones (fig. 11C); in man they are vestigial bones surrounding the internal nares. In the alligator, a higher reptile, this bony secondary palatal shelf is complete (fig. 11). The evolution of the secondary palate is exemplified in human ontogeny by the medial converging growth of the palatine processes of the maxilla. The cleft palate deformity, representing failure of this process, produces an incomplete secondary palate similar to that seen in the lower reptiles.

Jaw

Meanwhile, during evolution the lower jaw (Meckel) cartilage became invested with dermal bones. As with the calvarium, the lower jaw of fishes initially had numerous scalelike bones, which gradually were reduced in number. In the bony fishes (teleosts), the lower jaw already has been reduced to

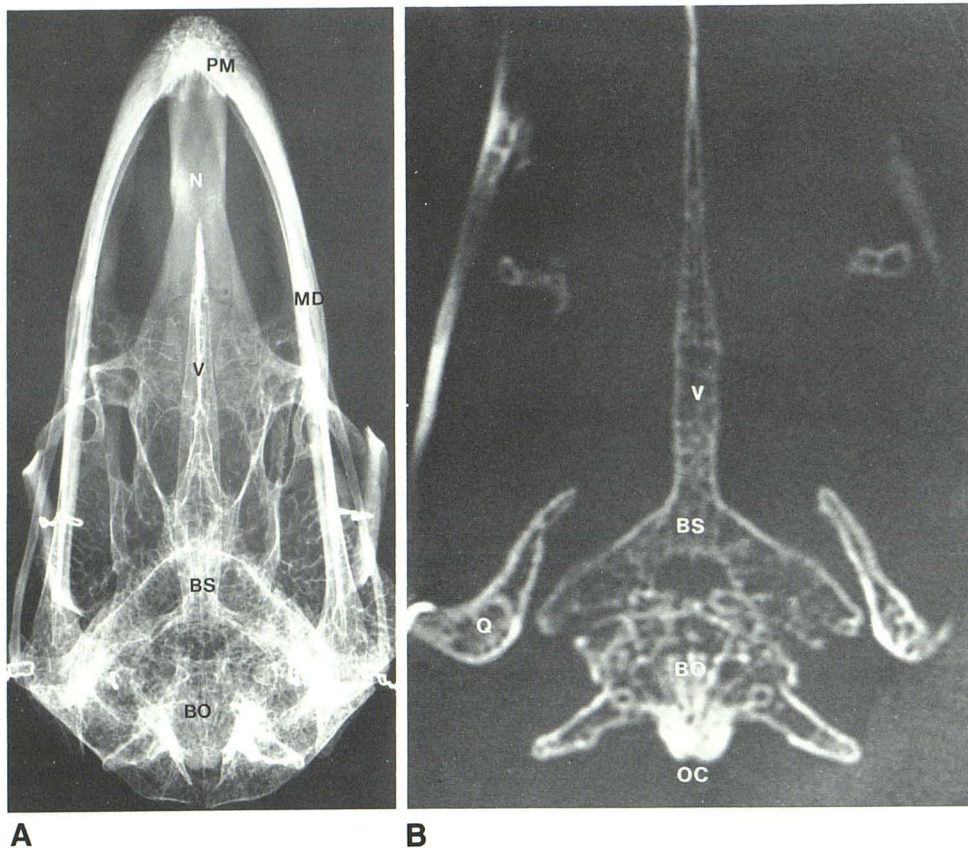


Fig. 5.—Ostrich skull: basal radiograph (A); axial CT scan (B). Numerous intradiploic air sacs. Note difference in resolution of thin trabeculae. BS = basisphenoid; BO = basioccipital; MD = mandible; N = nasal; OC = occipital condyle; PM = premaxilla; Q = quadrate; V = vomer.

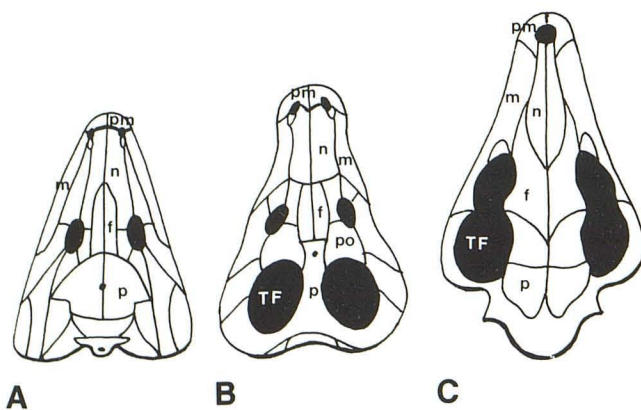


Fig. 6.—Changes in skull roof. Stem reptile (A); advanced reptile (B); mammal (C). Reduction in number of bones; appearance of temporal fenestration in advanced reptiles, with its subsequent enlargement in mammals. f = frontal; n = nasal; m = maxilla; p = parietal; pm = premaxilla; po = postorbital; TF = temporal fenestration.

a few dominant bones: dentary, angular, and articular. The latter two eventually were incorporated into the ear, and the dentary (mandible) remained as the only bone of the lower jaw. As stated, the conversion to air-breathing entailed the conversion of the gill arches to other specialized functions. The hyomandibular (second branchial) cartilage in the labyrinthodont amphibian was transformed into the columella, which

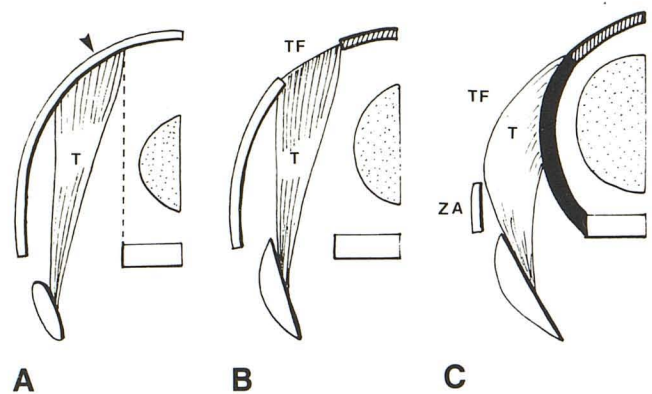


Fig. 7.—Development of temporal fenestration from anapsid (A) to mammalian state (C). (Diagrams correspond to those in fig. 6.) In stem reptile (A), temporal muscle (T) is impeded laterally by skull roof (arrowhead); in advanced reptile (B), an aperture (TF) allows further enlargement of this muscle. Its continued expansion in mammals (C) causes displacement of "old" calvarium (hatched area) downward to form a bar, the zygomatic arch (ZA), while "new" calvarium (shaded black area) is formed medially to cover enlarging brain (stippled area) and provide muscular attachment.

evolved into the stapes, resting medially against the oval window and laterally on a tympanic membrane. With the development of the secondary palate, the quadrate bone was reduced and relocated in the middle ear as the incus (fig. 11). The articular bone also was separated from the mandible

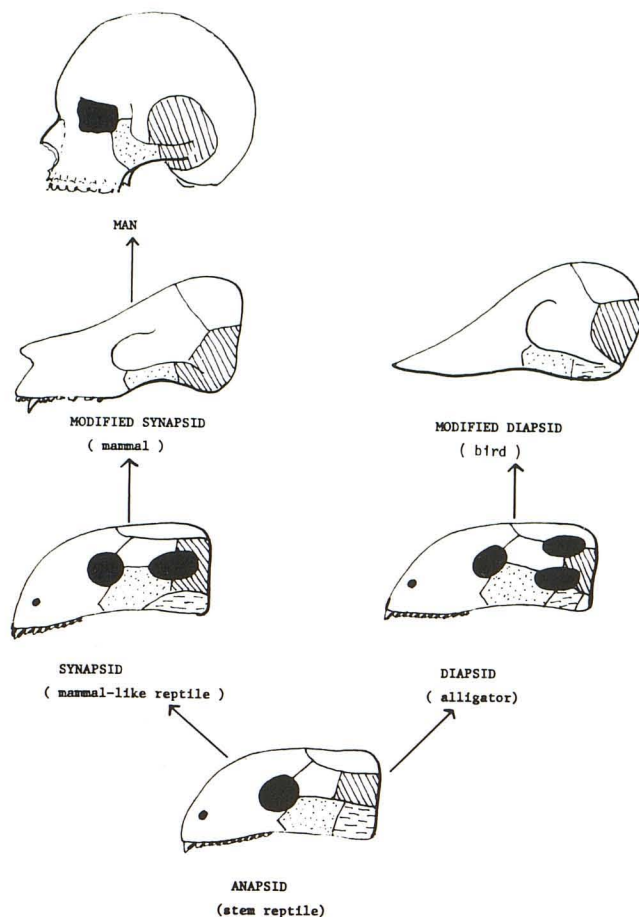


Fig. 8.—Divergent evolutionary changes in temporal fenestration from anapsid state. Stippled area = jugal; broken lines = quadratojugal; oblique hatching = squamosal.

proper and joined the quadrate bone as the malleus. The angular bone evolved into the tympanic bone. The removal of these bones from the lower jaw permitted free articulation between the dentary and the squamosal, present in virtually all mammals. The external auditory canal developed during the transition from reptiles to mammals. The late evolutionary acquisition of the external auditory canal and ossicles may explain, in part, the frequently concomitant anomalies of both structures in congenital external ear hypoplasia while the inner ear (being phylogenetically older) is spared.

Skull Base

In contrast to the evolution of the calvarium and palate, the evolution of the skull base (chondrocranium) remains largely controversial. During prevertebrate evolution, the chordates, such as the present-day amphioxus, had a rudimentary central nervous system consisting of a spinal cord with simple reflex arcs but without higher motor control. With the development of the brain and specialized sense organs at the cephalic extremity, the surrounding fields of mesenchyme were differentiated into a cartilaginous chondrocranium to

protect the sense organs. These cartilaginous fields can be subdivided into those lateral (parachordal) and those anterior (prechordal) to the notochord, which fused to form the basal plate. During further evolution, ossification occurred in the basal plate, forming the skull base, which was originally roofless [7]. Therefore, as a result of its phylogenetic heritage, the bones of the human skull base (ethmoid, sphenoid, temporal, and occipital) are preformed in cartilage, making them susceptible to cartilaginous disorders.

In the chondrocranium of fishes and other vertebrates, the basal plate surrounds the notochord posteriorly and the hypophysis anteriorly. Its lateral walls are formed by the otic capsules posteriorly and by the orbital cartilages and nasal capsule anteriorly. Perforations in the orbital cartilage give rise to a series of struts [8, 9] (fig. 12), although in some vertebrates the orbital cartilage may not be perforated. Thus, in relation to structures of the sidewall of the chondrocranium, the position of the emerging cranial nerves is established already in the lower vertebrates and remained virtually constant throughout vertebrate evolution. These nerves are segmented; their ganglia lie outside their respective foramina, resembling spinal nerves [10]. The twelfth cranial nerve passes through foramina provided by the occipital bone, formed by fusion of the occipital arches. The ninth and tenth nerves pass through foramina behind the otic capsule. The jugular fossa in man represents the phylogenetic separation between the otic capsule and the occipital arches [2]. The eighth nerve pierces the otic capsule medially, supplying fibers to the membranous labyrinth. The seventh nerve runs anteriorly to the otic capsule, but is separated from the trigeminal ganglion by a small cartilaginous strut (the prefacial commissure). The foramen for the fifth nerve is separated from the other foramina by another cartilaginous strut (the pila antotica), which may be pierced at its base by the sixth nerve.

The extracranial space, the cavum epiptericum lateral to the skull and bordered laterally by the ascending process of the epipterygoid (fig. 12) [8, 9], eventually moved intracranially to allow more space for the enlarging brain. This evolutionary process began in the advanced reptiles and was completed by the advent of mammals. At the same time, the ascending process of the epipterygoid was incorporated into the skull and expanded by the enlarging temporal lobes to form the greater wing of the sphenoid. Consequently, the semilunar ganglion, previously residing in the cavum epiptericum, moved intracranially, its second and third divisions in man piercing the newly acquired greater wing of the sphenoid (alisphenoid). Its first division, however, passes through a common foramen (the superior orbital fissure) with the third, fourth, and sixth nerves. This may be related to the complex evolution of the alisphenoid, a controversial subject. Also, in man, the facial nerve pierces the auditory capsule together with the eighth nerve, probably as a result of the phylogenetic development of the cochlea extending below the facial canal (seen already in amphibians) [8].

While evolutionary changes took place in the jaw and calvarium as a result of brain enlargement and feeding habits, the skull base remained relatively unmodified in mammals, except for the previously mentioned process resulting in the acquisition of the middle cranial fossa. The bones constituting

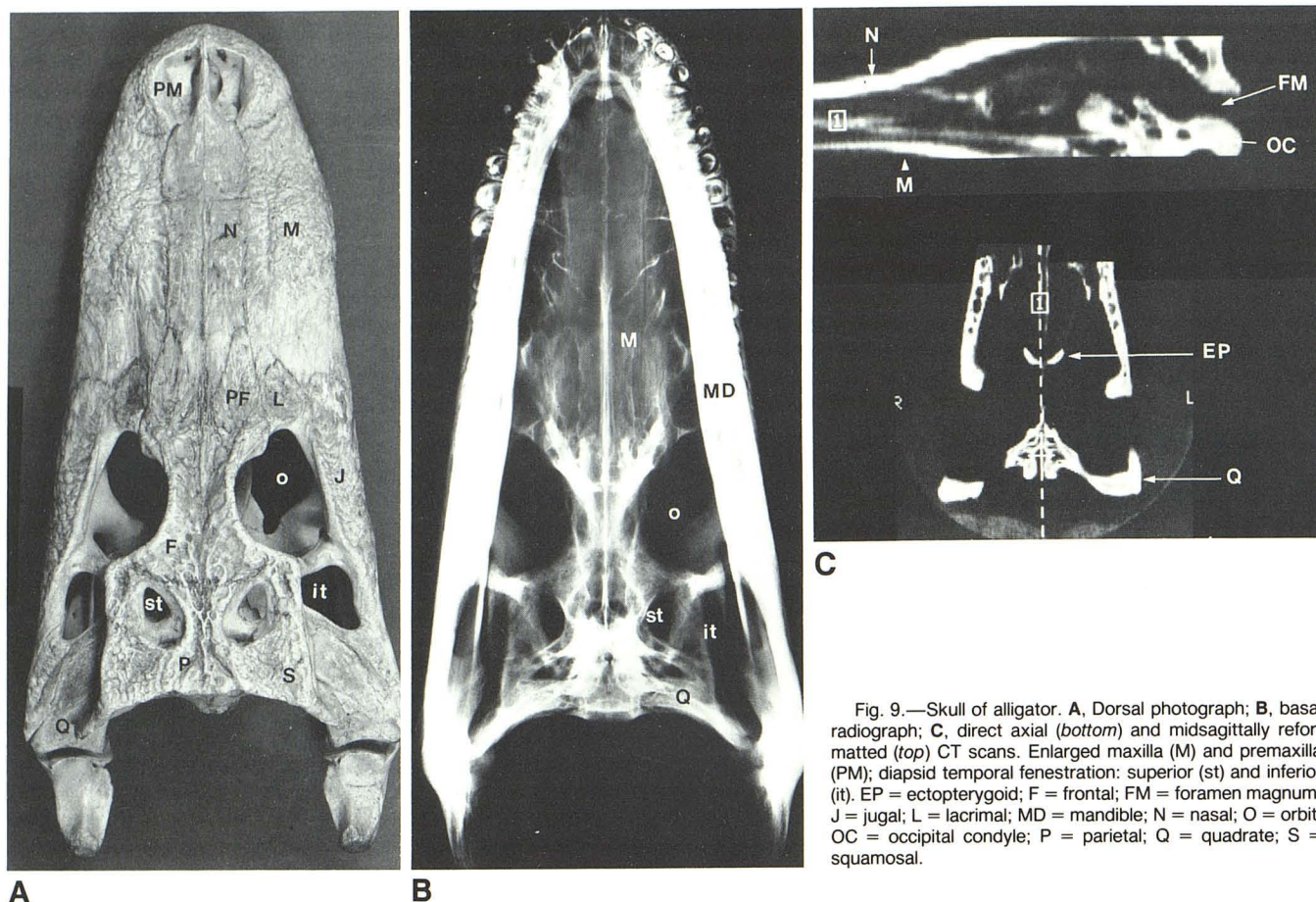


Fig. 9.—Skull of alligator. A, Dorsal photograph; B, basal radiograph; C, direct axial (bottom) and midsagittally reformatted (top) CT scans. Enlarged maxilla (M) and premaxilla (PM); diapsid temporal fenestration: superior (st) and inferior (it). EP = ectopterygoid; F = frontal; FM = foramen magnum; J = jugal; L = lacrima; MD = mandible; N = nasal; O = orbit; OC = occipital condyle; P = parietal; Q = quadrate; S = squamosal.

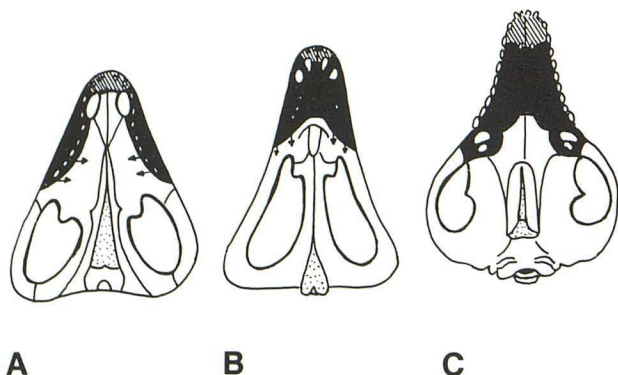


Fig. 10.—Evolution of secondary palate. Stem reptile (A); mammallike reptile (B); mammal (C). Palatal processes of maxilla (shaded black area) are rudimentary in stem reptile, allowing communication between oral and nasal cavities and exposing sphenoid and basioccipital (stippled area). Each palatal process is attached to premaxilla anteriorly (hatched area), producing appearance similar to cleft palate deformity in humans. Palatal processes approach each other and fuse to form palatal shelf; they also extend backward in correspondence with enlargement of jaw. Arrows = direction of evolutionary growth.

the skull base in mammals perform the same protective function as in the lower vertebrates, surrounding the foramen magnum, membranous labyrinth, pituitary gland, and olfactory fibrils. During the evolution of primates the process of basical flexion began, bringing the foramen magnum from the rear of the skull to a position below the skull (fig. 13). This migration

was coordinated with changes in the facial skeleton, which simultaneously underwent reduction and was brought into vertical alignment with the spine. Similarly, mandibular angulation changed from an oblique to a more perpendicular orientation, in keeping with the development of the upright stance. These evolutionary processes are replicated to a large extent in human ontogeny.

Conclusions

Each part of the human skull has evolved along its own path while maintaining functional harmony with its companion parts. Throughout the course of skull evolution, nature has exercised economy by quantitative reduction, refining the preexisting units without resorting to de novo creation.

High-resolution CT is useful for depicting fine bony anatomic structures (e.g., in the region of the temporal bone) (figs. 14 and 15). This explains the current popularity of high-resolution CT as the method of choice for examining bony fractures in facial trauma [11–13] and those resulting in rhinorrhea [14–16], as well as in the temporal bone [17–19]. However, it is a poor method for determining gross overall bone morphology, where plain radiography is more valuable. Only when contiguous CT slices of a particular bone are examined can overall bone contour be appreciated. Although this problem can be circumvented by reformatted imaging in various planes (fig. 7), the quality of the images is inadequate for precise assessment of bone morphology. Thus, it appears

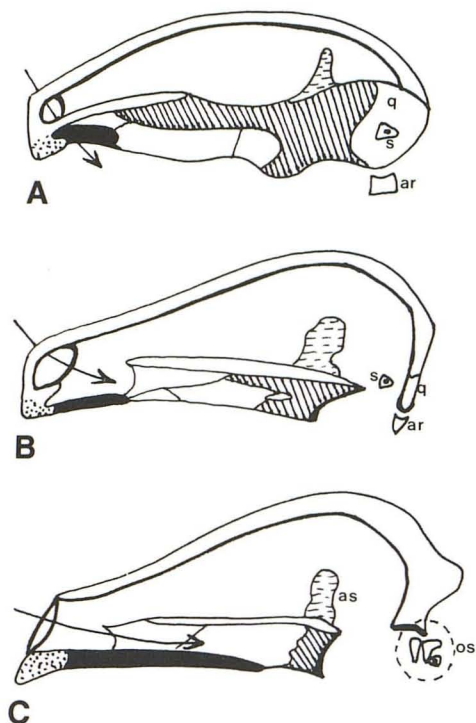


Fig. 11.—Midsagittal sections of skull: stem reptile (A); mammallike reptile (B); mammal (C). Anteroposterior enlargement of palatal processes (shaded black area). Stippled area = premaxilla. Pterygoid is gradually reduced in size to lie posterior to internal nares. Arrow = direction of air movement. Ascending process of pterygoid (broken lines), providing loose articulation with braincase in stem reptile, becomes incorporated into mammalian skull as alisphenoid (as). The quadrate (q) and articular (ar) are likewise reduced and recruited into middle ear as ossicles (os). s = stapes.

that the usefulness of high-resolution CT may be confined to regions of the skull in which greater contrast resolution is needed. For this reason, it may be used paleontologically as a means of differentiating rock adherents from fossil skull.

REFERENCES

1. Crelin ES. Development of the upper respiratory system. *Clin Symp* 1976;28(3):2
2. Romer AS. *The vertebrate body*, 4th ed. Philadelphia: Saunders, 1970
3. Kent GC. *Comparative anatomy of the vertebrates*, 3rd ed. St. Louis: Mosby, 1973
4. Hildebrand M. *Analysis of vertebrate structure*. New York: Wiley, 1974
5. Barghusen HR, Hopson JA. The endoskeleton: the comparative

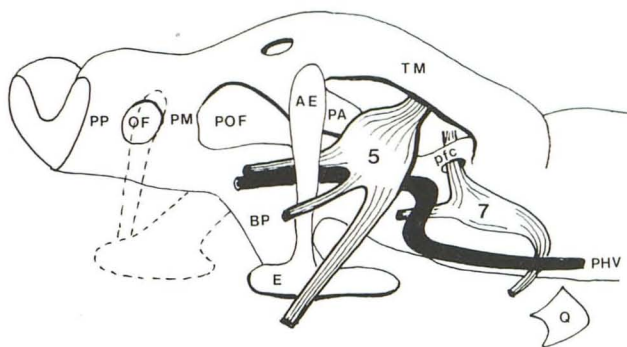


Fig. 12.—Lower vertebrate chondrocranium, lateral view. Cavum epiptericum, a space lateral to chondrocranium, contains semilunar ganglion and is bounded laterally by ascending process of epipterygoid and medially by cartilaginous struts of chondrocranium. AE = ascending process of epipterygoid; BP = basitrabecular process; E = epipterygoid; Q = quadrate; OF = optic foramen; PA = pila antotica; pfc = prefacial commissure; PHV = primary head vein; PM = pila metoptica; POF = postoptic fenestra; PP = pila preoptica; TM = taenia marginalis. (Modified from [9].)

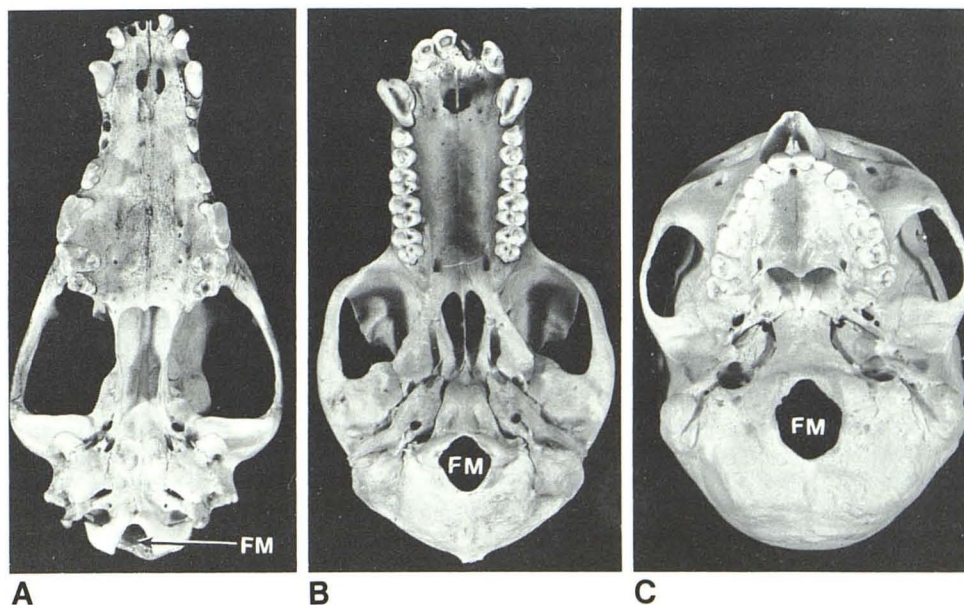


Fig. 13.—Skull base in dog (A), baboon (B), and man (C), demonstrating ventral movement of foramen magnum (FM). Concomitant reduction of anteroposterior dimension of hard palate due to development of upright posture brought face into vertical alignment with spine.

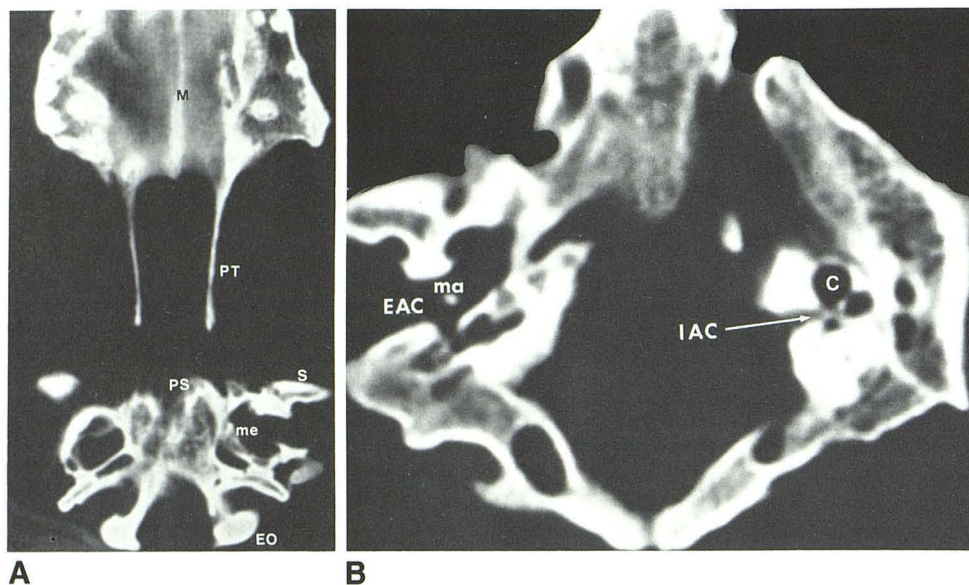


Fig. 14.—Skull base of dog. **A**, Axial CT scan; **B**, magnified view of temporal bones. CT appearance of inner ear is similar in dog and man, whereas middle and external ears of dog are more capacious. C = cochlea; EAC = external auditory canal; EO = exoccipital; IAC = internal auditory canal; M = palatal process of maxilla; ma = malleus; me = middle ear; PS = presphenoid; PT = pterygoid; S = squamosal.

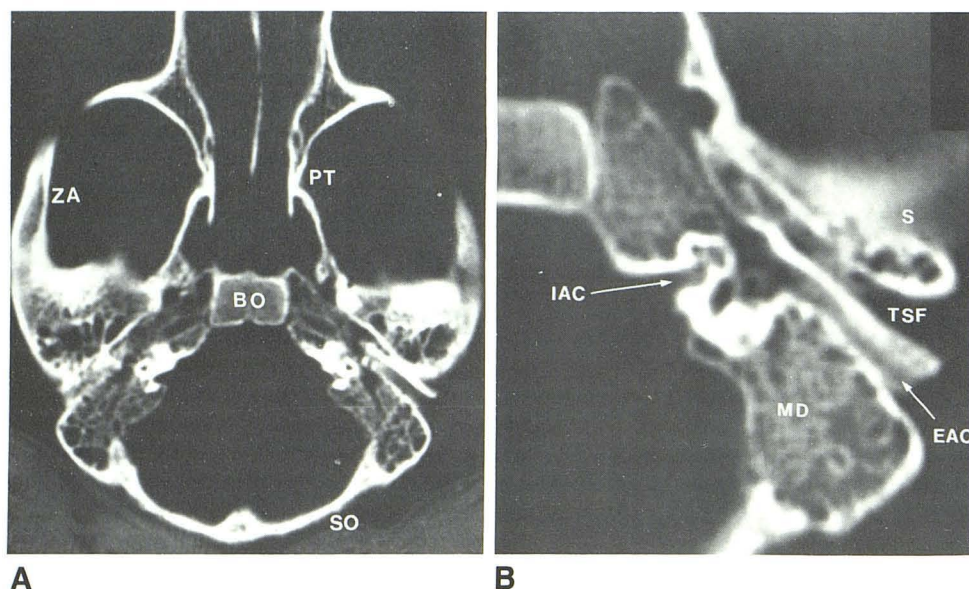


Fig. 15.—Skull base of baboon. **A**, Axial CT scan; **B**, magnified view of left temporal bone, showing similarity in CT appearance of primate ear and human ear. Only external auditory canal (EAC) differs in its oblique anteroposterior orientation. It is separated from temporal squama by widened tympanosquamosal fissure (TSF). Aeration in petromastoid is comparable to that in man. BO = basioccipital; IAC = internal auditory canal; MD = mastoid; PT = pterygoid; S = temporal squama; SO = supraoccipital; ZA = zygomatic arch.

- anatomy of the skull and visceral skeleton. In: Wake MH, ed. *Hyman's comparative vertebrate anatomy*, 3d ed. Chicago: University of Chicago Press, 1979:265-326
- Huxley TH. Contributions to morphology. Ichthyopsida No. 1. *Proc Zool Soc London*, 1876:24-59
 - Crelin ES. Development of the musculoskeletal system. *Clin Symp* 1981;33(1):5
 - deBeer GR. *Vertebrate zoology*. London: Sidgerich & Jackson, 1966
 - Presley R, Steel L. On the homology of the alisphenoid. *J Anat* 1976;121:441-459
 - Goodrich ES. *Studies on the structure and development of vertebrates*. London: Macmillan, 1930
 - Fujii N, Yamashiro M. Computed tomography for the diagnosis of facial fractures. *J Oral Surg* 1981;39:735-741
 - Gentry LR, Manor WF, Turski PA, Strother CM. High-resolution CT analysis of facial struts in trauma: 2. Osseous and soft-tissue complications. *AJR* 1983;140:533-541
 - Neumann PR, Zilkha A. Use of the CAT scan for diagnosis in the complicated facial fracture patient. *Plast Reconstr Surg* 1982;70:683-693
 - Manelfe C, Cellerier P, Sobel D, Prevost C, Bonafé A. Cerebrospinal fluid rhinorrhea: evaluation with metrizamide cisternography. *AJNR* 1982;3:25-30, *AJR* 1982;138:471-476
 - Ghoshhajra K. Metrizamide CT cisternography in the diagnosis and visualization of cerebrospinal fluid rhinorrhea. *J Comput Assist Tomogr* 1980;4:306-310
 - Drayer BP, Wilkins RH, Boehnke M, Horton JA, Rosenbaum AE. Cerebrospinal fluid rhinorrhea demonstrated by metrizamide CT cisternography. *AJR* 1977;129:149-151
 - Virapongse C, Rothman SLG, Kier EL, Sarwar M. Computed tomographic anatomy of the temporal bone. *AJNR* 1982;3:379-389, *AJR* 1982;139:739-749
 - Virapongse C, Rothman SLG, Sasaki C, Kier EL, Sarwar M. The role of high-resolution computed tomography in evaluating disease of the middle ear. *J Comput Assist Tomogr* 1982;6:711-720
 - Schaffer KA, Haughton VM, Wilson CR. High-resolution computed tomography of the temporal bone. *Radiology* 1980;134:409-414