



## Discover Generics

Cost-Effective CT & MRI Contrast Agents



WATCH VIDEO

# AJNR

### **Aneurysms of the posterior cerebral artery in children.**

P A Kaplan and F J Hahn

*AJNR Am J Neuroradiol* 1984, 5 (6) 771-774

<http://www.ajnr.org/content/5/6/771>

This information is current as  
of June 19, 2025.

# Aneurysms of the Posterior Cerebral Artery in Children

Phoebe A. Kaplan<sup>1</sup>  
Francis J. Hahn<sup>1</sup>

Intracranial aneurysms in children are very rare and differ from those in adults in several ways. Posterior cerebral artery (PCA) aneurysms are among the least common of intracranial aneurysms and little is known of their presentation and prognosis. Two cases of PCA aneurysms in children are reported, and 21 other cases of PCA aneurysms in patients 20 years of age or younger are reviewed. PCA aneurysms in children have a marked male predominance and are usually large, symptomatic, and tend to occur proximal or distal to the circle of Willis. Diagnostic computed tomography may be warranted earlier in children than in adults with similar symptoms referable to intracranial abnormalities because children are more likely to have an organic cause for such symptoms.

Cerebral aneurysms in children are rare [1-7], and the posterior cerebral artery (PCA) is infrequently involved by aneurysms regardless of age [8, 9]. We report two cases of PCA aneurysms in children under 5 years of age. Primary intracranial aneurysms in children differ from adult berry aneurysms in size, distribution, histology, and incidence of symptoms [3-7, 10].

## Case Reports

### Case 1

A boy just under 5 years of age had complained of headaches from the time he was able to communicate, at least 2 years before presentation to his physician. The headaches, which were in the left parietooccipital region, were associated with antecedent jarring of the head and usually lasted less than 1 hr.

Neurologic examination was unremarkable. Computed tomography (CT) of the head demonstrated a rounded, contrast-enhancing lesion in the left ambient cistern along the course of the PCA (figs. 1A and 1B). Vertebral angiography confirmed a 2 × 1 cm fusiform aneurysm of the PCA (figs. 1C and 1D). The patient underwent surgery to clip the PCA proximal to the aneurysm. He is now without headaches or other symptoms.

### Case 2

A 4-year-old girl had complained of headaches since the age of 2 years. The headaches, which were in the midfrontal region, were triggered by stress and excitement and alleviated by resting. Medical attention was sought because of an increase in frequency and duration of the headaches.

Physical examination was unremarkable. CT of the head showed a contrast-enhancing lesion in the left ambient cistern (figs. 2A and 2B). Selective vertebral arteriography demonstrated a 2 × 1 cm aneurysm of the ambient segment of the left PCA (figs. 2C and 2D), which proved to be fusiform at surgery. Again, the PCA was clipped proximal to the aneurysm. This patient also has remained asymptomatic since surgery.

Received November 9, 1983; accepted after revision April 18, 1984.

<sup>1</sup>Department of Radiology, University of Nebraska Medical Center, 42d and Dewey Ave., Omaha, NE 68105. Address reprint requests to F. J. Hahn.

**AJNR 5:771-774, November/December 1984**  
0195-6108/84/0506-0771  
© American Roentgen Ray Society



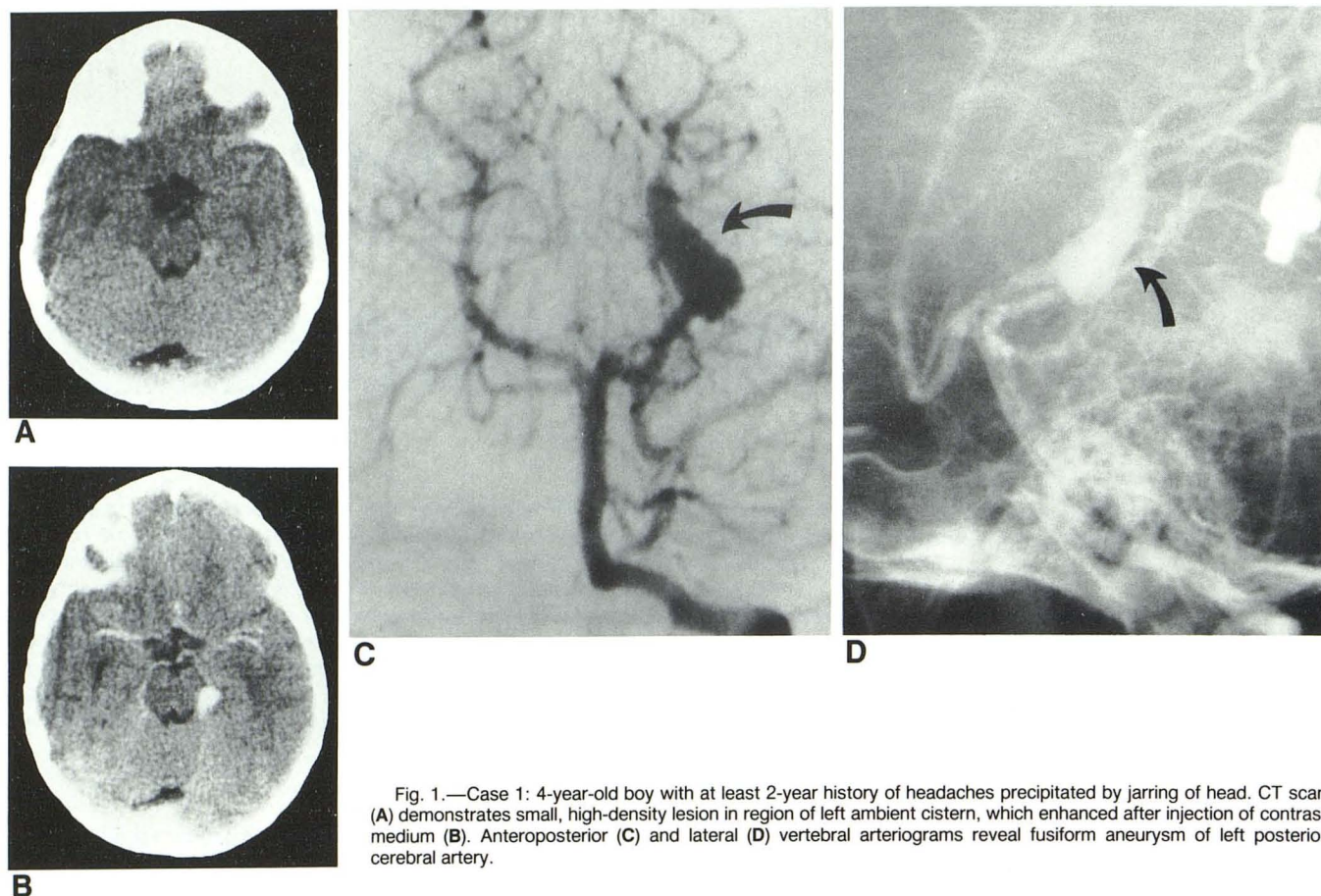


Fig. 1.—Case 1: 4-year-old boy with at least 2-year history of headaches precipitated by jarring of head. CT scan (A) demonstrates small, high-density lesion in region of left ambient cistern, which enhanced after injection of contrast medium (B). Anteroposterior (C) and lateral (D) vertebral arteriograms reveal fusiform aneurysm of left posterior cerebral artery.

#### Comment

Neither of the patients' histories suggested that their aneurysms were mycotic or traumatic in origin. There was no laboratory or clinical evidence of atherosclerosis, hypertension, or bacterial endocarditis. No coarctation of the aorta nor polycystic kidneys were found in these patients. The aneurysms were presumed to be primary (congenital) in both cases.

#### Discussion

Intracranial aneurysms of any etiology are rare during childhood. One-third are traumatic or mycotic in origin; the rest are congenital. Laitinen [11] reported that aneurysms in children account for only 1.3% of intracranial aneurysms overall. However, the incidence may prove to be somewhat higher with increased use of angiography in children as well as the relative ease of diagnosis with the availability of CT.

There are basic differences between saccular (berry) aneurysms in adults and congenital aneurysms in children, regardless of the intracranial vessel involved. Aneurysms in children are much more likely to cause symptoms than aneurysms in adults. An asymptomatic, incidental cerebral aneurysm in a child has been reported only once [8]. Thompson et al. [7] reported no incidental aneurysms among 1500 cerebral angiograms in children. Houspian and Pool [12] reported no aneurysms in a series of 3000 autopsies of children. Similarly, Riggs and Rupp [13] found no incidental aneurysms in 102

pediatric autopsies. In contrast, asymptomatic berry aneurysms in adults at necropsy have an incidence as high as 9% [13].

Aneurysms in children most often occur either proximal or distal to the circle of Willis, show a marked male predominance, and are large ( $\geq 1$  cm diam). Intracranial aneurysms in adults have a predilection to involve the circle of Willis; their incidence is equal in the two genders; and they usually are less than 1 cm in diameter. Because aneurysms in children are large, many produce symptoms by compression of surrounding structures [14]. However, most patients present to their physicians because the aneurysm has ruptured [15, 16].

Aneurysms in the two age groups differ histologically. In adults the internal elastic lamina and muscular media end abruptly at the entrance to the aneurysm; in children the internal elastic membrane tapers gradually as it enters the aneurysm. Aneurysms in children tend to be fusiform rather than saccular and involve the entire vessel wall. Atherosclerosis usually is associated with adult berry aneurysms, but is not a feature of aneurysms in children.

Aneurysms of the PCA are particularly unusual regardless of age. Pia and Fontana [8] reviewed 8968 reported cerebral aneurysms; the incidence of PCA aneurysms was 0.7%–2.2% (mean, 1%) with all ages included. Only 21 cases of PCA aneurysms in patients 20 years of age and younger have been reported [3, 7, 8, 17–25].



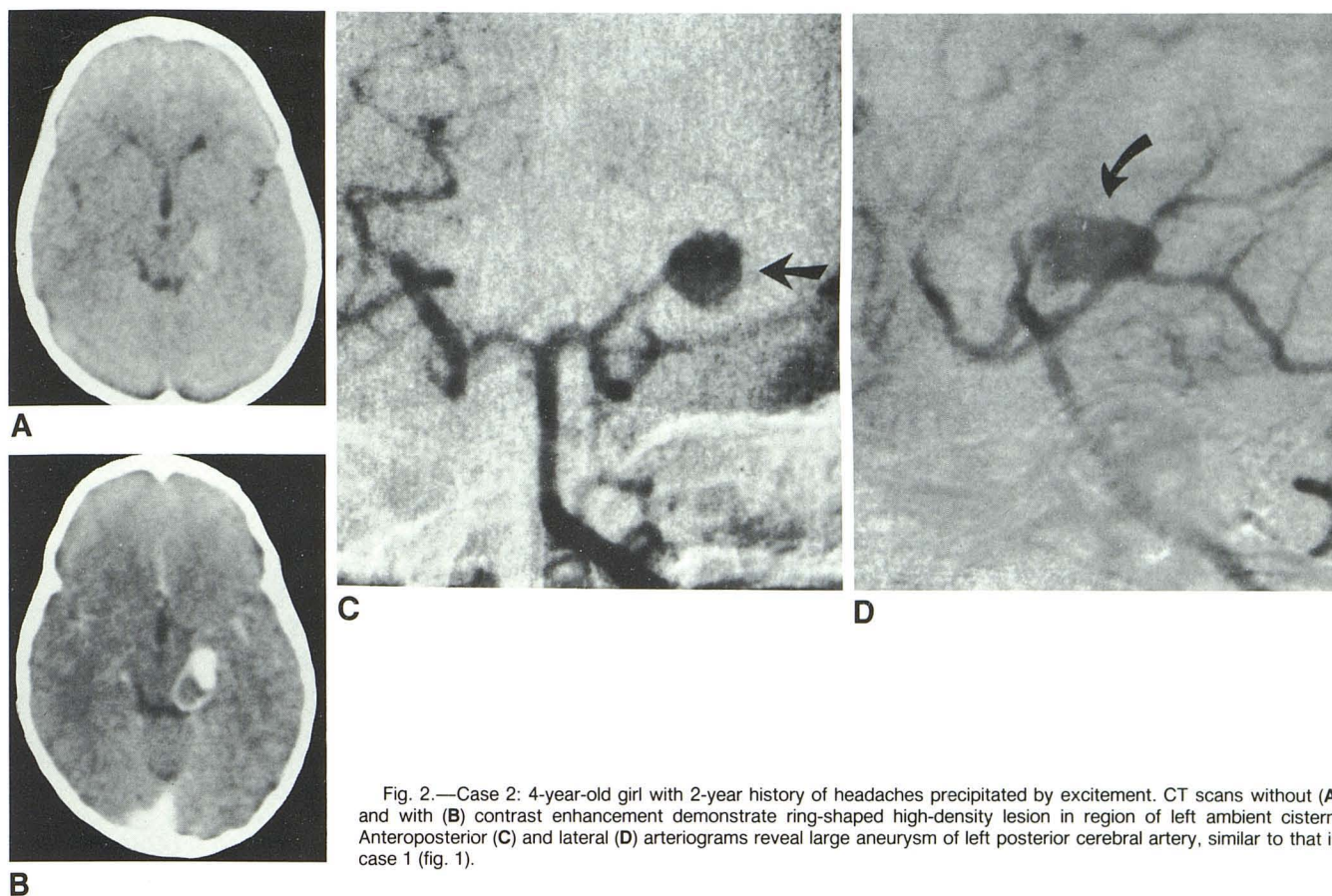


Fig. 2.—Case 2: 4-year-old girl with 2-year history of headaches precipitated by excitement. CT scans without (A) and with (B) contrast enhancement demonstrate ring-shaped high-density lesion in region of left ambient cistern. Anteroposterior (C) and lateral (D) arteriograms reveal large aneurysm of left posterior cerebral artery, similar to that in case 1 (fig. 1).

Our two cases are typical of childhood PCA aneurysms in size, location, and presence of symptoms. Table 1 lists all the previously reported cases of PCA aneurysms in patients 20 years of age or younger, as well as our two cases. Of 23 cases, 11 occurred in females and 10 in males; the gender of two patients was not reported. This gender distribution differs from that reported when all cerebral aneurysms in children, regardless of location, are considered. Both Orozco et al. [5] and Thompson et al. [7] reported the incidence in males to be about three times that in females. The apparently equal gender distribution of PCA aneurysms may be insignificant because of the relatively small population involved, or, on the other hand, there may indeed be an equal incidence of PCA aneurysms in males and females. Another interesting feature of unknown significance is that 10 of 13 PCA aneurysms in children occurred on the left side whereas only three were on the right. Ten of the 23 reported cases did not specify the side of involvement. In addition to the large size of the aneurysms in our two cases, both were fusiform in configuration. Aneurysms in children are often fusiform, regardless of location, but many giant aneurysms of the PCA are fusiform regardless of the age of the patient [26].

Aneurysms of the PCA are so rare that information about their clinical presentation and prognosis is limited. Cranial nerve abnormalities, especially of the oculomotor nerve, are among the presenting symptoms; however, the most common symptom is headache [8, 9, 27]. Headaches are usually attributable to a benign condition, but the younger the child

the more likely the headache will be organic in origin [28]. Early diagnosis of PCA aneurysms is of great importance because the artery supplies such vital structures as the midbrain, thalamus, and visual cortex. Since CT is a relatively simple and noninvasive method of diagnosis, perhaps it should be used more often and sooner in children than in adults, since minor symptoms such as headaches are more likely to be a manifestation of significant intracranial pathology in children.

#### REFERENCES

1. Stehbens WE. Intracranial berry aneurysms in infancy. *Surg Neurol* 1982;18:58-60
2. Shucart WA, Wolpert SA. An aneurysm in infancy presenting with diabetes insipidus. *J Neurosurg* 1972;37:368-370
3. Batnitzky S, Muller J. Infantile and juvenile cerebral aneurysms. *Neuroradiology* 1978;16:61-64
4. Kitano I, Sukui M, Kinoshita K. Infantile cerebral aneurysm. *Surg Neurol* 1981;16:386-390
5. Orozco M, Srignero SF, Quintana F, Diersen G. Intracranial aneurysms in early childhood. *Surg Neurol* 1978;9:247-252
6. Becker JR, Silverberg GD, Nelson DH, Hanfery JW. Saccular aneurysm of infancy and early childhood. *Neurosurgery* 1978;2:1-7
7. Thompson JR, Harwood-Nash DC, Fitz CR. Cerebral aneurysms in children. *AJR* 1973;118:163-175
8. Pia HW, Fontana H. Aneurysms of the posterior cerebral artery. *Acta Neurochir (Wien)* 1977;38:13-35



TABLE 1: Reported Cases of PCA Aneurysm in Patients 20 Years of Age or Younger

Author(s), Year	Age*	Gender	Location	Symptoms	Subarachnoid Hemorrhage?
Delpech [17], 1842 . . . . .	20	F	Left	Headache, 3d nerve abnormalities, hemiplegia	Yes
Rauchfuss [22], 1878 . . . . .	12	M	Left	3d and 7th nerve abnormalities	Yes
Lemmen [20], 1953 . . . . .	8 mo	M	Left	Large head	No
Jamieson [19], 1964 . . . . .	17	M	Left	Transient unconsciousness	Yes
Obrador et al. [21], 1967 . . .	20	F	Right	Blindness	No
Jain et al. [18], 1968 . . . . .	12	F	Right	Headache, coma	Yes
Uhlman and Kunzel [23], 1969 . . . . .	3	F	Left	Headache, coma	Yes
Thompson et al. [7], 1973 . . .	9 mo	F	...	Cerebellar and multiple cranial nerve signs	No
Pia and Fontana [8], 1976 . . .	18	F	Left	Headache, coma	Yes
<i>Ibid.</i> . . . . .	1	F	Left	Incidental finding; subdural hematoma	No
Batnitsky and Muller [3], 1978† . . . . .	...	...	...	...	...
Drake [26], 1979; Amacher et al. [25], 1981 . . . . .	17	M	...	...	No
Amacker et al. [25], 1981 . . .	14	F	...	...	Yes
<i>Ibid.</i> . . . . .	15	M	...	Headaches	No
<i>Ibid.</i> . . . . .	17	M	...	...	Yes
<i>Ibid.</i> . . . . .	11	M	...	...	Yes
<i>Ibid.</i> . . . . .	12	M	Right	Seizures	No
<i>Ibid.</i> . . . . .	14	F	...	...	Yes
<i>Ibid.</i> . . . . .	14	F	...	...	Yes
Ley-Valle et al. [24], 1983 . . .	9 mo	M	Left	Seizures	No
Kaplan and Hahn (case 1), 1984 . . . . .	4	M	Left	Headaches	No
Kaplan and Hahn (case 2), 1984 . . . . .	4	F	Left	Headaches	No

Note.—PCA = posterior cerebral artery.

\* In years, except as noted (mo = months).

† Two pediatric cases; age(s), gender(s), and other particulars not specified.

9. Drake CG, Amacher AL. Aneurysms of the posterior cerebral artery. *J Neurosurg* **1969**;30:468–474
10. Storrs BB, Humphreys RP, Hendrick EB, Hoffman HJ. Intracranial aneurysms in the pediatric age group. *Childs Brain* **1982**;9:358–361
11. Laitinen L. Arteriella aneurysm and subarachnoidalblodning hos barn. *Nord Med* **1964**;71:329–333
12. Houspian EM, Pool JL. Systematic analysis of intracranial aneurysms from the autopsy file of the Presbyterian Hospital 1914–1956. *J Neuropathol Exp Neurol* **1958**;17:409–429
13. Riggs HE, Rupp C. Miliary aneurysms: relation of anomalies of the Circle of Willis to aneurysm formation. *Arch Neurol Psychiatry* **1943**;49:615–616
14. Amacher AL, Drake CG. The results of operating upon cerebral aneurysms and angiomas in children and adolescents. *Childs Brain* **1979**;5:151–165
15. Ostergaard JR, Voldby B. Intracranial aneurysms in children and adolescents. *J Neurosurg* **1983**;58:832–837
16. Shucart WA, Wolpert SM. Intracranial arterial aneurysms in childhood. *Am J Dis Child* **1974**;127:288–293
17. Delpech M. Tumeur aneurysmale de la base du cerveau. *Bull Soc Anat (Paris)* **1842**;17:112–119
18. Jain KK, Robertson E, Pollak JE. Total visualization of intracranial arterial circulation following unilateral carotid angiography in a patient with ruptured posterior cerebral artery aneurysm. A case report. *AJR* **1968**;104:83–85
19. Jamieson KG. Aneurysms of the vertebro-basilar system. Surgical intervention in 19 cases. *J Neurosurg* **1964**;21:781–797
20. Lemmen G. Drei klinisch diagnostizierte Fälle von Aneurysmen der Hirngefäße. *MMW* **1931**;78:2193–2199
21. Obrador S, Dierssen G, Hernandez JR. Giant aneurysm of the posterior cerebral artery, case report. *J Neurosurg* **1967**;26:413–416
22. Rauchfuss C. Zur Kasuistik der Hirnembolien. In: *Krankheiten des Nervensystems* (cited by Westphal C). *Jahresbericht Fortschr Med* **1878**;13:102–103
23. Uhlman O, Kunzel W. Tödliche subarachnoidale Blutung aus einem rupturierten Aneurysma der A. cerebri posterior bei einem dreijährigen Mädchen. *Padiatr Grenzgeb* **1969**;8:49–56
24. Ley-Valle A, Vilatta J, Sahuquillo J, Garcia M, Nogues P, et al. Giant calcified aneurysm on the posterior cerebral artery in a nine-year-old child. *Surg Neurol* **1983**;20:396–398
25. Amacher AL, Drake CG, Ferguson CG. Posterior circulation aneurysms in young people. *Neurosurgery* **1981**;8:315–320
26. Drake CG. Giant intracranial aneurysms: experience with surgical treatment in 174 patients. *Clin Neurosurg* **1979**;26:12–15
27. Little JR, St Louis P, Weinstein M, Dohn D. Giant fusiform aneurysms of the cerebral arteries. *Stroke* **1981**;12:183–188
28. Raskin NH, Appenzeller O. *Headache*. Philadelphia: Saunders, **1980**:210–219