



Get Clarity On Generics

Cost-Effective CT & MRI Contrast Agents



FRESENIUS
KABI

WATCH VIDEO

AJNR

External carotid-vertebral artery anastomosis for vertebrobasilar insufficiency.

K F Gerke, S S Gebarski, W F Chandler and T W Phillips

AJNR Am J Neuroradiol 1985, 6 (1) 33-37

<http://www.ajnr.org/content/6/1/33>

This information is current as
of August 6, 2025.

External Carotid-Vertebral Artery Anastomosis for Vertebrobasilar Insufficiency

Katherine F. Gerke¹
 Stephen S. Gebarski¹
 William F. Chandler²
 Timothy W. Phillips²

Surgical treatment of vertebrobasilar insufficiency has long lagged behind that of carotid disease. However, as more aggressive microsurgical techniques have been developed, surgical intervention in vertebrobasilar occlusive disease is seen with increasing frequency. The authors describe three cases of external carotid vertebral artery anastomosis, a rarely reported operative procedure, in which blood flow was successfully restored to the diseased vertebral artery. Awareness of this new technique will be useful to the radiologist servicing an active neurosurgery practice. The clinical, radiologic, and pathologic manifestations of vertebrobasilar insufficiency are also briefly reviewed.

Vertebral artery abnormalities causing deficiencies in the posterior cerebral circulation may be severely debilitating, with varied symptoms ranging from visual disturbances to hemiplegia. Yet surgical treatment for these findings has been far less aggressive than that offered to the patient with carotid disease. Historically, the preoccupation with carotid disease is logical, since carotid disease occurs more often and the symptom complex is more consistent. Moreover, the diseased carotid lends itself to surgical intervention far more readily than the smaller and relatively inaccessible vertebral artery. To further confuse the issue, when vertebral artery and carotid artery disease coexist, repair of the carotid disease often augments collateral flow to the posterior circulation sufficiently to relieve vertebrobasilar symptoms.

A subgroup of patients with vertebrobasilar insufficiency without potential for collateral circulation, whether because of disease or because of developmental inadequacy of the circle of Willis, has been identified. This group may receive a variety of innovative surgical interventions. We describe three cases in which restoration of compromised posterior circulation was achieved by external carotid-vertebral artery anastomosis, a rarely reported surgical bypass technique. As clinical knowledge of this and other aggressive approaches to vertebral artery repair develops, use of these techniques will disseminate, necessitating increased radiologic awareness of the spectrum of vertebral artery disease and its pre- and postoperative angiographic appearance.

Received March 19, 1984; accepted after revision June 13, 1984.

¹ Department of Radiology, University of Michigan Hospitals, Ann Arbor, MI 48109. Address reprint requests to K. F. Gerke.

² Department of Surgery, Section of Neurosurgery, University of Michigan Hospitals, Ann Arbor, MI 48109.

AJNR 6:33-37, January/February 1985
 0195-6108/85/0601-0033 \$00.00
 © American Roentgen Ray Society

Case Reports

Case 1

A 64-year-old right-handed normotensive nondiabetic female smoker had a 2-year history of episodic dimming of vision in the right eye. Six months before admission she had experienced hearing loss on the right and vertigo; 2 months before evaluation, she had begun experiencing episodic weakness of her left arm. She denied syncope, facial numbness, or leg weakness. On examination, a right carotid bruit was heard, but the neurologic examination was negative except for hearing loss on the right. Angiography revealed severe stenosis of the origin of the left vertebral artery and high-grade stenosis of the origin of the right vertebral

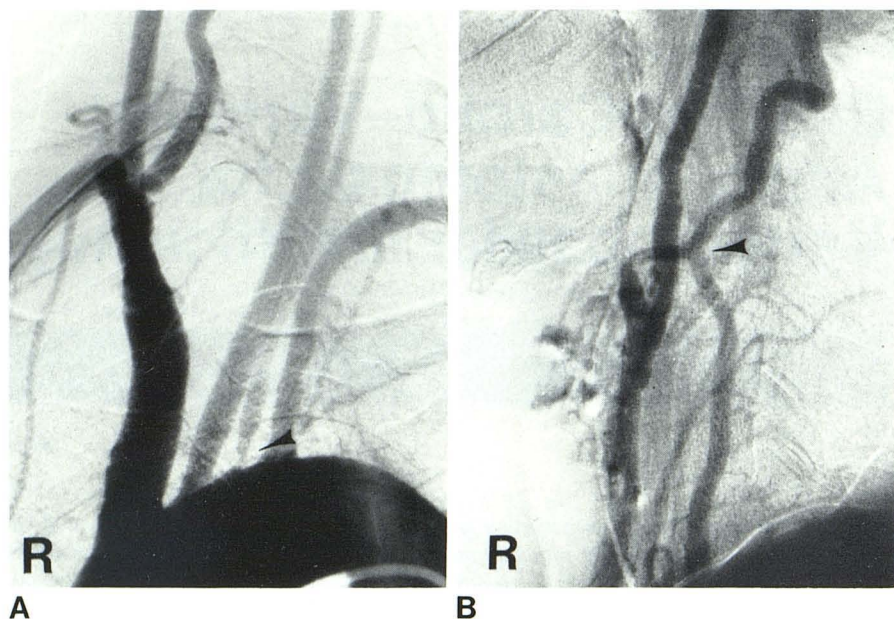


Fig. 1.—Case 1. **A**, Preoperative arch aortogram. Severe stenosis of origin of left vertebral artery (arrowhead); marked stenosis of origin of right vertebral artery, somewhat obscured by overlying vessels. (Arch origin of left vertebral artery is a normal variant.) **B**, Postoperative right common carotid artery injection. Right external carotid artery has been anastomosed end-to-side to right vertebral artery at C4–C5 level (arrowhead). Anastomosis is widely patent. Note retrograde filling of proximal right vertebral artery. (B reprinted from [1].)

artery (fig. 1A). Moderate stenoses and atherosclerotic plaque formation with ulceration at the origins of the internal carotid arteries were also present. Only a small-caliber right posterior communicating artery was identified; the left posterior communicating artery was not demonstrated. No other collateral formation was present.

A right carotid endarterectomy was performed; at the same time a right external carotid–right vertebral artery end-to-side anastomosis at the C4–C5 level was constructed to bypass the patient's stenosis. Although transluminal proximal vertebral artery angioplasty could have been employed, the inherent risks of this procedure were clinically believed to exceed those of bypass in this patient. Angiography performed 1 week postoperatively revealed a patent anastomosis (fig. 1B). Two months after surgery, the patient had no neck bruit, a normal neurologic examination, and reported no further episodic auditory, visual, vestibular, or motor symptoms.

Case 2

A 46-year-old right-handed normotensive nondiabetic male smoker in good health experienced sudden onset of dizziness and impending syncope, accompanied by diaphoresis, dysarthria, and numbness of the hand. On the way to the hospital, he had a complete cardiorespiratory arrest from which he was successfully resuscitated. On admission he exhibited normal mental status and normal physical examination except for right superior homonymous quadrantanopsia and hypesthesia to pinprick in the distribution of the maxillary division of the right trigeminal nerve. Extensive cardiac evaluation failed to reveal an etiology for his arrest. Initial cranial computed tomography (CT) was negative, but a repeat study 8 days later showed a recent infarct in the left temporooccipital area in the expected distribution of the posterior cerebral artery. Angiography revealed a marked focal stenosis of the right vertebral artery at the C3 level with an irregular proximal aneurysmal dilatation (fig. 2A). Occlusions of the peripheral branches of the left posterior cerebral artery, presumably secondary to emboli, were noted. A small-caliber left vertebral artery was patent to the basilar artery but essentially supplied only a large left posterior inferior cerebellar artery. Large-caliber right and small-caliber left posterior communicating arteries were demonstrated.

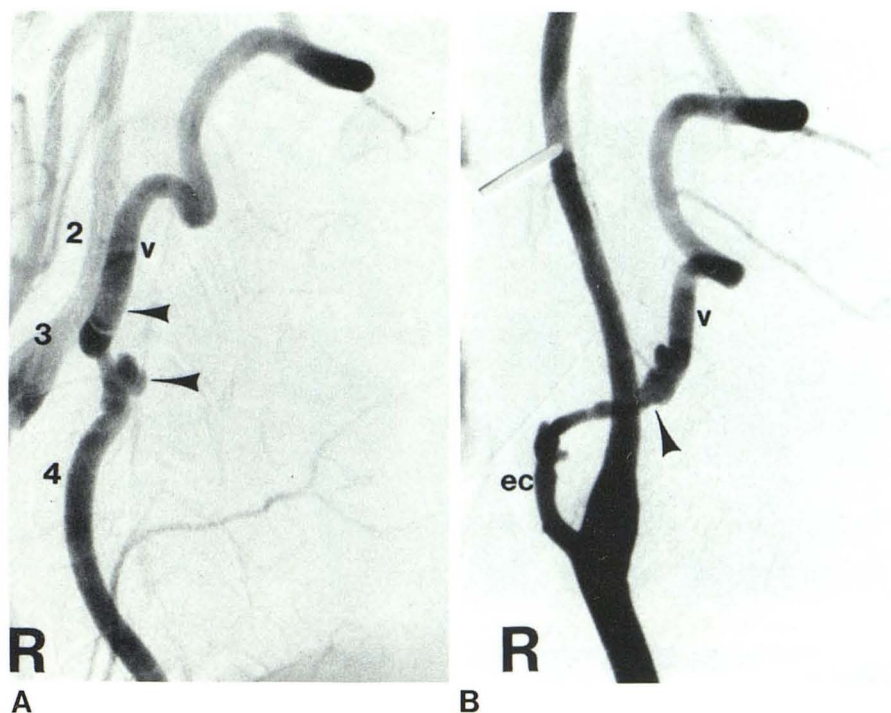
The etiology of the aneurysmal dilatation was uncertain, but may perhaps have been on the basis of old trauma, since a "karate-type" injury had occurred many years earlier. While only the single well defined ictus described above was apparent since this injury, careful questioning elicited a history of chronic episodic vertebrobasilar symptoms, which had been ignored by the patient. It was believed that the source of the apparent emboli to the posterior cerebral artery was thrombotic material forming within this irregular aneurysm. Therefore, to eliminate the aneurysm and improve the subsequently reduced blood flow, the right vertebral artery was ligated at C3 and the aneurysm isolated. The right external carotid artery was anastomosed to the right vertebral artery at the C2–C3 level in an end-to-side manner. Five days after surgery, cerebral angiography revealed a widely patent anastomosis (fig. 2B). On follow-up neurologic examination, residual numbness at the tips of the second and third digits of the right hand persisted. The patient has been otherwise asymptomatic for 4 years.

Case 3

A 47-year-old nonsmoking normotensive male diabetic had experienced acute onset of dizziness, loss of right visual field, and memory deficit 5 weeks before admission. Limited sensory deficit was present on the right side of his mouth, and he reported a 6-month history of episodic dizziness and diplopia without prolonged or fixed deficit. On physical examination, no bruits were heard in the neck. On neurologic examination, only a right homonymous hemianopsia was present. Angiography revealed occlusion of the left vertebral artery at its origin. This artery was reconstituted at the C5 level by muscular branches from the left ascending cervical and right vertebral arteries. The left vertebral artery then filled orthograde to its junction with the basilar artery (figs. 3A–3C).

To relieve the patient's symptoms, the left external carotid artery was end-to-side anastomosed to the vertebral artery at the C4–C5 level. One week after surgery, intravenous digital subtraction angiography demonstrated rapid flow through the anastomosis (fig. 3D). The postinfarction visual field deficit persisted on follow-up examination, but complete resolution of the other symptoms has occurred.

Fig. 2.—Case 2. **A**, Preoperative right subclavian artery injection for vertebral arterial filming. Stenosis of right vertebral artery just distal to dorsally located aneurysmal dilatation (*lower arrowhead*). Minor reflux of contrast material into right carotid artery. *Upper arrowhead* = level of future anastomosis; v = vertebral artery; 2, 3, 4 = vertebral bodies of second, third, and fourth cervical segments. (Reprinted from [1].) **B**, Postoperative right common carotid artery injection demonstrates widely patent anastomosis of right external carotid to right vertebral artery (*arrowhead*) at C2–C3 level. Postoperative perianastomotic spasm. ec = external carotid artery; v = vertebral artery.



Discussion

Pathophysiology

The clinical manifestations of vertebrobasilar insufficiency are diverse, not surprising in view of the multiple nuclei and tracts supplied by these vessels. Although the most common symptom is dizziness, this is a nonspecific finding [2]. More specific abnormalities relate to the ischemic brainstem (diplopia, dysarthria), cerebellum (ataxia), or occipital cortex (visual disturbances, including hemianopsia). Often these are accompanied by unilateral or bilateral face, arm, and leg weakness, numbness, or tingling. The symptom complex may also include the "drop attack," in which the patient loses muscular tone with consciousness intact and falls to the ground but immediately regains strength.

Various pathophysiologies can explain the clinical symptoms of vertebrobasilar insufficiency. Cardiac failure or arrhythmia can decrease cerebral blood flow sufficiently to produce transient ischemic attacks, and must be considered when these symptoms occur. However, it is disease intrinsic to the vertebrobasilar vessels themselves that is amenable to surgical intervention. Included in this category are arterial wall dysplasias [3], aneurysm [4], subclavian steal [5], and—most common by far—atherosclerosis [4]. The pattern of involvement by atherosclerosis varies considerably between the vertebrobasilar system and the carotid system. Atherosclerosis involving the carotid system alone occurs more often than that involving the vertebrobasilar system alone [6]. In addition, angiographic evidence for atherosclerotic plaque ulceration is recognized to be much less a feature of vertebral artery than carotid artery disease [6]. This finding supports the surgical dictum that embolism is the etiology of most

cases of symptomatic carotid disease, but that this is not so in the vertebral system. On the contrary, Castaigne et al. [4] demonstrated the primary source of symptomatic pathology in the vertebral and basilar arteries to be related to thrombosis occurring at the site of a preexisting atherosclerotic stenosis. Resulting infarctions occurred in 50% of these patients, with the territory involved determined by the relation of the thrombosis to the origin of the branches of the vertebral and basilar arteries. The vertebral artery origin and the perivertebral subclavian artery are the topographic regions most often affected by plaque and stenoses. However, pathologic studies suggest that it is unusual for *extracranial* vertebral artery disease to have clinical manifestations: Symptomatic lesions of the vertebrobasilar system are usually *intracranial* [4, 6]. This was not true of our three patients. This relation varies inversely with that seen in the carotid system, where *extracranial* occlusive disease is most often implicated as causing symptoms.

To summarize, vertebral artery disease is more protean in its manifestations and seems to be less frequent, less severe, and usually less symptomatic than carotid artery disease. All these factors have contributed to the less aggressive development of surgical techniques for treating vertebral artery versus carotid artery disease.

Surgical Considerations

The role of anticoagulants and antiplatelet agents in the treatment of vertebrobasilar insufficiency has not been established conclusively [7]. Rather, microsurgical techniques that allow direct intervention in the vertebrobasilar system have placed increasing reliance on the surgeon. However, the task

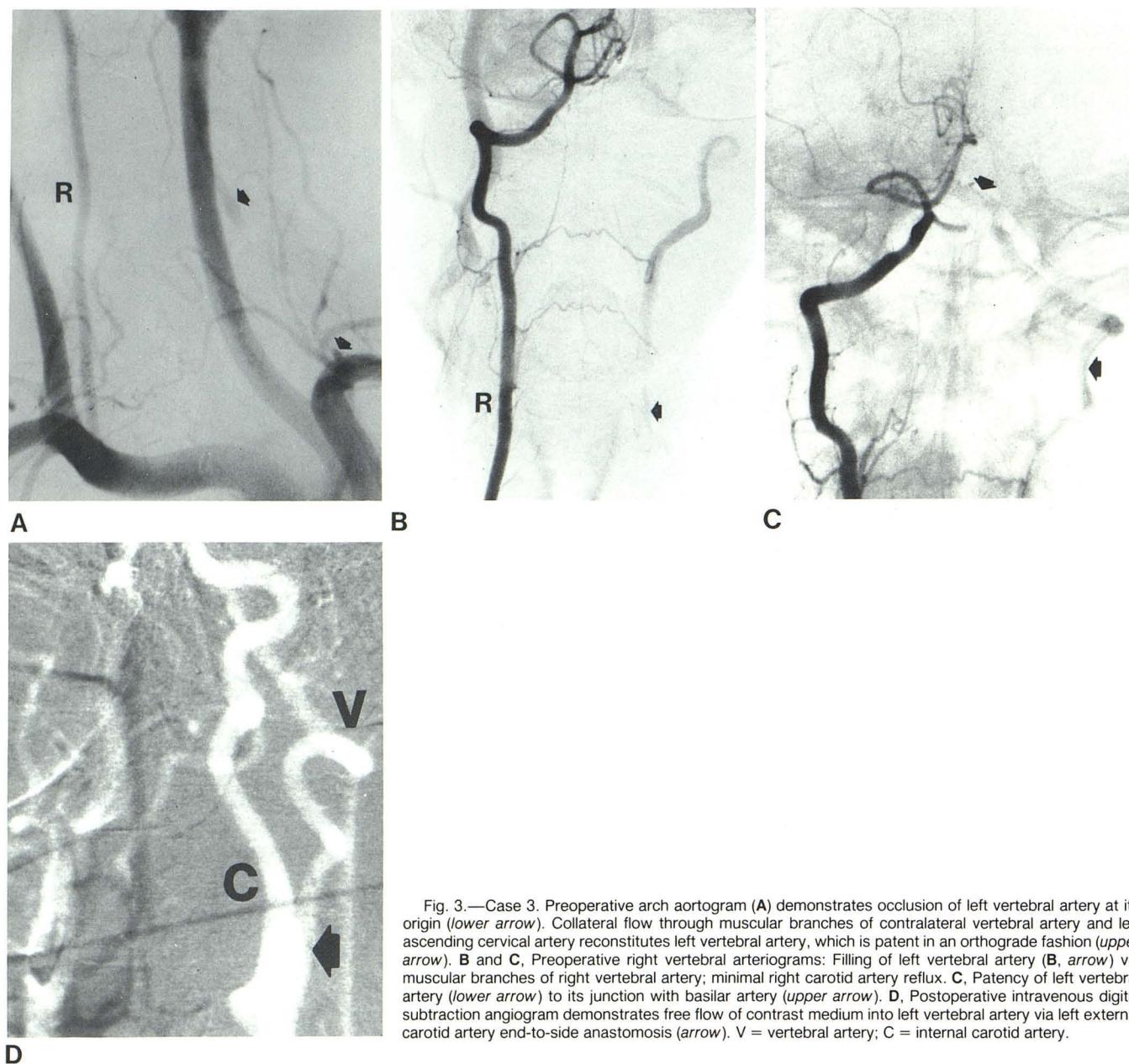


Fig. 3.—Case 3. Preoperative arch aortogram (A) demonstrates occlusion of left vertebral artery at its origin (*lower arrow*). Collateral flow through muscular branches of contralateral vertebral artery and left ascending cervical artery reconstitutes left vertebral artery, which is patent in an orthograde fashion (*upper arrow*). B and C, Preoperative right vertebral arteriograms: Filling of left vertebral artery (B, *arrow*) via muscular branches of right vertebral artery; minimal right carotid artery reflux. C, Patency of left vertebral artery (*lower arrow*) to its junction with basilar artery (*upper arrow*). D, Postoperative intravenous digital subtraction angiogram demonstrates free flow of contrast medium into left vertebral artery via left external carotid artery end-to-side anastomosis (*arrow*). V = vertebral artery; C = internal carotid artery.

faced by the neurosurgeon in attempting to relieve symptoms localized to the vertebral artery is formidable. Symptomatic carotid artery lesions are almost uniformly localized to the superficially located carotid bifurcation and thus are easily accessible. In contrast, although many atherosclerotic vertebral artery lesions are located at its origin from the subclavian artery, those lesions most often implicated in causing symptoms are located more distally. The vertebral artery not only is located deeper in the neck than the carotid artery, but also, in most patients, distal to C6, is encased by the vertebral venous plexus and the bone of the foramina transversaria. Once this difficult surgical exposure has been achieved, anastomosis proves technically more taxing, as the vertebral artery

is usually of smaller caliber and thinner-walled than the carotid artery.

The difficulty of surgical treatment of vertebral artery lesions is reflected in the multiplicity of procedures suggested for their treatment. Cate and Scott [8] first reported direct thromboendarterectomy of the occluded origin of the left vertebral and subclavian arteries in 1959, followed by DeBakey et al. [9] in 1961. Since then, other approaches to proximal vertebral artery disease have included transsubclavian endarterectomy [10, 11], subclavian-vertebral artery anastomosis with or without vein graft [12–14], common carotid-vertebral artery anastomosis with or without vein graft [10, 11, 15, 16], and angioplasty [17]. Clark and Perry [18] first reported

the use of external carotid-vertebral artery end-to-end anastomosis in 1966 as a surgical repair for the subclavian steal syndrome. Their report was followed in 1977 by that of Corkill et al. [19], who described two patients with vertebrobasilar insufficiency and proximal vertebral artery disease successfully treated by external carotid-vertebral artery end-to-side anastomosis.

Since the anastomosis of the proximal external carotid artery to the vertebral artery requires occlusion of the more distal external carotid artery, this vessel is then lost to possible future collateral supply or further anastomosis, e.g., superficial temporal-middle cerebral artery bypass. For this reason, all potential external carotid-vertebral artery anastomosis patients must be carefully evaluated and the type of occlusive correction prioritized with regard to present symptoms and prognosis. All three patients reported here had dominant vertebrobasilar symptoms. Postbypass angiography showed good cross-collateralization of the ipsilateral distal external carotid circulation from contralateral external carotid artery ramifications.

Radiologic Considerations

Preoperative evaluation including arch aortography with complete cerebral angiography must be performed to delineate the intra- and extracranial vessels in a patient suspected of vertebrobasilar disease. Special attention must be paid to good visualization of the occipital arteries, an important collateral between the external carotid and vertebral arteries. The origins of the vertebral arteries, the most frequent site of atherosclerotic lesions, must be clearly demonstrated. Concomitant carotid disease must be defined, as the surgeon often will wish to repair a superimposed significant carotid lesion either in a preliminary operation or simultaneously. It is essential to determine the potential and extant collateral supplies to the vertebrobasilar circulation, including posterior communicating artery patency, transsial collateralization from anterior or middle cerebral circulations, and muscular or meningeal contributions. If these alternative sources of blood flow are significant, surgery may not be indicated.

It has been reported that angiography performed in the immediate postoperative period may fail to demonstrate a patent anastomosis, whereas repeat studies 3–5 days later demonstrate patency [20, 21]. Perianastomotic arterial spasm, swelling, and temporary thrombosis are all hypothesized as the etiology. In our three cases, angiograms were obtained without complication 5–11 days after surgery. Although all demonstrated patent anastomoses, moderate arterial spasm was observed in case 2, in which angiography was performed only 5 days after surgery. Intravenous digital subtraction angiography was used in case 3 to determine graft patency. This less invasive procedure has been recommended as the study of choice in postoperative bypass patency evaluation [22].

ACKNOWLEDGMENT

We thank Sandra Ressler for manuscript preparation and secretarial assistance.

REFERENCES

1. Pritz MB, Chandler WF, Kindt GW. Vertebral artery disease: radiological evaluation, medical management, and microsurgical treatment. *Neurosurgery* 1981;9:524–530
2. Humphries AW, Young JR, Beven EG, LeFevre FA, deWolfe VG. Relief of vertebrobasilar symptoms by carotid endarterectomy. *Surgery* 1965;57:48–52
3. Stanley JC, Fry WJ, Seeger JF, Hoffman GL, Gabrielsen TO. Extracranial internal carotid and vertebral artery fibrodysplasia. *Arch Surg* 1974;109:215–222
4. Castaigne P, Lhermitte F, Gautier JC, Escourolle R, Derouesne C, Der Agopian P, Popa C. Arterial occlusions in the vertebrobasilar system. *Brain* 1973;96:133–154
5. Bohmfalk GL, Story JL, Brown WE, Marlin AE. Subclavian steal syndrome. Part I: Proximal vertebral to common carotid artery transposition in three patients, and historical review. *J Neurosurg* 1979;51:628–640
6. Fisher CM, Gore I, Okabe N, White PD. Atherosclerosis of the carotid and vertebral arteries—extracranial and intracranial. *J Neuropathol Exp Neurol* 1965;24:455–476
7. Terent A, Andersson B. The outcome of patients with transient ischemic attacks and stroke treated with anticoagulants. *Acta Med Scand* 1980;208:359–365
8. Cate WR, Scott HE. Cerebral ischemia of central origin: relief by subclavian-vertebral artery thromboendarterectomy. *Surgery* 1959;45:19–31
9. DeBakey ME, Crawford ES, Morris GC, Cooley DA. Surgical considerations of occlusive disease of the innominate, carotid, subclavian and vertebral arteries. *Ann Surg* 1961;154:698–725
10. Cormier JM, Laurian C. Surgical management of vertebral-basilar insufficiency. *J Cardiovasc Surg* 1976;17:205–223
11. Roon AJ, Ehrenfeld WK, Cooke PB, Wylie EJ. Vertebral artery reconstruction. *Am J Surg* 1979;138:29–35
12. George B, Laurian C. Surgical possibilities in the third portion of the vertebral artery (above C2). *Acta Neurochir [Suppl] (Wien)* 1979;28:263–269
13. Senter HN, Long ET. Subclavian to distal vertebral artery bypass. *J Neurosurg* 1983;58:607–610
14. Malone JM, Moore WS, Hamilton R, Smith M. Combined carotid-vertebral vascular disease. A new surgical approach. *Arch Surg* 1980;115:783–785
15. Edwards WH, Mulherin JL. The surgical approach to significant stenosis of vertebral and subclavian arteries. *Surgery* 1980;87:20–28
16. Camp PE. Carotid to distal vertebral artery bypass for vertebrobasilar ischemia. *J Neurosurg* 1984;60:187–189
17. Mojarteme A, Keifer JW, Zuka AJ. Percutaneous transluminal angioplasty of the vertebral arteries. *Radiology* 1981;39:715–717
18. Clark K, Perry MO. Carotid vertebral anastomosis: an alternate technic for repair of the subclavian steal syndrome. *Ann Surg* 1966;163:414–416
19. Corkill G, French BN, Michas C, Cobb CA, Mims TJ. External carotid-vertebral artery anastomosis for vertebrobasilar insufficiency. *Surg Neurol* 1977;7:109–115
20. Samson DS, Boone S. Extracranial-intracranial (EC-IC) arterial bypass: past performance and current concepts. *Neurosurgery* 1978;3:79–86
21. Khododad G. Transient postoperative occlusion of the superficial temporal-middle cerebral artery branch anastomosis: spasm, swelling, or thrombosis. *Surg Neurol* 1975;3:341–345
22. DeFilipp GJ, Pinto RS, Lin JP, Kricheff II. Intravenous digital subtraction angiography in the investigation of intracranial disease. *Radiology* 1983;148:129–136