



**Get Clarity On Generics**

Cost-Effective CT & MRI Contrast Agents



FRESENIUS  
KABI

WATCH VIDEO

**AJNR**

## **Metrizamide CT Myelography in Cervical Myelopathy and Radiculopathy: Correlation with Conventional Myelography and Surgical Findings**

J. Paul Badami, David Norman, Nicholas M. Barbaro, Christopher E. Cann, Philip R. Weinstein and David F. Sobel

This information is current as of August 6, 2025.

*AJNR Am J Neuroradiol* 1985, 6 (1) 59-64  
<http://www.ajnr.org/content/6/1/59>

# Metrizamide CT Myelography in Cervical Myelopathy and Radiculopathy: Correlation with Conventional Myelography and Surgical Findings

J. Paul Badami<sup>1</sup>  
David Norman  
Nicholas M. Barbaro  
Christopher E. Cann  
Philip R. Weinstein  
David F. Sobel

Conventional myelography, metrizamide computed tomographic (CT) myelography, and surgical findings were correlated in 30 patients with cervical radiculopathy and/or myelopathy. In 60% of patients, metrizamide CT myelography provided significant additional information including better characterization of the abnormality, lateralization if the conventional myelogram was indeterminate, more definitive demonstration of cord atrophy, foraminal narrowing not appreciated on myelography, and demonstration of abnormalities distal to a myelographic block. In no case was a myelographic abnormality not detected on metrizamide CT myelography. In patients with cervical myelopathy, a cross-sectional diameter of the cord equaling less than 50% of the subarachnoid space is predictive of poor patient response to surgical intervention.

Computed tomography (CT) has been widely accepted as an initial radiographic examination in the evaluation of lumbar radiculopathy [1-3]. The assessment of spinal pathology in patients with cervical myelopathy and/or radiculopathy has continued to consist primarily of conventional myelography. While previous studies have reported CT findings in the abnormal cervical spine [4-15], none have compared metrizamide myelography with metrizamide CT myelography and correlated the observations with surgical findings. This approach permits the development of objective criteria for the abnormal cervical metrizamide CT myelogram. The technique may in many cases eliminate the necessity for conventional myelography.

## Materials and Methods

During a 20 month period, 30 patients with cervical myelopathy and/or radiculopathy were evaluated with conventional myelography followed by metrizamide CT myelography. All patients subsequently underwent either anterior cervical discectomy, foraminotomy, or cervical laminectomy. Surgical findings were recorded at the time of surgery, and postoperative follow-up was from 6 weeks to 14 months.

Conventional myelography was performed via lateral C1-C2 puncture using horizontal fluoroscopic guidance with the patients prone. Posteroanterior (PA), lateral, swimmer, and oblique views were obtained. Metrizamide concentration was 240-300 mg I/ml with volumes of 6-12 ml. CT myelograms (GE 8800) with 5 mm beam collimation and 3 mm slice increments were obtained with the patient supine 3-4 hr after myelography. The overlapped sections were contiguous from the C4 to the T1 level. Immediately before scanning, patients were placed in a prone Trendelenburg position for 3-4 min.

Measurements of spinal cord and subarachnoid space cross-sectional area were performed utilizing a cursor-trace function and obtaining region-of-interest measurements within the circumscribed areas. Both CT and conventional myelograms were evaluated by at least two neuroradiologists working independently and correlated with pre- and postoperative neurologic findings.

This article appears in the January/February 1985 issue of *AJNR* and the April 1985 issue of *AJR*.

Received March 19, 1984; accepted after revision July 11, 1984.

Presented at the annual meeting of the American Society of Neuroradiology, San Francisco, June 1983.

<sup>1</sup> All authors: Department of Radiology, University of California, San Francisco, CA 94143. Address reprint requests to D. Norman.

*AJNR* 6:59-64, January/February 1985

0195-6108/85/0601-0059 \$00.00

© American Roentgen Ray Society

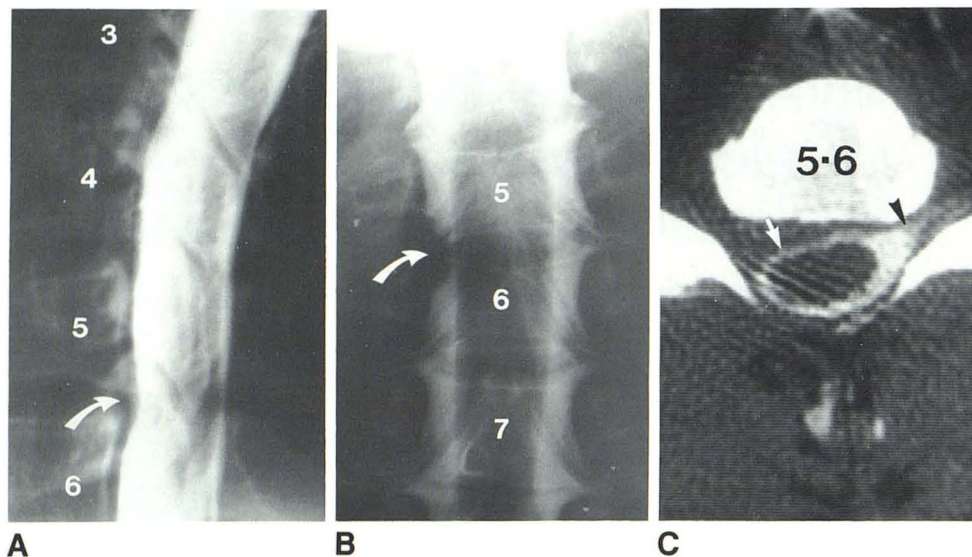


Fig. 1.—29-year-old man with right C6 radiculopathy. **A**, Lateral myelogram. Minimal ventral extradural defect at C5–C6 (arrow). **B**, Anteroposterior spot film. Right C6 root sleeve cutoff (arrow). **C**, Axial CT myelogram. Normal filling of left C6 root sleeve (arrowhead) with nonfilling of right C6 nerve root secondary to soft (nonossified) lateral disk herniation. Rotation of cord to left with attenuation of ventral subarachnoid space (arrow). Herniated disk was removed via C5–C6 anterior discectomy. Patient had complete resolution of radiculopathy.

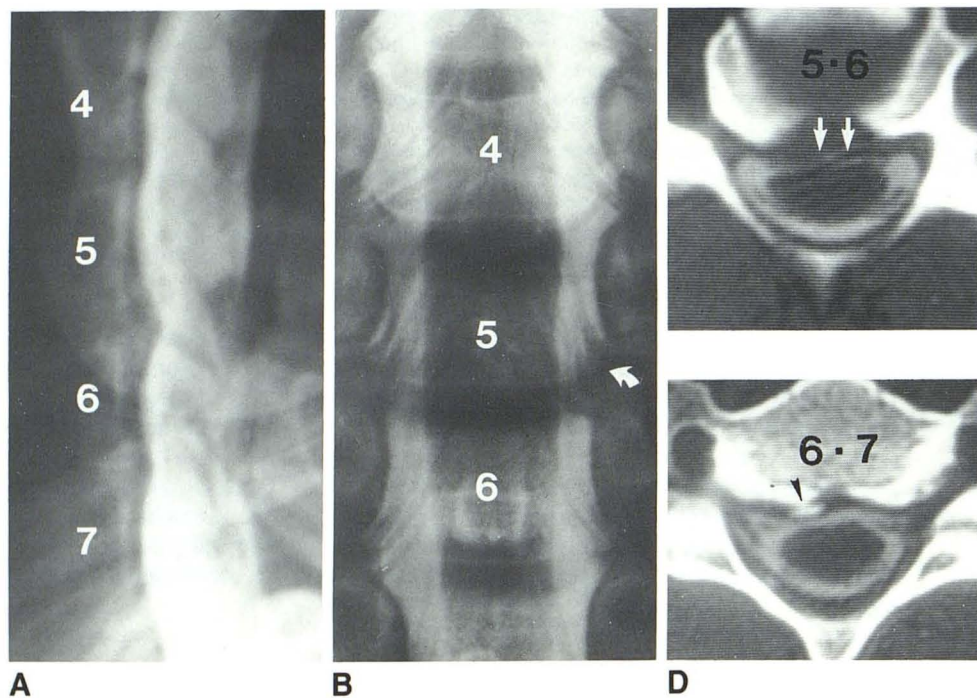


Fig. 2.—37-year-old man with neck pain radiating into right hand. There was hypalgesia in C5–C6 and C6–C7 dermatomes and loss of right biceps reflex. **A**, Lateral myelogram. Large C5–C6 ventral defect with smaller lesion at C6–C7. **B**, Frontal view. Minimal root sleeve changes at C5–C6 (arrow). **C**, Axial CT myelogram at C5–C6. Diffuse central soft disk herniation with cord deformity. Ventral subarachnoid space is nearly obliterated (arrows) and dorsal space is spared. **D**, At C6–C7. Focal spondylotic spurring (arrowhead) on right with compromise of ventral space. Degree of C6–C7 disease was not appreciated on conventional myelogram. Patient underwent anterior C5–C6 and C6–C7 discectomy. There was a soft disk herniation at C5–C6 and large osteophyte on right at C6–C7. He had resolution of pain, and some improvement in sensation. Biceps reflex remained silent.

## Results

Abnormalities identified on CT myelography in order of decreasing frequency were attenuation of the subarachnoid space (97%), spurring (93%), focal cord flattening (80%), foraminal encroachment (73%), root sleeve cutoff (66%), cord rotation (33%), disk herniation (13%), and lateral mass abnormality (3%). Metrizamide CT myelography provided significant additional information compared with conventional myelography in 18 (60%) of the 30 patients studied: (1) better characterization of myelographically demonstrated abnormality in 11 patients (37%); (2) lateralization of abnormalities, the location of which was indeterminate on conventional myelography, in

five patients (17%); (3) more definitive demonstration of cord atrophy in six (20%), which was not appreciated on conventional myelography in three; (4) foraminal narrowing not appreciated on conventional myelography in 12 (40%); (5) lateral mass degenerative abnormalities in one (3%); and (6) evaluation of pathology distal to the level of a complete myelographic block in three (10%). In no case was a myelographically noted abnormality not detected on metrizamide CT myelogram. Intentional placement of the patient in a Trendelenburg position 4 hr after the cervical myelogram did not increase the incidence of side effects usually associated with metrizamide cervical myelography.

### CT Anatomy

Normally the ventral surface of the opacified thecal sac in the cervical region is separated from the dorsal margin of the vertebral end-plate by a 1–2 mm space filled by the posterior longitudinal ligament. Disk herniation is manifested on metrizamide CT myelography as either a central or lateral soft-tissue mass centered at the intervertebral disk level increasing separation of the thecal sac from the vertebral end-plate (figs. 1 and 2).

Spondylotic spurring is seen as bony overgrowth adjacent

to the vertebral end-plate. The posterior protrusion of this "mass" of bone results in thinning of the posterior longitudinal ligament. Thus in spondylotic narrowing of the opacified subarachnoid space, the soft-tissue density between the bone and thecal sac is reduced in thickness. This contrasts with a soft disk herniation in which the distance between bone and thecal sac is increased. This phenomenon occurs either diffusely or focally and either centrally or laterally along the end-plate (figs. 2 and 3). Of importance is that a laterally located focal spur may be myelographically occult (fig. 3).

Foraminal encroachment by lateral spurring at the uncovertebral joints or degenerative hypertrophy of the lateral masses is readily identified on CT myelograms. Conventional myelography may show focal root sleeve defect but frequently is normal (fig. 4). Cord rotation (figs. 1 and 3) is a secondary manifestation of laterally located extradural masses, whether hypertrophic bone or soft disk. If such masses occur in or adjacent to the neural foramen, no root sleeve filling may be seen. Cord flattening is similarly noted in either central disk herniation or spurring when the attenuation of the subarachnoid space is more severe (fig. 4). Mild attenuation of the subarachnoid space from small ventral spurs is a subtle finding on CT compared with conventional myelography (fig. 5). This finding is demonstrated by diminution of the subarachnoid space ventral to the spinal cord with relative preservation of the dorsal space.

The ratios of the spinal cord cross-sectional area to the cross-sectional area of the subarachnoid space had prognostic significance in patients with cervical myelopathy secondary to spondylosis and/or spinal stenosis. In those patients with a cord-to-subarachnoid space ratio of greater than 50% (six patients, fig. 6A) (a relatively small subarachnoid space relative to cord size), a good recovery of function was noted after surgical decompression. In those with a cord-to-subarachnoid space ratio of less than 50% (three patients, fig. 6B) (a

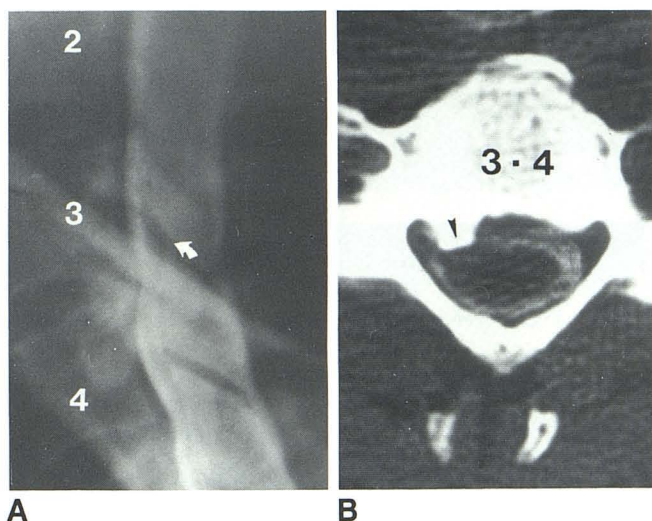
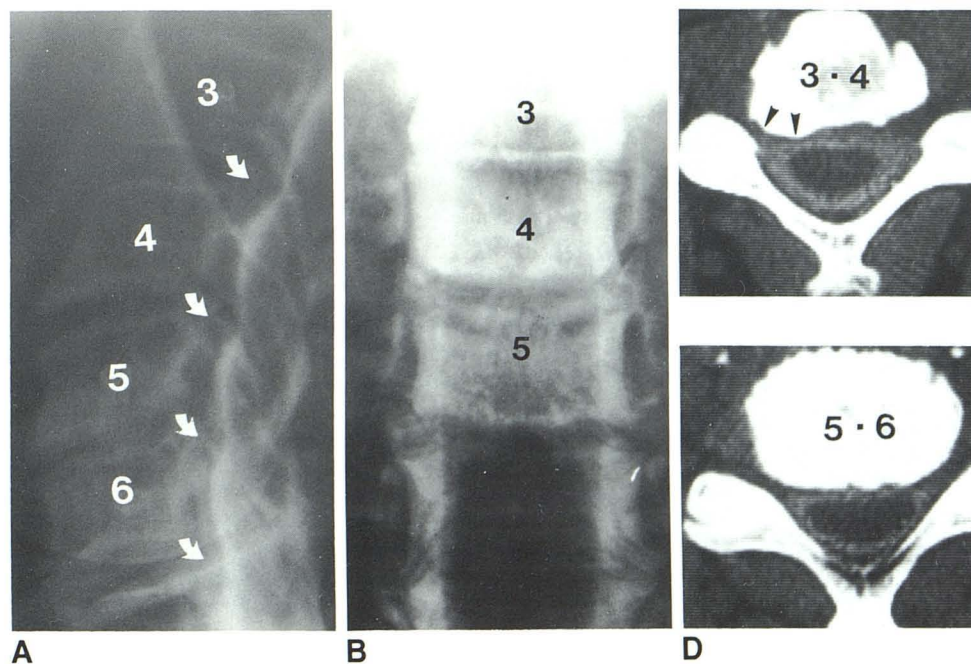


Fig. 3.—50-year-old man with neck and right shoulder pain. **A**, Lateral myelogram. Double density at C3–C4 level (arrow). There was no evidence of lateralization on frontal view. **B**, CT myelogram. Focal spur on right (arrowhead) with focal obliteration of ventral space. Symptoms improved after removal of C3–C4 osteophyte via anterior discectomy.

Fig. 4.—55-year-old man with neck, right shoulder, and right arm pain. There was patchy hypalgesia over right shoulder. Both biceps reflexes were diminished, but motor examination was normal. **A**, Lateral myelogram. Ventral defects at C3–C4 through C6 (arrows). **B**, Frontal view. Mild increase in transverse cord dimension at C3–C6 levels, without focal root sleeve abnormality. **C**, CT myelogram at C3–C4. Focal spurring at right uncovertebral joint with foraminal stenosis (arrowheads). Lateralization was not possible with conventional myelography. **D**, At C5–C6 level. Diffuse bony eburation along end-plate. Resultant spinal stenosis diminishes ventral and dorsal subarachnoid space. There is also flattening of the cord. C4–C5 and C5–C6 anterior discectomies were performed with removal of large osteophytes at both levels. There was postoperative improvement in pain and sensory deficits.



capacious subarachnoid space relative to cord size), no recovery of function was obtained postoperatively. Thus, severe cord atrophy in the face of spinal stenosis carries a poor prognosis.

One patient developed recurrent signs postoperatively. Conventional myelography was essentially normal. CT myelography well demonstrated central decompression of the spinal canal with residual lateral spurs causing cord compression (fig. 7).

In three cases, a complete or nearly complete myelographic block was encountered. Delayed CT myelograms demonstrated additional significant disease beyond the block not imaged on conventional myelograms (fig. 8).

Postoperative follow-up revealed clinical improvement in 19 (91%) of 21 patients with radiculopathy. Of the two patients showing no improvement, one was subsequently diagnosed as having thoracic outlet syndrome. As was discussed above, six patients (67%) with myelopathy showed improvement, while three patients (33%) were unchanged or worse.

## Discussion

Patients with signs and symptoms of cervical myelopathy and/or radiculopathy have traditionally undergone film-screen cervical myelography in anticipation of definitive surgery [16]. However, screen-film myelography may be misleading [11], occasionally failing to demonstrate an abnormality (e.g.,

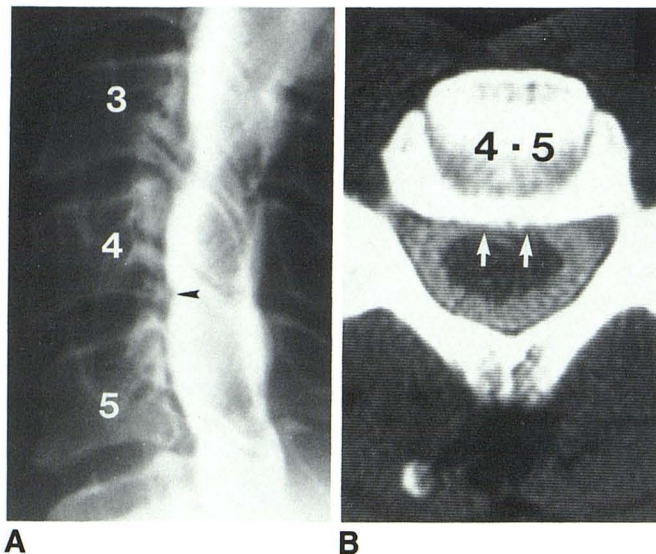


Fig. 5.—61-year-old patient with pain radiating down right arm into thumb. There was biceps weakness, and hypesthesia and hypalgesia in C5 and C6 dermatomes. **A**, Myelogram. Small ventral defect at C4–C5 (arrowhead) and larger impressions at C3–C4 and C5–C6 levels. **B**, CT myelogram at C4–C5 shows how CT can reveal subtle compromise of subarachnoid space. Ventral space attenuated centrally (arrows). Dorsal space is normal. C4–C5 and C5–C6 discectomies were performed with removal of osteophytes larger on right but significant in size bilaterally. There was postoperative improvement in pain and sensory deficits, with little improvement in biceps weakness.

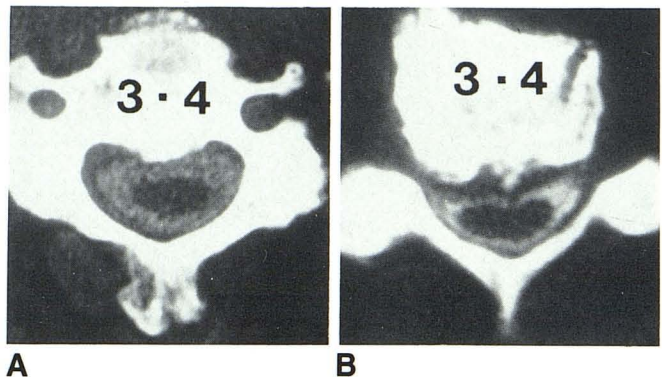


Fig. 6.—Two elderly patients with cervical myelopathy. Cord is small in both. **A**, Spinal canal is narrowed by ventral spur. Cord:subarachnoid space ratio is 23%. Neurologic defect did not improve after surgery. **B**, Spinal canal narrowing is secondary to partly ossified herniated disk. Although cord is small and deformed, cord:subarachnoid space ratio is 72%. Patient showed marked clinical improvement after cervical laminectomy.

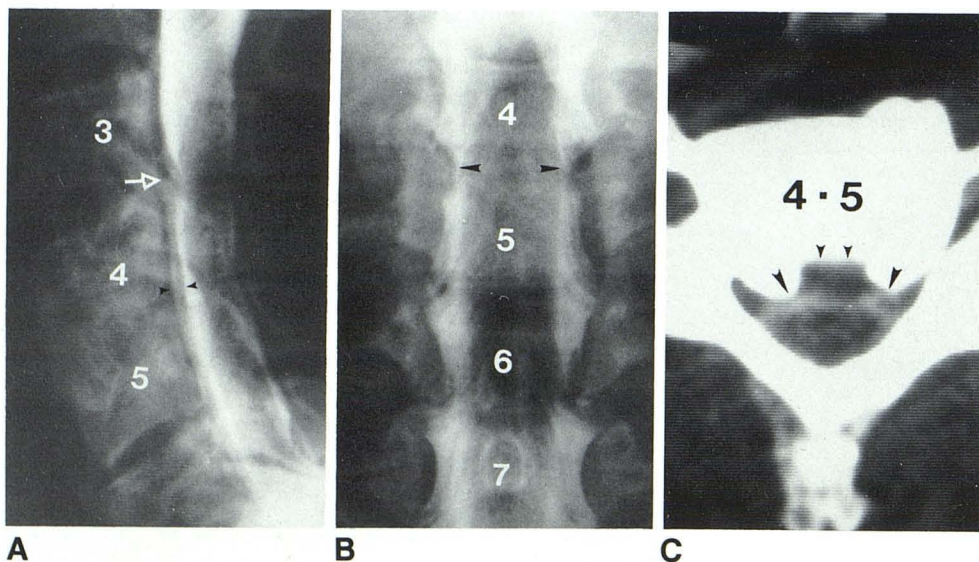


Fig. 7.—49-year-old man after C4–C5 anterior cervical discectomy and fusion with recurrent cervical myeloradiculopathy. **A**, Lateral myelogram. C3–C4 defect (arrow) and double density at C4–C5 (arrowheads). **B**, Posteroanterior view. Bilateral C4–C5 root sleeve defects (arrowheads). **C**, CT myelogram. Surgical defect (small arrowheads). Because of inadequate curettage of lateral recesses, residual spurs (large arrowheads) result in continued stenosis, cord compression, and persistent symptoms.

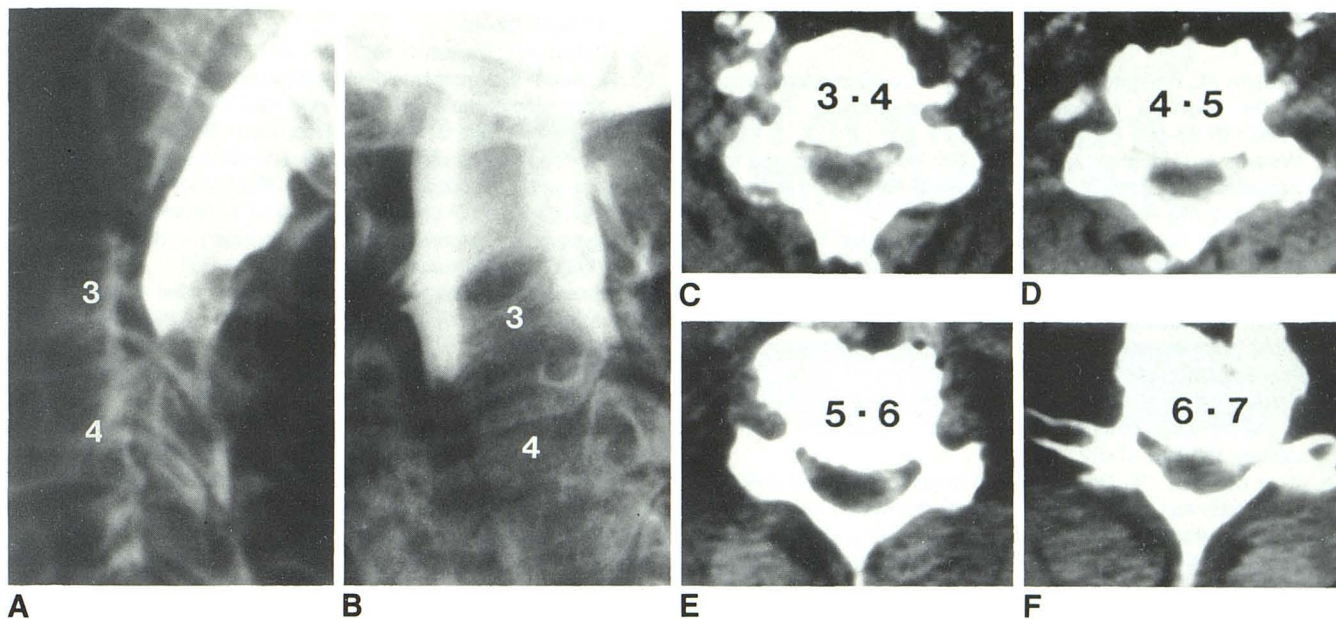


Fig. 8.—72-year-old woman with severe cervical myelopathy. Lateral (A) and posteroanterior (B) myelograms. Complete block at C3–C4. C, CT myelogram at C3–C4. Ventral spur obliterating ventral subarachnoid space. D, Canal stenosis is even more marked at C4–C5 level with secondary cord flattening.

E and F, Similar changes are noted at lower levels with most pronounced canal and cord compromise at C6–C7. These changes would not have been appreciated without metrizamide CT myelograms.

foraminal narrowing), failing to characterize the abnormality (e.g., soft disk versus bony spur), or incompletely evaluating the entire cervical canal (e.g., high cervical block).

By virtue of its axial projection and broad range of contrast sensitivity, CT is well suited for evaluation of the bony cervical spine. The addition of intrathecal contrast material permits assessment of relative cord size, degree of cord and root displacement or deformity, and relation of the cord to adjacent structures.

Metrizamide CT myelography can characterize extradural abnormalities be they soft, nonossified disks or bony spurs and facilitates the localization of laterally placed focal spurs, which is particularly important to surgeons who prefer anterior cervical discectomy [16, 17]. Because the surgeons field of view is limited in this approach, knowledge of the extent of lateral curettage necessary is paramount. The lateral elements are better evaluated including foraminal stenosis, which is usually incompletely examined on conventional myelography.

When a myelographic block is encountered, delayed CT myelography is informative, because, with time, metrizamide eventually percolates beyond these lesions allowing examination of adjacent cervical disk levels that often harbor even more severe disease. Metrizamide CT myelography, by allowing more accurate delineation of the cord size relative to the degree of spinal stenosis, may allow more accurate prognostication as to anticipated recovery of function in cervical myelopathy. In those patients with myelopathy, spinal stenosis, and severely atrophic cords with a capacious subarachnoid space relative to cord size, one expects relatively poor recovery of function after decompression. In these patients surgery may, in fact, not be indicated. Metrizamide CT myelography provides this quantitative assessment. It has been

our experience that scanning without metrizamide in patients with moderate to severe spondylosis does not allow adequate differentiation of spinal cord from the surrounding thecal sac, thus limiting the study's prognostic value.

Abnormalities demonstrated on metrizamide CT myelography may be subtle with diminution of the thickness of the subarachnoid space ventral to the spinal cord being the earliest sign of impingement on the thecal sac. It is likely that the ventral subarachnoid space is obliterated earlier than the dorsal space due to anterior tethering of the spinal cord by dentate ligaments and nerve roots [13]. It should be noted, however, that even in severe stenosis with cord compression and myelographic block, some metrizamide will be seen ventral to the cord on CT. In general ventral abnormalities appear less marked on CT than on myelography. These abnormalities probably are accentuated on conventional myelography due to hyperextension of the patient's neck along with narrowing of the canal and forward cord displacement by infolding of the posterior longitudinal ligament.

With attention to detail, metrizamide CT myelography of the cervical spine correlates well with conventional cervical myelography. In many cases it adds significant information unavailable from the latter. Of course, as with conventional myelography, clinical correlation is of utmost importance. Because it can be performed using a low dose of metrizamide (e.g., 3–5 ml, 170 mg I/ml) instilled via lumbar puncture followed by immediate scanning, it can be performed with relatively low morbidity and as an outpatient procedure. It is worth considering this technique as the primary procedure with cervical myelopathy and/or radiculopathy. In the future it should obviate conventional myelography and its attendant morbidity in many patients.

## REFERENCES

1. Williams AL, Haughton VM, Syvertsen A. Computed tomography in the diagnosis of herniated nucleus pulposus. *Radiology* **1980**;135:95-99
2. Williams AL, Haughton VM, Meyer GA, Ho KC. Computed tomographic appearance of the bulging annulus. *Radiology* **1982**;142:403-408
3. Raskin SP, Keating JW. Recognition of lumbar disk disease: comparison of myelography and computed tomography. *AJNR* **1982**;3:215-221, *AJR* **1982**;139:349-355
4. Geehr RB, Rothman SLG, Kier EL. The role of computed tomography in the evaluation of upper cervical spine pathology. *Comput Radiol* **1978**;2:79-97
5. Thijssen HOM, Keyser A, Horstink MWN, Meijer E. Morphology of the cervical spinal cord on computed myelography. *Neuroradiology* **1979**;18:57-62
6. Coin CG, Coin JT. Computed tomography of cervical disk disease: technical considerations with representative case reports. *J Comput Assist Tomogr* **1981**;5:275-280
7. Miyasaka K, Isu T, Iwasaki Y, Abe S, Takei H, Tsuru M. High resolution computed tomography in the diagnosis of cervical disk disease. *Neuroradiology* **1983**;24:253-257
8. Van der Tas C. Computed-assisted myelography in degenerative abnormalities of the cervical vertebral column. *Diag Imaging* **1979**;48:32-40
9. Dublin AB, McGahan JP, Reid MH. The value of computed tomographic metrizamide myelography in the neuroradiologic evaluation of the spine. *Radiology* **1983**;146:79-86
10. Scotti G, Scialfa G, Pieralli S, Boccardi E, Balsecchi F, Tonon C. Myelopathy and radiculopathy due to cervical spondylosis: myelographic-CT correlations. *AJNR* **1983**;4:601-603
11. Nakagawa H, Okumura T, Sugiyama T, Iwata K. Discrepancy between metrizamide CT and myelography in diagnosis of cervical disk protrusions. *AJNR* **1983**;4:604-606
12. Baleriaux D, Noterman J, Ticket L. Recognition of cervical soft disk herniation by contrast-enhanced CT. *AJNR* **1983**;4:607-608
13. Mawad ME, Hilal SK, Fetell MR, Silver AJ, Ganti SR, Sane P. Patterns of spinal cord atrophy by metrizamide CT. *AJNR* **1983**;4:611-613
14. Barrow DL, Wood JH, Hoffman JC. Clinical indications for computer-assisted myelography. *Neurosurgery* **1983**;12:47-56
15. Sackett JF, Strother CM. *New techniques in myelography*. Hagerstown, MD: Harper & Row, **1979**
16. Lunsford LD, Bissonette DJ, Jannetta PJ, Sheptak PE, Zoub DS. Anterior surgery for cervical disk disease. *J Neurosurg* **1980**;53:1-11
17. Lourie H, Shende MC, Stewart DH. The syndrome of central soft cervical disk herniation. *JAMA* **1973**;226:302-305