



## Get Clarity On Generics

Cost-Effective CT & MRI Contrast Agents

**FRESENIUS  
KABI**

[WATCH VIDEO](#)

# AJNR

## **Latex vascular occlusion balloons: histopathologic evaluation in a high-flow aortocaval fistula model.**

R G Quisling, J P Mickle and W Ballinger, Jr

*AJNR Am J Neuroradiol* 1985, 6 (4) 583-587

<http://www.ajnr.org/content/6/4/583>

This information is current as  
of August 14, 2025.

# Latex Vascular Occlusion Balloons: Histopathologic Evaluation in a High-Flow Aortocaval Fistula Model

R. G. Quisling<sup>1</sup>  
J. P. Mickle<sup>2</sup>  
W. Ballinger, Jr.<sup>3</sup>

The treatment of carotid-cavernous fistulae with intravascular, detachable latex balloons has become an accepted method. However, the histologic changes associated with such balloon embolization in a high-flow fistula state have not been described. This study evaluated the microscopic findings in a series of 12 rats studied over a 3-month period using an aortocaval fistula model. Small latex balloons were introduced into the venae cavae of rats in whom aortocaval fistulae had been surgically created 3 weeks earlier. The histopathologic changes associated with treatment of these fistulae were examined at 1, 2, 4, 6, 8, and 12 weeks. These changes can be characterized by an acute phase with thrombus formation and acute inflammation, followed by intermediate (or subacute) and chronic phases with diminishing inflammation and progressively increasing fibrosis of the fistula site. The latex balloon became encased by the fibrotic reaction but remained nonadherent and was easily removed at every study interval. No abscess formation or persistent vasculitis was apparent, and foreign-body giant cell reaction was minimal. Closure of the high-flow fistula site required the balloon to remain inflated for at least 7–9 days.

Latex balloon placement in either the arterial or venous side of carotid-cavernous or vertebrovertebral fistulae has been accepted as the most feasible method of treatment for such lesions [1–3]. Although latex is known to be a biocompatible [4, 5], the spectrum of pathologic changes associated with fistula treatment has not been addressed in an experimental model. A method of creating a high-flow aortocaval fistula in the rat has been reported [6]. This experimental model has proved to be an easily obtainable and reliable means of manipulating and studying the healing process in such fistulae. It also provides a method of examining the histopathologic changes associated with balloon occlusion of such high-flow arterial-to-venous shunts. We report the histologic changes resulting from the placement of a latex balloon within the margins of a high-flow fistula and examine the biological fate of such intravascular balloon emboli.

Received July 18, 1984; accepted after revision October 4, 1984.

This work was supported in part by grant AG 623 from the Florida affiliate of the American Heart Association.

<sup>1</sup> Department of Radiology, University of Florida Medical Center, Shands Teaching Hospital, Gainesville, FL 32610. Address reprint requests to R. G. Quisling (Box J-374).

<sup>2</sup> Department of Neurosurgery, University of Florida Medical Center, Shands Teaching Hospital, Gainesville, FL 32610.

<sup>3</sup> Department of Pathology/Neuropathology, University of Florida Medical Center, Shands Teaching Hospital, Gainesville, FL 32610.

**AJNR 6:583–587, July/August 1985**  
0195–6108/85/0604–0583

© American Roentgen Ray Society

## Materials and Methods

The method of creating a high-flow fistula in the rat has been detailed elsewhere [6, 7]. Briefly, the distal aortocaval juncture is exposed through a right flank incision and a small ellipse of the adherent common wall between the aorta and vena cava is removed transversely. The vein is repaired, leaving a fistula between the aorta and vena cava. The fistula matures over a 3-week period. The vena cava dilates and its wall thickens tremendously because of increases in connective tissue and smooth muscle. Eventually, there is an arterIALIZATION of the vein wall. The margins of the fistula initially contain organized thrombus at the fistula margin and in the inevitable area of dissection between the vessels. A pseudoaneurysm may form in this region. Healing of the fistula site occurs over the ensuing 3–4 weeks [7].

Twelve rats underwent surgical creation of such a distal aortocaval fistula. These fistula were allowed to mature for 3 weeks before they were treated using a sterile modified Debrun balloon technique. The balloon sets were gas-sterilized. Under general anesthesia the coaxial



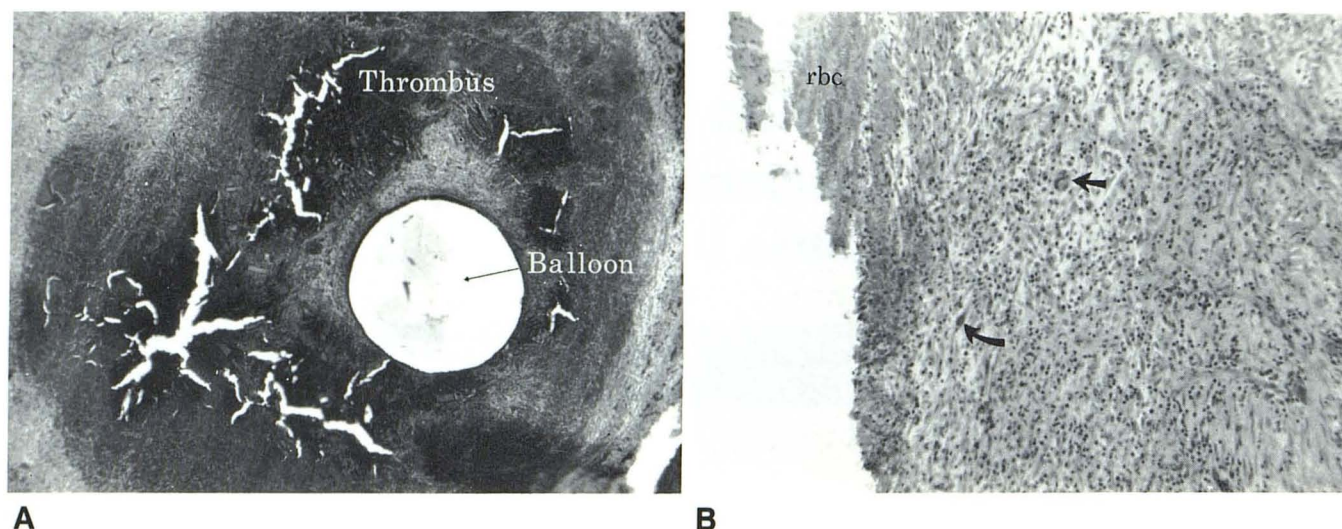


Fig. 1.—Acute phase (1 week after balloon occlusion) of high-flow aortocaval fistula. **A**, Latex balloon within lumen of inferior vena cava, surrounded by acute thrombus. Wall of vena cava is difficult to identify because of acute inflammatory response resulting from combination of venous occlusion and presence of latex balloon. (Original magnification,  $\times 9$ .) **B**, Section from margin between latex balloon and vena cava wall shows exuberant inflammatory reaction with abun-

dant polymorphonuclear white cells (straight arrow) and reactive fibroblasts (curved arrow). Even at this increased magnification ( $\times 87$ ), it is difficult to identify wall of vena cava. Balloon has fallen away from endothelial margin (to left of slide) during pathologic sectioning and therefore is not seen on this section. Both intact and degenerating red cells (rbc) within blood clot are evident.

catheter set with the attached balloon was passed via a right femoral vein cut down into the area of the fistula and inflated with contrast material (diluted diatrizoate meglumine). Correct balloon placement was based on the disappearance of the loud bruit when the balloon was inflated at the fistula site. After correct placement, the balloon was detached and the femoral vein repaired. Two rats were sacrificed at biweekly intervals (weeks 1, 2, 4, 6, 8, and 12) by perfusing the anesthetized animal through the cardiac ventricle with 10 ml of a mixture of 2% paraformaldehyde, 2% glutaraldehyde in cacodylate buffer. The fistula site was removed and imbedded. The specimens were stained with H and E stains and examined microscopically.

## Results

All rats survived the embolization and no infections occurred. Ten of the 12 rats were cured of their fistulae. Two fistulae recurred at 1 week as a result of early deflation of the balloon. The histopathologic changes associated with latex balloon occlusion can be separated into three phases. The acute phase occurs within the first 2 weeks and is associated with acute thrombosis of the vena cava and occlusion of the fistula site, eliciting an inflammatory reaction characterized by polymorphonuclear leukocytes. An intermediate or subacute phase (weeks 2–5) follows, wherein the acute inflammatory reaction and acute thrombosis are replaced by organization and fibrosis of the thrombus. Finally, the chronic or healed phase is marked by dense fibrosis (including calcium deposition) at the fistula closure site.

### Acute Phase

The presence of the latex balloon combined with the associated venous (vena cava) thrombosis initially stimulates a

dramatic inflammatory reaction. Acute hemorrhage and thrombosis occurs within the wall of the vena cava and within the lumen contiguous to the balloon. An infiltration by polymorphonuclear leukocytes and reactive fibroblasts occurs within the thrombus (fig. 1).

### Intermediate Phase

The acute inflammatory reaction and thrombosis evolves into a chronic organizing process by 5 weeks. The acute inflammatory cells are replaced by chronic inflammatory cells, macrophages containing hemosiderin, and some eosinophils. An ingrowth of new vessels and minimal degradation of the latex matrix occurs during this period. The organizing process begins peripherally and works toward the center of the thrombus. Recanalization of the vena cava occurs during this phase. Initially (by 2 weeks), small collateral channels form in the more organized portions in the periphery of the thrombus. These small channels coalesce, reconstituting the inferior vena cava by 5–7 weeks (figs. 2 and 3).

### Chronic (Healed) Phase

After 8 weeks the inflammatory cells are no longer present. There are fibroblasts and hemosiderin-filled macrophages. The thrombus has organized and become largely fibrotic. Microscopic calcification can be identified in the late healed state. The fistula region has contracted to a much smaller size. The balloon, however, remained relatively stable biologically even 3 months after treatment. Examination of the liver and spleen in the later phase demonstrated no foreign-body reaction or particles of latex (figs. 4 and 5).



Fig. 2.—Early intermediate or sub-acute phase (2 weeks after balloon occlusion). **A**, Balloon (B) within inferior vena cava (IVC). Reaction is already less cellular than during acute phase. Organization of thrombus begins at periphery and proceeds toward central region near balloon margin. Residual blood clot is evident in region of interest labeled 2c, whereas region 2b is more representative of cellular reaction. Most-organized, peripheral margin of thrombus also demonstrates earliest phase of vena cava recanalization with formation of multiple, small, venous collateral channels (arrows). (Original magnification,  $\times 13$ .) **B**, Section from region 2b (see **A**) with increased magnification ( $\times 33$ ) demonstrates less-cellular response occurring at 2 weeks as compared with that present at 1 week (cf. fig. 1B): The larger reactive fibroblasts have become elongated (f); there are numerous eosinophiles (e), fewer polymorphonuclear cells, and more lymphocytes. No foreign-body giant cells are evident.

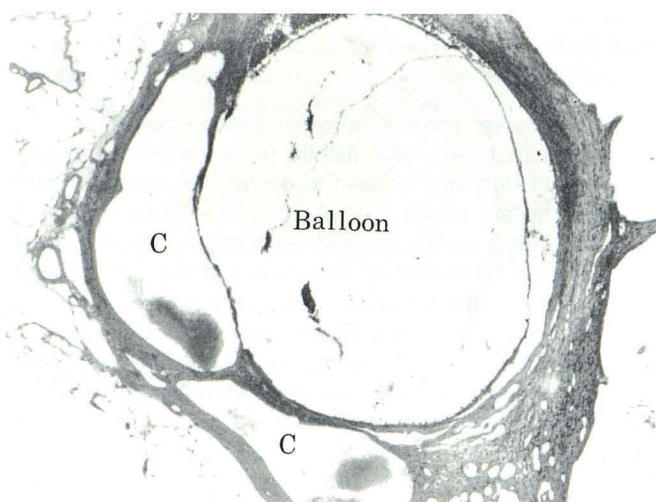
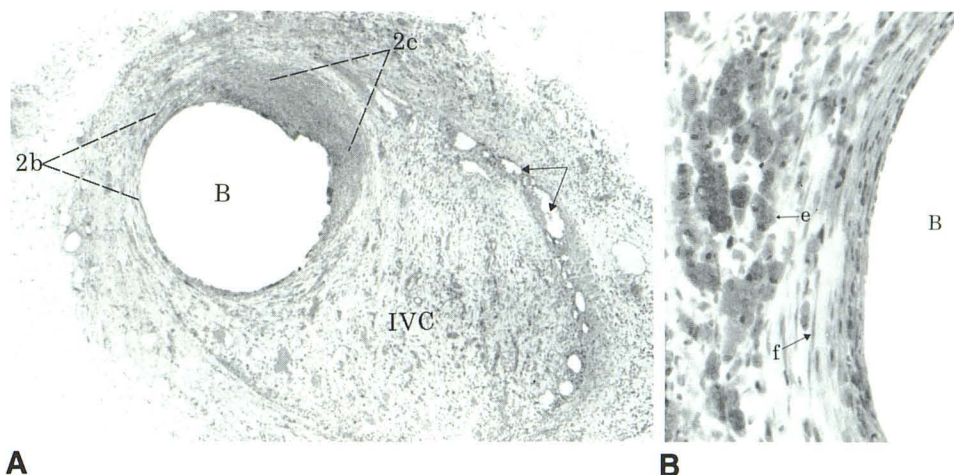


Fig. 3.—Late intermediate phase (6 weeks after balloon occlusion). Small collateral venous channels coalesce into larger ones (C), and eventually vena cava is reconstituted. This occurs at different rates, but was present in all samples by 8 weeks. It appeared complete in some at only 4 weeks.

#### Fistula Closure

The rate of balloon deflation was gradual, since partly inflated balloons were evident in the fistula sites at 6 and 8 weeks. The fistula site remained closed if the balloon stayed inflated longer than 7–9 days. Deflation before 1 week caused a recurrence of two fistulae. In one of these animals the balloon had partly deflated and then migrated proximal to the fistula. Closure of the fistula site results in part from the mechanical obstruction caused by balloon distension and in part by the thrombus that inevitably surrounds the balloon. This combination of balloon distension and adjacent thrombus provides the base for an ingrowth of fibroblasts. If the region between the balloon and the aorta is thin and the balloon

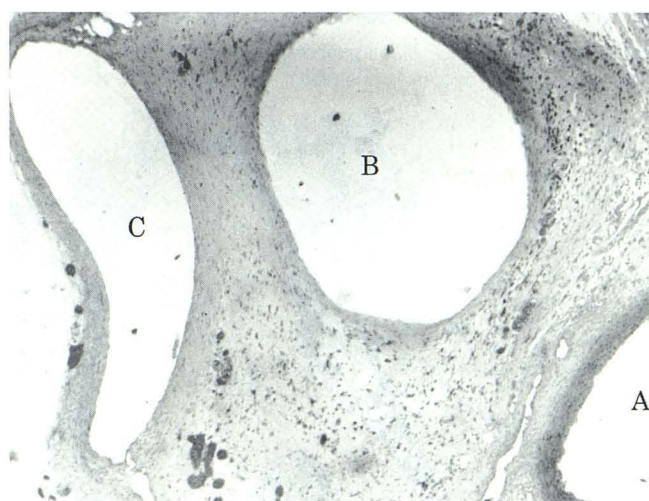


Fig. 4.—Early chronic (healed) phase (8 weeks after balloon occlusion). Only minimal cellularity. Vena cava (C) has recanalized; inflammatory cells are gone, with only hemosiderin-laden macrophages remaining. Thrombus is completely organized and densely fibrotic. Fistula tract has been obliterated by fibrosis surrounding balloon (B) and is interposed between aorta (A) and vena cava (C). During gross pathologic dissection, balloon could be removed from this encasing fibrotic mass without difficulty at this stage and also at 3 months after occlusion. No bonding or adhesions occurred between vessel endothelium and balloon.

partly deflates, a bulge may form across the fistula site. Such a bulge creates a “venous pouch” [1, 8], which was seen on specimens at about 4 weeks but was not evident on later examples (fig. 6). Over the ensuing 3 months, the fibrosis continues and the pouch disappears. The aortic wall at the fistula becomes thickened and fibrotic with no elastica or smooth muscle. None of the aortae at the fistula sites were stenosed. The vena cava is initially occluded by the balloon. The recanalization of the vena cava begins relatively quickly, with collateral channels evident within the margins of the



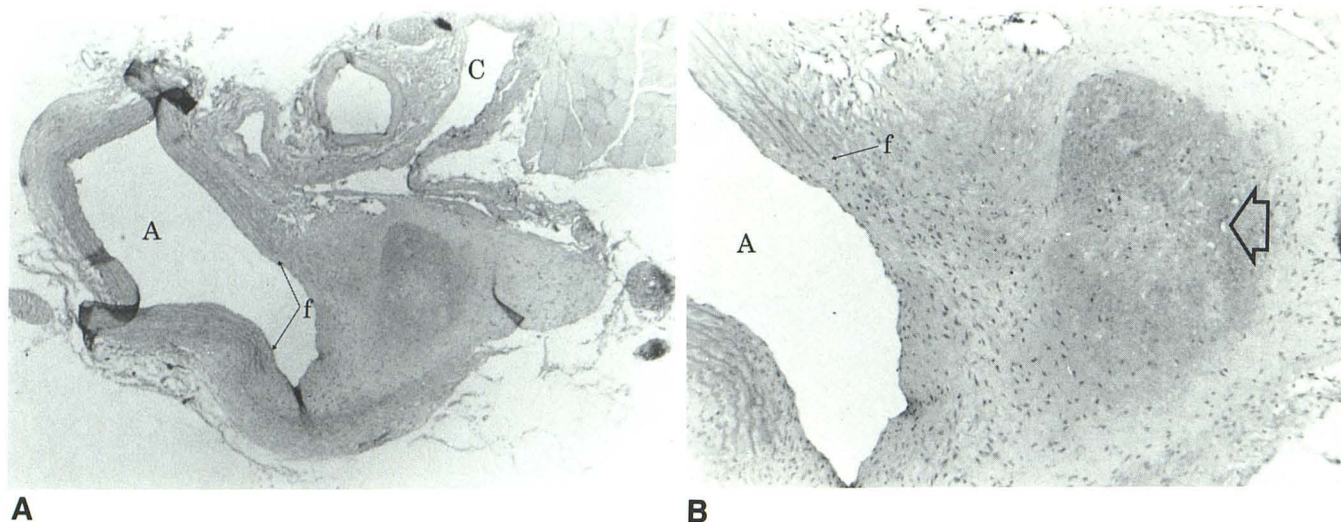


Fig. 5.—Late chronic (healed) phase (3 months after balloon occlusion). A, Fistula site (f) along part of aorta (A). No evidence of venous pouch or pseudoaneurysm. Latex balloon was removed before sectioning and therefore is not seen on this histologic section. Contracted scar between aorta and folded inferior vena cava (C) is seen better in B. (Original magnification,  $\times 13$ .)

B, Section with increased magnification ( $\times 33$ ) illustrates end result of intravascular balloon occlusion of high-flow aortocaval fistula. Margins of fistula site are seen clearly where wall of aorta is interrupted by fibrotic scar. Fistula site has reendothelialized. A particularly dense region of fibrosis contains microcalcifications (large arrow).

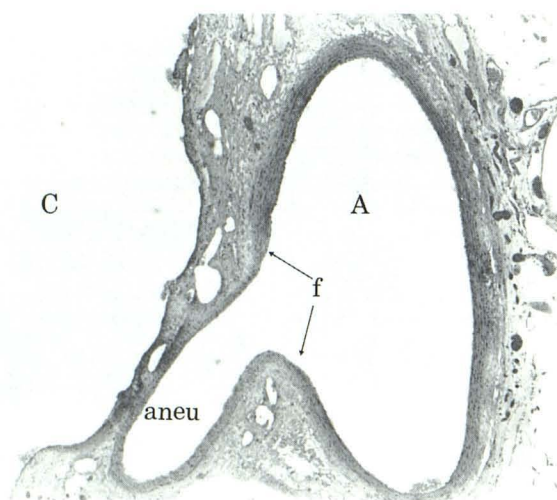


Fig. 6.—Bulge at fistula site in specimen at 4 weeks after balloon occlusion. Fibrotic changes are seen between walls of vena cava (C) and aorta (A). Fistula site (f) is easily identified by changes in aortic wall. A pseudoaneurysm (aneu) bulges from fistula but does not communicate with vena cava. This is believed to correspond to "venous pouch" seen clinically in some cases of carotid-cavernous fistulae treated by intravascular latex balloons.

thrombus by 2 weeks. Reformation of a channel sufficient to be considered an inferior vena cava was present on specimens at both 4 and 6 weeks (figs. 3 and 4).

## Discussion

We examined two aspects of latex balloon occlusion of aortocaval fistulae: (1) the histopathologic effect of contact between the balloon and the vena cava at the fistula site, and

(2) the temporal relation between balloon placement and permanent closure of the fistula. In all cases the original aortocaval fistula was allowed to evolve into a more mature phase, requiring about 3 weeks [7]. The basis for this is twofold. After 3 weeks, the histopathologic changes associated with acute thrombus formation and the inflammation associated with the surgically created fistulae have reached a chronic phase, involving fibrosis and endothelialization of the fistula tract. Thus, the more acute changes associated with the balloon occlusion can be differentiated from the chronic changes of the fistula preparation. In addition, the hemodynamics of the arterial-to-venous fistula have been allowed to stabilize. Balloon occlusion of fistulae may initially compromise the aortic lumen, which may result in ischemic myelopathy and a higher rate of failure of the model. Balloon occlusion in the subacute or chronic phase of fistula evolution does not appear to have the same neurologic difficulties (work in progress).

Closure of the aortocaval fistula requires balloon distension sufficient to preclude arterial-to-venous flow for at least 7–9 days. Premature deflation and/or migration of the balloon occurred in two cases, resulting in fistula recurrence. The actual fistula closure is the result of an acute inflammatory response elicited both by the balloon and by the thrombus surrounding it. Thrombus forms in part from the occlusion of the vena cava and in part from clot adherent to the balloon surface. Within 2 weeks the initial thrombus becomes infiltrated by fibroblasts and chronic inflammatory cells. The thrombus becomes organized and progressively more fibrotic. At 4 weeks the degree of fibrosis may be insufficient to prevent arterial pressure from creating a bulge at the fistula site; this bulge has a clinical counterpart, the venous aneurysm and/or pouch [1, 8]. Although the number of specimens is relatively small, this venous pouch was not seen on exam-

ples at 6, 8, or 12 weeks after balloon embolization. This implies that the continuation of the fibrotic reparative process gradually reduces such venous aneurysms.

The vena cava begins to recanalize within 2 weeks. It initially develops small channels within the inflammatory mass associated with the periballoon thrombus. These venous channels coalesce into larger channels, eventually forming the recanalized inferior vena cava. Several animals developed a bruit at 2–4 weeks after balloon occlusion. This bruit was ascribed to either a venous or arterial sound, since recurrence of the fistula could not be identified at the time of sacrifice nor on pathologic sectioning of the fistula site.

The biologic fate of the latex balloon was demonstrated in this study. Although it remained encased by the fibrotic reaction (as described above), the balloon was not adherent and could be removed without difficulty at every interval of sacrifice (through 3 months). In two additional animals not included in this study, the occlusive balloon was removed from the fistula site without adherence at 6 months after embolization. Examination of the liver, spleen, and pericaval/periaortic lymph nodes in two animals revealed no abnormality and, in particular, no foreign-body granuloma formation. In only one animal could a small, persistent inflammatory focus be identified. This focus was not associated with abscess formation, since it was seen at 4 weeks after embolization.

This study confirms the benign nature of the latex material of high-flow aortocaval fistula state.

#### REFERENCES

1. Debrun G, LaCour P, Vinuela R, Fox A, Drake C, Caron J. Treatment of 54 traumatic carotid-cavernous fistulas. *J Neurosurg* **1981**;55:678–692
2. Scialfa G, Valsecchi F, Scotti G. Treatment of vascular lesions with balloon catheters. *AJNR* **1983**;4:395–398
3. Negoro M, Kageyama N, Ishiguchi T. Cerebrovascular occlusion by catheterization and embolization: clinical experience. *AJNR* **1983**;4:362–365
4. Debrun G, LaCour P, Caron J, Hurth M, Comoy J, Keravel Y. Inflatable and released balloon technique. Experimentation in dog—application in man. *Neuroradiology* **1975**;9:267–271
5. Berenstein A, Kricheff II. Balloon catheters for investigating carotid cavernous fistulas. *Radiology* **1979**;132:762–764
6. Mickle JP, Menges JT, Day AL, Quisling RG, Ballinger W. Experimental aortocaval fistulae in rats. *J Microsurgery* **1981**;2:283–288
7. Quisling RG, Mickle JP, Ballinger W. High-flow, aortocaval fistulae: radiologic and histopathologic evaluation in a rat model. *AJNR* **1983**;4:369–373
8. Tsai FY, Hieshima GB, Mehringer CM, Grinnell V, Pribram HW. Delayed effects in the treatment of carotid-cavernous fistulas. *AJNR* **1983**;4:357–361