



Get Clarity On Generics

Cost-Effective CT & MRI Contrast Agents



FRESENIUS
KABI

WATCH VIDEO

AJNR

Measurement of pituitary gland height with MR imaging.

S N Wiener, M S Rzeszutarski, R T Droege, A E Pearlstein and M Shafron

AJNR Am J Neuroradiol 1985, 6 (5) 717-722

<http://www.ajnr.org/content/6/5/717>

This information is current as
of August 8, 2025.

Measurement of Pituitary Gland Height with MR Imaging

Stephen N. Wiener¹
 Mark S. Rzeszutarski
 Ronald T. Droege
 Avram E. Pearlstein
 Melvin Shafron

From sagittal magnetic resonance (MR) images with 10 mm slice thickness, the mean vertical height of the pituitary gland in 42 normal patients was found to be 5.4 ± 0.9 mm. Computed tomographic (CT) scans in the coronal plane showed the same. Measurements of pituitary size in 13 patients with tumors using both CT and MR were also essentially equivalent. The ease, comfort, and accuracy of the MR pituitary measurement supports its use as the examination of choice for measuring pituitary height.

The height of the pituitary gland is the most important measurement in the detection of an intrasellar mass. This determination is currently made from direct or reformatted coronal contrast-enhanced computed tomographic (CT) views of the sella turcica using 1.0–1.5 mm slice thicknesses [1, 2]. One can also obtain pituitary gland measurements using sagittal magnetic resonance (MR) images [3], with a slice thickness of 10.0 mm. The purpose of our report is to demonstrate the equivalency of the two methods for measuring pituitary gland height, and to suggest that MR may be clinically preferable to CT for this measurement.

Subjects and Methods

MR Procedure

Sagittal 10.0 mm slices of the head were obtained using a 0.15 T resistive MR imager (Picker). Patients were positioned supine in the scanner with the head gently immobilized to minimize motion artifacts. Multislice spin-echo pulse sequences were used with repetition times (TRs) of 500 or 850 msec and an echo time (TE) of 40 msec. Acquisition time was about 2–3½ min to collect 128 views with two averages. The signal from each view was sampled 256 times, thereby yielding a 128×256 image matrix, subsequent to two-dimensional Fourier transformation. This matrix was interpolated to 256×256 for display purposes. The direction of phase encoding was selected to cause the maximum resolution to be in the direction of the pituitary height (i.e., pixel size of 1.2 mm in the vertical direction). The height of the pituitary gland was measured using an electronic cursor on views that were magnified two times using linear interpolation.

CT Procedure

Direct coronal CT scans of the pituitary were obtained using a GE model 8800 CT/T scanner. The patients were positioned with hyperextension of the head in the supine position with the CT gantry positioned for optimal coronal projections. One hundred ml of Renografin 60 containing 29 g of organically bound iodine was injected intravenously. Scan times were 4.8 sec/slice. Images were collected using the standard head scanning protocol (320×320 image matrix with 1.5 mm slice thickness and pixel size of 0.8 mm). After completion of the test, views were magnified electronically using linear interpolation to obtain images with three times magnification. These were used for direct pituitary gland height measurement using an electronic cursor.

Received October 10, 1984; accepted after revision January 24, 1985.

¹ All authors: Department of Radiology, Mt. Sinai Medical Circle, University Circle, Cleveland, OH 44106. Address reprint requests to S. N. Wiener.

AJNR 6:717–722, September/October 1985

0195–6108/85/0605–0717

© American Roentgen Ray Society

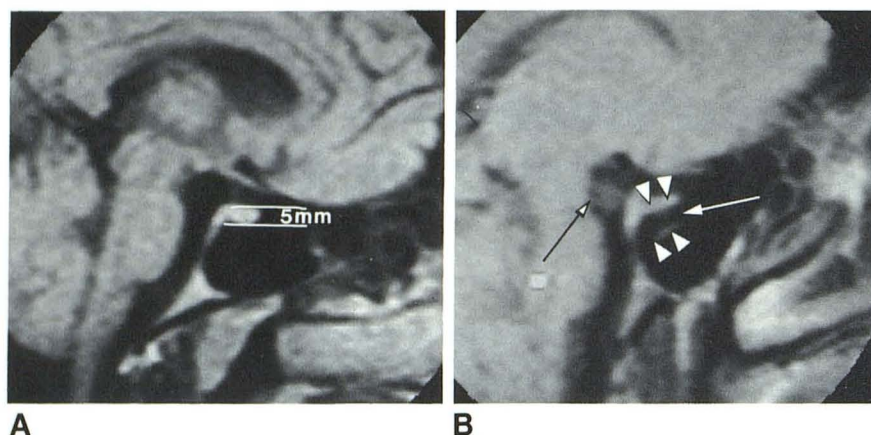


Fig. 1.—Normal pituitary. Contiguous 10 mm sagittal MR views. **A**, Midline view. Third and fourth ventricles, optic recesses, optic tract/chiasm, and brainstem. Pituitary gland vertical height = 5.0 mm. **B**, Off-center view contains part of uncus (black arrow) and carotid artery. Lumen (white arrow); walls (arrowheads).

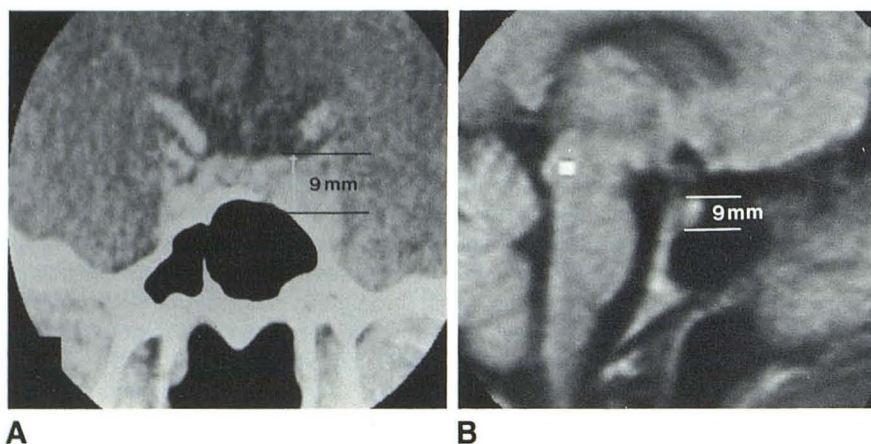


Fig. 2.—Measurement of prolactin-secreting tumor with CT (**A**) and MR (**B**). Vertical height = 9.0 mm on both. CT enlargement mainly on left.

Resolution Measurements

The resolution of the CT and MR scanners was determined experimentally using the variance method [4]. The test consisted of measuring the variance of the pixel values in regions of interest drawn over bar patterns of varying frequencies. The values measured were normalized to compute the modulation transfer function (MTF) for the device. A bar pattern phantom with alternating Plexiglas plastic and copper sulfate-doped water ($T_1 = 400$ msec) was used for both the CT and MR measurements.

Patient Population

The height of the pituitary gland was measured on sagittal MR images for 42 normal patients who had neither clinical nor chemical evidence of pituitary disease (fig. 1). There were 17 men and 25 women aged 19–83 years. The measurements were compared with the range of pituitary height values for the normal population from previously reported CT studies [2].

Another 13 patients with known pituitary tumors were evaluated using both CT and MR. The patients were 26–68 years; there were five men and eight women. These were used to compare CT and MR measurements in the same patients (fig. 2).

Computer Simulations

Simulated images were used to study the effect of slice thickness on measurement accuracy. The appearance of spherical lesions in image sections 5–20 mm thick was simulated based upon the MR pixel values observed for the pituitary gland and the surrounding tissue. Increasing slice thickness in MR or CT will reduce the contrast in the image due to partial-volume effects. The equations for partial volume effects are: $PV(obs) = PV(les) \times D/S + PV(sur) \times (S - D)/S$; $C = PV(obs) - PV(sur)$; and $CNR = C/N$. For these equations, $PV(obs)$ = observed pixel value after partial-volume effects; $PV(les)$ = true lesion pixel value; $PV(sur)$ = surrounding tissue pixel value; D = diameter of lesion in millimeters; S = slice thickness in millimeters; C = tissue contrast observed in the image; CNR = contrast to noise ratio; and N = image noise. Normally one can only measure $PV(obs)$ and $PV(sur)$ in an image. $PV(les)$ can be calculated if the lesion diameter is known (found by using CT). The noise in an MR image is normally taken as the standard deviation for a region of interest in air next to the head in the direction of the phase encoding.

Lesion diameters were varied from 3 to 15 mm in 1 mm increments, and each was assumed to be centered within the slice. The images were filtered using a two-dimensional finite impulse response digital filter with frequency response matching the experimentally measured MTF for our MR imager. Zero mean gaussian random noise was added to the images with a standard deviation selected to be com-

TABLE 1: Comparison of MR and CT Measurements of Pituitary Gland Height in Patients with Confirmed Pituitary Tumors

Case No. (age, gender)	Gland Height (mm)	
	CT	MR
1 (40,F)	16	14
2 (29,M)	14	15
3 (38,F)	16	15
4 (36,M)	14	13
5 (36,M)	12	11
6 (35,F)	5	5
7 (32,F)	9	10
8 (29,F)	18	15
9 (68,F)	22	19
10 (38,M)	12	11
11 (26,F)	15	14
12 (43,M)	35	32
13 (41,F)	14	14

parable to that measured on clinical images. Images were averaged one, two, and four times. Each of the simulated lesions was measured in a random order using the MR console with two times magnification and the electronic cursor as used for patient measurements.

Results

For the group of 42 normal patients, a mean pituitary gland height of 5.4 mm (0.9 mm SD) was measured from the sagittal MR images. Included in the 3–9 mm range, the pituitary gland height measured 3 mm in one patient, 5 mm in 26, 6 mm in 12, 7 mm in two, and 9 mm in one.

For the group of 13 patients with pituitary tumors, CT measurements demonstrated a mean pituitary gland height of 15.5 mm (range, 5–35 mm; 7.1 mm SD). For the MR measurements, the mean pituitary gland height was 14.5 mm (range, 5–32 mm; 6.2 mm SD) (table 1).

For the tumor patients, the two techniques were compared using a paired *t* statistic. The result of the test indicated that at the *p* = 0.05 level, the two measurement methods are statistically different, with the CT measurements being greater by 1.0 mm. When this consistent difference between the two methods is removed, the two methods are statistically indistinguishable at the *p* = 0.05 level.

The experimentally measured MTFs for the CT and MR imagers are illustrated in figure 3. The pixel size for CT (0.8 mm) is smaller than that of MR (1.2 mm), but the MTF shapes are similar, and the cutoff frequencies are consistent with the pixel sizes.

The effects of lesion diameters, variable slice thicknesses, and signal averaging on tissue contrast are presented in table 2. Figure 4 demonstrates examples of the simulated images using the slice thickness of 10 mm and one, two, and four averages. For diameter measurements, one of these lesions was randomly selected and displayed at the center of the image. Diameter differences of 1 pixel were readily detected for all spheres ranging from 5 to 15 mm, with a mean error of zero.

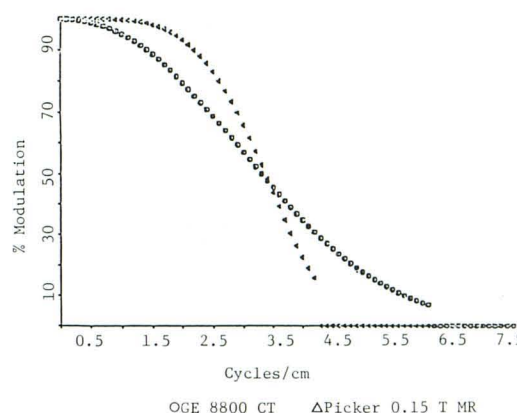


Fig. 3.—Experimentally measured MTFs for Picker 0.15 T resistive MR imager and General Electric 8800 CT/T scanner. Cutoff frequency for MR imager is 4.27 cycles/cm, and CT cutoff frequency is 6.25 cycles/cm. Curves are normalized so low frequency response is 100%.

TABLE 2: Contrast-to-Noise (C/N) Ratio as Function of Slice Thickness and Averaging for Computer-Simulated Spherical Lesion 5.0 mm Diam Totally Contained in Slice of Uniform Surrounding Tissue

No. of Averages	C/N Ratio per Slice Thickness (in mm)				
	5.0	7.0	10.0	15.0	20.0
One	24.8	17.7	12.4	8.3	6.2
Two	35.1	25.1	17.6	11.7	8.8
Four	49.6	35.5	24.8	16.6	12.4
Eight	70.2	50.1	35.1	23.4	17.6

Discussion

CT is currently the examination of choice for evaluating the pituitary gland. Coronal views after intravenous administration of contrast material are required. Direct coronal acquisition is preferable to reformatted coronal images since there is better resolution with the former [5]. The CT coronal projection, using either the supine or prone position, is uncomfortable for most patients. In some, satisfactory positioning cannot be achieved; in others, gantry angulation at right angles to the diaphragma sellae is not possible either by virtue of limited hyperextension of the head or interfering metal within the oral cavity.

Early reports of MR imaging demonstrated the ease of diagnosing intra- and juxtaseal lesions [6]. Although occasional claustrophobia and comparatively longer imaging times may hinder MR definition of the pituitary, these disadvantages are more than compensated by the benefits of improved patient comfort, elimination of intravenous contrast material, and absence of ionizing radiation. With the patient positioned in a comfortable supine position, the imaging plane is selected at the option of the console operator. The pulse sequence is chosen such that the pixel values from the pituitary and brain tissue are clearly delineated from the low signals of the surrounding air, cerebrospinal fluid (CSF), and cortical bone. The data collection time for a single CT slice is about 5 sec

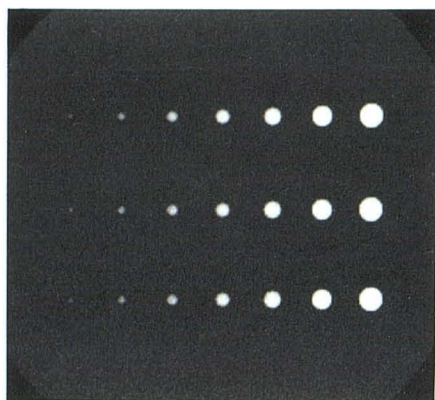
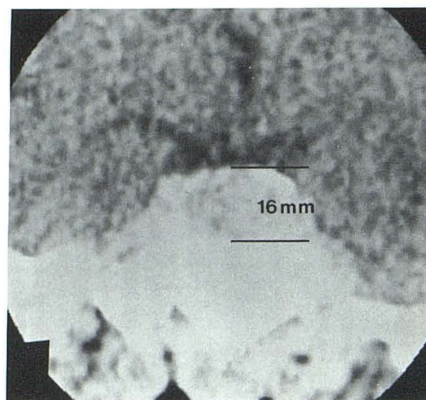
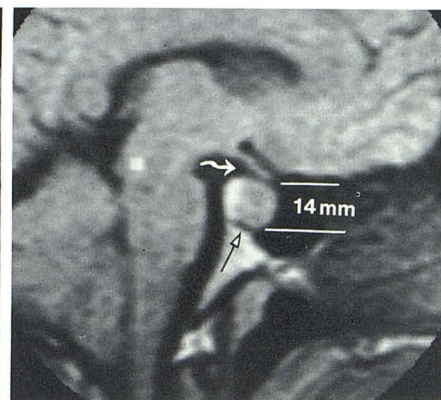


Fig. 4.—Examples of simulated MR images of spherical lesions totally contained in uniform surrounding tissue. Assumed pixel values of lesion = 92, surrounding tissue = 25, and noise SD = 2.7. Lesion diameter is 3–15 mm in 2.0 mm steps from left to right. Slice thickness is 10 mm with four, two, and one averages, respectively. The 3 mm sphere is at lower limit of detectability.

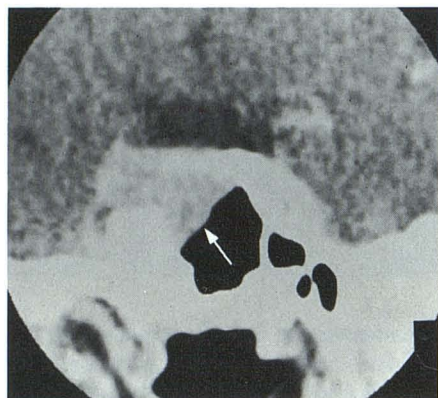


A

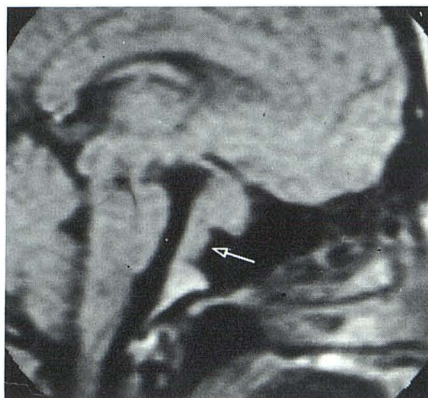

B

Fig. 5.—Prolactin-secreting tumor. Maximum vertical height: CT (A) = 16 mm; MR (B) = 14 mm. Cortical bone identified as low-intensity pixels inferiorly (*straight arrow*). Erosion of cortex posteriorly confirmed by CT. Tumor-free space between lesion and optic tract/chiasm (*curved arrow*).



A



B

Fig. 6.—Pituitary tumor. Erosion of bone and extension into sphenoid inferiorly demonstrated by CT (A) and MR (B) (*arrows*). Tumor extends to optic chiasm.

compared with 2–3½ min for MR. However, if one considers the patient positioning time, the simultaneous (MR) vs. sequential (CT) multislice acquisition, and the requirements of the contrast injection, the total examination time for MR is similar to CT.

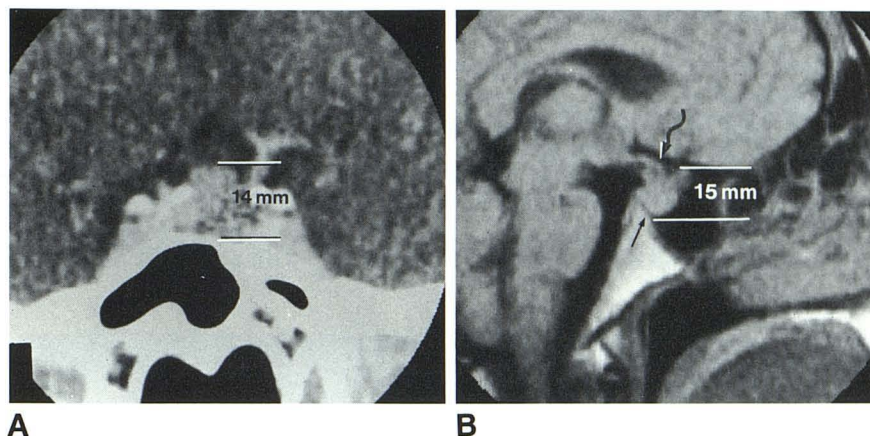
Although the MR coronal view is valuable for assessing the pituitary and juxtasellar region, this plane is not uniformly satisfactory for measurement purposes. In this plane, bright signals from bone marrow within the dorsum may be contained within the 1 cm slice thickness and obscure pituitary delineation. If thinner slice thicknesses comparable to CT are chosen, the resulting decrease in the signal-to-noise ratio degrades pituitary and lesion detection.

We chose the sagittal view of the pituitary gland since the sellar contents can be demonstrated easily using the multislice option and contiguous 1 cm slice thicknesses. Patient positioning with laser beam localization of the midline is accomplished with the head in a comfortable neutral position. The

midline selection need not be ultraprecise, since an offset, for example, of 5 mm would still contain the gland within a 10 mm slice and yet not include the higher intensity signals from juxtasellar tissue. The central slice usually includes the optic tracts and chiasm, the third ventricle including the infundibular and supraoptic recesses, the massa intermedia, and the central parts of the brainstem (fig. 1A). The precision of the midline view can be judged from the appearance of the adjacent contiguous slices. The internal carotid artery and the uncus often are visible on the improperly centered slice (fig. 1B). The need for additional, off-center images, especially when the gland is enlarged, can be further judged by coronal plane views.

The MR sagittal view of the sphenoid bone and sella turcica contain a variable amount of high signal intensity, presumably from marrow fat. The usual pattern is a triangular area of sphenoid marrow posteroinferiorly, extending cranially as a narrow stem to expand slightly within the dorsum sellae

Fig. 7.—Pituitary tumor. Lobulated superior contour defined by CT (A) and MR (B). Maximum vertical height: CT = 14 mm; MR = 15 mm. Cortex preserved inferiorly (*straight arrow*). Lesion extends to optic chiasm (*curved arrow*).



immediately posterior to the gland (figs. 1, 2, 5, and 6). Rarely, a small focus of marrow signal is identified at the tuberculum anteriorly. Since neither air nor cortical bone yields MR signals, variations in sphenoid sinus development inferiorly do not vary the MR image or affect the measurement. Tumors that extend inferiorly are identified easily (fig. 6). Occasionally, a relatively large marrow space is encountered immediately inferior to the gland. For these patients, low pixel values representing cortical bone are used to demarcate the inferior limits of the pituitary (figs. 5 and 7). Conversely, absence of cortical bone suggests tumor erosion of bone (figs. 5 and 6). Difficulty in the MR sagittal measurement should be expected if the tumor erodes into the marrow space, with loss of definition inferiorly. However, we did not encounter this problem in the limited number of tumor patients studied.

The superior limit of the pituitary can be defined easily also and well contrasted with CSF. Alterations in contour in the MR sagittal plane are similar to those on coronal CT images (fig. 7). The MR image provides a better view of the tumor-free space between the lesion and the optic tracts and chiasm. Precise measurements are difficult only for larger lesions that extend superiorly and that merge, for example, with the optic tracts or frontal lobes (fig. 6).

The pulse sequences used will not identify microadenomas contained within the gland or that do not produce glandular enlargement of greater than 3 mm. Variations in signal intensity within the MR image of the pituitary have been described in patients with pituitary tumors, but we were unable to confirm this finding for all lesions [3, 6]. The diagnostic limitations of small hypo- or hyperdense areas within the pituitary have been noted with CT also. Similarly, alterations in the contour of the superior surface of the intrasellar contents have been shown to have questionable clinical significance [5].

We found good clinical agreement between the CT and MR measurements of pituitary height. The 42 normal patients evaluated by MR were found to have a mean height of 5.4 mm, consistent with the value of 5.3 mm previously determined by coronal CT [2]. A similarly excellent correlation between CT and MR was found for the measured pituitary tumors. Although a systematic difference of 1 mm was ob-

served, the two methods can be made to agree if this small difference is considered. The larger CT values could result from difficulties in obtaining a precise coronal plane and the measurement of a slightly oblique diameter.

The similar results for CT and MR are to be expected for a variety of reasons. First, the MTF curves for CT and MR are quite similar. Although CT is better able to resolve small objects, this advantage is not critical to accurate pituitary height measurements because the height is relatively large (i.e., 5 mm or greater) compared with the resolution limits of CT and MR (0.8 and 1.2 mm, respectively). Second, both methods provide a contrast-to-noise (C/N) ratio sufficient to enable lesion boundaries to be accurately delineated. CT achieves the required C/N ratio via thin image slices that minimize the contrast-degrading effects of partial-volume averaging. Thick slices are acceptable for MR because the inherent lesion contrast is so great that significant contrast loss attributable to partial volume is tolerable (table 2). Furthermore, the thicker slice is generally necessary for a 0.15 T resistive imager to increase the MR signal strength so that surrounding anatomy is clearly depicted. Finally, the simulated images confirm the accuracy with which spherical lesion dimensions can be measured, given the MR imaging characteristics.

If the measurement of the vertical height of the pituitary is to remain a clinically important criterion for the diagnosis of a pituitary tumor and is used as a guideline of response to medical therapy, the MR sagittal view can be substituted for the comparable CT measurement with greater convenience to the patient and with potentially lesser risk.

ACKNOWLEDGMENTS

We thank Victoria Stine for manuscript preparation, Robert Newhouse for photography, and Susan Adamczak and Sophia Christopoulos for technical assistance.

REFERENCES

1. Swartz JD, Russell KB, Basile BA, O'Donnell PC, Popky GL. High resolution computed tomography of the intrasellar contents:

- normal, near normal and abnormal. *Radiographics* **1983**;3:228-247
2. Wolpert SM. The radiology of pituitary adenomas. *Semin Roentgenol* **1984**;19:53-69
 3. Oot R, New PFJ, Buonanno FS, et al. MR imaging of pituitary adenomas using a prototype resistive magnet: preliminary assessment. *AJNR* **1984**;5:131-137
 4. Droege RT, Rzeszutarski, MS. Modulation transfer function from the variance of cyclic bar images. *Opt Eng* **1984**;23:68-72
 5. Wolpert SM, Molitch ME, Goldman JA. Size, shape, and appearance of the normal female pituitary gland. *AJNR* **1984**;5:263-267, *AJR* **1984**;143:377-381
 6. Hawkes RC, Holland GN, Moore WS. The application of NMR imaging to the evaluation of pituitary and juxtasellar tumors. *AJNR* **1983**;4:221-222