



**Providing Choice & Value**

Generic CT and MRI Contrast Agents



FRESENIUS  
KABI

CONTACT REP

**AJNR**

**Embolization of intramedullary arteriovenous malformations of the spinal cord.**

J A Horton, R E Latchaw, L H Gold and D Pang

*AJNR Am J Neuroradiol* 1986, 7 (1) 113-118

<http://www.ajnr.org/content/7/1/113>

This information is current as  
of July 4, 2025.

# Embolization of Intramedullary Arteriovenous Malformations of the Spinal Cord

Joseph A. Horton<sup>1</sup>  
 Richard E. Latchaw<sup>1</sup>  
 Lawrence H. A. Gold<sup>2</sup>  
 Dachling Pang<sup>3</sup>

Intramedullary spinal cord arteriovenous malformation (AVM) can be a devastating disease. It is not usually amenable to surgery without producing severe neurologic deficit. Previously, the risk of cord ischemia was considered a contraindication to therapeutic embolization. Three patients with intramedullary spinal cord AVMs were examined and treated using polyvinyl alcohol foam, mixed with Gelfoam in two cases. In all three cases there was marked improvement, in two to complete normalcy and in the other to near-normalcy. Successful therapy involves the appropriate angiographic mapping, choice of embolus size and composition, and challenge of function by either test occlusion or long perfusion with contrast material.

Since the work of Doppman et al. in 1969 [1] and again in 1971 [2], of Djindjian and Merland [3], and of Riche et al. [4], the treatment of spinal cord arteriovenous malformations (AVMs) has included embolization as well as excision. Dorsal spinal cord AVMs can be attacked surgically since there is no central nervous tissue between the AVM and skin. Intramedullary and ventral AVMs are not so easily amenable to surgery because a myelotomy would be required. Dorsal AVMs tend to be supplied by posterior spinal arteries and, therefore, can be either embolized or surgically removed with relatively little fear of ischemia to the anterior spinal artery distribution. On the other hand, intramedullary and ventral spinal cord AVMs may be supplied by the anterior spinal artery and have therefore been considered unsafe candidates for embolization.

In any given patient multiple radicular arteries may connect with and feed the anterior spinal artery. For this reason interruption of one or more of the *radicular* arteries may be well tolerated as long as flow in the anterior spinal artery is preserved by collaterals. Thus, if one uses emboli larger than the anterior spinal artery but smaller than the vessel(s) feeding the AVM (fig. 1), one can theoretically embolize the malformation with impunity.

## Case Reports

### Case 1

A 24-year-old man had left leg weakness for 1 year. Just before admission, he developed acute headache, meningismus, and increased weakness of his left leg. On physical examination, he had weakness, hyperreflexia, and positive Babinski on the left, but no other deficit. Myelography showed a mass extending from T2 to T4 accompanied by tortuous dilated vessels. Spinal cord angiography showed an anterior and intramedullary AVM supplied by the left T6 intercostal (fig. 2A) and branches of the left thyro/costocervical arteries (fig. 2D). These supplied the AVM by means of the anterior spinal artery or a branch of it. (The reason for referring to the target vessels as the *thyro/costocervical trunk* is to underscore the innate difficulty encountered when normally small vessels are abnormally enlarged and possibly variational in their anatomies in the face of an angiodysplasia such as an AVM. While it is most likely that the artery to which we here refer is the thyrocervical, it is by no means

Received October 11, 1984; accepted after revision June 6, 1985.

Presented in part at the Symposium Neuroradiologicum, Washington, DC, October 1982.

<sup>1</sup> Department of Radiology, University Health Center of Pittsburgh, Presbyterian-University Hospital, Pittsburgh, PA 15213. Address reprint requests to J. A. Horton.

<sup>2</sup> Department of Radiology, University of Minnesota Hospitals, Minneapolis, MN 55455.

<sup>3</sup> Department of Neurosurgery, University Health Center of Pittsburgh, Pittsburgh, PA 15213.

**AJNR 7:113-118, January/February 1986**

0195-6108/86/0701-0113

© American Society of Neuroradiology



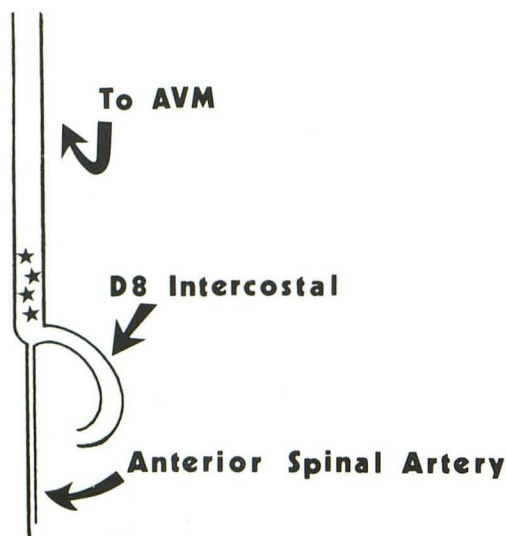


Fig. 1.—Rationale for treatment. Emboli (stars) are larger than anterior spinal artery, but smaller than vessel supplying AVM.

certain, and an unreasonable amount of further investigation would be required to show this to be the case.)

Although the anterior spinal artery was clearly in jeopardy, it was believed that the risk of doing nothing or of attacking it surgically exceeded the risks involved in embolization. For this reason, embolization using polyvinyl alcohol (PVA) foam was undertaken. During the first stage, about 75 emboli (1-mm-diam compressed cylinders) were injected into the T6 intercostal artery (fig. 2A). Although some of the AVM remained patent, it was supplied only by a small vascular pedicle from the T6 intercostal artery (fig. 2B). Immediate angiography of the left thyro/costocervical trunk showed dramatic and immediate increase in flow from this vessel to the AVM (fig. 2E). Because a large amount of contrast material had been used (250 ml) and because the patient was becoming fatigued, the procedure was discontinued.

After the embolization, the patient developed stiff neck, fever, and white blood cells in the cerebrospinal fluid (CSF), but culture was negative. Tentative diagnosis of aseptic meningitis was made, and recovery was uneventful. There was no significant change in neurologic status.

One month later, repeat angiography showed further decreased flow through the residual T6 intercostal supply (fig. 2C). This feeder was again embolized, providing complete occlusion of the radiculo-medullary feeding artery. There had been a substantial decrease in the prominence of the thyro/costocervical supply (cf. fig. 2F with fig. 2E) in the 4 week interval, and this was also definitively embolized (fig. 2G).

Four months later, angiographic evaluation showed no evidence of residual AVM from any supply (fig. 2H). Seen in long-term follow-up (8 years), the patient had returned virtually to normal and was working successfully.

#### Case 2

An 8-year-old boy had been evaluated 1 year before at another institution for subarachnoid hemorrhage. At that time, cranial CT and cerebral angiography were normal. Myelography was diagnostic of an AVM, and spinal cord angiography showed an intramedullary AVM with supply from the right T5 and left T8 intercostal arteries. The right intercostal artery was partly embolized and the patient underwent surgery. The result was believed to be total excision of the

AVM. The patient did well for about 1 year. By that time, he had some further decrease in strength in his legs, his limp increased, and sensory changes in his legs were present. Bowel and bladder problems were also present.

Myelography again showed a large tangle of vessels in the upper dorsal canal. Spinal cord angiography (figs. 3A–3C) under general anesthesia disclosed three principal blood supplies to the AVM, the largest being the left T8 intercostal artery. The left supreme intercostal and right thyro/costocervical arteries also contributed. A lateral view strongly suggested that the AVM was in and/or anterior to the cord.

The next week, we embolized the AVM with the patient under local anesthesia. The reason for local rather than general anesthesia in the case of a child was to permit evaluation of his neurologic status throughout the procedure. While somatosensory evoked potentials (SSEPs) might have furnished some useful information, the likelihood was that it would only inform us about dorsal column function but not about the anterior and lateral cord.

We first catheterized the left T8 intercostal artery and injected a non-leak-balloon catheter. This was inflated to complete occlusion of the proximal intercostal artery, and the patient was evaluated continuously for 15 min without evidence of any change in his neurologic status. The balloon was deflated and withdrawn and the AVM embolized with 1.0 and 1.4 mm pieces of PVA foam. No increase in his neurologic deficit occurred. We next catheterized the left supreme intercostal artery. It was impossible to place even a small balloon into this artery. Therefore, we elected to perfuse the artery with contrast material slowly over about 5 min to provoke a neurologic deficit. None occurred, and it was similarly embolized with PVA. Finally, the right thyro/costocervical artery was catheterized and perfused without the onset of a deficit. It, too, was embolized in a similar manner. Immediate subtracted fluoroscopic angiography of the right subclavian artery failed to show the thyro/costocervical artery.

Over the next week, the patient had no change in his neurologic status. Angiography 1 week later showed complete closure of all previously embolized arteries (figs. 3D and 3E). One month later, the patient's neurologic status had improved to the best that it had been since his operation over a year earlier. A CT scan showed PVA particles within the spinal cord confirming the intramedullary location of the malformation (fig. 3F).

The patient improved and reached a plateau, but at a level believed not to be as nearly intact as would have been expected. Because of this, follow-up angiography was done and showed persistence of malformation, now supplied by a muscular branch of the right vertebral artery arising at the level of the bottom of C3 (fig. 3G). It was impossible to catheterize this artery selectively since (1) the vertebral artery itself was small, (2) the vessel supplying the AVM was smaller still, and (3) it arose at about a 100° angle to the path of the parent vertebral artery.

Since we had previously shown the left vertebral artery to be the dominant one, it was deemed safe to occlude the right vertebral permanently. This we did with a 1 mm B-D detachable balloon *distal* to the origin of the abnormal artery (fig. 3H). Before detachment the balloon was inflated for 10 min without producing a neurologic deficit. To prevent the balloon from migrating cephalad, we detached it just proximal to the level at which the vertebral artery curves laterally away from the foramina transversaria. This curve presents an un-navigable barrier to the elongated balloon and, therefore, resists distal movement. With the balloon now in place between the catheter and the brain, we were able to embolize the AVM via the right vertebral artery-to-muscular artery route. A check angiogram confirmed occlusion of this vessel (fig. 3I). Additional supply to the malformation from both L4 arteries was demonstrated and embolized at this time.

The patient improved steadily, though slightly after this last procedure. He had no further hemorrhage.



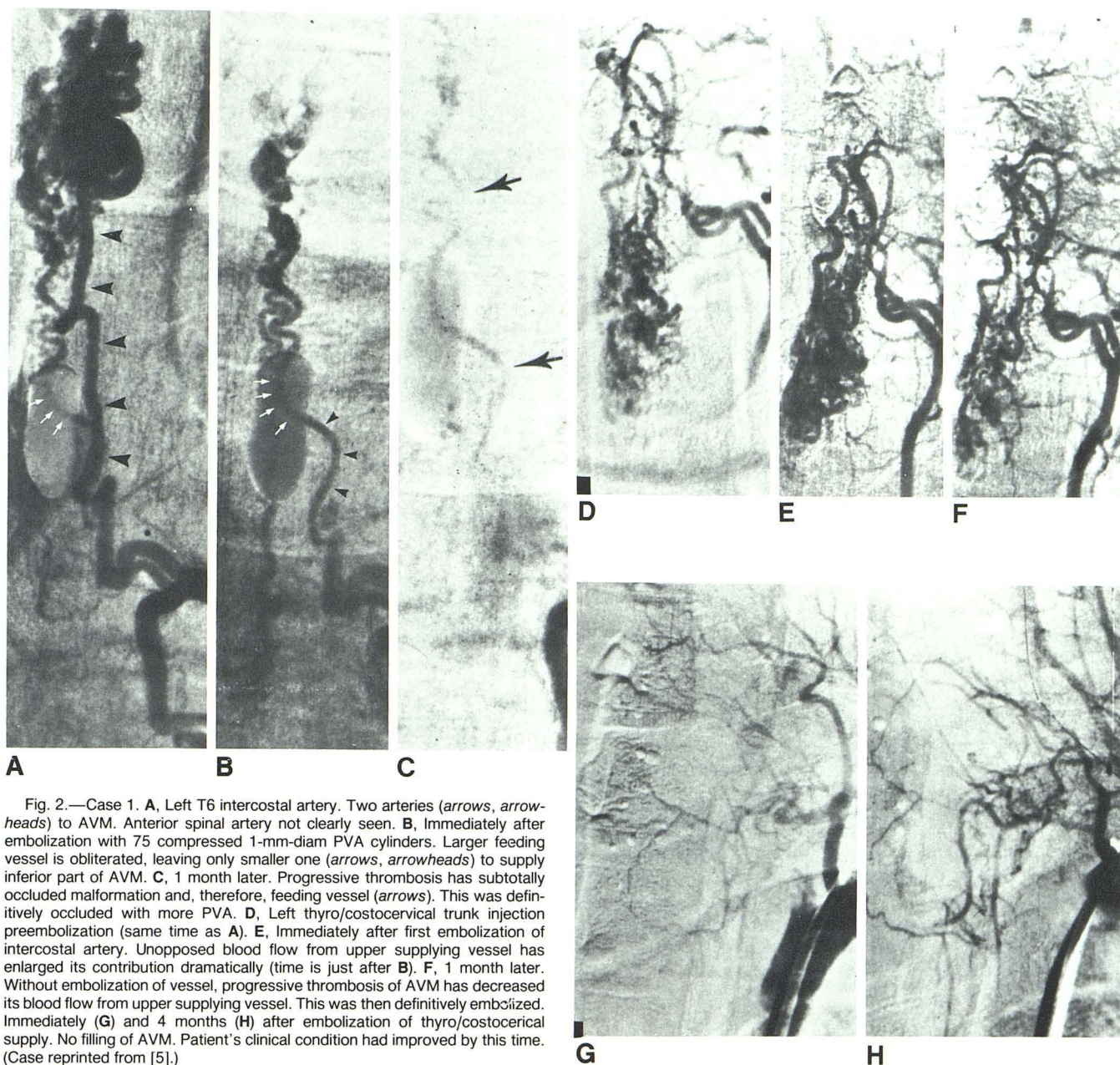


Fig. 2.—Case 1. **A**, Left T6 intercostal artery. Two arteries (arrows, arrowheads) to AVM. Anterior spinal artery not clearly seen. **B**, Immediately after embolization with 75 compressed 1-mm-diam PVA cylinders. Larger feeding vessel is obliterated, leaving only smaller one (arrows, arrowheads) to supply inferior part of AVM. **C**, 1 month later. Progressive thrombosis has subtotally occluded malformation and, therefore, feeding vessel (arrows). This was definitively occluded with more PVA. **D**, Left thyrocervical trunk injection preembolization (same time as **A**). **E**, Immediately after first embolization of intercostal artery. Unopposed blood flow from upper supplying vessel has enlarged its contribution dramatically (time is just after **B**). **F**, 1 month later. Without embolization of vessel, progressive thrombosis of AVM has decreased its blood flow from upper supplying vessel. This was then definitively embolized. Immediately (**G**) and 4 months (**H**) after embolization of thyrocervical supply. No filling of AVM. Patient's clinical condition had improved by this time. (Case reprinted from [5].)

### Case 3

A 5½-year-old boy was in excellent health until 3 days before admission, when he felt a sudden sharp pain in the thoracolumbar region followed within minutes by severe bioccipital headache. The pain and headache lasted 4 hr and were partly alleviated by aspirin. He had a second catastrophic episode of back pain and headache 24 hr later that persisted and was accompanied by photophobia and neck stiffness. Examination showed severe nuchal rigidity, and on attempted passive neck flexion he assumed an opisthonoid posture. There was mild papilledema but no focal neurologic deficits. No cutaneous angioma or paravertebral bruit was detected.

Plain films of the entire spine showed an occult bifid S1 lamina and some scalloping of the posterior bodies of L2–L5 vertebrae. The first CT examination of the head was done without and with intravenous contrast material and showed symmetrically but mildly dilated ventri-

cles but not focal lesions. A second CT scan immediately after the second ictus showed blood within the fourth ventricle. Lumbar puncture yielded xanthochromic CSF with opening pressure of 250 mm H<sub>2</sub>O. Because of the higher likelihood of an intracranial bleeding source over a spinal source, four-vessel cerebral angiography was performed; no abnormality was seen.

The search for an intraspinal bleeding source began with metrizamide myelography, which showed multiple irregular filling defects that, corresponding to no normal anatomic structure, later proved most likely to represent clot. Spinal cord angiography under general anesthesia demonstrated an AVM with major components both ventral to and within the substance of the low thoracic cord. It was primarily fed by the left T10 (figs. 4A and 4E) and T11 (fig. 4F) intercostal arteries. The lower of these arose as a branch of the right intercostal artery at the same level.

We embolized these arteries with a mixture of PVA (1.0–2.0 mm)



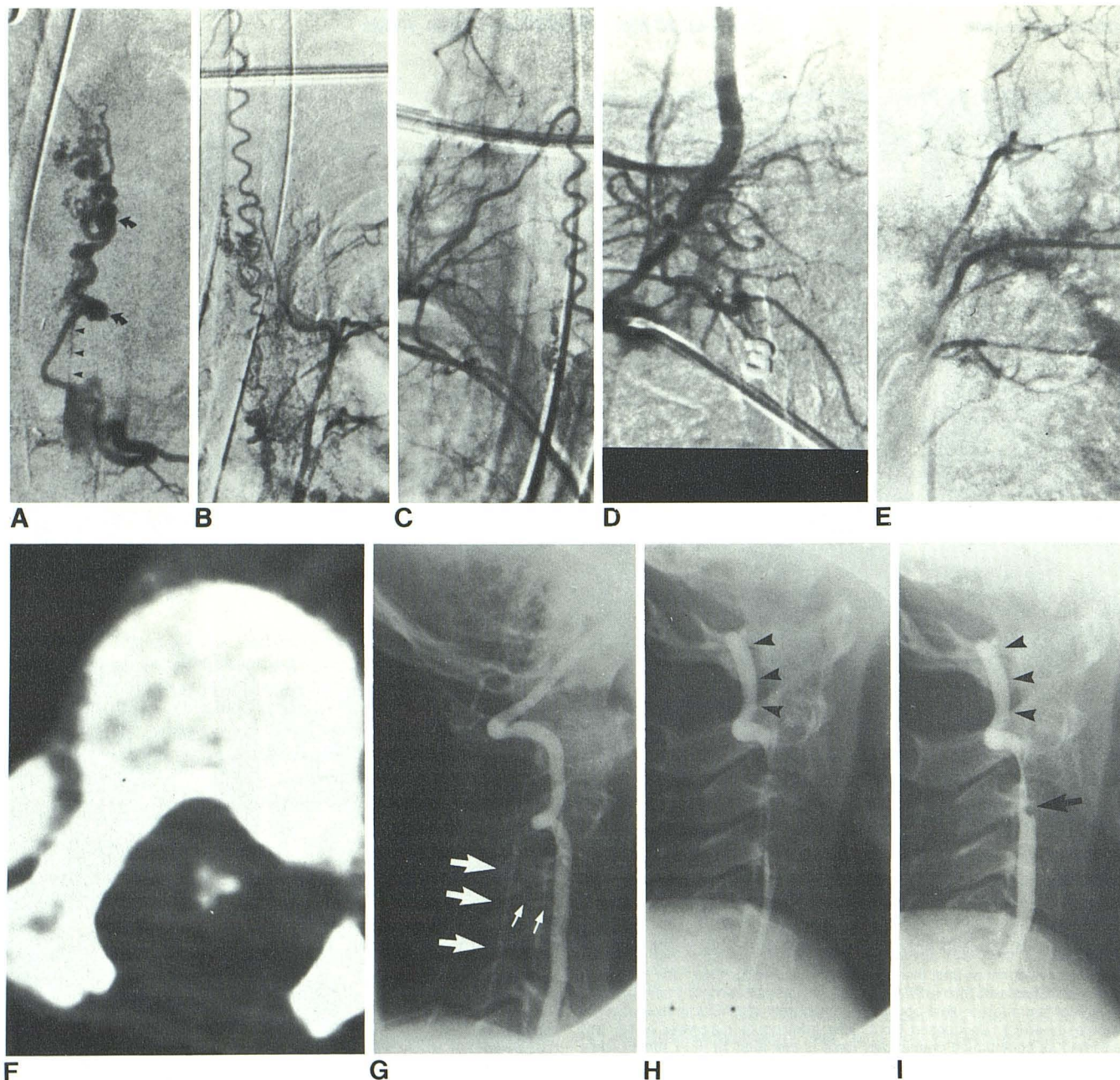


Fig. 3.—Case 2. **A**, Left T8 intercostal arteriogram about 1 year after surgery. Anterior spinal artery (*arrowheads*) arises from anterior part of AVM. Two aneurysmal segments (*arrows*) are present. **B**, Left supreme intercostal arterial injection shows communications with serpiginous radiculomedullary vessel, which arises from **C**, right thyro/costocervical artery. **D**, Right subclavian injection. Superior supplying vessel is no longer filled. **E**, Injection into left T8 intercostal artery (with reflux to higher ones). Supply to AVM is closed. **F**, Follow-up CT scan of spine through AVM 2 months after embolization. Barium-impregnated particles within cord confirm intramedullary location. **G**, Right vertebral arteriogram shows last identified artery supplying malformation (*small*

*arrows*). It is too small to catheterize selectively and its takeoff angle is unfavorable. Main intraspinal tributary (*large arrows*). **H**, After detachment of 1-mm B-D balloon (*arrowheads*) distal to origin of small feeder. Balloon is placed so that it is proximal to sharp curve in artery so that, in the event that distal migration should occur, the brain is protected, since the balloon, being elongated, cannot negotiate the curve. **I**, Final arteriogram after PVA-Gelfoam embolization of vertebral artery proximal to occluding balloon (*arrowheads*). Tributary no longer fills. Gelfoam particle (*arrow*) floats on cephalic end of contrast column.

and Gelfoam (1.5 mm cubes). The child recovered from anesthesia with no neurologic deficits. His headache and papilledema subsided, and repeat CT showed diminished size of the ventricular system.

Three months later, the patient underwent elective spinal angiography to exclude delayed or persistent vascularization of the malformation. This time, the lesion, although shrunken somewhat since the previous embolization, was filled by the right first and third lumbar arteries (fig. 4H). The former was occluded with microparticles of PVA foam sponge through a 5-French polyethylene catheter. By the time the L3 feeder was selectively catheterized, the limit of contrast material had been reached, and further embolization was postponed.

One week later, the remaining L3 feeder was similarly occluded, and no filling of the malformation was demonstrated on a high-volume abdominal aortogram. The child recovered from both procedures without neurologic deficits. He was still asymptomatic 1 year after the last procedure.

## Discussion

Spinal cord angiography carries some risk. Embolization of vessels known to supply the spinal cord should theoretically increase that risk. Our experience, as well as that of others,



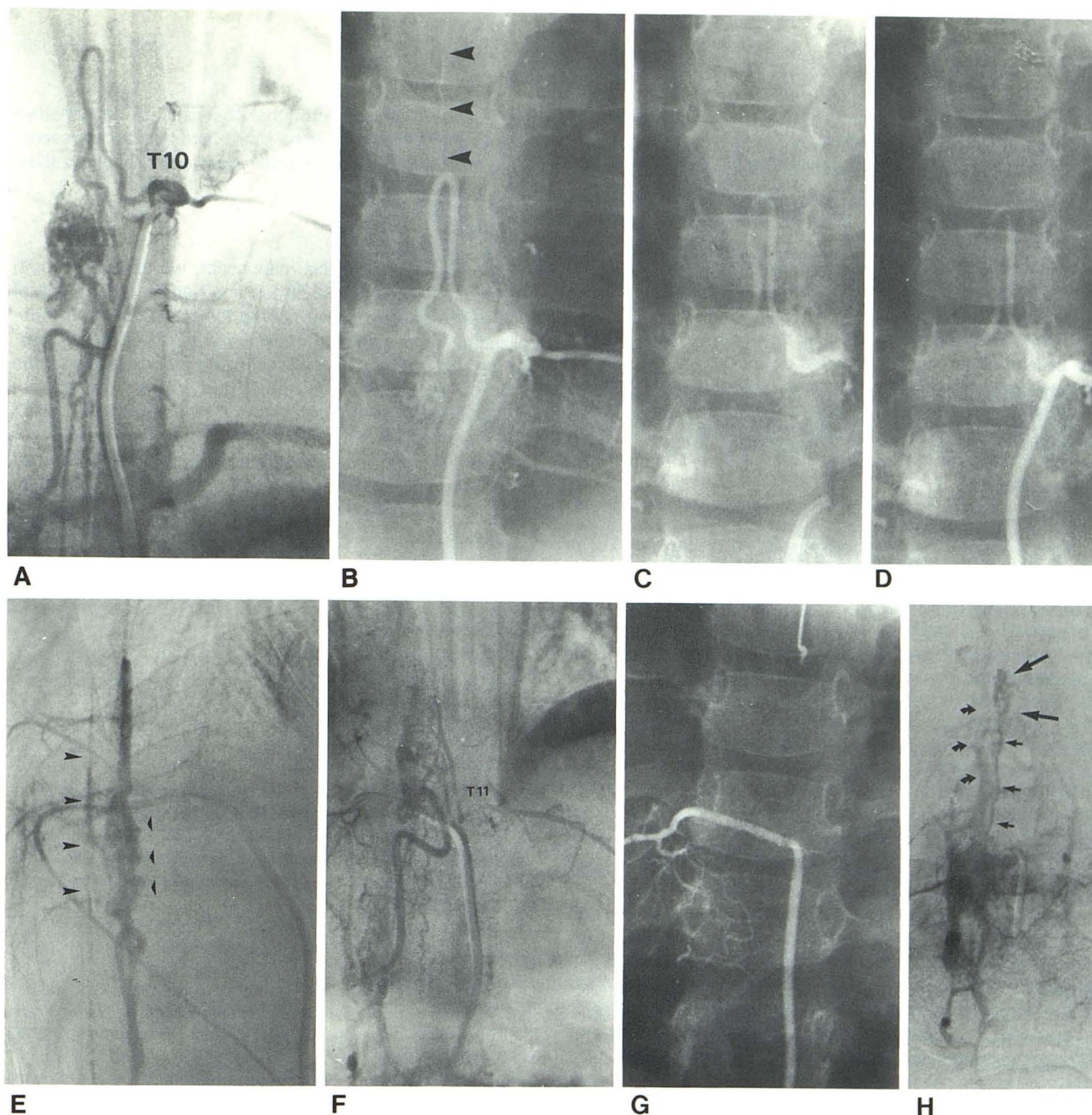


Fig. 4.—Case 3. **A**, Left T10 intercostal arteriogram opacifies hairpin-shaped artery supplying bulk of malformation. **B**, Anterior spinal artery arises from apex of loop (*arrowheads*). **C**, Immediately after deposition of embolic mixture. Cast of emboli and contrast material opacifies artery. **D**, Immediate follow-up angiogram fails to opacify malformation and confirms solidity of occlusion. Anterior spinal artery is not seen. Patient was neurologically intact before anesthesia for the procedure and awoke without deficit. Thus, anterior spinal artery must be filling via other collaterals. **E**, Lateral view of left T10 intercostal injection shows anterior location of malformation. Oversubtracted vertebral bodies (*small arrowheads*); dorsum of cord is highlighted by structure that is either posterior

spinal artery or enlarged vein (*large arrowheads*). **F**, Right T11 intercostal artery injection fills its left counterpart, which in turn fills AVM. **G**, After embolization. Neither left intercostal artery nor malformation is filled from right intercostal artery. **H**, Immediate preembolization injection of right third lumbar artery shows filling of markedly shrunken AVM (*large arrows*). Radiculomedullary feeder (*small arrows*) and epidural venous drains (*curved arrows*) are also opacified. Artery was immediately embolized with PVA and Gelfoam. Postembolization study of this vessel was not done since it was not large initially and it was embolized to its origin at aorta. Thus, injection at its origin was impossible. AVM was not seen on postembolization aortogram.

suggests that judicious spinal cord AVM embolization can be done safely. It is important, particularly if the AVM is supplied by the anterior spinal artery, to choose particles larger than the anterior spinal artery itself (fig. 1). This decreases considerably the likelihood of ischemia to the spinal cord and its attendant complications. Note that this principle precludes the use of liquid embolic agents (IBCA or silicone) as well as finely divided agents such as Gelfoam powder.

It is possible to eradicate intramedullary spinal cord AVMs with embolization [3]. The sole requirement for safety is usually met: the arteries supplying the AVM must be larger than the anterior spinal artery. Thus, embolization can theoretically be done safely if the size of the particles used exceeds the size of the anterior spinal artery itself and if radicles other than the one(s) feeding the AVM are able to provide adequate blood supply to the cord.



Constant monitoring of the patient's neurologic status is necessary. SSEPs have been advocated for this [6], but they only permit us to evaluate dorsal column function and not the status of the corticospinal tracts and anterior columns. Thus, embolization should, if at all possible, be done on an awake, alert patient who is challenged by perfusion of contrast material and/or proximal and reversible occlusion of the vessel(s) to be embolized, during constant monitoring of motor and sensory function.

There is probably no single test that will prove an artery can be embolized safely. Proximal occlusion with a balloon tells us what the result of proximal, that is, large-particle, embolization would likely be. We consider the parallel between large-particle and proximal embolization as a consequence of the fact that large particles cannot enter smaller distal vessels.

When we were unable to perform a proximal occlusion on two of the first three arteries embolized in case 2, we made use of the known neurotoxicity of contrast material [7-11] to test the left supreme intercostal artery and the right thyrocostocervical artery. While this can be clearly regarded as dangerous, so is embolization, but solid particles are permanent as far as spinal cord vascularity is concerned, while liquid agents may and usually do produce reversible effects. Thus these two tests, while possibly inadequate and not without risk, allowed us at least a logically supportable challenge to use before committing to permanent occlusion of arteries that might have placed the spinal cord in jeopardy.

PVA continues to cause clot to form and propagate after completion of the procedure [12-14]. Thus, it is unnecessary to achieve an immediate angiographic obliteration of the AVM; over time thrombosis will extend (case 1), and further embolization should always be considered an option.

Staging of embolization makes it safer to occlude arteries that, though small, still supply a malformation immediately after an embolization. After embolization of the principal artery(ies) to an AVM, such arteries meet either of two fates: either they close completely if they supply the vascular compartment that was embolized or they enlarge. If the former is the case, embolization of that artery is unnecessary; if it is the latter, then further treatment is easier and safer to do.

Much has been written about the artery of Adamkiewicz, particularly by interventional radiologists who embolize spinal cord vascular malformations. We have not mentioned it in this work. The reason for this omission is the fact that in some cases of cord AVM (cases 2 and 3 in this article and two other apparently dorsal AVM cases of ours not pertinent to the main topic of this article), the hairpin-curved radiculomedullary artery feeding the anterior spinal artery is not solitary.

We now consider the artery of Adamkiewicz to be a set of arteries that supply the ventrum of the spinal cord. While this set may have only one member, our experience shows this not always to be the case. Rather, we believe that several such arteries exist in normal patients, and that the extraordinary flow demands exerted by an AVM cause these small accessory arteries to dilate and, therefore, become visible to the angiographer.

All three patients in our admittedly short series benefited considerably from embolization of their intramedullary spinal

cord AVMs. It is our belief that the risks of conservative treatment and surgery may be similar and that each presents the patient with a greater risk than does careful embolization.

### Addendum

Since submission of this manuscript, we have used both Amytal and lidocaine (see Horton and Kerber in this issue of *AJNR* [14]) as provocative agents for spinal cord AVM embolization in two patients not reported here. As of this time, neither has produced a deficit, so the blood supply to the cord has been separate from that to the AVMs. We are not certain whether Amytal or lidocaine is the appropriate agent in this setting: Is the cord chemically more like brain or peripheral nerve? Lidocaine can theoretically cause cord seizures if the cord is more like brain, but would be unlikely to do so if it is more like peripheral nerve. Because of this uncertainty, we first challenge with Amytal; if no effect, we move to lidocaine.

### REFERENCES

1. Ommaya AK, Di Chiro G, Doppman J. Ligation of arterial supply in the treatment of spinal cord arteriovenous malformations. *J Neurosurg* 1969;30:670-692
2. Doppman JL, Di Chiro G, Ommaya AK. Percutaneous embolization spinal cord arteriovenous malformations. *J Neurosurg* 1971;34:48-55
3. Djindjian R, Merland JJ. Place de l'embolisation dans le traitement des malformations arterio-veineuses medullaires. A propos de 38 de cas. *Neuroradiology* 1978;16:428-429
4. Riché MC, Melki JP, Merland JJ. Embolization of spinal cord vascular malformations via the anterior spinal artery. *AJNR* 1983;4:378-381
5. Ausman JI, Gold GH, Tadavarthy SM, Amplatz K, Chou SN. Intraparenchymal embolization for obliteration of an intermedullary AVM of the spinal cord. *J Neurosurg* 1977;47:119-125
6. Berenstein A, Young W, Ransohoff J, Benjamin V, Merkin H. Somatosensory evoked potentials during spinal angiography and therapeutic transvascular embolization. *J Neurosurg* 1984;60:777-785
7. Jeppson PG, Olin T. Lesions of the blood-brain barrier following selective injection of contrast material into the vertebral artery in rabbits. *Acta Radiol [Diagn]* (Stockh) 1972;12:271-282
8. Epsen F. Spinal cord lesion as a complication of abdominal aortography. *Acta Radiol [Diagn]* (Stockh) 1966;4:47-61
9. Di Chiro G. Unintentional spinal cord angiography: a warning. *Radiology* 1974;112:231-233
10. Feigelson HH, Ravin HA. Transverse myelitis following selective bronchial arteriography. *Radiology* 1965;85:663-665
11. Kardjiev V, Semyonov A, Chankov T. Etiology, pathogenesis and prevention of spinal cord lesions in selective angiography of the bronchial and intercostal arteries. *Radiology* 1974;112:81-83
12. Horton JA, Marano GD, Kerber CW, Jenkins JJ, Davis S. Polyvinyl alcohol foam-Gelfoam for therapeutic embolization: a synergistic mixture. *AJNR* 1983;4:143-147
13. Latchaw RE, Gold LHA. Polyvinyl foam embolization of vascular and neoplastic lesions of the head, neck, and spine. *Radiology* 1979;131:669-679
14. Horton JA, Kerber CW. Lidocaine injection into extracranial carotid branches: provocative test to preserve cranial nerve function in therapeutic embolization. *AJNR* 1986;7:105-108