



Choroid plexus papilloma: detection by real-time and Doppler sonography.

P P Chow, J G Horgan, P N Burns, G Weltin and K J Taylor

AJNR Am J Neuroradiol 1986, 7 (1) 168-170

<http://www.ajnr.org/content/7/1/168.citation>

This information is current as
of July 1, 2025.

Choroid Plexus Papilloma: Detection by Real-Time and Doppler Sonography

Peter P. Chow^{1,2} J. Gerard Horgan^{1,3} Peter N. Burns¹ Gregory Weltin¹ Kenneth J. W. Taylor¹

Brain tumors arising in the neonatal period are rare and diagnosis is usually delayed. We encountered a case of choroid plexus papilloma (CPP) in a term newborn infant. The sonographic findings of this case demonstrated a striking similarity to intraventricular hemorrhage, an entity commonly seen in premature infants. A preoperative diagnosis was made, however, with the application of the pulsed Doppler technique showing markedly increased vascularity of this tumor. A search of the literature revealed only two reported cases of CPP demonstrated by sonography. The sonographic features of this rare tumor are reviewed. The potential role of Doppler sonography in the differential diagnosis of an intracranial mass is discussed.

Case Report

A 2820 g male infant was born at 36 weeks of gestation by spontaneous vaginal delivery. Fetal hydrocephalus was demonstrated during a prenatal sonographic examination at 34 weeks of gestation. At birth his head circumference was increased and the anterior fontanelle was tense. There were no neurologic or general physical

abnormalities. Real-time sonograms demonstrated marked hydrocephalus in the lateral ventricles and a lobulated mass in the third ventricle extending into the frontal horn of the lateral ventricle (fig. 1). A Doppler flow study was performed using a Mk600/5MHz duplex scanner (ATL Inc., Bellevue, WA) (fig. 2). Cranial CT (fig. 3) demonstrated an isodense mass showing uniform and marked enhancement after intravenous administration of contrast material. Preoperative internal carotid and vertebral angiograms revealed hypertrophy of the medial posterior choroidal artery and tumor stain in the capillary and venous phases. After 3 weeks of ventriculoperitoneal drainage, a frontoparietal craniotomy with transcallosal excision of the tumor was performed. Unfortunately, the patient developed hypotension and bradycardia followed by cardiac arrest soon after the removal of the tumor. Autopsy was performed, and histologic examination revealed a typical benign CPP arising from the third ventricle and extruding into the right lateral ventricle.

Discussion

CPP is a rare epithelial tumor of the central nervous system and may arise wherever choroid plexus occurs within the cranial cavity. It accounts for 3%–5% of brain tumors in

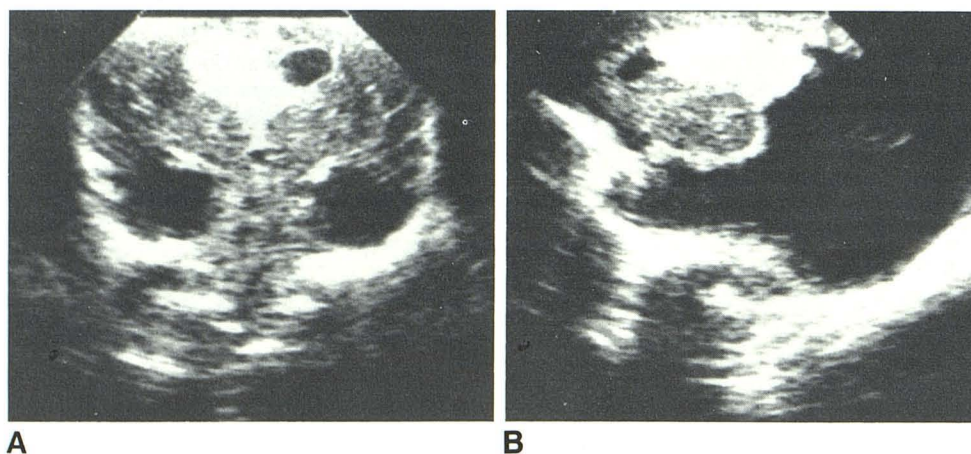


Fig. 1.—Coronal (A) and sagittal (B) sonograms at birth. Uniformly echogenic mass in third ventricle extending into frontal horn of right lateral ventricle. Marked hydrocephalus in lateral ventricle.

Received July 18, 1984; accepted after revision September 20, 1984.

¹Department of Diagnostic Imaging, Yale University School of Medicine, New Haven, CT 06510. Address reprint requests to K. J. W. Taylor.

²Present address: Department of Diagnostic Radiology, State University of New York at Stony Brook, Stony Brook, NY 11790.

³Present address: Department of Radiology, Meath Hospital, Dublin 8, Ireland.

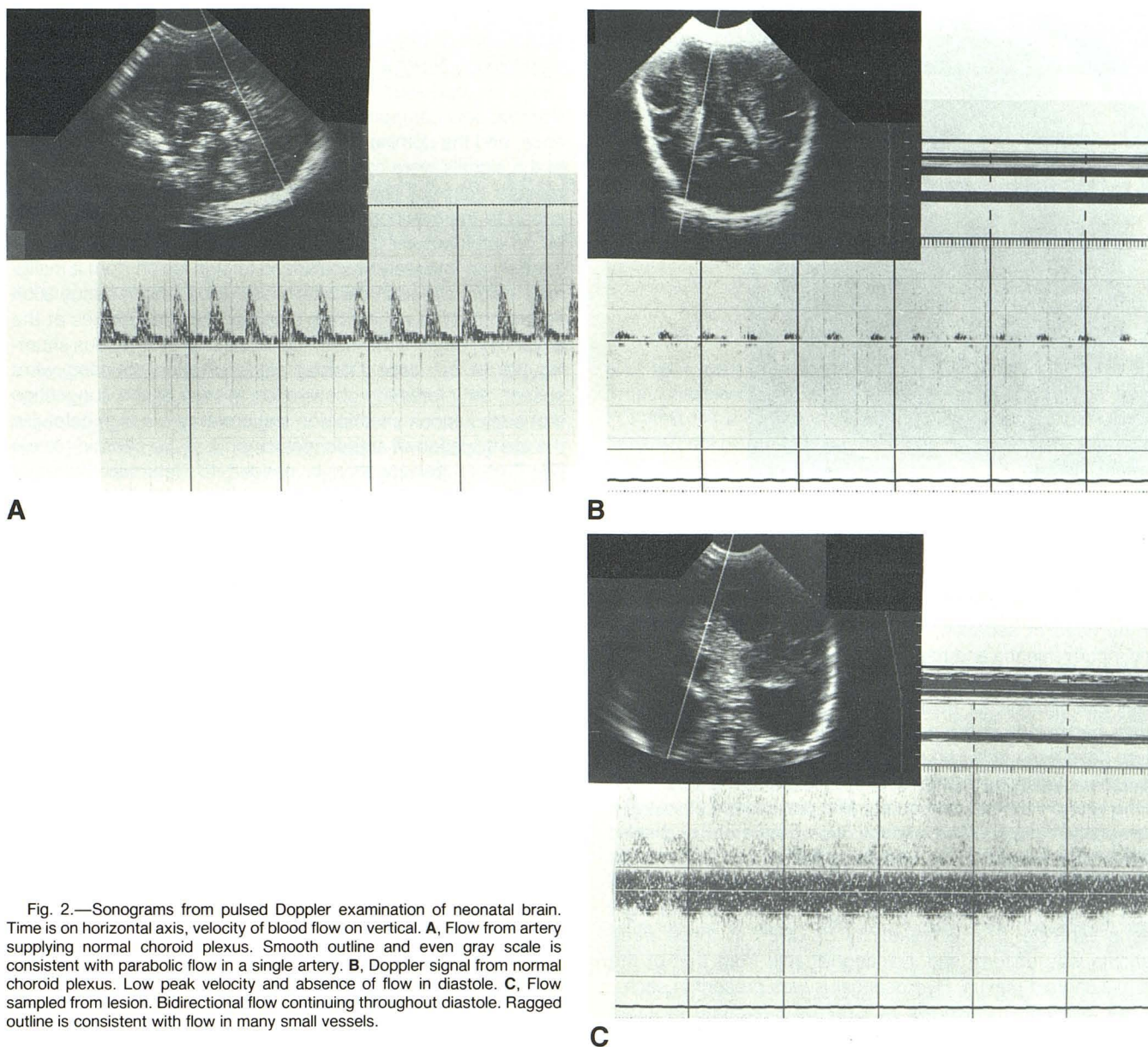


Fig. 2.—Sonograms from pulsed Doppler examination of neonatal brain. Time is on horizontal axis, velocity of blood flow on vertical. **A**, Flow from artery supplying normal choroid plexus. Smooth outline and even gray scale is consistent with parabolic flow in a single artery. **B**, Doppler signal from normal choroid plexus. Low peak velocity and absence of flow in diastole. **C**, Flow sampled from lesion. Bidirectional flow continuing throughout diastole. Ragged outline is consistent with flow in many small vessels.

children [1–3]. The tumor is seen most often during the first decade of life, particularly in infancy. A number of cases have been reported in the neonatal period [4] and have been considered congenital in origin [5].

Histologically, CPP resembles the normal choroid plexus very closely. There are papillary projections outlined by columnar epithelium bearing central thin-walled vascular channels surrounded by scanty connective tissue. This pattern is distinguished from normal plexus in that the epithelium of the latter is more cuboid and is usually aligned less compactly [6]. A malignant form, adenocarcinoma, is rare, but may occur with invasion of adjacent neural structures.

The clinical diagnosis of CPP is difficult because of the nonspecific nature of the symptoms and signs. Hydrocephalus

is the most common clinical presentation. It is from obstruction of the CSF pathways and/or overproduction of CSF by the papilloma. If surgical removal can be carried out before irreversible brain damage develops secondary to severe hydrocephalus or spontaneous hemorrhage, a favorable outcome can be expected. Therefore, it is of paramount importance that the presence of CPPs be recognized early.

CT now constitutes the primary imaging technique for the diagnosis of CPP [4]. Benign CPP is seen as a lobulated, intraventricular mass without invasion of the brain parenchyma. It enhances markedly and uniformly after injection of iodinated contrast medium. The differentiation between benign and malignant CPP is also possible by CT. The use of CT is, however, somewhat limited in newborn infants because

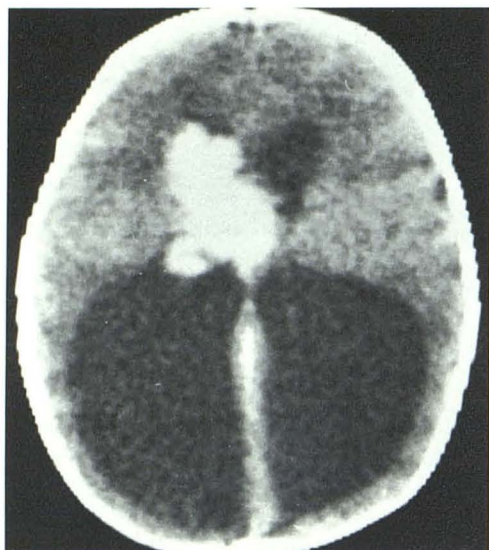

Fig. 3.—Preenhancement CT scan. Isodense lobulated intraventricular mass. After intravenous injection of contrast material, mass enhanced markedly and uniformly.

of the need of sedation, undesirability of ionizing radiation, and inconvenience and risks of patient transportation.

Recently, real-time sonography has gained popularity as an initial examination for neurologic abnormality in newborn infants, particularly in the neonatal period. To our knowledge, there have been only two previously reported cases of CPPs demonstrated by sonography. One case showed a focal mass in the lateral ventricle contiguous with the choroid plexus [7]; the second case showed bilateral hypertrophy of the choroid plexus that proved to be bilateral papilloma of the choroid plexus [8]. Our case demonstrated a lobulated mass in the third ventricle extending into the frontal horn of the right lateral ventricle. The echogenicity of CPPs in these three patients was uniform and indistinguishable from that of the normal choroid plexus. Hydrocephalus was present in each.

The differential diagnosis of CPP in a neonate includes intraventricular hemorrhage and other intraventricular masses such as ependymoma, colloid cyst, and meningioma. Follow-up sonograms may show evolution of intracranial hemorrhage. The echogenicity of CPP, uniform and similar to the normal choroid plexus, may help differentiate it from other intraventricular tumors.

To obtain a more specific diagnosis, we studied blood flow

signals from the lesion using pulsed Doppler. These Doppler signals showed several features suggestive of a neovascularized lesion. The high amplitude of the Doppler signals indicated an increased vascular density, the large continuous diastolic flow component resulted from a low vascular impedance, and the dominant low velocity shifts and bidirectionality of the signals were consistent with flow in a chaotic arrangement of vessels. These findings have been shown to correspond to the flow conditions that accompany tumor vascularity on angiography [9]. It remains difficult to distinguish accurately an intensely vascularized benign lesion from a malignant lesion, although the latter has been found in tissue such as the breast to exhibit high Doppler shift frequencies at the advancing edge of the lesion because of arteriovenous shunting [9]. In our case Doppler signs of such shunting were absent, an interesting observation in view of the suggestion that early venous shunting on angiography is a sign helpful in the identification of an adenocarcinoma of the choroid plexus [2]. Further investigation is needed to determine whether other hypervascular intracranial tumors exhibit these neovascular Doppler signals.

ACKNOWLEDGMENT

We thank Leon Kier for figure 3.

REFERENCES

1. Matson DD, Crofton FDL. Papilloma of the choroid plexus in childhood. *J Neurosurg* 1960;17:1002-1027
2. Thompson JR, Harwood-Nash DC, Fitz CR. The neuroradiology of childhood choroid plexus neoplasms. *AJR* 1973;118:116-133
3. Rovit RL, Schechter MM, Chodrott P. Choroid plexus papilloma: observation of radiographic diagnosis. *AJR* 1970;110:608-617
4. Pascual-Castroviejo I, Villarejo F, Perez-Higueras A, et al. Childhood choroid plexus neoplasms. *Pediatrics* 1983;140:51-56
5. Raskind R, Beigel F. Brain tumors in early infancy—probably congenital in origin. *Pediatrics* 1964;65:727-732
6. Carter LP, Beggs J, Waggener JD. Ultrastructure of three choroid plexus papillomas. *Cancer* 1972;30:1130-1136
7. Shkolnik A, Tomita T, Raimondi AJ, Hahn YS, McLone DG. Work in progress. Intraoperative neurosurgical ultrasound: localization of brain tumors in infants and children. *Radiology* 1983;148:525-527
8. Welch K, Strand R, Bresnan M, Cavazzuti V. Congenital hydrocephalus due to villous hypertrophy of the telencephalic choroid plexuses. *J Neurosurg* 1983;59:172-175
9. Burns PN, Halliwell M, Wells PNT. Ultrasonic Doppler studies of the breast. *Ultrasound Med Biol* 1982;8:127-143