



**Providing Choice & Value**  
Generic CT and MRI Contrast Agents

**FRESENIUS  
KABI**

**CONTACT REP**

**AJNR**

**Traumatic pneumocephalus caused by stab wound to the neck.**

M Naseem, J D Hood and R Devasthali

*AJNR Am J Neuroradiol* 1986, 7 (1) 174-175

<http://www.ajnr.org/content/7/1/174.citation>

This information is current as  
of July 9, 2025.

## Traumatic Pneumocephalus Caused by Stab Wound to the Neck

Mohammad Naseem,<sup>1</sup> James D. Hood, and Ramakrishna Devasthali

An extensive review of the literature showed that trauma is the most common cause of pneumocephalus. Most often the trauma involves the frontoethmoidal or other air sinuses. Three types of injuries are frequently described to be responsible for pneumocephalus: (1) automobile accidents, (2) motorcycle accidents, and (3) missile injuries. A thorough review of the literature revealed that there is no known case report of pneumocephalus secondary to stab-wound injury to the neck. We describe a case in which the patient was a victim of multiple stab wounds to the chest and back, and one stab wound to the back of the neck was responsible for pneumocephalus.

### Case Report

A 24-year-old right-handed man was admitted to the Cook County Hospital trauma unit because of multiple stab wounds to the chest and back and one stab wound to the back of the neck. He denied shortness of breath, headache, stiff neck, or visual or auditory difficulty.

On physical examination, vital signs were stable, and the patient

was alert and oriented. There was no evidence of head trauma, and the neurologic examination was normal. A 2 cm transverse deep laceration was noted 3 cm inferior to and 2 cm to the right of theinion. The laceration was draining glucose-positive clear fluid. Several small lacerations were found at the T10 level in the right midscapular line and at T6 level in the midaxillary line under the left nipple. During hospitalization, the patient developed a left hemothorax that responded to chest tube insertion.

The plain films of the cervical spine (fig. 1A) and skull (fig. 1B) revealed the soft-tissue laceration in the neck and air in the lateral ventricles. Aortic arch and vertebral (fig. 1C) angiograms were obtained to rule out arterial injury. No arterial injury was demonstrated on the arteriograms.

### Discussion

There have been reports of pneumocephalus since 1884 when Chiari [1] reported a case discovered at autopsy in a patient who had a history of chronic inflammation of ethmoid cells. With the advent of radiography, Luckett [2] was the first to report the appearance of air in the ventricles in a patient with a skull fracture involving the right frontal sinus. In 1930,

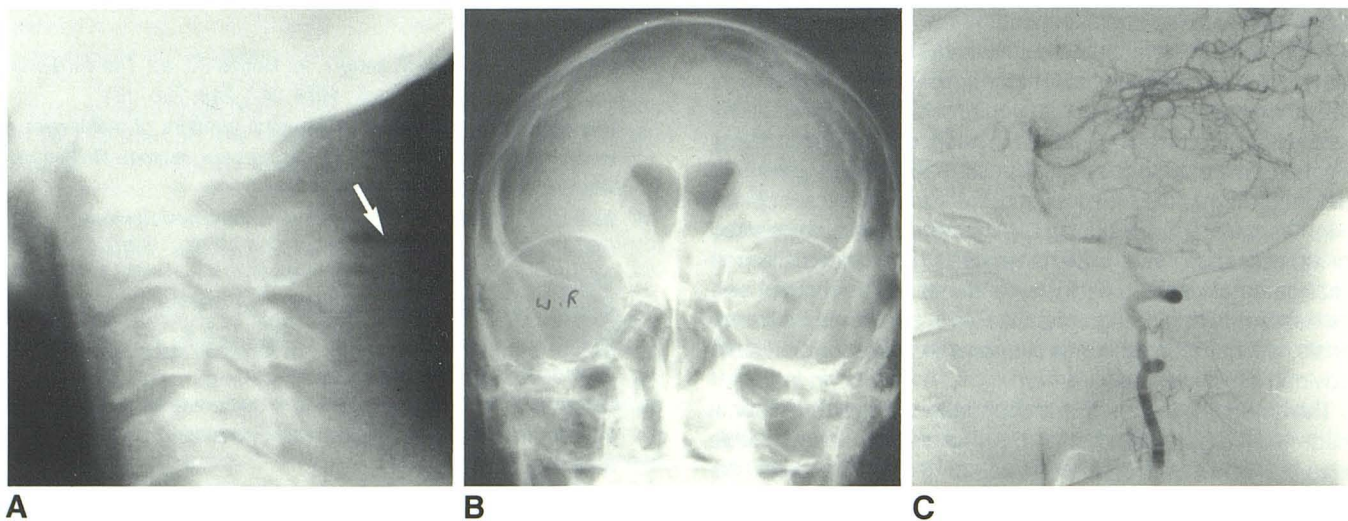


Fig. 1.—A, Lateral view of cervical spine. Site of laceration (arrow). Air-fluid level in soft tissues. B, Frontal view of skull. Air outlines lateral ventricles. C, Lateral view during right vertebral artery angiogram. No arterial injury.

Received August 15, 1984; accepted after revision January 16, 1984.

<sup>1</sup>Department of Radiology, Cook County Hospital, 1835 W. Harrison St., Chicago, IL 60612. Address reprint requests to M. Naseem.

Rand [3] reported eight cases of pneumocephalus. Between 1884 and 1967, other cases not included in a review by Markham [4] include one reported by Jacobs and Persky [5], two reported by Jones [6], and one by D'Addario et al. [7].

In a 1967 review of the literature, Markham [4] listed the various causes: trauma (fractures of the skull involving either the sinuses or base), 73.9%; neoplasm, 12.9%; infection, 8.8%; surgical intervention, 3.7%; and idiopathic, 0.6%. There are two major theories as to how pneumocephalus develops. The first proposes that air is forced into the intracranial cavity by a rapid increase in the intrasinus pressure that occurs with coughing, sneezing, Valsalva, or nose blowing. When the pressure wave subsides, the brain covers the defect through which the air entered. Such repeated episodes of air entry without simultaneous loss of cerebrospinal fluid may lead to elevated intracranial pressure. The second theory involves a cerebrospinal fluid leak that causes the intracranial pressure to drop and is compensated by an influx of air. Our case can be explained on the basis of the second theory. The stab wound to the back of the neck was deep enough to enter the subarachnoid space of the upper cervical region and was followed by cerebrospinal fluid leak. This resulted in a drop of the intracranial pressure and was compensated by an influx of air.

There appears to be no case in the literature identical to

the one reported here. In the absence of skull fracture and with a history of clear fluid draining from the neck wound, it is obvious that laceration of meninges provided a means of entrance for the air. Most likely the dural laceration had sealed itself off since the drainage had stopped by the time of admission.

#### REFERENCES

1. Chiari H. Ueber einen Fall von Luftansammlung in den Ventrikeln des menschlichen Gehirns. *Zachr Heilk* **1884**;5:383-390
2. Luckett WH. Air in the ventricles of the brain following a fracture of the skull. Report of a case. *Surg Gynecol Obstet* **1913**;17:237-240
3. Rand CW. Traumatic pneumocephalus. Report of eight cases. *Arch Surg* **1930**;20:935-958
4. Markham JW. The clinical features of pneumocephalus based upon a survey of 284 cases with a report of 11 additional cases. *Acta Neurochir (Wien)* **1967**;16:1-78
5. Jacobs JR, Persky MS. Traumatic pneumocephalus. *Laryngoscope* **1980**;90:515-521
6. Jones HM. Cranial pneumatocele. *Proc R Soc Med* **1970**;63:257-262
7. D'Addario R, Greenberg J, O'Neill TJE, Spagna P. Pneumocephalus: an unusual cause. *J Neurol Neurosurg Psychiatry* **1974**;37:271-274