



## Discover Generics

Cost-Effective CT & MRI Contrast Agents



FRESENIUS  
KABI

WATCH VIDEO

# AJNR

## CT recognition of anomalies of the posterior arch of the atlas vertebra: differentiation from fracture.

H L Dorne and P H Lander

*AJNR Am J Neuroradiol* 1986, 7 (1) 176-177

<http://www.ajnr.org/content/7/1/176.citation>

This information is current as of June 30, 2025.

## CT Recognition of Anomalies of the Posterior Arch of the Atlas Vertebra: Differentiation from Fracture

Howard L. Dorne,<sup>1,2</sup> N. Just,<sup>1</sup> and P. H. Lander<sup>1</sup>

Congenital anomalies of the first cervical vertebra are uncommon [1, 2]. Atlas malformations simulating Jefferson fractures have been reported [3, 4]. We report a patient who had an atlas malformation that simulated a fracture of the posterior arch of C1 on plain films. The diagnosis of a congenital anomaly was confirmed with computed tomography (CT).

### Case Report

A 24-year-old male firefighter fell while carrying a victim away from a fire. He complained of neck pain. In the emergency room a lateral cervical spine film (fig. 1A) showed a large ossific fragment slightly posterior and inferior to the posterior arch of the atlas. There was also interruption of one of the posterior hemiarches. The differential diagnosis was a posterior arch fracture, a malformation of the atlas,

or an atlas malformation with traumatic angulation of a hypoplastic lamina. Because of the uncertainty, CT was performed (figs. 1B and 1C). It demonstrated total hemiaptasia of the right posterior arch, partial hemiaptasia of the left posterior arch, and a midline cleft of the anterior arch. There were no soft-tissue abnormalities, and the posterior ossific fragment had a smooth, intact cortical margin. On the basis of these findings, the diagnosis of an atlas anomaly was made. Acute traumatic displacement of the hypoplastic lamina was excluded by the lack of soft-tissue changes.

### Discussion

The normal atlas vertebra can be divided into three parts; the anterior arch, the lateral masses, and the posterior arch. It differs from the other vertebrae in that it lacks a spinous process and a body [5, 6].

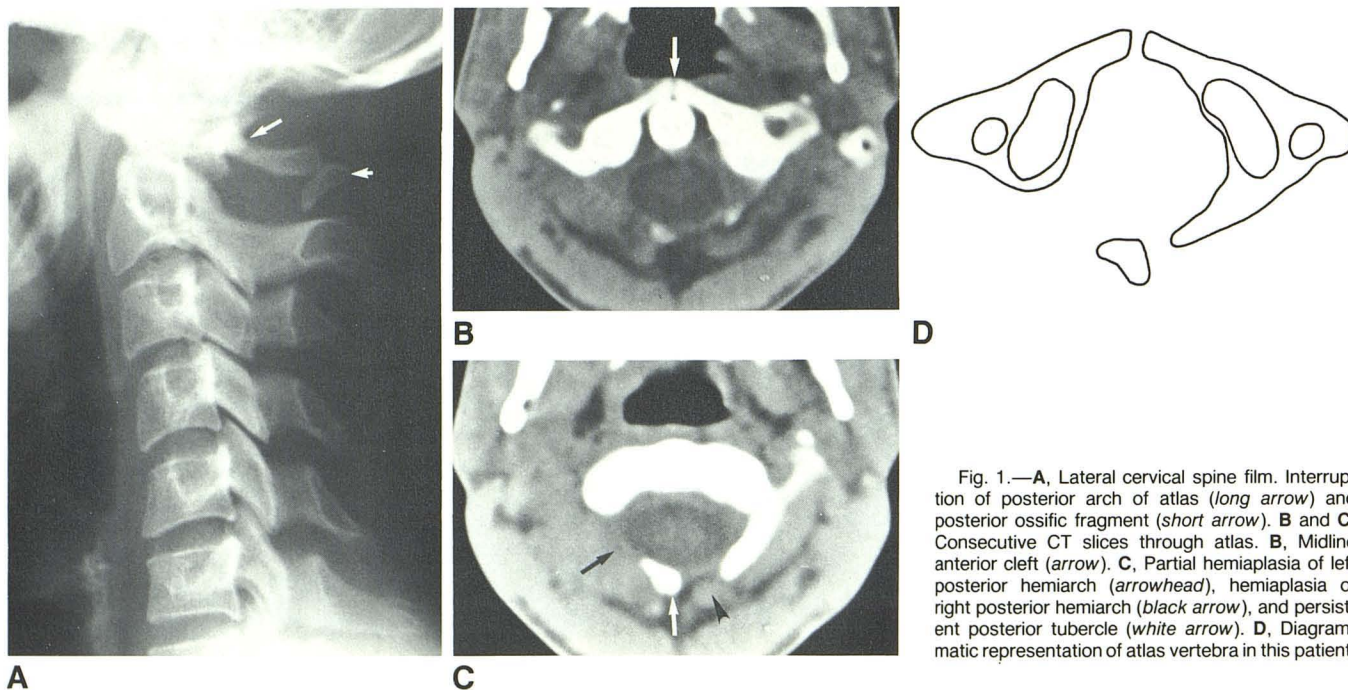


Fig. 1.—A, Lateral cervical spine film. Interruption of posterior arch of atlas (*long arrow*) and posterior ossific fragment (*short arrow*). B and C, Consecutive CT slices through atlas. B, Midline anterior cleft (*arrow*). C, Partial hemiaptasia of left posterior hemiarch (*arrowhead*), hemiaptasia of right posterior hemiarch (*black arrow*), and persistent posterior tubercle (*white arrow*). D, Diagrammatic representation of atlas vertebra in this patient.

Received August 15, 1984; accepted after revision November 26, 1984.

<sup>1</sup>Department of Diagnostic Radiology, Sir Mortimer B. Davis Jewish General Hospital and McGill University, 3755 Cote. St. Catherine Rd., Montreal, Quebec H3T 1E2, Canada. Address reprint requests to P. H. Lander.

<sup>2</sup>Present address: Department of Radiology, University of Michigan Medical Center, Ann Arbor, MI 48109.

Ossification of the atlas begins from the lateral masses and extends dorsally during the second intrauterine month. At birth, there remains a several-millimeter cartilaginous cleft between the bony posterior hemiarches. During the second year of life a separate ossification center develops in the cartilaginous cleft. Normally the posterior arch is completely ossified by the fourth year. The anterior arch ossifies from either one or two ossification centers that form within it or by ventral extension of the lateral masses without a separate ossification center. Ossification is complete by age 10 [1, 3].

Malformations of the atlas include both clefts and aplasias. Clefts and aplasias of the anterior arch are very rare. Geipel [2] found a cleft of the anterior arch of the atlas in only 0.1% of 1613 adult specimens examined. Clefts of the posterior arch occurred in 2%–4% of the specimens studied. They were in the midline in 97%. Aplasias of the posterior arch are unusual. They may be partial or complete. The latter is extremely rare [2]. Partial posterior aplasias may take the form of aplasia with persistent posterior tubercle, aplasia with unilateral or bilateral remnant with midline rachischisis, hemi-aplasia, or partial hemi-aplasia [3]. The combination of findings in our case—anterior cleft, posterior right hemi-aplasia, posterior left partial hemi-aplasia, and a persistent posterior tubercle—is quite rare (fig. 1D).

Pseudofractures of the atlas often can be suspected on the routine radiograph. Typically, developmental cleft margins are smooth with an intact cortical edge and no soft-tissue swell-

ing. Conversely, fractures have jagged edges or are comminuted and generally are associated with soft-tissue swelling [5, 6]. Displacement of the lateral masses is seen with axial compression fractures.

After trauma, if the initial plain film examination of the cervical spine does not clearly distinguish a fracture of the atlas from a congenital anomaly, CT should be performed. In most circumstances, the CT study will resolve any uncertainty. By virtue of its axial orientation and ability to define cortical edges and soft-tissue abnormalities, CT is the definitive study for differentiating atlas fractures from atlas malformations.

#### REFERENCES

1. Von Torklus D, Gehle W. *The upper cervical spine*. New York: Grune & Stratton, 1972
2. Geipel P. Zur Kenntnis der Spaltbildungen des Atlas und Epitropheus. *Zentralbl Allg Pathol* 1955;94:19–84
3. Gehweiler JA, Daffner RH, Roberts L. Malformations of the atlas vertebra simulating the Jefferson fracture. *AJR* 1983;140:1083–1086
4. Suss RA, Zimmerman RD, Leeds NE. Pseudospread of the atlas: false sign of Jefferson fracture in young children. *AJR* 1983;140:1079–1082
5. Gehweiler J, Duff D, Martinez S, Miller M, Clark W. Fractures of the atlas vertebra. *Skeletal Radiol* 1976;1:97–102
6. Gehweiler J, Osborne R, Becker R. *The radiology of vertebral trauma*. Philadelphia: Saunders, 1980