



Providing Choice & Value

Generic CT and MRI Contrast Agents



FRESENIUS
KABI

CONTACT REP

AJNR

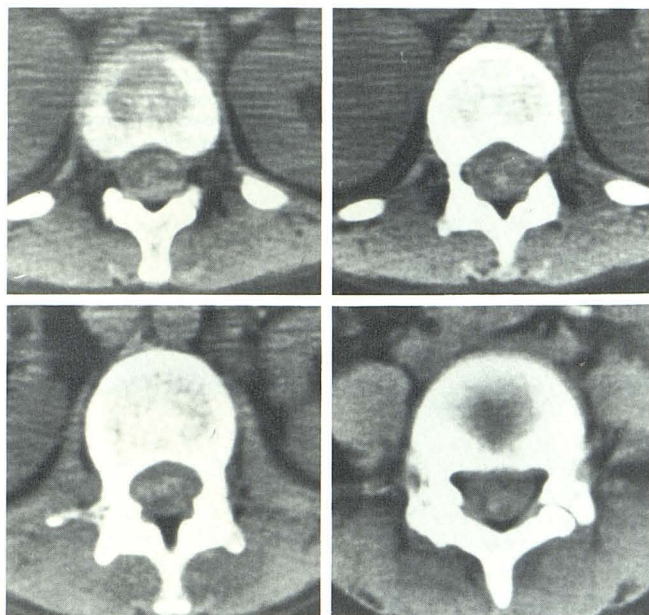
Transient global amnesia: complication of arterial DSA.

R E Reichter, T G Belt and J Stevens

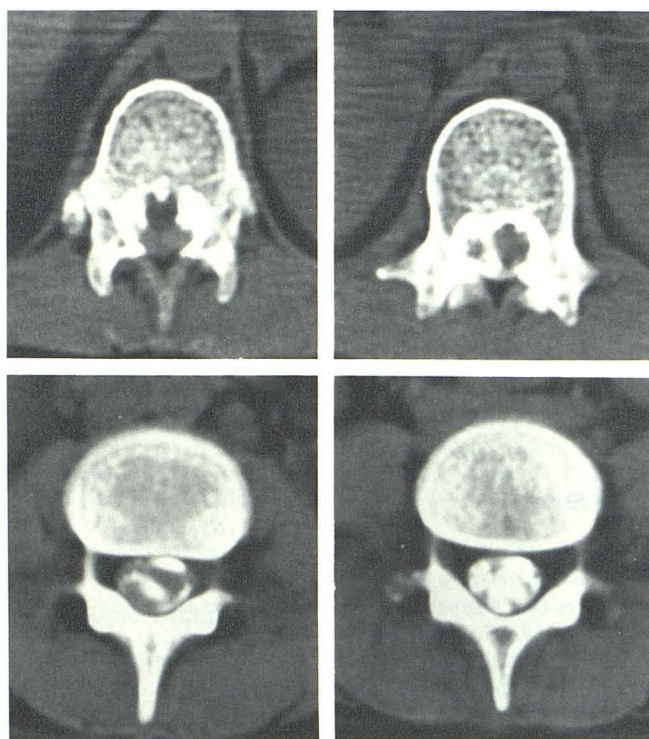
AJNR Am J Neuroradiol 1986, 7 (1) 179-180

<http://www.ajnr.org/content/7/1/179.citation>

This information is current as
of July 4, 2025.



A



B

Fig. 1.—A, CT of lower thoracic and upper lumbar spine. Patchy areas of increased density in dural sac represent blood clots. B, CT metrizamide myelogram. Multiple filling defects and linear lucencies represent blood clots.

bleeding at the site of the puncture was prolonged, and laboratory tests showed thrombocytopenia. Repeat CT of the spine 8 days later failed to demonstrate previously noted increased densities of the hematoma. We suggest that the subarachnoid hematoma was caused by repeated spinal tap, abnormal coagulation, and possible engorged spinal vessels from a reactive process secondary to men-

ingitis. C1–C2 puncture for myelography was avoided in this patient to prevent possible hematoma in the high cervical region and its grave consequences. Spinal CT is an essential study in cases with rapid progression of neurologic symptoms after traumatic spinal tap to rule out subarachnoid hematoma.

Behrooz Azar-Kia
 Mohammad H. Naheedy
 Michael Fine
 Loyola University Medical Center
 Maywood, IL 60153

REFERENCES

1. Rengachary SS, Murphy D. Subarachnoid hematoma following lumbar puncture causing compression of the cauda equina. *J Neurosurg* 1974;41:252–254
2. King OJ Jr, Glas WW. Spinal subarachnoid hemorrhage following lumbar puncture. *Arch Surg* 1960;80:574–577
3. Masdeu JC, Breuer AC, Schoene WC. Spinal subarachnoid hematomas: clue to a source of bleeding in traumatic lumbar puncture. *Neurology* 1979;29:872–876
4. Frager D, Zimmerman RD, Wisoff HS, Leeds NE. Spinal subarachnoid hematoma. *AJNR* 1982;3:77–79

Transient Global Amnesia: Complication of Arterial DSA

Transient global amnesia (TGA) is a clinical syndrome described by Bender [1] and Fisher and Adams [2] that consists of a single episode of the inability to assimilate new information for a finite period of time while retaining remote memory. This phenomenon has been described with selective cerebral [3–6] and coronary [7] angiography. A review of the literature revealed no report of TGA in nonselective angiography. Our report describes TGA in a nonselective digital subtraction angiographic (DSA) study of the aortic arch and cerebral circulation.

A 59-year-old man was referred for "dizziness." A 4 French pigtail catheter (Mallinckrodt) was placed in the ascending aorta via a right brachial artery approach, and the patient received four injections of 20 ml/sec for 2 sec (40 ml/injection) of Conray 43 (Mallinckrodt). The patient received our standard injection series of 160 ml of contrast material. This large volume of contrast material insures excellent demonstration of the carotid bifurcations. At 202 mg I/ml, 160 ml of Conray 43 gives the patient only 2.3 g more iodine than 100 ml of Hypaque 50 (Winthrop-Breon).

After the catheter was removed from the brachial artery and while hemostasis was being secured, the patient became confused and mildly agitated, repeating the questions, "Where am I?" and "What am I here for?" Physical examination revealed a normal pulse and blood pressure. Neurologic examination revealed no abnormalities except for the failure to remember three objects at 3 min. The patient correctly remembered his name, address, and where he worked. The patient recovered fully within 3 hr and had no residual deficit 2 months later. DSA showed a 25% concentric stenosis caused by atherosclerotic plaque in the proximal right internal carotid artery (fig. 1A) and a diminutive vertebrobasilar system (fig. 1B) without atherosclerotic stenosis.

TGA is a syndrome defined by Mathew and Meyer [6] as the sudden onset of episodes of loss of memory for recent events and inability to recall recently learned information, associated with retrograde amnesia. During the amnesic event the patient is alert and retains most of his personal identity. However, the patient is confused and upset about the memory loss. Repetitive questioning after having been given the answer is common.

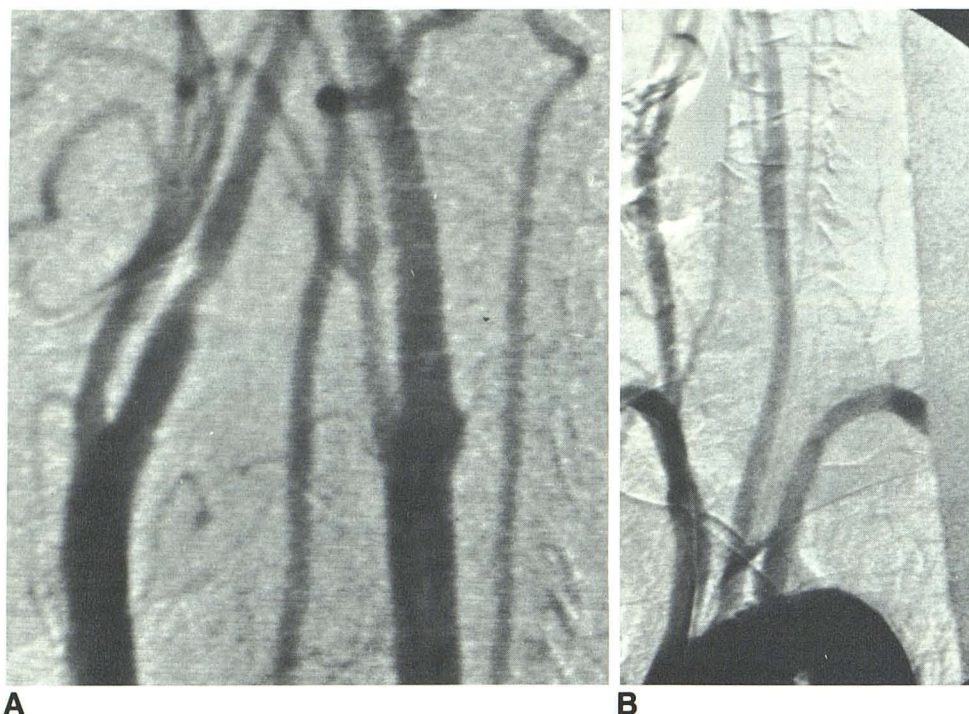


Fig. 1.—A, Intraarterial DSA of carotid bifurcations, right posterior oblique projection, shows 25% stenosis in proximal right internal carotid artery. B, Aortic arch injection, right posterior oblique projection. Diminutive caliber of vertebral arteries. Left vertebral artery originates from aortic arch.

The etiology of angiographically induced TGA has not been determined definitively. The prevailing theories suggest either an embolic event [7] or transient metabolic disturbance secondary to contrast medium [8] or ischemia [6] in the hippocampus of the temporal lobe, which is the center for recent memory function.

Our patient with a diminutive vertebrobasilar system lends credence to the metabolic or ischemic etiology. Because of the small size of the vertebral arteries, the preferential flow is in the carotid arteries, making embolization in the vertebral arteries much less likely. If the vertebral artery caliber approximates the internal carotid artery caliber, embolization to the vertebrobasilar system would be a more likely possibility.

The left vertebral artery originated from the aortic arch in our patient. This allowed more of the contrast material to be delivered into the vertebrobasilar system because of the high concentration of contrast material in the aortic arch. Again because of preferential flow, it would be less likely for an embolus to travel up the vertebral artery as compared with the carotid artery.

Our patient was referred for possible vertebrobasilar insufficiency. Pexman and Coates [4] suggest that there are areas in the hippocampus made susceptible to operator- or contrast-induced changes if there is vertebrobasilar disease. Since this patient had such small vertebral artery caliber bilaterally, he was more likely to be susceptible to transient contrast-induced metabolic changes or ischemia leading to TGA.

TGA is a rare but well defined disorder of acute memory loss. Possible etiologies have not been determined definitively. Because of the anatomic variability of the vertebrobasilar and carotid arteries, embolic, metabolic, or ischemic causes are viable considerations. Selective catheterization of the vertebral artery increases the likelihood of embolization as the cause. In patients with vertebrobasilar disease, nonselective catheterization such as intraarterial DSA may

increase the likelihood of TGA on the basis of metabolic or ischemic changes as suggested by our case.

Russell E. Reichter*

Thomas G. Belt

Department of Radiology

James Stevens

Department of Neurology

Indiana University School of Medicine

Indianapolis, IN 46223

* Present address: Duluth Clinic

Duluth, MN 55805

REFERENCES

1. Bender MB. Syndrome of isolated episode of confusion with amnesia. *J Hillside Hosp* 1956;5:212-215
2. Fisher CM, Adams RD. The transient global amnesic syndrome. *Acta Neurol Scand [Suppl]* 1964;40:7-82
3. Cochran JW, Morrell F, Huckman MS, Cochran EJ. Transient global amnesia after cerebral angiography. *Arch Neurol* 1982;39:593-594
4. Pexman JHW, Coates RK. Amnesia after femorocerebral angiography. *AJNR* 1983; 4:979-983
5. Wales LR, Nov AA. Transient global amnesia: complication of cerebral angiography. *AJNR* 1981;2:275-277
6. Mathew NT, Meyer JS. Pathogenesis and natural history of transient global amnesia. *Stroke* 1974;5:303-311
7. Shuttleworth EC, Wise GR. Transient global amnesia due to arterial embolism. *Arch Neurol* 1973;29:340-342
8. Murphy DJ. Cerebrovascular permeability after meglumine iohalamate administration. *Neurology* 1973; 23:926-936