



## Get Clarity On Generics

Cost-Effective CT & MRI Contrast Agents



WATCH VIDEO

# AJNR

### **CT evaluation of the greater sciatic foramen in patients with sciatica.**

B A Cohen, C F Lanzieri, D S Mendelson, M Sacher, G Hermann, J S Train and J G Rabinowitz

*AJNR Am J Neuroradiol* 1986, 7 (2) 337-342

<http://www.ajnr.org/content/7/2/337>

This information is current as  
of August 11, 2025.

# CT Evaluation of the Greater Sciatic Foramen in Patients with Sciatica

Burton A. Cohen<sup>1</sup>  
 Charles F. Lanzieri  
 David S. Mendelson  
 Michael Sacher  
 George Hermann  
 John S. Train  
 Jack G. Rabinowitz

Sciatic and lower extremity neurologic symptoms may be from pathologic involvement of the sacral plexus or sciatic nerve in the region of the greater sciatic foramen. Twenty-five patients were reviewed who presented consecutively over a 4 year period with sciatic symptoms secondary to pathologic changes in the greater sciatic foramen. Malignant neoplasm alone (18 patients) and malignant neoplasm associated with infection (two patients) account for most of these cases. Neurogenic tumors (three patients), both benign and malignant, and infection alone (three patients) were less frequent. Although sciatic symptoms usually derive from spinal abnormalities, the evaluation of sciatic symptoms should not be considered complete without CT scanning of the greater sciatic foramen.

The importance of computed tomography (CT) of the spine and sacrum in the evaluation of patients with sciatica and lower extremity neurologic symptoms has been well described [1-10]. Pathologic processes may involve the sacral plexus or sciatic nerve, causing lower extremity neurologic or sphincter symptoms by irritation of the long lumbar or sacral nerves. These processes may be occult to plain film or myelographic examination.

CT provides an accurate means of evaluating the sacrum and parasacral spaces including the greater sciatic foramen (GSF) [1-3]. Therefore, it is an extremely important technique in the evaluation of sciatic symptoms in those patients with a negative workup for spinal pathology. In the absence of sciatic symptoms, CT is also quite helpful in evaluating the GSF and its structures and in determining the nature and extent of pelvic inflammatory and neoplastic processes.

We retrospectively reviewed CT scans of 25 patients whose sciatic symptoms were demonstrated by CT to be caused by pathologic involvement of the GSF. We shall discuss the CT findings in these pathologic cases after briefly reviewing the normal anatomy of this region.

## Anatomic Considerations

The GSF is an oval space in the posterolateral aspect of the pelvis. It is bordered by the ilium superiorly, the sacrum posteriorly, the ischium anteriorly, and the sacrospinous ligament inferiorly. The GSF is traversed by several important structures including the piriform muscle, the sciatic nerve, and vessels and nerves to the internal obturator, quadratus femoris, and gluteal muscles.

On CT scanning, the piriform muscle and the sacrospinous ligament serve as useful landmarks in evaluating the GSF. The piriform muscle originates on the ventral surface of the sacrum and passes through the upper part of the GSF to insert on the greater trochanter (fig. 1A). It is the largest structure within the GSF and serves as an easily identifiable landmark for the superior part of the GSF. The sacral plexus resides on the anterior surface of the piriform muscle.

The sacrospinous ligament appears as a thin, gracile structure passing through

Received March 6, 1985; accepted after revision June 27, 1985.

<sup>1</sup> All authors: Department of Radiology, Mount Sinai Hospital and School of Medicine of the City University of New York, New York, NY 10029. Address reprint requests to B. A. Cohen, Mount Sinai Medical Center, 1 Gustave L. Levy Pl., New York, NY 10029.

**AJNR 7:337-342, March/April 1986**

0195-6108/86/0702-0337

© American Society of Neuroradiology

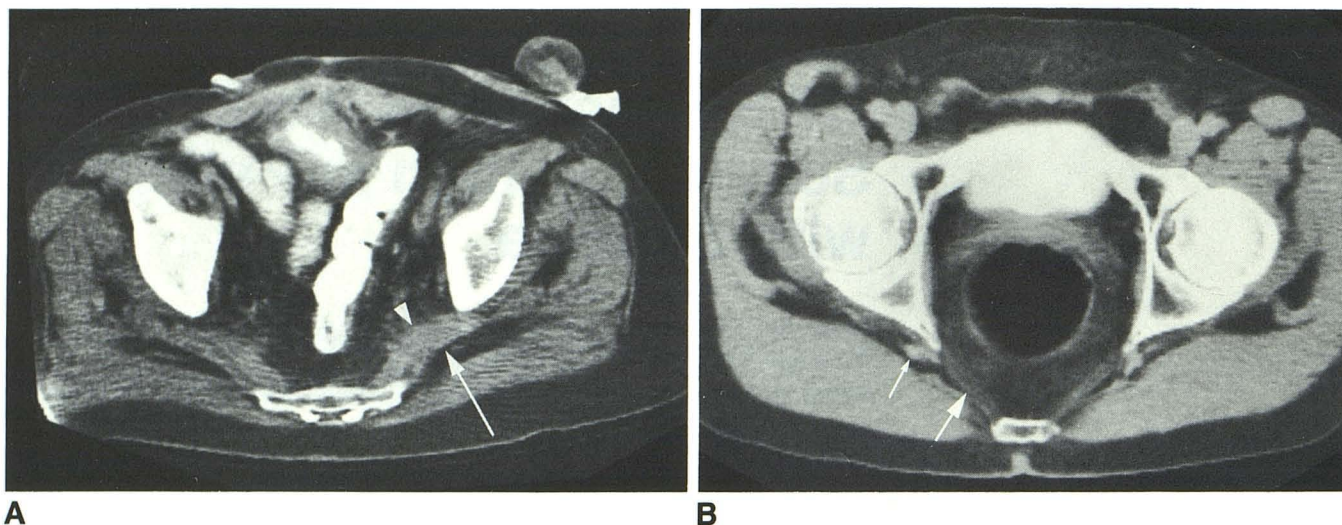


Fig. 1.—Normal greater sciatic foramen, axial images. **A**, Patient with bladder tumor and diverting colostomy for colon carcinoma. Piriform muscle (arrow) originating on lateral angle of sacrum passes through GSF. Sacral plexus (arrowhead) rests on anterior surface of piriform muscle. **B**, Caudad section in another patient. Sacrospinous ligament (large arrow), thin, gracile

structure originating on inferolateral aspect of sacrum and inserting on ischial spine. Sciatic nerve (small arrow) can often be identified as circular structure posterior to ischial spine and lateral to anterior insertion of sacrospinous ligament.

the inferior part of the GSF (fig. 1B). It has a wide origin on the inferolateral aspect of the sacrum and a narrow insertion on the ischial spine. The sciatic nerve can often be identified as a circular structure posterior to the ischial spine and lateral to the anterior insertion of the sacrospinous ligament (fig. 1B).

### Materials and Methods

The CT scans of 25 patients who presented consecutively over a 4 year period with a history of sciatic or lower extremity neurologic symptoms and were found by CT to have pelvic pathology involving the GSF were reviewed. The scans were obtained on a Pfizer 200 FS and a GE 8800 scanner in the axial plane using 13 and 10 mm slice thicknesses, respectively. Scans were viewed at window settings appropriate for soft tissue and bone detail. Intravenous contrast material was used in all cases.

Pathologic proof was obtained in 17 patients by either percutaneous or surgical biopsy. Two of the other eight patients had neurofibromatosis with other lesions noted, and six had well documented malignancy.

### Results

In a retrospective study, 25 patients with sciatic or lower extremity neurologic symptoms and examined by CT were found to have involvement of the GSF by tumor (neural and nonneural) or infection or a combination of both as an etiology for their symptoms (table 1). In most instances there was clinical suspicion that the cause of the sciatic pain arose in the pelvis; thus, much of the traditional workup was eliminated. CT of the lumbar spine and/or myelography were performed in cases 2, 4, 11, 24, and 25 and were normal. Of the 25 patients in our study, three suffered from neurofibromatosis with involvement of the GSF. In case 3 (fig. 2), a right

foot drop and enhancing fullness of the right sciatic nerve seen on multiple CT images was presumed to have represented a neurofibroma in a patient with known neurofibromatosis. One patient (case 1) presented with bilateral lower extremity pain and weakness. On CT (fig. 3), she was noted to have bilateral, large low-attenuation masses growing through the GSF and displacing the gluteal muscles; biopsy revealed that these low-attenuation masses represented liposarcomas.

Involvement of the GSF secondary to tumor was noted in 19 patients without history of neurofibromatosis. Tumor alone was the cause in 17 patients and tumor with secondary infection was noted in two. These diagnoses were confirmed by biopsy in 13 patients and were presumed to represent tumor recurrence or metastasis in six.

Four patients suffered from diffuse bone metastasis with involvement of the GSF. Case 5 had a right nephrectomy for an adult Wilms tumor. CT (fig. 4) demonstrated diffuse destructive bone metastasis with involvement of the left GSF and sacral plexus by an enhancing soft-tissue mass. In a patient (case 4) who presented with right-sided sciatic symptoms, CT demonstrated a mass destroying the right side of the bony pelvis growing into the right GSF. Further evaluation by CT demonstrated a previously unknown hypernephroma that was proven to represent the primary lesion in this patient.

Three patients presented with masses destroying the sacrum. In case 9, with right buttock and lower extremity pain, CT (fig. 5) demonstrated a large soft-tissue mass destroying the sacrum and filling almost the entire right GSF. Surgical biopsy demonstrated this to represent a primary lipofibrosarcoma.

In addition to case 8, three patients with histories of abdominal perineal or low anterior resection for colorectal carcinoma

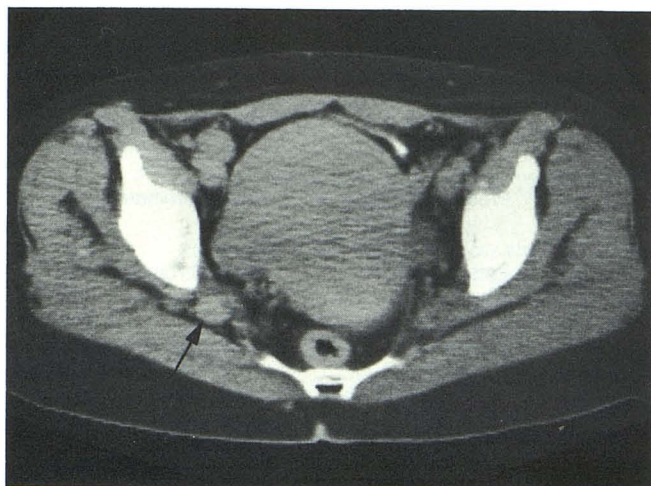


Fig. 2.—Case 3: neurofibromatosis and right-sided leg pain. CT demonstrates marked enlargement of right sciatic nerve (arrow).

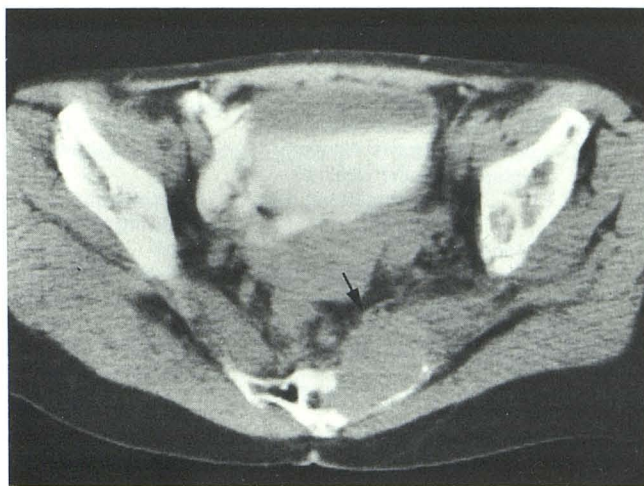


Fig. 4.—Case 5: left-sided sciatica after nephrectomy for Wilms tumor. CT demonstrates mass destroying left side of sacrum and extending into GSF (arrow) to involve sacral plexus.

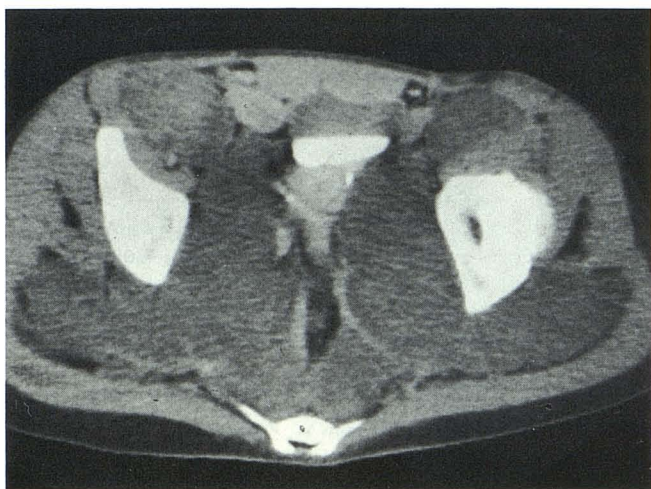


Fig. 3.—Case 1: neurofibromatosis and bilateral leg pain and weakness. CT demonstrates bilateral, large, low-attenuation pelvic masses extending through GSF. Surgical biopsy revealed these to represent bilateral liposarcomas.

were noted to have tumor recurrence involving the GSF. In one patient (case 11), this represented direct extension of tumor into the left GSF. In two cases, recurrent presacral tumors were complicated by abscesses extending into the GSF, bilaterally in case 12 (fig. 6) and into the right GSF in case 13.

Four patients had involvement of the GSF due to metastases to the iliac chain lymph nodes with encroachment on the GSF. Cases 15 and 17 had lymph node involvement caused by adenocarcinoma of unknown primary and prostatic carcinoma, respectively. Case 14 (fig. 7), status post total abdominal hysterectomy and bilateral salpingo-oophorectomy for endometrial carcinoma, was noted to have encroachment on the left GSF from metastases to the left iliac node chain.

Case 16 presented with a large rectal mass with metastatic involvement of the right obturator nodes extending into the right GSF.

Four patients presented with masses in the gluteal muscles extending into the GSF. Cases 20 and 21 had mass involvement secondary to metastatic colon carcinoma and liposarcoma, respectively. Cases 18 and 19 (fig. 8) presented with huge masses, in both cases representing melanoma involving the gluteal muscles and extending into the GSF.

Three patients presented with infection alone involving the GSF. In two, cases 23 and 25, the abscesses originated from the sacroiliac joint. In the third patient, case 24, the abscess was secondary to tuberculous spondylitis with a psoas abscess extending through the right GSF and involving the gluteal muscles.

## Discussion

Evaluation of the GSF is important when searching for the causes of sciatica and essential when evaluating the pelvis in patients with neoplastic and/or inflammatory disease. A knowledge of the anatomy of the GSF is necessary for the evaluation of this area and has been discussed.

Distinct and well defined fascial planes surround the pelvic and parapelvic structures. These planes may serve as avenues of communication between the presacral and parapelvic spaces, the retrosoas region, and the subgluteal regions (via the GSF). There are reports, primarily in the surgical and obstetric literature, that demonstrate that infectious processes involving the pelvic soft tissues have direct and easy access to and through the GSF [8, 11–16]. Kobak et al. [15], using radiopaque contrast material, demonstrated that fluid injected into paracervical and parauterine tissues spreads posteriorly into the presacral space and disperses laterally. Hibbard et al. [13] postulated that a pelvic infection can travel via the areolar tissues involving the lumbosacral plexus,

TABLE 1: Summary of Patients with CT Findings of Pelvic Pathology Involving the Greater Sciatic Foramen

Case No. (age, gender)	Clinical History	CT Findings	Diagnostic Procedures	Diagnosis
1 (37, F) . .	Neurofibromatosis; bilateral lower extremity pain and weakness	Bilateral low attenuation pelvic masses growing through GSF	Biopsy	Bilateral liposarcomas; neurofibromatosis
2 (35, F) . .	Neurofibromatosis; right foot drop	Multiple soft-tissue masses; mass involving right GSF; bony abnormality	Presumed	Neurofibromatosis
3 (62, F) . .	Neurofibromatosis; right-sided leg pain	Multiple neurofibromatous masses including involvement of right sciatic nerve	Presumed	Neurofibromatosis
4 (64, M) . .	Right-sided sciatica	Destruction of right ilium with mass growing into right GSF; scan of abdomen demonstrated right hypernephroma	Biopsy	Hypernephroma; metastases to right ilium extending into right GSF
5 (46, F) . .	S/P right nephrectomy for adult Wilms tumor; left-sided sciatica	Metastases involving both sides of bony pelvis; bone metastases on left side of sacrum extends into GSF	Presumed	Presumed metastases; chemotherapy and immunotherapy
6 (50, M) . .	Hypernephroma; diffuse bone pain; right-sided sciatica	Soft-tissue masses destructive of bone throughout pelvis; soft-tissue masses extending into right GSF	Presumed	Metastases; hypernephroma primary
7 (65, F) . .	Bilateral hip pain; right foot drop	Multiple masses destroying bone; mass in right GSF	Biopsy	Adenocarcinoma, unknown primary
8 (62, M) . .	Severe left sciatica; S/P abdominal perineal resection	Destruction of sacrum extending into left GSF	Biopsy	Metastatic rectal cancer
9 (70, F) . .	Right buttock and lower extremity pain	Large mass destroying sacrum, involving rectum, extending into right GSF and right gluteal muscles	Biopsy	Lipofibrosarcoma
10 (40, F) . .	Left-sided sciatic pain	Enhancing mass destroying sacrum, involving left GSF	Surgical biopsy and partial resection of sacrum	Chordoma
11 (73, F) . .	S/P low anterior resection; left-sided sciatica	Metallic clips posterior to bladder; mass in left GSF	Treated empirically with radiotherapy; did well symptomatically	Presumed metastatic colon carcinoma
12 (53, M) . .	S/P anterior resection for colon carcinoma; left-sided sciatica; right-sided sciatica	Recurrent tumor; abscess extending through right GSF; abscess extending through left GSF	Bilateral percutaneous drainage, producing purulent material	Bilateral trans-GSF abscesses; recurrent tumor
13 (53, M) . .	Rectal carcinoma; S/P abdominal perineal resection; right-sided sciatica; point tenderness	Recurrent mass in presacral space; abscess in right buttock extending through GSF; S/P percutaneous drainage with catheter extending through GSF	Percutaneous drainage and biopsy	Recurrent tumor abscess
14 (57, F) . .	S/P TAHBSO for endometrial carcinoma; left-sided sciatic pain	Mass involving left iliac lymph nodes, extending into GSF	Presumed	Presumed metastases; chemotherapy
15 (44, F) . .	Left-sided sciatica; S/P TAHBSO for benign disease	Enlargement of left iliac nodes extending into GSF	Surgical biopsy	Adenocarcinoma; unknown primary
16 (66, F) . .	Right-sided sciatica; large pelvic mass	Massive lymphadenopathy; large rectal mass; soft tissue fullness in region of right obturator nodes involving piriform muscles	Surgery	Rectal carcinoma; metastatic lymphadenopathy
17 (52, M) . .	Prostatic carcinoma; right-sided sciatica	Large, irregular prostate; soft-tissue fullness in region of sacral plexus most likely representing obturator nodes; bony abnormality	Presumed	Metastatic prostatic carcinoma
18 (68, M) . .	Bilateral lower extremity pain and weakness	Bilateral masses in upper abdomen involving left gluteal muscles and left GSF	Biopsy	Melanoma
19 (60, M) . .	Melanoma; right sciatic symptoms	Intraabdominal masses; large mass involving right gluteal muscles extending into right GSF	Surgical biopsy	Melanoma
20 (74, F) . .	Left-sided sciatica; history of colon carcinoma	Intraabdominal masses and lymphadenopathy; mass in left gluteal muscles involving GSF	Presumed	Metastatic colon carcinoma

TABLE 1: continued

Case No. (age, gender)	Clinical History	CT Findings	Diagnostic Procedures	Diagnosis
21 (40, M) . .	Severe right-sided sciatica	Soft-tissue mass in right gluteal muscles involving right GSF	Surgery	Liposarcoma
22 (59, F) . .	Severe right-sided sciatica; adenocarcinoma of unknown primary in liver	Large, irregular low-attenuation mass involving right GSF	Percutaneous biopsy	Adenocarcinoma of unknown primary
23 (28, F) . .	Right-sided sciatic pain	Low attenuation process involving right iliopsoas and obturator muscles extending to right GSF	Surgery	Sacroiliac abscess
24 (73, F) . .	Low back pain 2 years; right thigh pain 2 months	Destruction of L4; psoas abscess communicating with large right gluteal abscess via GSF	Percutaneous aspiration	Tuberculous abscess
25 (46, F) . .	Left thigh pain and sciatica	Osteomyelitis sacroiliac joint with associated abscess involving GSF	Percutaneous aspiration	Staphylococcal abscess

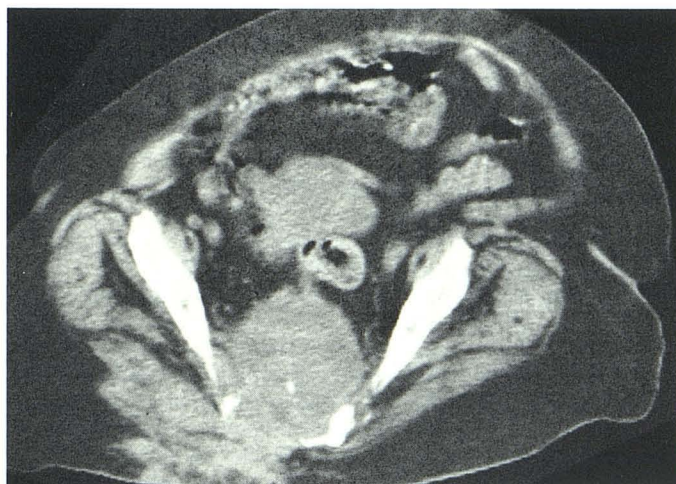
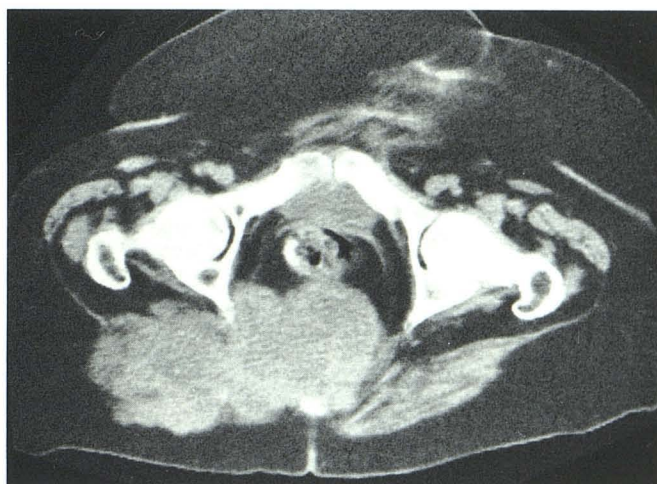
Fig. 5.—Case 9: right buttock and lower extremity pain. CT demonstrates large pelvic mass destroying sacrum and extending through GSF into right



buttock. Surgical biopsy demonstrated lipofibrosarcoma.

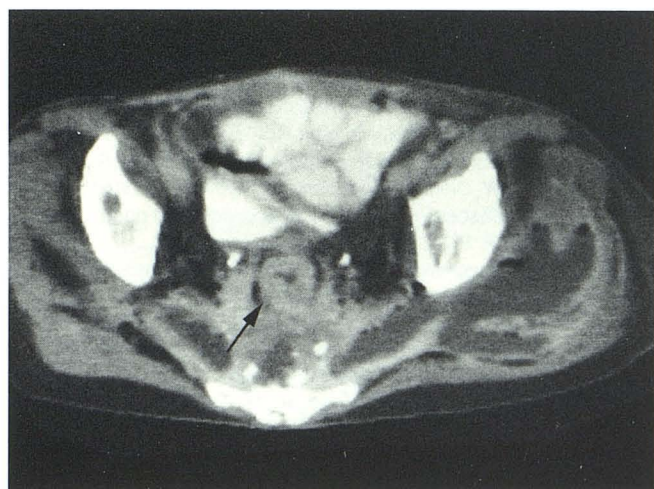

Fig. 6.—Case 12: severe bilateral sciatic symptoms. CT demonstrates rectum (arrow) to be anteriorly displaced by partly necrotic mass. Calcified densities in region of mass. Fluid collections extend into GSF bilaterally with air-fluid levels noted on left. Bilateral trans-GSF abscesses and recurrent tumor were diagnosed. Treatment was by percutaneous abscess drainage.

downward along the sciatic nerve roots through the GSF, or upward below the border of the psoas muscle to cause a retropsoas abscess. Spread of infection through the GSF via the fascial planes of either the pudendal nerves and vessels [12], the gluteal vessels, or the piriform muscle [8] has also been suggested. Hermann et al. [16] reported a case (included in our series) in which CT demonstrated a psoas abscess secondary to tuberculosis at L4–L5. This inflammatory process descended along the psoas muscle through the GSF to the gluteal region and extended to the posterolateral aspect of the upper thigh.

The use of CT for evaluation and follow-up of patients with pelvic malignancies, especially rectal carcinoma, has been described [17, 18]. Husband et al. [18] pointed out that recurrent rectal carcinoma may involve some of the structures that pass through the GSF, notably the piriform muscle. We have described multiple forms of metastases that may invade and affect the GSF. Tumor from the gluteal muscles extending into the GSF, as well as bone metastases, lymphadenopathy, and recurrent tumors with extension into the GSF, were all noted in our patients. Primary tumors, both benign and malig-

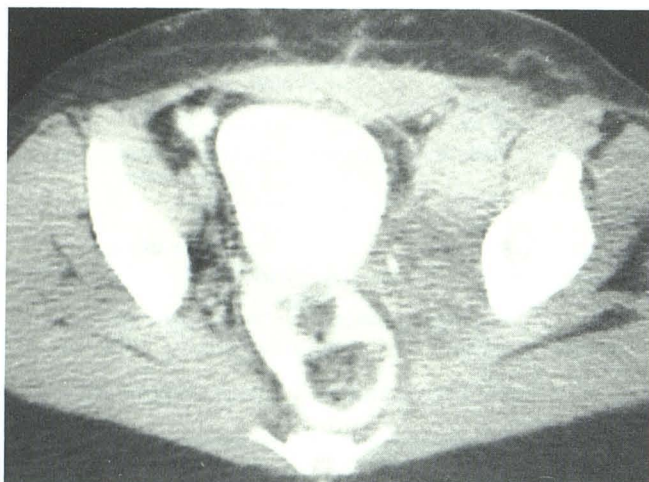


Fig. 7.—Case 14: left-sided sciatica. After total abdominal hysterectomy and salpingo-oophorectomy for endometrial carcinoma, CT demonstrates metastatic involvement of left iliac lymph node chain extending to left GSF.

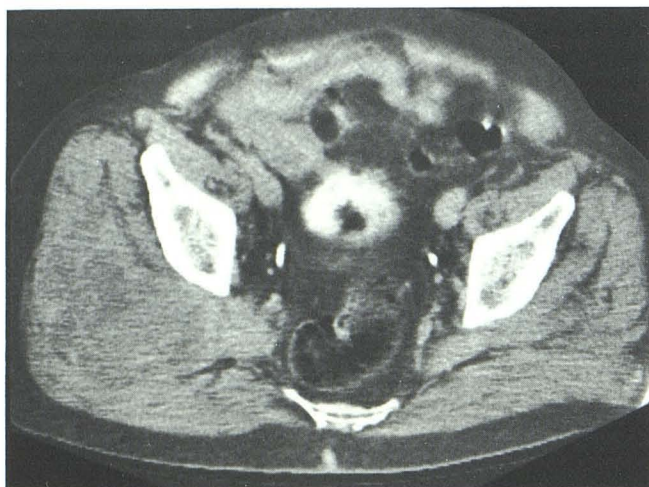


Fig. 8.—Case 19: severe pain in right leg in melanoma patient. CT demonstrates huge mass involving right gluteal muscles and extending into GSF.

nant, may arise within the GSF. When benign, these are often of neural origin. Woolfitt et al. [19] have reported the CT demonstration of primary neurofibrosarcoma involving the femoral nerve. We have noted bilateral primary liposarcomas and presumed benign neurofibromas involving the GSF and diagnosed by CT in patients with neurofibromatosis. Such tumors probably arise from the sacral plexus or sciatic nerves. We have demonstrated primary tumors of the sacrum involving the GSF. In our series the most common cause of GSF involvement by tumor has been metastatic disease.

The role of CT in the examination of the pelvis, especially the GSF, in patients complaining of sciatica must be stressed. Our cases indicate that a variety of inflammatory and neoplastic processes may involve the GSF and can be demonstrated to best advantage by CT. All of our patients had a history of lower extremity neurologic symptoms that were from involvement of the sciatic nerve or sacral plexus by a

process in the GSF. Pelvic CT demonstrated pathology unequivocally and was accurate in assessing the extent of disease. In the case of abscesses, CT-guided percutaneous aspiration is often a definitive treatment. We maintain that a negative workup of the patient with sciatica should not be considered complete without CT of the pelvis and GSF.

We recommend that patients with sciatica who have normal lumbar myelography and CT scans or in whom there is clinical suspicion of pelvic pathology have a CT evaluation of their greater sciatic foramen.

#### ACKNOWLEDGMENT

We thank Louisa Haigler for assistance in manuscript preparation.

#### REFERENCES

1. Lanzieri CT, Hilal SK. Computed tomography of the sacral plexus and sciatic nerve in the greater sciatic foramen. *AJNR* 1984; 5:315-318
2. Whelan MA, Gold RP. Computed tomography of the sacrum: 1. Normal anatomy. *AJNR* 1982;3:547-554
3. Gilula LA, Murphy WA, Tailor CC, Patel RB. Computed tomography of the osseous pelvis. *Radiology* 1979;132:107-114
4. Whelan MA, Gold RP. Computed tomography of the sacrum: 2. Pathology. *AJNR* 1982;3:555-559
5. Batnitzky S, Soye I, Levine E, Price HI, Hart KZ. Computed tomography in the evaluation of the lesions arising in and around the sacrum. *Radiographics* 1982;2:500-528
6. Turner ML, Mulhern CB, Dalinka MK. Lesions of the sacrum. *JAMA* 1981;245:275-277
7. Soye I, Levine E, Batnitzky S, Price HI. Computed tomography of sacral and presacral lesion. *Neuroradiology* 1982;24:71-76
8. Meshkov SL, Seltzer SE, Finberg HJ. CT detection of intraabdominal disease in patients with lower extremity signs and symptoms. *J Comput Assist Tomogr* 1982;6:497-501
9. Carrera GF, Williams AL, Haughton VM. Computed tomography in sciatica. *Radiology* 1980;137:433-437
10. Federle MP, Moss AA, Margolin FR. Role of computed tomography in patients with sciatica. *J Comput Assist Tomogr* 1980;4:335-341
11. Wolverson MK, Jagannadharao B, Sundaram M, Heiberg E, Grider R. Computed tomography in the diagnosis of gluteal abscess. *J Comput Assist Tomogr* 1981;5:34-38
12. Wenger DR, Gitchell RG. Severe infections following pudendal block anesthesia. *J Bone Joint Surg* 1973;55:202-207
13. Hibbard LT, Snyder EN, McVann RM. Subgluteal and retropsoal infection in obstetric practice. *Obstet Gynecol* 1972;39:137-150
14. Svancarek W, Chirino O, Schaefer G, Blythe JG. Retropsoas and subgluteal abscesses following paracervical and pudendal anesthesia. *JAMA* 1977;237:892-894
15. Kobak AJ, Sadove MS, Mazeros WT. Anatomic studies of transvaginal regional anesthesia. *Obstet Gynecol* 1962;19:302-310
16. Hermann G, Mendelson DS, Cohen BA, Train JS. Role of computed tomography in the diagnosis of infectious spondylitis. *J Comput Assist Tomogr* 1983;7:961-968
17. Kelvin FM, Forobkin M, Breiman RS, et al. Recurrent rectal carcinoma in an asymptomatic patient. *J Comput Assist Tomogr* 1982;6:186-188
18. Husband JE, Jodson NJ, Parsons CA. The use of computed tomography in recurrent rectal tumors. *Radiology* 1980; 134:677-682
19. Woolfitt RA, Brantly PN, Neal RK. CT demonstration of neurofibrosarcoma causing femoral neuropathy. *J Comput Assist Tomogr* 1982;6:1013-1014