



Get Clarity On Generics

Cost-Effective CT & MRI Contrast Agents



FRESENIUS
KABI

WATCH VIDEO

AJNR

Myelography with metrizamide: effect of contrast removal on side effects.

Y Numaguchi, A M Weems, A Mizushima, J Keating, A B Rege, F J Mather and J C Rice

AJNR Am J Neuroradiol 1986, 7 (3) 498-501

<http://www.ajnr.org/content/7/3/498>

This information is current as
of August 18, 2025.

Myelography with Metrizamide: Effect of Contrast Removal on Side Effects

Yuji Numaguchi,^{1,2} Alan M. Weems,² Akira Mizushima,¹ James Keating,¹ Arvind B. Rege,³ Francis J. Mather,⁴ and Janet C. Rice⁴

Although myelography with metrizamide may produce excellent-quality radiographs, the adverse side effects of the contrast agent often make it a less than desirable technique. In this report, the authors evaluate the effect of removing contrast medium after myelographic procedures.

Materials and Methods

Between January 1983 and May 1985, a group of patients who underwent either total spine, cervical, or combined (i.e., cervical-lumbar, cervical-thoracic, or lumbar-thoracic) myelography with metrizamide were reviewed to determine if removal of the metrizamide after the examination reduces the frequency of side effects. Another group of patients who had the same procedures without removal of the contrast medium served as the control. Lumbar or C1-C2 lateral punctures, or both, were used.

In the majority of cases of total or combined myelography, the cervical region was initially examined by using 5–10 ml of metrizamide (250–280 mg/ml). For lumbar and thoracic studies with split-dose techniques, 5–8 ml (180–220 mg I/ml) were added. For most patients who had total or combined myelography, large and small vials of metrizamide containing 3.26 and 1.81 g of iodine, respectively, were used to obtain two different concentrations. Patients were hydrated with oral fluids and premedicated with steroids and diazepam. A conventional fluoroscopy unit was employed and in the majority of patients, a 20-gauge spinal needle was used.

All patients were examined by using a protocol for total myelography (Figs. 1 and 2). Figure 1 demonstrates the lumbar method, which was used for patients who could fully extend their necks. Figure 2 shows the protocol for total myelography via the C1-C2 route, which was used for patients who could not fully extend their necks and for those with moderate kyphoscoliosis. Two methods of performing the procedure by the C1-C2 route were used: patients were either in a prone or supine position.

Combined myelography, such as cervical-lumbar, cervical-thoracic, or lumbar-thoracic, was performed by using various combinations of the protocols depending on the clinical indications.

Cerebrospinal fluid (CSF) with the contrast medium was removed in 73 patients upon completion of the study. Eighty-four patients, in whom the CSF was not removed after the procedure, served as the

control group. For removal of the CSF, replacement of a needle into the lumbar subarachnoid space was often necessary; 20–25 ml CSF containing metrizamide were removed in the upright and/or lateral recumbent position for retrieval of maximum amounts of contrast medium (Fig. 1). An additional 10–15 min were required for this procedure.

All patients, including the control group, were kept in a semierect position for 10 hr and then supine with their necks propped up for an additional 8 hr. Copious fluid intake was encouraged in both the study and control groups.

Results

The number of patients who experienced side effects after myelography is shown in Table 1. One group included patients who received more than 3.0 gl of metrizamide, and the other included those who received 3.0 gl or less. Mild adverse effects included headache, nausea, or vomiting within the first 24 hr after the procedure. Moderate adverse effects consisted of seizures, headache, nausea, or vomiting lasting more than 24 hr, or psychoneurologic symptoms such as confusion or disorientation.

When more than 3.0 gl contrast material were used, only mild or no adverse effects were encountered in 55 of the patients, while moderate effects were seen in 18. When 3.0 gl or less were used, 65 patients experienced mild or no adverse effects, while 19 experienced moderate effects. There was no significant difference in the rate of adverse effects between the two dose groups. One patient developed grand mal seizures 6 hr after cervical myelography via C1-C2 puncture in which 2.8 gl (280 mg/ml) was used. No contrast medium was removed in this patient after the procedure. To determine the effects of removing the contrast medium, we analyzed the data using the two sample tests of proportions.

With the administration of more than 3.0 gl, moderate adverse effects were noted in 13 (40%) of 32 patients from whom no metrizamide was removed, while only 5 (12%) of

Received January 18, 1985; accepted after revision October 20, 1985.

¹ Department of Radiology, Tulane Medical Center Hospital and Clinic, 1415 Tulane Avenue, New Orleans, LA 70112. Address reprint requests to Y. Numaguchi.

² Department of Neurosurgery, Tulane Medical Center Hospital and Clinic, 1415 Tulane Avenue, New Orleans, LA 70112.

³ Department of Pharmacology, Tulane Medical Center Hospital and Clinic, 1415 Tulane Avenue, New Orleans, LA 70112.

⁴ Department of Biostatistics and Epidemiology, Tulane Medical Center Hospital and Clinic, 1415 Tulane Avenue, New Orleans, LA 70112.

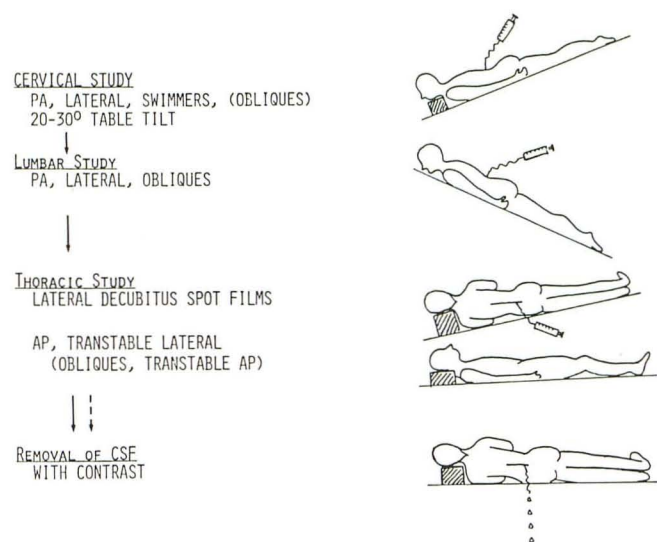


Fig. 1.—Protocols for total or combined myelography by lumbar route.

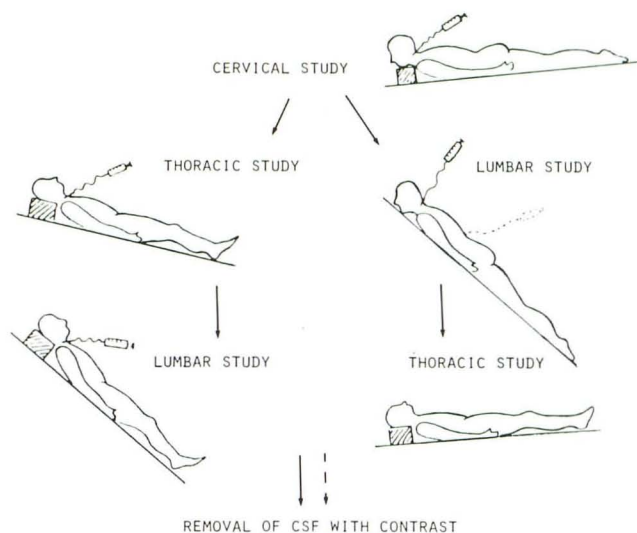


Fig. 2.—Protocols for total or combined myelography by C1-C2 and/or lumbar route.

TABLE 1: Adverse Effects According to Metrizamide Dose and Removal of Metrizamide

Type of myelography	Greater than 3.0 gl				3.0 gl or Less			
	Nonremoval		Removal		Nonremoval		Removal	
	None/Mild*	Moderate†	None/Mild	Moderate	None/Mild	Moderate	None/Mild	Moderate
Cervical (Lumbar Route)	5	8 (1)‡	6	0	17	5	15	1
Cervical (C1-C2)	1	1	1	0	8	5 (1§)	9	2
Total (Lumbar Puncture)	5	1 (1)	12	3	2	0	1	1
Total (C1-C2 and Lumbar Puncture)	0	0	6	0	1	0	0	0
Combined (C1-C2 and/or Lumbar Puncture)	8	3	11	2	10	4 (2)	2	1
Total Number	19	13 (2)	36	5	38	14 (3)	27	5

Note: Numerals indicate number of patients divided according to amount of metrizamide used and whether or not the contrast agent was removed following myelography.

* Headache, nausea, or vomiting within the first 24 hr.

† Headache, nausea, or vomiting lasting more than 24 hr and psychoneurologic symptoms.

‡ Numbers in parentheses indicate the number of patients with psychoneurologic symptoms.

§ This patient experienced seizure.

41 patients whose metrizamide was removed after the procedure experienced moderate adverse effects. The difference was statistically significant ($p < 0.01$).

Among the patients who received 3.0 gl or less, 14 (27%) of 52 whose metrizamide was not removed developed moderate adverse effects, while 5 (16%) of 32 whose metrizamide was removed experienced moderately adverse effects. This difference was also statistically significant ($p < 0.01$).

When data from the two dose groups were pooled, 27 (32%) of 84 patients whose metrizamide was not removed experienced moderate adverse effects. Among 73 patients whose metrizamide was removed, only 10 (14%) developed moderate adverse effects. Thus there were significantly fewer moderate adverse effects in the groups when CSF with metrizamide was removed ($p < 0.01$).

In the group whose metrizamide was removed, there were no psychoneurologic symptoms or seizures, whereas psychoneurologic symptoms occurred in 5 of 84 patients whose

metrizamide was not removed. One of them developed convulsions after the procedure.

For 20 patients whose CSF was removed, the amount of metrizamide removed was quantified by using liquid chromatography and/or digital photodensitometry. Removal of 20–25 ml CSF after myelography in the upright and/or lateral recumbent positions retrieved 20%–48% (average 34%) of the total contrast medium.

In many cases of cervical myelography by C1–C2 route, the retrieval of contrast medium was more effective because the medium was concentrated in the cervical region. With total or combined myelography, retrieval was more difficult because of diffusion.

Discussion

Numerous reports have been published concerning lumbar, cervical, or combined thoracic myelography with metrizamide.

The optimal techniques for these procedures are well documented [1-16].

Cervical, total, or combined myelography often requires large doses of metrizamide. Solti-Bohman and Bentson reported that total spinal canal myelography performed with less than the customary dose of 3.75 g metrizamide (containing 1.81 gl) was inadequate [14]. If complex motion tomography or digital subtraction units can be used [15, 16], the total dose of contrast medium for these techniques can be lower; for example, less than 2.0 gl may suffice. However, with conventional fluoroscopic units, 2.3 gl or more are necessary to achieve high-quality cervical, total, or combined studies. It is often necessary to use more than the recommended 3.0 gl, especially in heavier patients [9, 10]. When a large amount of contrast medium is used, adverse effects such as prolonged headache, nausea, vomiting, psychoneurologic symptoms, and seizures can be expected [14, 17-22].

Adverse effects after metrizamide myelography have been reported to be dose dependent [14], but our study showed no significant difference in adverse effects between the two dose groups. This may be because the iodine dose administered in these two groups fell within a relatively narrow range, approximately 3.0 gl. The rate of moderate adverse effects in our series was slightly higher than that measured by Fox et al. [9] but was similar to that reported by Sackett et al. for cervical and lumbar studies [22].

Attempts have been made to reduce these adverse reactions [8, 9, 14, 23-27]. Adequate hydration, small needles, minimum metrizamide doses, careful positioning of patients during the procedures, and prompt and optimal radiographic techniques decrease adverse effects. Removing metrizamide after myelography as described here has been given little attention [28]. Data and the efficacy of this technique have never been described in the literature. The exact amount of retrieved contrast medium by removing 20-25 ml of CSF fluctuates according to the patient's position and the examiner's skill. So far we have limited metrizamide retrieval to 25 ml to avoid intractable headache. Significant reduction of such adverse effects as prolonged headache, nausea, vomiting, and psychoneurologic symptoms seems to be the greatest advantage of contrast-removal techniques, especially in cases where large amounts of metrizamide are used.

Recently, new nonionic, water-soluble contrast media, such as iohexol or iopamidol, have been clinically investigated [29-33], and according to some studies, there are fewer adverse reactions associated with these newer agents than with the more commonly used metrizamide. These studies suggest that contrast-removal techniques may not be warranted with these agents. However, most data concerning the new contrast agents were restricted to lumbar or cervical studies in which a low iodine dose was used. No report is yet available concerning total or combined studies in which a larger amount of iodine is used.

Summary

Moderately severe side effects, such as prolonged headache, nausea, vomiting, or psychoneurologic symptoms, were

noted in 27 (32%) of 84 patients in whom the contrast medium was not removed. Conversely, among 73 patients from whom 20-25 ml of cerebrospinal fluid with the contrast medium was removed, only 10 (14%) experienced adverse effects, a statistically significant reduction. Although new contrast agents, such as iohexol and iopamidol, are reportedly less toxic than metrizamide, the contrast-removal technique described here may be indicated when large amounts of any contrast medium are used.

ACKNOWLEDGMENTS

We are grateful to Drs. Walter J. Russell and D. G. K. Varma for their valuable comments and for editing this manuscript.

REFERENCES

1. Skälpe IO, Amundsen P. Lumbar radiculography with metrizamide. *Radiology* 1974;115:91-95
2. Skälpe IO, Amundsen P. Thoracic and cervical myelography with metrizamide: clinical experience with a water-soluble, non-ionic contrast medium. *Radiology* 1975;116:101-106
3. Amundsen P. Metrizamide in cervical myelography. *Acta Radiol [Suppl]* (Stockh) 1977;355:85-97
4. Qronquist S, Brismar J. Cervical myelography with metrizamide. *Acta Radiol [Suppl]* (Stockh) 1977;355:110-120
5. Hindmarsh T. Metrizamide in selective cervical myelography. *Acta Radiol [Suppl]* (Stockh) 1977;355:127-134
6. Sortland O, Skälpe IO. Cervical myelography by lateral cervical and lumbar injection of metrizamide: a comparison. *Acta Radiol [Suppl]* (Stockh) 1977;355:154-167
7. Boyd WR, Gardiner GA. Metrizamide myelography. *AJR* 1977;129:481-484
8. Khan A, Marc JA, Chen M, Epstein JA. Total myelography with metrizamide through the lumbar route. *AJNR* 1981;2:85-90
9. Fox AJ, Vinuela F, Bebrun C. Complete myelography with metrizamide. *AJNR* 1981;2:79-84
10. Alenghat JP, Kin H, Duda EE. Cervical and lumbar metrizamide myelography: split-dose technique. *Radiology* 1983;149:852-853
11. Kaplan JO, Quencer RM, Strokes NA. Improved technique for cervical metrizamide myelography. *Radiology* 1980;135:519-520
12. Russell EJ, Pinto R, Krichell II. Supine metrizamide myelography; a technique for achieving excellent visualization of the thoracic cord and conus medullaries. *Radiology* 1980;135:227-228
13. Gabrielsen TO, Seeger JF, Knake JE, Burke DP, Stilwell EW. C1-2 puncture with the patient supine for thoracic metrizamide myelography. *Radiology* 1980;136:229-230
14. Solti-Bohman L, Bentson JR. Comparable advantage of small- and large-dose metrizamide myelography. *AJR* 1983;141:825-828
15. Holder JC, Binet EF. Metrizamide myelography with complex-motion tomography. *Radiology* 1982;145:201-202
16. Sherry RC, Anderson RE. Real-time digitally subtracted fluoroscopy for cervical myelography. *Radiology* 1984;151:243-244
17. Kieffer S, Binet E, Esquerre J, Hantman RP, Gross CE. Adverse side effects of metrizamide myelography: clinical and radiological evaluation of Amipaque and Pantopaque. *Radiology* 1978;129:695-705
18. Gelmers H. Adverse side effects of metrizamide in myelography. *Neuroradiology* 1979;181:177-184

19. Schmidt RC. Mental disorders after myelography with metrizamide and other water-soluble contrast media. *Neuroradiology* **1980**;19:153-157
20. Gauge O, Falkenberg H. Neuropsychologic reactions and other side effects after metrizamide myelography. *AJR* **1982**;139:357-360
21. Galle G, Huk W, Arnold K. Psychopathometric demonstration and quantification of mental disturbances following myelography with metrizamide and iopamidol. *Neuroradiology* **1984**;26:229-233
22. Sackett JF, Strother CM, Quagliari CE, Javid MJ, Levin AB, Duff TA. Metrizamide-CSF contrast medium: analysis of clinical application in 215 patients. *Radiology* **1977**;123:779-782
23. Eldevik OP, Nakken KO, Haughton VM. The effect of dehydration on the side effect of metrizamide myelography. *Radiology* **1978**;129:715-716
24. Robertson WD, Lapointe JS, Nugent RA, Robinson RC, Daly LF. Positioning of patients after metrizamide lumbar myelography. *AJR* **1980**;134:947-948
25. Sykes RHD, Wasenaar W, Clark P. Incidence of adverse effects following metrizamide myelography in nonambulatory and ambulatory patients. *Radiology* **1981**;138:625-627
26. Culati AN, Guadagnol DA, Quigley JM. Relationship of side effects to patient position during and after metrizamide lumbar myelography. *Radiology* **1981**;141:113-116
27. Teasdale E, Macpherson P. Incidence of side effects following direct puncture cervical myelography: bed rest versus normal mobility. *Neuroradiology* **1983**;25:85-86
28. Strother CM, Sackett JF, Kozarek JA. Removal of contrast medium after metrizamide myelography—effect on adverse reactions. Presented at annual meeting of the American Society of Neuroradiology, Toronto, Canada, May **1978**
29. Trevisan C, Malaguti C, Manfredini M, Tampieri D. Iopamidol vs metrizamide myelography: clinical comparison of side effects. *AJNR* **1983**;4:306-308
30. Bockenheimer SAM, Hillesheimer W. Clinical experience with iopamidol for myelography. *AJNR* **1983**;4:314-316
31. Kieffer SA, Binet EF, Davis DO, et al. Lumbar myelography with iohexol and metrizamide: a comparative multicenter prospective study. *Radiology* **1984**;151:665-670
32. Nakstad P, Helgetveit A, Aaserud O, Ganes T, Nubert-Hansen P. Iohexol compared to metrizamide in cervical and thoracic myelography. A randomized double blind study. *Neuroradiology* **1984**;26:479-484
33. Burrows EH. Myelography with iohexol (Omnipaque): review of 300 cases. *AJNR* **1985**;6:349-351